

October 2005

Bullous eruption on the posterior thigh

James Studdiford


Thomas Jefferson University, james.studdiford@jefferson.edu

Amber Stonehouse

Thomas Jefferson University

Let us know how access to this document benefits you

Follow this and additional works at: <http://jdc.jefferson.edu/fmfp>

 Part of the [Family Medicine Commons](#), and the [Translational Medical Research Commons](#)

Recommended Citation

Studdiford, James and Stonehouse, Amber, "Bullous eruption on the posterior thigh" (2005).

Department of Family & Community Medicine Faculty Papers. Paper 9.

<http://jdc.jefferson.edu/fmfp/9>

This Article is brought to you for free and open access by the Jefferson Digital Commons. The Jefferson Digital Commons is a service of Thomas Jefferson University's [Center for Teaching and Learning \(CTL\)](#). The Commons is a showcase for Jefferson books and journals, peer-reviewed scholarly publications, unique historical collections from the University archives, and teaching tools. The Jefferson Digital Commons allows researchers and interested readers anywhere in the world to learn about and keep up to date with Jefferson scholarship. This article has been accepted for inclusion in Department of Family & Community Medicine Faculty Papers by an authorized administrator of the Jefferson Digital Commons. For more information, please contact: JeffersonDigitalCommons@jefferson.edu.

Bullous eruption on the posterior thigh

James Studdiford, MD; Amber Stonehouse, MD

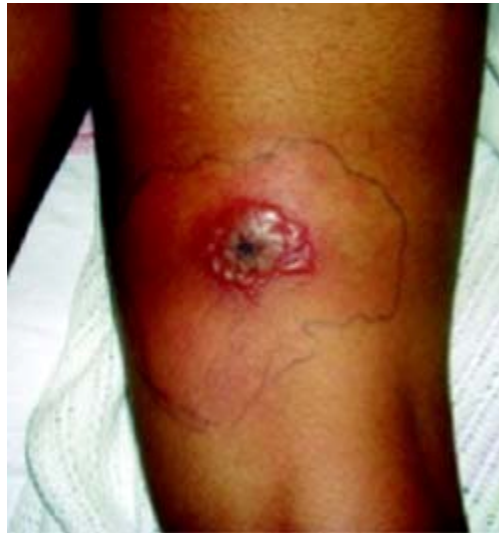Thomas Jefferson University Hospital, Department of Family and Community Medicine, Philadelphia, Pa

A healthy 11-year-old girl visited her family physician with a lesion on her right posterior thigh. The lesion was a 1-cm plaque that was tender, firm, erythematous, and indurated, with a central pustule. It had been present for 3 days; it was noticed by the patient after returning from a camping trip in southeastern Pennsylvania. The pustular area was incised, drained, and cultured, and the patient was started on cephalexin.

Two days later, the lesion did not improve, showing increased induration, erythema, and blistering. The patient went to the emergency department with an 8 cm by 6 cm coalescence of thin-walled vesicles and bullae with surrounding erythema (**FIGURES 1 AND 2**). A thick, honey-yellow adherent crust covered the eroded center of the lesion. The girl's temperature was 37.1°C, and she reported no burning, pain, or pruritus. She had full range of motion of her right hip and knee, and no lymphadenopathy was detected. Her white blood cell count was normal; blood and wound cultures were taken.

FIGURE 1

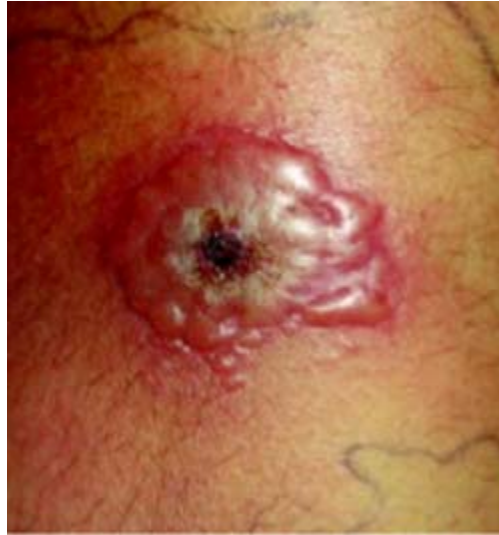Bullous eruption on the thigh



Large coalescence of thin-walled bullae on an erythematous base located on the right posterior thigh.

FIGURE 2

Close-up



Large coalescence of thin-walled bullae with a thick, honey-yellow adherent crust covering the eroded center of the lesion.

- **What is the most likely diagnosis?**
- **How would you empirically treat this condition?**
- **Diagnosis: Bullous impetigo, caused by methicillin-resistant *S aureus***

Impetigo is a highly contagious superficial skin infection, with peak incidence among children aged 2 to 6 years.^{1,2} Nonbullous impetigo (70% of cases) is caused by *Staphylococcus aureus* or beta-hemolytic *Streptococcus*.³ Bullous impetigo is almost always caused by *S aureus*. Epidermolytic toxins produced by phage group II strains cause loss of cell adhesion in the stratum granulosum due to proteolytic attack of desmoglein 1, resulting in bullae.⁴

Bullous impetigo may occur after minor skin injury, such as an insect bite, abrasion, or dermatitis.

Lesions generally start as small vesicles on the face, buttocks, extremities, or perineum, and may progress to a coalescence of thin-roofed bullae. The flaccid bullae rupture easily, draining serous or purulent fluid.

Lesions are usually painless, and systemic findings are rare. Lymphadenopathy is rare in bullous impetigo but common in nonbullous impetigo. The disease is generally self-limited and complications are uncommon. However, ecthyma (ulcerative impetigo) may result from an untreated impetigo infection.⁵

Differential diagnosis

The differential diagnosis for bullous impetigo is broad, and may include allergic contact dermatitis, herpes simplex, herpes zoster, pemphigus foliaceus, bullous pemphigoid, pemphigus vulgaris, and (in this case specifically) erythema migrans.

Allergic contact dermatitis is a delayed hypersensitivity reaction, usually caused by skin contact with an allergen. Lesions can be vesicular, edematous, erythematous, and pruritic. In this case, the patient did not have allergen exposure or a pruritic lesion.

Herpes zoster is a reactivation of the varicella zoster virus, characterized by stabbing, neuritic pain in a dermatomal distribution. Clear vesicles on an erythematous, edematous base distributed along a dermatome constitutes the classic appearance. This was not the case with this patient.

Pemphigus foliaceus is an autoimmune intraepidermal blistering disease with lesions occurring on the face, scalp, chest, and upper back.⁵ Intact blisters are not commonly seen. The vesicle roof is very thin and ruptures easily, forming broad areas of crust. Skin biopsy reveals intraepidermal bulla or acantholysis in the upper epidermis.

Pemphigus vulgaris is also an autoimmune blistering disease that affects the skin and mucous membranes. It is generally seen among patients aged >40 years.

Bullous pemphigoid is an autoimmune disorder presenting with chronic eruption of erythematous, papular, urticaria lesions often evolving into bullae. Childhood cases are rare. Biopsy of the lesions demonstrates subepidermal bulla with an infiltration of eosinophils within the dermis.⁵

Erythema migrans with central vesiculation must be considered given the patient's camping trip. Recent evidence shows that erythema migrans with central redness accounts for most cases in areas endemic for Lyme disease. Only 10% of the patients with early Lyme disease show the classic bulls-eye lesion with concentric erythematous rings and central clearing. Vesiculation can occur in up to 30% of lesions.⁶

Staphylococcus aureus and antibiotic resistance

As many as 61% of community-acquired methicillin-resistant *S aureus* (MRSA) infections are initially treated only with beta-lactam antibiotics, to which they are resistant.⁷ Risk factors for community-acquired MRSA infection include day-care attendance, recent hospitalization, recent antibiotic use, chronic illness, and frequent health care visits.⁸ A growing number of cases are reported among patients without risk factors.

Community-acquired MRSA isolates are usually genetically different from nosocomial isolates, and have been relatively susceptible to non-beta-lactam antibiotics. These

strains vary substantially, however, and it is important to check the susceptibility of the isolate.

Virulent new strains of *S aureus* are infecting children—these strains have a novel transpeptidase, which offers them a mechanism of resistance to beta-lactams different from hospital- and community-acquired types.

Awareness of the local antimicrobial susceptibility patterns of community *S aureus* isolates is also helpful. Oral antibiotics that have been successful include clindamycin, minocycline, doxycycline, and trimethoprim-sulfamethoxazole. Cephalexin has no therapeutic value in treating community-acquired MRSA.

Preventing disease spread in the patient and contacts

Preventive efforts should be directed at patients with recurrent episodes of MRSA skin abscesses. Metabolic and immunologic screening should be performed to rule out underlying disease processes causing increased risk for infection. In most cases these test results are normal, and patients with recurrent MRSA skin abscesses should also be empirically treated for presumed nasal carriage of MRSA.

Mupirocin ointment (Bactroban) should be applied to the nares twice daily for 5 days in an effort to prevent recurrent self-inoculation and lateral transmission of MRSA.

Patients and families should also be instructed in hygienic measures such as daily changing of underwear and personal use only of towels, washcloths, and sleepwear. Fingernails should be kept short and clean. Open insect bites or superficial skin abrasions should be kept clean and covered. Benefit from the daily use of antimicrobial soaps is controversial.

Empiric treatment of impetigo: Consider a culture for MRSA

For localized impetigo, topical therapy with mupirocin 2% ointment 3 times a day for 10 days is usually adequate. A 10-day course of oral antibiotic therapy with dicloxacillin or cephalexin is indicated in more widespread impetigo presumed to be methicillin-sensitive *S aureus*. Azithromycin (Zithromax) or clarithromycin (Biaxin) may be given to patients allergic to penicillin.

However, it is becoming increasingly important to consider community-acquired methicillin-resistant *S aureus* species in cases such as this that do not respond to traditional therapy. Hence, culture and sensitivity of all suspicious lesions is highly suggested.

Patient's treatment and recovery

In this case, the patient was diagnosed with bullous impetigo and admitted to the hospital. She was started on intravenous clindamycin at 380 mg (30 mg/kg) every 8 hours.

Clindamycin was chosen because most cases of community-acquired MRSA in this geographic area are resistant to trimethoprim-sulfamethoxazole and susceptible to clindamycin.

Although doxycycline would have covered both community-acquired MRSA and Lyme disease, we were less suspicious of Lyme given the physical exam of the patient, and we were reluctant to start this patient on doxycycline due to the fact she did not have complete maturation of her dentition.

Within 24 hours of intravenous clindamycin, the lesion was markedly improved and the culture confirmed that the MRSA was sensitive to clindamycin. She was discharged on oral clindamycin at 375 mg 3 times daily, to complete a 14-day course of therapy. The lesion was completely resolved without recurrence within 2 weeks.

REFERENCES

1. Dagan R. Impetigo in children: changing epidemiology and new treatments. *Pediatric Annals* 1993;22:235–240.
2. Bruijnzeels MA, van Suijlekom-Smit LW, van der Velden J, van der Wouden JC. The child in general practice. Dutch national survey of morbidity and interventions in general practice. Rotterdam: Erasmus University Rotterdam, 1993.
3. Allen CH, Patel M, Endom E. Primary bacterial infections of the skin and soft tissues changes in epidemiology and management. *Clin Ped Emerg Med* 2004;5:246–255.
4. Amagai M, Matsuyoshi N, Wang ZH, et al. Toxin in bullous impetigo and staphylococcal scalded skin syndrome targets desmoglein 1. *Nat Med* 2000;6:1275.
5. Habif TP. *Skin Disease Diagnosis and Treatment*. 2nd ed. Philadelphia, Pa: Elsevier-Mosby 2005;136–141.
6. Smith RP, Schoen RT, Rahn DW, et al. Clinical characteristics and treatment outcome of early Lyme disease in patients with microbiologically confirmed erythema migrans. *Ann Intern Med* 2002;136:477–479.
7. Naimi TS, LeDell KH, Como-Sabetti K, et al. Comparison of community- and health care-associated methicillin-resistant *Staphylococcus aureus* infection. *JAMA* 2003;290:2976.
8. Cohen P. Community-acquired methicillin-resistant *Staphylococcus aureus*: skin infection presenting as an axillary abscess with cellulites in a college athlete. *Skin Med* 2005;4:115–117.

CORRESPONDING AUTHOR: Richard P. Usatine, MD, University of Texas Health Science Center at San Antonio, Department of Family and Community Medicine, MC 7794, 7703 Floyd Curl Drive, San Antonio, TX 78229-3900. E-mail: usatine@uthscsa.edu