As submitted to:

Personalized Medicine Universe

And later published as:

Extracorporeal Membrane Oxygenation as a Bridge to Decision or Recovery: Medical and Ethical Dilemmas

Volume 2, Pages: 37-40, July 2013.

Shigeki Tabata, MD, James T. Diehl, MD, Nicholas C. Cavarocchi, MD, Hitoshi Hirose, MD

Department of Surgery, Division of Cardiothoracic Surgery, Thomas Jefferson University, Philadelphia, PA

Address for correspondence:

Hitoshi Hirose, MD, Thomas Jefferson University, 1025 Walnut Street, Room 605

Philadelphia, PA 19107

Tel.: +1-215-955-5654; Fax: +1-215-955-6010

E-mail: Hitsohi.Hirose@jefferson.edu

Abstract

Extracorporeal life support has advanced from its humble beginnings over 3 decades ago, with the first description of its success in a patient with Acute Respiratory Distress Syndrome (ARDS), going as far back as 1971. The indications for extracorporeal membrane oxygenation (ECMO) therapy include refractory respiratory and/or cardiac failure, and ECMO is now being increasingly used in adult patients. In this case report, we present a patient who had traveled from India to the United States, where she developed acute decompensated biventricular failure and shock, requiring ECMO placement as a bridge to a decision. During her first 36 hours on ECMO, the patient lost intrinsic cardiac rhythm. However, her multiple organ dysfunction as well as her neurological status improved and were maintained by ECMO support. Further work-up indicated that the patient was not a candidate for heart transplant or for a permanent ventricular-assist device. The patient and her family were persistent in her desire to live, and ECMO was continued until the patient recovered from the acute decompensation of her chronic heart failure. ECMO was weaned with the appropriate pharmacological support. The patient was switched over to oral heart failure medications, transferred to a rehabilitation facility, and discharged to home in 1 month.

Keywords: ECMO, cardiac arrest, heart failure, survival

Selected Abbreviations and their Definitions

ARDS = Acute Respiratory Distress Syndrome

BSA = Body Surface Area

CT = Computed Tomography

ECMO = Extracorporeal Membrane Oxygenation

ELSO = Extracorporeal Life Support Organization

EF = Ejection Fraction

ICU = Intensive Care Unit

LV = Left Ventricle

LVAD – Left Ventricular–Assist Device

MCS = Mechanical Cardiac Support

NIRS = Near-Infrared Spectroscopy

PMP = Poly-Methyl-Pentene

RV = Right Ventricle

TEE = Transesophageal Echocardiography

VAD = Ventricular Assist Device

VA ECMO = Veno-Arterial ECMO

1. **Introduction**

The in-hospital mortality of acute decompensated heart failure is as high as 50–70% [1]. Extracorporeal membrane oxygenation (ECMO) has been used for rescue with hemodynamic collapse. Bedside percutaneous ECMO requires arterial and venous access with 18–24-Fr cannulas, and its procedure is relatively easy to perform in the Intensive Care Unit (ICU). Compared with other modalities of mechanical cardiac support (MCS), such as ventricular-assist devices (VADs), ECMO is simple in design and able to provide biventricular support. The reported rate of successfully weaning patients in cardiogenic shock from ECMO is 30–45% [2], and more than half of patients weaned from ECMO undergo permanent VAD placement or heart transplantation. However, certain patients do not qualify for either a VAD or heart transplantation due to body habitus, presence of co-morbidities, or low socioeconomic status. Depending on the primary pathology, patients with acute decompensated heart failure could recover if appropriate support, even ECMO, were provided. The maintenance of end-organ function is the key to success in the survival of patients on ECMO. With appropriate ECMO support and medical management, the patient can be alert enough to communicate with family and medical personnel and to be involved in making critical medical decisions. In this report, we present a patient who developed cardiogenic shock, was supported with ECMO, and recovered from a complete loss of cardiac function to be successfully discharged from the hospital without the need for any MCS.

2. Case report

A 66-year-old woman, who had traveled from India, presented to the emergency room complaining of shortness of breath. Her past medical history included remote stroke and recent weight loss (20 kg over the past year). When she arrived at the emergency room, she was fully awake and hemodynamically stable. Her physical examination was unremarkable except for fine crackles heard on auscultation of both lungs and a small body habitus, with cachexia (weight 38 kg, height 152 cm, and body surface area [BSA] 1.27 cm^2). Echocardiography revealed chronic biventricular failure, with an ejection fraction (EF) of 10% (Video 1).

The patient's condition deteriorated overnight, and she was placed on mechanical ventilation for acute pulmonary edema (Fig. 1). Inotropes and vasopressors were initiated. Swan-Ganz catheter was inserted, and it demonstrated a cardiac index of 1.2 L/min/cm^2, on maximum inotropic support (dobutamine 20 µg/kg/min, epinephrine 0.1 µg/kg/min, and milrinone 0.5 µg/kg/min). The patient developed a ventricular tachyarrhythmia requiring multiple cardioversions. Because of profound cardiogenic shock, veno-arterial ECMO (VA ECMO) cannulae were placed in the patient’s femoral artery and vein at bedside in the ICU. Initial ECMO flow was 4 L/min. Inotropes and vasopressors were quickly discontinued under ECMO support. The patient was placed on hypothermia protocol due to emergency codes related to multiple episodes of cardiac ventricular tachyarrhythmia and unresponsiveness. . Cardiac catheterization was performed to rule out coronary artery disease (Fig. 2). Computed tomography (CT) scan of the chest showed chronic pulmonary emboli in the left main pulmonary artery (Fig. 3), with chronic interstitial lung disease; CT scan of the head revealed a prior left frontal stroke. In the first 24–36 hours on ECMO support, the patient continued to have multiple ventricular tachyarrhythmias, which were

treated with amiodarone and lidocaine. On ECMO day 2, the patient developed complete AV block, while ECMO flow was maintained at 4 L/min. On ECMO day 4, a temporary transvenous endocardial pacing wire was inserted without capture, despite optimal placement; ventricular capture was regained 48 hours later. Neurological exams were not reliable until sedation and paralytics was discontinued on ECMO day 3. Although the sedatives were discontinued the patient remained unresponsive off any sedation for a week. The patient slowly awakened, and she was able to communicate with her family through the endotracheal tube; she clearly expressed her wish to live. Her chronic lung disease, age, and previous stroke eliminated her as a candidate for heart transplantation. She underwent tracheostomy and percutaneous endoscopic gastrostomy to facilitate pulmonary toilet and nutritional support (Fig. 4). A bedside ECMO weaning trial using echocardiography was performed. The first weaning trial on ECMO day 10 failed, secondary to the right ventricular (RV) failure; however, the second weaning trial on ECMO day 15 showed improvement of the RV function (Videos 2 and 3). Despite RV recovery, the left ventricular (LV) function remained poor. Left ventricular–assist device (LVAD) placement was considered; however, due to her small body habitus and her status as a non-transplant candidate, an LVAD procedure was declined. Multiple family discussions were held to discuss medical options as well as end-of-life decisions. Because the patient was not a candidate for either transplant or LVAD, the decision was made to wean her off ECMO and optimize her pharmacologic management. On ECMO day 17, she was taken to the operating room for ECMO removal under miniaturized transesophageal echocardiography (TEE, Imacor, Garden City, NY.). With dobutamine and epinephrine support, ECMO could be discontinued. During her 17-day period of ECMO support, she had no complications, including infection, surgical-site bleeding, or mechanical problems with the oxygenator or pump.

Over the next week, the patient was weaned off mechanical ventilation, and parenteral inotropes were tapered as the transition to oral heart-failure medications was made. On postoperative day 7 after ECMO removal, an intracardiac defibrillator with biventricular pacer was placed for primary prevention of the ventricular arrhythmia. Echocardiography demonstrated severe LV dysfunction, with an EF of 25%, and normal RV function (Video 4). The patient was able to sit in chair with a physical therapist on postoperative day 9 (Fig. 5). She was eventually transferred to rehabilitation facility on postoperative day 22, without supplemental oxygen support and on an oral diet. She was discharged to home after 2 weeks in the rehabilitation facility. Echocardiography performed the week after discharge demonstrated stable LV function, with an EF of 25%, and normal RV function (Video 5).

3. Discussion

On May 6, 1953, Gibbon used the first heart–lung machine (cardiopulmonary bypass), which was developed at Jefferson Medical College in Philadelphia, for the repair of an atrial-septal defect in an 18-year-old girl. ECMO is the extension of the Gibbon's heart–lung machine. Both cardiopulmonary bypass and ECMO provide mechanical cardiopulmonary support; however, the present-day ECMO circuits provide a rapid, inexpensive, and portable device to support circulation. The primary components of an ECMO circuit are the pump and the oxygenator, which assume the roles of the heart and the lungs, respectively.

In 1971, Hill reported the first successful use of ECMO in a patient who was dying from respiratory failure [3]. Initially, the use of ECMO was reserved primarily for neonates, with a

success rate of 60–75%. On the contrary, the early results of ECMO use in adults were disappointing. In the 1970s, the National Institutes of Health supported a randomized multicenter trial of adult ECMO and concluded there was no survival benefit in ECMO over the optimal medical therapy [4]. However, with advancements in mechanical technology, the outcomes in adult ECMO cases have continuously improved [5]. The Extracorporeal Life Support Organization (ELSO) established a database of ECMO cases in the 1980s. In the early stage of the ELSO database, the adult cardiac survival rate was 0; however, it improved to 30–40% in the 1990s and to 40–50% in the 2000s [2]. A major contribution to ECMO technology over the past decade has been the development of the poly-methyl-pentene (PMP)-membrane oxygenator. Compared with the first generation of oxygenators, such as the silicone-membrane and the hollow-fiber polypropylene-membrane oxygenators, the PMP-membrane oxygenator provides improved gas-exchange efficiency and increased longevity [5]. Another critical development in ECMO therapy is the evolution of the centrifugal pump. Driven by a magnetic impeller, it is gaining popularity worldwide and has been reported to result in reduced hemolysis and few circuit complications [6].

As the technology of the ECMO circuit has improved, patient care during ECMO support has focused on end-organ recovery. During ECMO support, organs such as the brain, liver, kidney, lungs, gastrointestinal tract, and muscles are well perfused; thus, the organ injured due to abrupt cardiopulmonary failure will have a chance to recover [7]. Reviewing our institutional experience in the academic year of 2010–2011, 16 patients (median age of 46 years) underwent ECMO support for a median of 8 days (range, 2–28 days), with a survival-to-discharge rate of 63%. Among these survivors, metabolic laboratory profiles were improved in all, liver function

was maintained or improved in 93%, renal function was maintained or improved in all, and pulmonary edema was improved in all.

The presented case was a typical VA ECMO case for cardiogenic shock. ECMO was placed to support the patient in order to provide a bridge to a decision, since the patient was pre-morbid. ECMO provided sufficient blood flow to vital organs, improving or maintaining end-organ function. The optimal flow on ECMO is usually set as 2.2 × BSA, as long as the heart is beating. In this case, the BSA was 1.27 cm^2; thus, 2.8 L/min was theoretically enough to maintain the circulation. However, we ran the ECMO with maximal flow (4 L/min) to avoid overdistension of the heart while the patient was asystolic and in cardiac standstill.

Therapeutic hypothermia post cardiac arrest has been demonstrated to improve neurological recovery [8]. During the 24-hour cooling and 12-hour rewarming, cerebral perfusion was monitored using near infrared spectroscopy (NIRS). We have recently reported the results with NIRS monitoring to detect cerebral events in patients on ECMO [9]. The NIRS monitoring showed equal and adequate regional tissue oxygen saturation even while the patient was hypothermic. Although we were optimistic for her neurological recovery with adequate NIRS signals on ECMO, the patient did not fully awaken for a week. The confirmation of neurological recovery is important information in order to proceed with the next step of treatment. Initially, this was difficult to confirm, as the patient spoke only Hindi. Fortunately, the house staff and hospital services provided interpretation, and her neurological recovery was confirmed early. The family continued to support her decision of not wanting to withdraw care.

There were few long-term treatment options left for this patient. ECMO is a temporary device and not designed for long-term use. The chances of complications related to ECMO, especially bleeding complications, increase exponentially over time. The decision as to the next treatment option after ECMO removal was discussed at length with the staff and family. The patient's body habitus was simply too small for an implantable LVAD. The second-generation LVADs, such as the Heartmate II, which is almost half of the size of the first-generation LVAD (Heartmate XVE), can be placed in smaller patients; however, the FDA recommends careful patient selection for patients with small body habitus (BSA less than 1.3 cm^2) and recommends against implantation in patients with cachexia [10]. The other possible experimental implantable device available to our program was the Jarvik 2000; it can be used in patients with a BSA under the lower limit of 1.5 cm^2, but requires that this be performed only as a bridge to transplant [11]. The only option left for this patient was optimal medical management. We performed careful bedside ECMO weaning over 4 hours, using miniaturized TEE designed for hemodynamic monitoring in addition to conventional transthoracic echocardiography, and demonstrated appropriate cardiac responses to inotropes. One day after confirmation of hemodynamic stability with minimal ECMO support, the ECMO was successfully decannulated in the operating room. After ECMO was discontinued and the patient was weaned from inotropes, she was managed with standard oral heart failure medications, which played a role in her recovery and her return home.

4. Conclusion

In this case report, we presented a patient who required ECMO support for cardiogenic shock complicated by malignant tachyarrhythmia and cardiac arrest. ECMO maintained organ

perfusion without causing any complications. ECMO was removed solely with pharmacological support, without any need for MCS.

References

1 Holmes DR Jr, Bates ER, Kleiman NS, Sadowski Z, Horgan JH, Morris DC, Califf RM, Berger PB, Topol EJ. Contemporary reperfusion therapy for cardiogenic shock: the GUSTO-I trial experience. The GUSTO-I Investigators. Global Utilization of Streptokinase and Tissue Plasminogen Activator for Occluded Coronary Arteries. J Am Coll Cardiol. 26 (1995) 668-674.

2 Conrad SA, Rycus PT, Dalton H. Extracorporeal Life Support Registry Report 2004. ASAIO J 2005;51:4-10.

3 Hill JD, O'Brien TG, Murray JJ, Dontigny L, Bramson ML, Osborn JJ, Gerbode F. Prolonged extracorporeal oxygenation for acute post-traumatic respiratory failure (shock-lung syndrome). Use of the Bramson membrane lung. N Engl J Med 1972; 286:629-34.

4 Zapol WM, Snider MT, Hill JD, Fallat RJ, Bartlett RH, Edmunds LH, Morris AH, Peirce EC 2nd, Thomas AN, Proctor HJ, Drinker PA, Pratt PC, Bagniewski A, Miller RG Jr. Extracorporeal membrane oxygenation in severe acute respiratory failure. A randomized prospective study. JAMA 1979; 242: 2193-6.

5 Sidebotham D, McGeorge A, McGuinness S, Edwards M, Willcox T, Beca J. Extracorporeal membrane oxygenation for treating severe cardiac and respiratory failure in adults: part 2-technical considerations. J Cardiothorac Vasc Anesth 2010; 24:164-72.

6 Formica F, Avalli L, Martino A, Maggioni E, Muratore M, Ferro O, Pesenti A, Paolini G. Extracorporeal membrane oxygenation with a poly-methylpentene oxygenator (Quadrox D). The experience of a single Italian centre in adult patients with refractory cardiogenic shock. ASAIO J 2008;54:89-94.

7 Wong JK, Siow VS, Hirose H, Karbowski P, Miessau J, Baram M, DeCaro M, Pitcher HT, Cavarocchi NC. End organ recovery and survival with the QuadroxD oxygenator in adults on extracorporeal membrane oxygenation. Word J Cardiovasc Surg 2012;2:73-80

8 Nolan JP, Morley PT, Hook TL, Hickey RW. Advancement Life support Task Force of the International Liaison committee on Resuscitation. Therapeutic hypothermia after cardiac arrest. An advisory statement by the Advancement Life support Task Force of the International Liaison committee on Resuscitation. Resuscitation 2003;57:231-5.

9 Wong JK, Smith TN, Pitcher H, Hirose H, Cavarocchi NC. Cerebral and extremity near-infrared spectroscopy in adults on extracorporeal membrane oxygenation (ECMO). Artif Organs 2012;36:659-67.

10 Russell S, Slaugher M, Pagani F, Moore S, Idrissi K, Klodell C. Heartmate II LVAS: patient management guideline. Available from FDA website: dockets/ac/07/briefing/2007-4333b2-20-%209_4%20HM%20II%20Patient%20Management%20Guidelines.pdf.

11 Komoda T, Drews T, Hetzer R, Lehmkuhl HB. Adult candidates for heart transplantation with larger body surface area have better prognosis on waiting list after progression to critically ill status. Eur J Cardiothorac Surg 2011;39:317-22.

Figure Legends

Figure 1. Chest x-ray on presentation

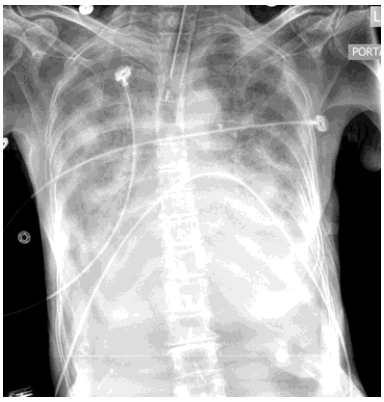

Figure 2. Cardiac cauterization showing patent coronary arteries. A: Right coronary angiography; B: Left coronary angiography

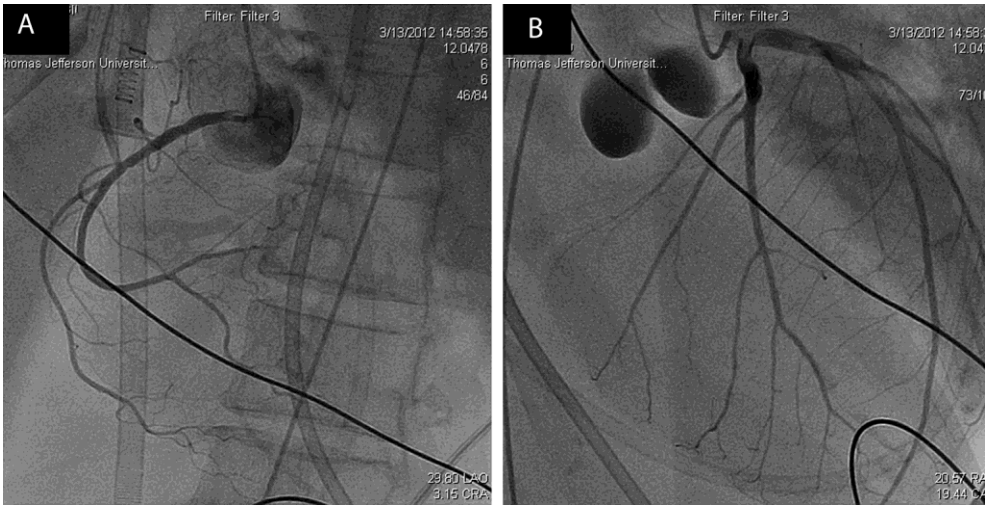

Figure 3. CT scan of the chest showing chronic pulmonary emboli

Figure 4. Chest x-ray post tracheostomy

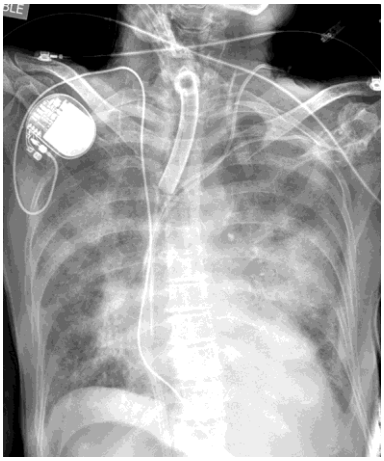

Figure 5. Patient is sitting in a chair

Video 1. Echocardiography at presentation showing biventricular dysfunction

Video 2. Echocardiography on full ECMO support without inotropes

Video 3. Echocardiography on minimal ECMO support with dobutamine 5 µg/kg/min showing improved right ventricular function

Video 4. Echocardiography of the patient 14 days after ECMO removal

Video 5. Echocardiography of the patient after discharge to home