

8-27-2023

## Isolated Cerebral Mucormycosis and Aspergillosis Coinfection in an Immunocompromised Adult

George Sun

Allison Weiss

Joy Zhao

Mitchell Silver

Michael DeMaio

*See next page for additional authors*

Follow this and additional works at: <https://jdc.jefferson.edu/neurologyfp>



Part of the [Fungi Commons](#), [Medical Immunology Commons](#), and the [Neurology Commons](#)

**[Let us know how access to this document benefits you](#)**

---

This Article is brought to you for free and open access by the Jefferson Digital Commons. The Jefferson Digital Commons is a service of Thomas Jefferson University's [Center for Teaching and Learning \(CTL\)](#). The Commons is a showcase for Jefferson books and journals, peer-reviewed scholarly publications, unique historical collections from the University archives, and teaching tools. The Jefferson Digital Commons allows researchers and interested readers anywhere in the world to learn about and keep up to date with Jefferson scholarship. This article has been accepted for inclusion in Department of Neurology Faculty Papers by an authorized administrator of the Jefferson Digital Commons. For more information, please contact: [JeffersonDigitalCommons@jefferson.edu](mailto:JeffersonDigitalCommons@jefferson.edu).

---

**Authors**

George Sun, Allison Weiss, Joy Zhao, Mitchell Silver, Michael DeMaio, and Sara Dehbashi



OPEN ACCESS

# Isolated cerebral Mucormycosis and Aspergillosis coinfection in an immunocompromised adult

George Sun , Allison Weiss, Joy Zhao, Mitchell Silver, Michael DeMaio, Sara Dehbashi

Neurology, Thomas Jefferson University Sidney Kimmel Medical College, Philadelphia, Pennsylvania, USA

**Correspondence to**  
Dr Sara Dehbashi;  
sara.dehbashi@jefferson.edu

Accepted 14 August 2023

## SUMMARY

Opportunistic fungal infections are a major cause of mortality in immunosuppressed patients, with mucormycosis and aspergillosis as two of the most commonly identified fungal organisms. Coinfection with mucormycosis and aspergillosis is rare, but cases have been reported in literature, most commonly presenting as disseminated invasive fungal infection with cerebrorhino-orbital involvement in an immunocompromised patient. Infections are most commonly caused by direct implantation of spores with localised angioinvasion. Haematogenous spread is rare, with most cases secondary to haematological malignancies or intravenous drug use. Coinfection with mucormycosis and aspergillosis portends a poor prognosis, with a high mortality rate. Thus, prompt recognition and intervention are crucial to prevent poor outcomes. In this unique case report, we describe a case of isolated cerebral mucormycosis and aspergillosis coinfection, not previously reported in literature.

## BACKGROUND

Cerebral coinfection with haematogenous mucormycosis and aspergillosis is a rare and often fatal diagnosis. Few, if any, isolated cases have been reported in medical literature. This case with a complicated atypical presentation serves to highlight the importance of having a high suspicion for cerebral fungal infections and coinfections in immunocompromised patients as well as prompt intervention that is crucial to mitigate poor prognosis.

## CASE PRESENTATION

A patient in their 20s with a medical history of active intravenous polysubstance use was brought to the emergency department with altered mental status. On admission, vitals were within normal limits. The patient was somnolent and non-verbal but withdrawing all four extremities to noxious stimuli. The initial metabolic workup revealed normal blood glucose, thyroid-stimulating hormone and free T4, elevated creatine kinase (2860 IU/L), and newly found to be HIV positive with CD4 count 224 cells/MCL, 18%. Urine drug screen was positive for amphetamines and fentanyl. CT scan of the head did not show an acute intracranial abnormality. The patient soon developed seizure and left facial droop, with a temperature of 101.9°F (38.8°C), and became less responsive; as a result, the patient was transferred to intensive care unit.

MRI of the brain without contrast showed greater right than left basal ganglia diffusion restriction with

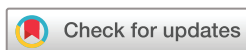surrounding oedema. Stroke workup, including CT angiography of head and neck, transthoracic echocardiogram and transoesophageal echocardiogram, was unremarkable. Continuous electroencephalogram showed diffuse background slowing but no seizures or epileptiform discharges.

Lumbar puncture was suggestive of inflammatory or infectious central nervous system disease (Red blood cell (RBC): 1400 x 10<sup>12</sup>/L, White blood cell (WBC): 240 x 10<sup>9</sup>/L, glucose 39 mg/dL, protein 128 mg/dL, herpes simplex virus 1/2 PCR negative). The patient was started on vancomycin, ceftriaxone and ampicillin for possible meningoencephalitis, in addition to clindamycin, leucovorin and pyrimethamine due to concern for toxoplasmosis.

MRI of the brain with and without contrast then showed areas of restricted diffusion in the bilateral basal ganglia and anterior left midbrain, a new lesion compared with previous MRI, which demonstrated non-specific peripheral enhancement, concerning for infection, neoplasm or less likely infarction ([figure 1](#)).

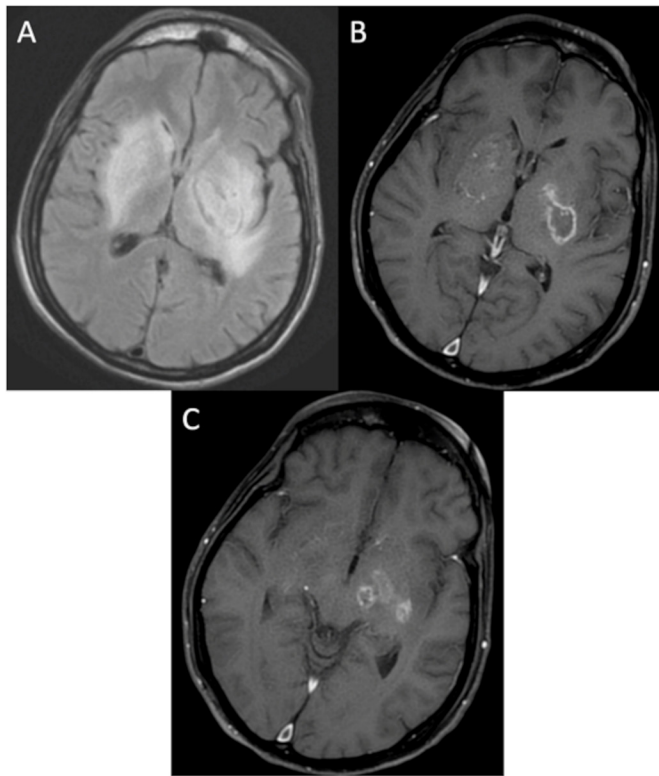
Cerebrospinal fluid (CSF) studies eventually returned negative for venereal disease research laboratory (VDRL) test, acid-fast bacillus (AFB) gram stain and culture, cryptococcal antigen, fungal culture, John Cunningham (JC) virus quant PCR, and toxoplasma IgG. Cytology showed numerous lymphocytes and cytometry showed no phenotypically abnormal cell population. IgG synthesis was elevated at 73.8 mg/dL and IgG index was elevated at 0.82. The patient also had negative serum IgG for toxoplasmosis. Given imaging, serum and CSF studies were not consistent with toxoplasmosis, all prior treatment regimen was discontinued, and empiric Bactrim was started, which led to slight improvement in mental status.

However, due to the patient's lack of progressive improvement after several days on Bactrim, the patient underwent stereotactic needle biopsy of the left basal ganglia. Frozen sections from biopsy showed aseptate, ribbon-like fungus with some right-angle and acute angle branching. The fungus was thinner than mucor but thicker than aspergillus fungus, but there was a greater concern for mucor over aspergillus ([figure 2](#)). Brain tissue fungal culture was negative. Pathology was sent to the University of Washington for panfungal PCR assay. CT Chest Abdomen Pelvis did not show evidence of disseminated systemic infection. The patient was then started on liposomal amphotericin. The infectious disease (ID) team suggested lesion debridement with neurosurgery, but it was determined to



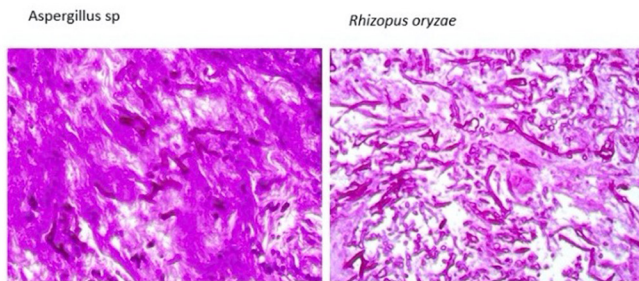
© BMJ Publishing Group Limited 2023. Re-use permitted under CC BY-NC. No commercial re-use. See rights and permissions. Published by BMJ.

**To cite:** Sun G, Weiss A, Zhao J, et al. *BMJ Case Rep* 2023;**16**:e255909. doi:10.1136/bcr-2023-255909



**Figure 1** (A) Axial T2 Fluid-attenuated inversion recovery (FLAIR), presence of a T2/FLAIR hyperintense lesion centred in the left basal ganglia measuring 3.4×2.3 cm transaxially extending into the adjacent white matter including the external and internal capsules, corona radiata and left cerebral peduncle/midbrain. (B, C) Axial T1 post contrast, presence of haemorrhagic peripherally enhancing, non-pyogenic lesions in both gangliocapsular regions extending into the left cerebral peduncle/midbrain with surrounding oedema.

be morbid, difficult and high risk. The PCR returned positive for both aspergillus and mucor species, isolated to the brain, so amphotericin was continued for 28 days and followed by isavuconazole. Additionally, dolutegravir and emtricitabine/tenofovir were started for highly active antiretroviral therapy.



**Figure 2** Pathology lab microscopic description: the fungal organisms are present in necrotic brain tissue and focally in brain tissue containing marked inflammatory infiltrates consisting of lymphocytes and multinucleated giant cell macrophages. No lymphoma is identified in the biopsy specimens and CD20 immunohistochemical stain is negative. The fungal hyphae are highlighted on periodic acid-Schiff (PAS) and Grocott methenamine silver (GMS) stains. Immunohistochemical stain for Ki67 shows positive staining of reactive inflammatory lymphocytes.

## OUTCOME AND FOLLOW-UP

The patient's mental status gradually improved in 2–3 weeks, although he continued to have intermittent agitation, for which he was started on clonidine and olanzapine. He was eventually alert and oriented to the person, and was evaluated by speech therapy and cleared to take tablets and capsules per oral prior to discharge to a skilled nursing facility. ID team recommended to continue isavuconazole (for 6–24 months, based on repeat imaging) and antiretroviral therapy. His mental status gradually improved, and he is now alert and oriented to person and place, and is able to communicate with family members, however, has limited ability to perform daily activities. He is scheduled to have outpatient neurology and ID follow-up and physical therapy/occupational therapy at home.

## DISCUSSION

Mucormycosis and aspergillosis are two invasive, opportunistic fungal infections that are clinically similar but rarely associated. Risk factors for invasive fungal infections include primary immunodeficiency, uncontrolled diabetes mellitus, intravenous drug use, HIV/AIDS and malnutrition.<sup>1–2</sup> Isolated cerebral mucormycosis is well described in people who inject drugs.<sup>1</sup> These infections are independently severe and often fatal.<sup>3</sup> Coinfection is associated with even poorer outcomes, and often correct diagnosis is not made until postmortem.<sup>4</sup>

This coinfection is commonly reported in patients with haematological malignancies or diabetes mellitus.<sup>5–7</sup> Both species are filamentous fungi that invade rapidly through tissue and disseminate early. They are ubiquitous in the environment, posing a threat to immunocompromised individuals. Contamination can occur through spore inhalation or percutaneous injection. Mucor infection can cause damage via angioinvasion and tissue necrosis.<sup>8</sup> Damage from aspergillus infection results from direct tissue invasion or from recruitment of inflammatory cells to sites of infection.<sup>9</sup>

This case report emphasises the importance of retaining a high index of suspicion for coinfection with mucor and aspergillus. The European Society of Clinical Microbiology and Infectious Diseases and European Confederation of Medical Mycology Joint Clinical Guidelines strongly recommend direct visualisation, culture and histopathology as the gold standard for diagnosis of both mucormycosis and aspergillosis, with histology showing right-angle, non-septate hyphae and 45°, septate hyphae, respectively.<sup>10–11</sup>

In our case, given the dual presentation of right-angle and acute angle branching, a comprehensive 18S rRNA gene sequence primer was used to confirm the diagnosis. As individual prognosis is driven by early treatment, guidelines stress the importance of early diagnosis in the implementation of intervention.<sup>10–12</sup> One study found that delay in medical treatment with amphotericin B resulted in a twofold increase in mortality rate at 12 weeks after diagnosis, compared with early treatment (82.9% vs 48.6%).<sup>12</sup>

Additionally, the importance of early imaging cannot be overstated. CT scan can provide an early screening tool, while MRI provides detection of the extent of infection, often deciding whether surgical debridement is an option. In our case, initial differential included stroke, but involvement of the basal ganglia on imaging and a lesion inconsistent with typical ischaemic stroke raised suspicion for infectious invasion. Additionally, earlier imaging may offer a window for surgical intervention before the spread of infection makes the intervention unfeasible.

A delay in diagnosis can be fatal, stressing the importance of early recognition and intervention. In patients with multiple risk factors, mucormycosis and aspergillosis infections should be on the list of differential diagnoses, even without the classic rhino-orbital invasion. This case contributes to greater awareness of presentation of disseminated fungal infections to help expedite identification and treatment of these pathologies.

### Learning points

- ▶ Mucormycosis and aspergillosis are two invasive, opportunistic fungal infections that are clinically similar but rarely associated. Risk factors for invasive fungal infections include primary immunodeficiency, uncontrolled diabetes mellitus, intravenous drug use, HIV/AIDS and malnutrition.
- ▶ These infections are independently severe and often fatal. Coinfection is associated with even poorer outcomes, and often correct diagnosis is not made until postmortem.
- ▶ The European Society of Clinical Microbiology and Infectious Diseases and European Confederation of Medical Mycology Joint Clinical Guidelines strongly recommend direct visualisation, culture and histopathology as the gold standard for diagnosis of both mucormycosis and aspergillosis.
- ▶ This case with a complicated atypical presentation serves to highlight the importance of having a high suspicion for cerebral fungal infections and coinfections in immunocompromised patients as well as prompt intervention that is crucial to mitigate poor prognosis.

**Contributors** The following authors were responsible for drafting of the text, sourcing and editing of clinical images, investigation results, drawing original diagrams and algorithms, and critical revision for important intellectual content: GS, AW, JZ, SD, MS and MD. The following author gave final approval of the manuscript: SD.

**Funding** The authors have not declared a specific grant for this research from any funding agency in the public, commercial or not-for-profit sectors.

**Competing interests** None declared.

**Patient consent for publication** Consent obtained from parent(s)/guardian(s).

**Provenance and peer review** Not commissioned; externally peer reviewed.

**Open access** This is an open access article distributed in accordance with the Creative Commons Attribution Non Commercial (CC BY-NC 4.0) license, which permits others to distribute, remix, adapt, build upon this work non-commercially, and license their derivative works on different terms, provided the original work is properly cited and the use is non-commercial. See: <http://creativecommons.org/licenses/by-nc/4.0/>.

Case reports provide a valuable learning resource for the scientific community and can indicate areas of interest for future research. They should not be used in isolation to guide treatment choices or public health policy.

### ORCID iDs

George Sun <http://orcid.org/0000-0002-2510-0943>

Sara Dehbashi <http://orcid.org/0000-0002-2336-0274>

### REFERENCES

- 1 Chermetz M, Gobbo M, Rupel K, *et al*. Combined orofacial Aspergillosis and Mucormycosis: fatal complication of a recurrent Paediatric glioma-case report and review of literature. *Mycopathologia* 2016;181:723–33.
- 2 Borjian Boroujeni Z, Shamsaei S, Yarahmadi M, *et al*. Distribution of invasive fungal infections: molecular epidemiology, etiology, clinical conditions, diagnosis and risk factors: a 3-year experience with 490 patients under intensive care. *Microb Pathog* 2021;152:104616.
- 3 Webb BJ, Ferraro JP, Rea S, *et al*. Epidemiology and clinical features of invasive fungal infection in a US health care network. *Open Forum Infect Dis* 2018;5:ofy187.
- 4 Mölle M, Blaschke-Hellmessen R, Schuler U, *et al*. Disseminated Aspergillosis and Mucormycosis. A case report. *Mycoses* 1996;39 Suppl 1:59–64.
- 5 Zayet S, Zaghdoudi A, Ammari L, *et al*. Cerebro-Rhino-orbital Mucormycosis and Aspergillosis Coinfection in a patient with diabetes mellitus: a case report. *IDCases* 2021;23.
- 6 Maiorano E, Favia G, Capodiferro S, *et al*. Combined Mucormycosis and Aspergillosis of the Oro-Sinonasal region in a patient affected by Castleman disease. *Virchows Arch* 2005;446:28–33.
- 7 Rit K, Saha R, Dey R, *et al*. Rhino-Oculo-cerebral Aspergillus and Mucor Coinfections in an immunocompromised patient with type 2 diabetes mellitus. *Med J DY Patil Univ* 2014;7:486.
- 8 Liu M, Spellberg B, Phan QT, *et al*. The endothelial cell receptor Grp78 is required for Mucormycosis pathogenesis in diabetic mice. *J Clin Invest* 2010;120:1914–24.
- 9 Hohl TM, Feldmesser M. Aspergillus Fumigatus: principles of pathogenesis and host defense. *Eukaryot Cell* 2007;6:1953–63.
- 10 Cornely OA, Arikan-Akdagli S, Dannaoui E, *et al*. ESCMID and ECMM joint clinical guidelines for the diagnosis and management of Mucormycosis 2013. *Clin Microbiol Infect* 2014;20 Suppl 3:5–26.
- 11 Ullmann AJ, Aguado JM, Arikan-Akdagli S, *et al*. Diagnosis and management of Aspergillus diseases: executive summary of the 2017 ESCMID-ECMM-ERS guideline. *Clin Microbiol Infect* 2018;24 Suppl 1:e1–38.
- 12 Chamilos G, Lewis RE, Kontoyiannis DP. Delaying amphotericin B-based frontline therapy significantly increases mortality among patients with hematologic malignancy who have Zygomycosis. *Clin Infect Dis* 2008;47:503–9.

Copyright 2023 BMJ Publishing Group. All rights reserved. For permission to reuse any of this content visit <https://www.bmj.com/company/products-services/rights-and-licensing/permissions/>  
BMJ Case Report Fellows may re-use this article for personal use and teaching without any further permission.

Become a Fellow of BMJ Case Reports today and you can:

- ▶ Submit as many cases as you like
- ▶ Enjoy fast sympathetic peer review and rapid publication of accepted articles
- ▶ Access all the published articles
- ▶ Re-use any of the published material for personal use and teaching without further permission

### Customer Service

If you have any further queries about your subscription, please contact our customer services team on +44 (0) 207111 1105 or via email at [support@bmj.com](mailto:support@bmj.com).

Visit [casereports.bmj.com](http://casereports.bmj.com) for more articles like this and to become a Fellow