

9-26-2021

Percutaneous coronary intervention of totally occluded coronary venous bypass grafts: An exercise in futility?

Evan Nardone
Thomas Jefferson University

Brandon M Madsen
Medstar Georgetown University Hospital

Melissa McCarey
Thomas Jefferson University

D L Fischman
Jefferson Medical College

Nicholas Ruggiero
Follow this and additional works at: <https://jdc.jefferson.edu/medfp>
Thomas Jefferson University

 Part of the [Anesthesiology Commons](#), and the [Cardiology Commons](#)

[Let us know how access to this document benefits you](#)

See next page for additional authors

Recommended Citation

Nardone, Evan; Madsen, Brandon M; McCarey, Melissa; Fischman, D L; Ruggiero, Nicholas; Walinsky, Paul; Vishnevsky, Alec; and Savage, Michael P., "Percutaneous coronary intervention of totally occluded coronary venous bypass grafts: An exercise in futility?" (2021). *Department of Medicine Faculty Papers*. Paper 313.

<https://jdc.jefferson.edu/medfp/313>

This Article is brought to you for free and open access by the Jefferson Digital Commons. The Jefferson Digital Commons is a service of Thomas Jefferson University's [Center for Teaching and Learning \(CTL\)](#). The Commons is a showcase for Jefferson books and journals, peer-reviewed scholarly publications, unique historical collections from the University archives, and teaching tools. The Jefferson Digital Commons allows researchers and interested readers anywhere in the world to learn about and keep up to date with Jefferson scholarship. This article has been accepted for inclusion in Department of Medicine Faculty Papers by an authorized administrator of the Jefferson Digital Commons. For more information, please contact: JeffersonDigitalCommons@jefferson.edu.

Authors

Evan Nardone, Brandon M Madsen, Melissa McCarey, D L Fischman, Nicholas Ruggiero, Paul Walinsky, Alec Vishnevsky, and Michael P. Savage

World Journal of *Cardiology*

World J Cardiol 2021 September 26; 13(9): 381-525



REVIEW

- 381 Quantifying tissue perfusion after peripheral endovascular procedures: Novel tissue perfusion endpoints to improve outcomes
Arkoudis NA, Katsanos K, Inchingolo R, Paraskevopoulos I, Mariappan M, Spiliopoulos S
- 399 Exercise-mediated adaptations in vascular function and structure: Beneficial effects in coronary artery disease
Sakellariou XM, Papafaklis MI, Domouzoglou EM, Katsouras CS, Michalis LK, Naka KK
- 416 Stent visualization methods to guide percutaneous coronary interventions and assess long-term patency
Ghafari C, Carlier S

MINIREVIEWS

- 438 Interpersonal violence: Serious sequelae for heart disease in women
Mazza M, Marano G, Gonzalez del Castillo A, Chieffo D, Albano G, Biondi-Zoccai G, Galiuto L, Sani G, Romagnoli E
- 446 Coronary artery aneurysm: A review
Matta AG, Yaacoub N, Nader V, Moussallem N, Carrie D, Roncalli J
- 456 Coronary vasospasm: A narrative review
Jewulski J, Khanal S, Dahal K
- 464 Sodium glucose cotransporter 2 inhibitors: New horizon of the heart failure pharmacotherapy
Naito R, Kasai T
- 472 Intensive lipid-lowering therapy, time to think beyond low-density lipoprotein cholesterol
Abdalwahab A, Al-atta A, Zaman A, Alkhalil M

ORIGINAL ARTICLE**Retrospective Study**

- 483 Patients' time in therapeutic range on warfarin among atrial fibrillation patients in Warfarin Medication Therapy Adherence Clinic
Lee SL, Ong TJ, Mazlan-Kepli W, Mageswaran A, Tan KH, Abd-Malek AM, Cronshaw R
- 493 Percutaneous coronary intervention of totally occluded coronary venous bypass grafts: An exercise in futility?
Nardone EW, Madsen BM, McCarey MM, Fischman DL, Ruggiero NJ, Walinsky P, Vishnevsky A, Savage MP

Prospective Study

- 503** Red blood cell distribution width in elderly hospitalized patients with cardiovascular disease
Xanthopoulos A, Tryposkiadis K, Dimos A, Bourazana A, Zagouras A, Iakovis N, Papamichalis M, Giamouzis G, Vassilopoulos G, Skoularigis J, Triposkiadis F
- 514** Effects of exercise training on diastolic and systolic dysfunction in patients with chronic heart failure
Chaveles I, Papazachou O, Shamari MA, Delis D, Ntalianis A, Panagopoulou N, Nanas S, Karatzanos E

ABOUT COVER

Editorial Board Member of *World Journal of Cardiology*, Stavros Dimopoulos, PhD, Doctor, Postdoc, Research Scientist, Senior Researcher, Staff Physician, Cardiac Surgery ICU, Onassis Cardiac Surgery Center, Athens 17674, Greece. stdimop@gmail.com

AIMS AND SCOPE

The primary aim of *World Journal of Cardiology (WJC, World J Cardiol)* is to provide scholars and readers from various fields of cardiology with a platform to publish high-quality basic and clinical research articles and communicate their research findings online.

WJC mainly publishes articles reporting research results and findings obtained in the field of cardiology and covering a wide range of topics including acute coronary syndromes, aneurysm, angina, arrhythmias, atherosclerosis, atrial fibrillation, cardiomyopathy, congenital heart disease, coronary artery disease, heart failure, hypertension, imaging, infection, myocardial infarction, pathology, peripheral vessels, public health, Raynaud's syndrome, stroke, thrombosis, and valvular disease.

INDEXING/ABSTRACTING

The WJC is now abstracted and indexed in Emerging Sources Citation Index (Web of Science), PubMed, PubMed Central, Scopus, China National Knowledge Infrastructure (CNKI), China Science and Technology Journal Database (CSTJ), and Superstar Journals Database. The 2021 edition of Journal Citation Reports® cites the 2020 Journal Citation Indicator (JCI) for WJC as 0.36. The WJC's CiteScore for 2020 is 0.3, and Scopus CiteScore rank 2020: Cardiology and Cardiovascular Medicine is 289/317.

RESPONSIBLE EDITORS FOR THIS ISSUE

Production Editor: Lin-YuTong Wang; Production Department Director: Xiang Li; Editorial Office Director: Ya-Juan Ma.

NAME OF JOURNAL

World Journal of Cardiology

ISSN

ISSN 1949-8462 (online)

LAUNCH DATE

December 31, 2009

FREQUENCY

Monthly

EDITORS-IN-CHIEF

Ramdas G Pai, Dimitrios Tousoulis, Marco Matteo Ciccone

EDITORIAL BOARD MEMBERS

<https://www.wjgnet.com/1949-8462/editorialboard.htm>

PUBLICATION DATE

September 26, 2021

COPYRIGHT

© 2021 Baishideng Publishing Group Inc

INSTRUCTIONS TO AUTHORS

<https://www.wjgnet.com/bpg/gerinfo/204>

GUIDELINES FOR ETHICS DOCUMENTS

<https://www.wjgnet.com/bpg/GerInfo/287>

GUIDELINES FOR NON-NATIVE SPEAKERS OF ENGLISH

<https://www.wjgnet.com/bpg/gerinfo/240>

PUBLICATION ETHICS

<https://www.wjgnet.com/bpg/GerInfo/288>

PUBLICATION MISCONDUCT

<https://www.wjgnet.com/bpg/gerinfo/208>

ARTICLE PROCESSING CHARGE

<https://www.wjgnet.com/bpg/gerinfo/242>

STEPS FOR SUBMITTING MANUSCRIPTS

<https://www.wjgnet.com/bpg/GerInfo/239>

ONLINE SUBMISSION

<https://www.f6publishing.com>

Retrospective Study

Percutaneous coronary intervention of totally occluded coronary venous bypass grafts: An exercise in futility?

Evan W Nardone, Brandon M Madsen, Melissa M McCarey, David L Fischman, Nicholas J Ruggiero, Paul Walinsky, Alec Vishnevsky, Michael P Savage

ORCID number: Evan W Nardone 0000-0003-0265-3619; Brandon M Madsen 0000-0002-2366-8359; Melissa M McCarey 0000-0002-5094-3600; David L Fischman 0000-0001-9711-7616; Nicholas J Ruggiero 0000-0002-3231-5600; Paul Walinsky 0000-0002-4841-8938; Alec Vishnevsky 0000-0002-9096-2988; Michael P Savage 0000-0002-5259-1178.

Author contributions: Savage MP, Nardone EW, Madsen BM, Fischman DL and McCarey MM contributed to the design of the research study; Savage MP, Fischman DL, Walinsky P, Ruggiero NJ, and Vishnevsky A acquired the data and conducted the procedures. Nardone EW, Madsen BM, Savage MP and Melissa McCarey performed the research. Savage MP, Nardone EW, Melissa McCarey, Fischman DL, Madsen BM, Ruggiero NJ, Walinsky P, and Vishnevsky A analyzed the data and wrote or revised the manuscript; all authors read and approve the final manuscript.

Institutional review board

statement: The retrospective saphenous vein graft study was approved by the IRB at Thomas Jefferson University.

Informed consent statement: This

Evan W Nardone, David L Fischman, Nicholas J Ruggiero, Paul Walinsky, Alec Vishnevsky, Michael P Savage, Department of Medicine, Thomas Jefferson University, Philadelphia, PA 19107, United States

Brandon M Madsen, Department of Anesthesiology, Medstar Georgetown University Hospital, Washington, DC 20007, United States

Melissa M McCarey, Jefferson Clinical Research Institute, Thomas Jefferson University, Philadelphia, PA 19107, United States

Corresponding author: Michael P Savage, FACC, FACP, MD, Director, Professor, Department of Medicine, Thomas Jefferson University, 111 South 11th Street, Philadelphia, PA 19107, United States. michael.savage@jefferson.edu

Abstract**BACKGROUND**

Percutaneous coronary intervention (PCI) of diseased saphenous vein grafts (SVG) continues to pose a clinical challenge. Current PCI guidelines give a class III recommendation against performing PCI on chronically occluded SVG. However, contemporary outcomes after SVG intervention have incrementally improved with distal protection devices, intracoronary vasodilators, drug-eluting stents, and prolonged dual antiplatelet therapy.

AIM

To reassess the procedural and long-term outcomes of PCI for totally occluded SVG with contemporary techniques.

METHODS

This was a retrospective observational study conducted at a single university hospital. The study population consisted of 35 consecutive patients undergoing PCI of totally occluded SVG. Post-procedure dual antiplatelet therapy was continued for a minimum of one year and aspirin was continued indefinitely. Clinical outcomes were assessed at a mean follow-up of 1221 ± 1038 d. The primary outcome was freedom from a major adverse cardiac event (MACE) defined as the occurrence of any of the following: death, myocardial infarction, stroke, repeat bypass surgery, repeat PCI, or graft reocclusion.

was a retrospective study which did not require written consent.

Conflict-of-interest statement: All authors have no conflicts of interest.

Data sharing statement: Technical appendix, statistical code, and dataset available from the corresponding author at michael.savage@jefferson.edu.

Consent was not obtained but the presented data are anonymized and risk of identification is low.

Open-Access: This article is an open-access article that was selected by an in-house editor and fully peer-reviewed by external reviewers. It is distributed in accordance with the Creative Commons Attribution NonCommercial (CC BY-NC 4.0) license, which permits others to distribute, remix, adapt, build upon this work non-commercially, and license their derivative works on different terms, provided the original work is properly cited and the use is non-commercial. See: <http://creativecommons.org/licenses/by-nc/4.0/>

Manuscript source: Invited manuscript

Specialty type: Cardiac and cardiovascular systems

Country/Territory of origin: United States

Peer-review report's scientific quality classification

Grade A (Excellent): 0
Grade B (Very good): 0
Grade C (Good): C
Grade D (Fair): 0
Grade E (Poor): 0

Received: March 23, 2021

Peer-review started: March 24, 2021

First decision: May 5, 2021

Revised: May 27, 2021

Accepted: July 27, 2021

Article in press: July 27, 2021

Published online: September 26, 2021

P-Reviewer: Vermeersch P

S-Editor: Ma YJ

RESULTS

The study group included 29 men and 6 women with a mean age of 69 ± 12 years. Diabetes was present in 14 (40%) patients. All patients had Canadian Heart Classification class III or IV angina. Clinical presentation was an acute coronary syndrome in 34 (97%) patients. Mean SVG age was 12 ± 5 years. Estimated duration of occlusion was acute (< 24 h) in 34% of patients, subacute (> 24 h to 30 d) in 26%, and late (> 30 d) in 40%. PCI was initially successful in 29/35 SVG occlusions (83%). Total stent length was 52 ± 35 mm. Intraprocedural complications of distal embolization or no-reflow occurred in 6 (17%) patients. During longer term follow-up, MACE-free survival was only 30% at 3 years and 17% at 5 years.

CONCLUSION

PCI of totally occluded SVG can be performed with a high procedural success rate. However, its clinical utility remains limited by poor follow-up outcomes.

Key Words: Coronary artery bypass grafting; Coronary stents; Chronic total occlusion; Percutaneous coronary intervention; Restenosis; Saphenous vein grafts

©The Author(s) 2021. Published by Baishideng Publishing Group Inc. All rights reserved.

Core Tip: Cardiovascular guidelines give a Class III recommendation against performing percutaneous coronary intervention (PCI) on chronically occluded saphenous vein grafts (SVG). Given contemporary advances in SVG intervention, the goal of this study was to reassess the outcomes of PCI for totally occluded SVG in 35 consecutive patients. PCI was initially successful in 29/35 (83%) SVG occlusions. However, at 3 years only 30% of patients survived without a major cardiac event. Although PCI of totally occluded SVG can be performed with a high procedural success rate, its clinical utility remains limited by poor follow-up outcomes.

Citation: Nardone EW, Madsen BM, McCarey MM, Fischman DL, Ruggiero NJ, Walinsky P, Vishnevsky A, Savage MP. Percutaneous coronary intervention of totally occluded coronary venous bypass grafts: An exercise in futility? *World J Cardiol* 2021; 13(9): 493-502

URL: <https://www.wjnet.com/1949-8462/full/v13/i9/493.htm>

DOI: <https://dx.doi.org/10.4330/wjc.v13.i9.493>

INTRODUCTION

Percutaneous coronary intervention (PCI) of diseased saphenous vein grafts (SVG) continues to be a clinical challenge[1-4]. According to present cardiovascular guidelines, PCI of SVG with chronic total occlusions is discouraged and given a class III recommendation[5]. However, outcomes after SVG intervention have incrementally improved with distal protection devices, intracoronary vasodilators, drug-eluting stents, and prolonged dual antiplatelet therapy (DAPT). The goal of this study was to reassess the procedural and long-term outcomes of PCI for totally occluded SVG in contemporary practice.

MATERIALS AND METHODS

A review of medical records and coronary angiographic films was performed to identify patients with PCI performed on totally occluded SVG. This retrospective study was approved by the Institutional Review Board of the Thomas Jefferson University Hospital. All patients had a 100% occlusion of a venous bypass graft with Thrombolysis In Myocardial Infarction (TIMI) 0 or 1 flow. Patients with subtotal occlusions and TIMI 2 or 3 flow were excluded. PCI of occluded arterial bypass grafts were also excluded.

L-Editor: A
P-Editor: Li JH



Detailed procedural information was collected on the type of anticoagulation, use of thrombectomy and distal protection device, the number of stents implanted, total stent length, and type of stent. Procedural success was defined as restored SVG patency with > TIMI 2 flow and < 20% residual stenosis. Post-discharge, all patients with successful PCI were treated with dual antiplatelet therapy (DAPT) for at least 1 year and aspirin indefinitely.

The primary outcome was freedom from a major adverse cardiac event (MACE) during a mean follow-up period of 1121 ± 1038 d. MACE was defined as the occurrence of any of the following: Death, myocardial infarction (MI), stroke, repeat bypass surgery, repeat PCI of the target vessel, or graft reocclusion. Event rates were determined by Kaplan-Meier analysis. Event free survival was also assessed as a function of the duration of SVG occlusion classified as acute (< 24 h), subacute (> 24 h to 30 days), or late (> 30 d). Duration of occlusion was estimated on the basis of the patient's history of symptom onset. Subgroup analyses were performed based on the duration of occlusion, clinical presentation, and stent type. Fisher's exact test was used to evaluate the relationship of duration of occlusion and clinical presentation with initial clinical success. Between group comparison of the survival curves was performed using the Mantel-Cox log rank test. *P* values < 0.05 were considered significant. Descriptive statistics were used to analyze baseline patient and bypass graft characteristics. Continuous variables are reported as mean \pm SD.

RESULTS

Baseline characteristics of the patients are presented in [Table 1](#). The study population consisted of 29 men and 6 women. Mean age was 69 ± 12 years. Diabetes was present in 40% of patients. Twenty patients (57%) had a history of prior MI. Mean left ventricular ejection fraction was $43\% \pm 12\%$. All patients had Canadian Heart Classification III or IV angina. Clinical presentation included ST-elevation MI (STEMI) in 6 patients (17%), non-STEMI in 14 patients (40%), unstable angina in 14 patients (40%), and stable angina in 1 patient (3%).

Bypass graft characteristics are shown in [Table 2](#). Mean SVG age was 12.1 ± 5.1 years. The grafted native coronary artery was the left anterior descending in 9 patients (26%), left circumflex in 13 patients (37%), right coronary artery in 10 patients (29%), and multiple vessels in 3 patients (9%). Previous PCI had been performed in 10 (29%) of the SVG. The duration of graft occlusion was acute in 12 (34%), subacute in 9 (26%), and late in 14 (40%).

Procedural features and outcomes are presented in [Table 3](#). Glycoprotein IIb/IIIa inhibitors were used in 15 (43%) of cases. Thrombectomy was performed in 20 (57%). Distal protection devices were used in 9 (26%). The mean number of stents implanted was 2.1 ± 1.3 and total stent length was 52 ± 35 mm. Drug-eluting stents were used in the majority of patients.

Procedural success in restoring SVG patency was achieved in 29 of the 35 patients (83%). Of the 6 unsuccessful procedures, 2 were due to the failure to cross through the occluded graft with any guidewire; in the remaining 4 cases, successful guidewire passage to the distal native vessel was accomplished but graft patency could not be restored despite balloon angioplasty and thrombectomy. Procedural success was not correlated with either clinical presentation ($P = 0.99$) or duration of graft occlusion ($P = 0.33$). Procedural complications included distal embolization or no-reflow in 6 (17%) patients. There were no instances of coronary perforation. In-hospital MACE occurred in 3 (9%) patients including 2 deaths and one nonfatal MI.

Follow-up event free survival is shown in [Figure 1](#). MACE free survival was 58% at 1 year, 30% at 3 years, and 17% at 5 years. Distribution of specific MACE events during follow up is shown in [Table 4](#). Longer term outcome was not related to the initial duration of SVG occlusion ([Figure 2](#)) ($P = 0.60$) or clinical presentation ($P = 0.87$). There was no difference in MACE free survival for patients with drug-eluting stents compared to bare metal stents ($P = 0.97$).

DISCUSSION

The management of patients who develop bypass graft disease after previous coronary artery bypass grafting (CABG) surgery continue to pose a clinical challenge. For post-CABG patients with unstable or medically refractory symptoms, all revascularization options entail heightened complexity and procedural risk. Redo CABG carries an

Table 1 Patient characteristics

Characteristic	n = 35
Men	29 (83%)
Age (mean ± SD)	69 ± 12 yr
Hypertension	33 (94%)
Hyperlipidemia	25 (71%)
Diabetes	14 (40%)
Smoking	14 (40%)
Renal insufficiency	14 (40%)
History of CHF	6 (17%)
Prior MI	20 (57%)
Ejection fraction (mean ± SD)	43% ± 12%
Clinical presentation	
STEMI	6 (17%)
NSTEMI	14 (40%)
Unstable angina	14 (40%)
Stable angina	1 (3%)
Canadian heart class	
I, II	0
III	7 (20%)
IV	28 (80%)

CHF: Congestive heart failure; MI: Myocardial infarction; NSTEMI: Non-ST elevation myocardial infarction; SD: Standard deviation; STEMI: ST elevation myocardial infarction.

increased risk of morbidity and mortality compared to the initial operation[6,7]. The outcomes of PCI in SVG have been significantly improved by coronary stenting[8]. Nevertheless, compared to native coronary arteries, PCI of SVG continues to be associated with higher risk of both procedural and long-term adverse events[9]. Accordingly, if revascularization is indicated in the presence of SVG disease, it is generally preferable to intervene on the native coronary artery if technically feasible. On the other hand, native coronary arteries long after bypass surgery often have complex, heavily calcified chronic total occlusions (CTO) which result in a significantly augmented risk of PCI failure and major complications[10-12].

Historically, before the introduction of distal protection devices and drug-eluting stents, PCI of totally occluded SVG has been associated with low initial procedural success, a high rate of complications, and frequent follow-up adverse events[13,14]. More contemporary PCI studies of SVG in the setting of acute thrombosis and STEMI while demonstrating improved procedural success still report poor longer term clinical outcomes[15,16]. A few studies have evaluated the outcome of PCI in chronically occluded SVG in the DES era[17-20]. An early small study of 11 patients with chronically occluded SVG suggested a high procedural success rate and favorable longer term outcomes after PCI[17]. Subsequent studies of chronically occluded SVG involving 22 to 34 patients reported PCI procedural success in 68% to 79% of cases with relatively high rates of MACE during medium term follow-up[18-20].

Citing low success rates, high complication rates, and poor long-term patency, ACC/AHA/SCAI PCI guidelines have a Class III: Harm recommendation against PCI for chronic SVG occlusions[5]. However, it is important to note that these guidelines were published over a decade ago. Accordingly, the unanswered question is whether the cumulative advances in SVG intervention have translated into improved outcome for totally occluded grafts. Distal protection devices have been shown to reduce periprocedural MACE, can be deployed with high success rate, and are given a Class I recommendation in PCI guidelines[5,21-23]. Intracoronary vasodilators have been shown to be effective in treating no-reflow which is a common complication during

Table 2 Bypass graft characteristics

Characteristic	n (%)
SVG age (mean ± SD)	12.1 ± 5.1 yr
Prior PCI of SVG	10 (29)
Grafted native vessel	
LAD	9 (26)
LCx	13 (37)
RCA	10 (29)
Multiple	3 (9)
Duration of graft occlusion	
Acute (< 24 h)	12 (34)
Subacute (> 24 h to 30 d)	9 (26)
Late (> 30 d)	14 (40)

LAD: Left anterior descending; LCx: Left circumflex; m: mean; PCI: Percutaneous coronary intervention; SD: standard deviation; SVG: Saphenous vein graft.

SVG PCI and may have benefits if given prophylactically[24-27]. Drug-eluting stents appear to reduce restenosis in SVG early after PCI although they exhibit a catch-up phenomenon during late follow-up[28-31]. Prolonged DAPT improves outcomes following PCI in high risk patient subsets and has been suggested as a possible strategy to improve the long-term outcome after PCI of SVG[4,32,33]. In addition to these advances in SVG intervention, significant improvements in CTO outcomes have been made through continued technical and procedural innovations[34,35].

Given the aforementioned advances, the goal of the current study was to reassess the procedural and long-term outcomes of occluded SVG PCI in the context of contemporary techniques. The initial procedural success in restoring SVG patency was achieved in 83% of patients. This procedural success rate is quite favorable compared to prior reports of totally occluded SVG. On the other hand, long-term clinical outcomes remained poor even though DAPT was continued for a minimum of one year and DES were used in most patients. MACE free survival was 58% at 1 year, 30% at 3 years, and only 17% at 5 years. There was no relation between the duration of SVG occlusion prior to PCI and long-term outcome. There was also no difference in outcome with drug-eluting compared to bare metal stents. The disappointing long-term results of DES in occluded SVG is consistent with the findings of other recent studies of DES for non-occluded SVG[29-31].

Limitations of the current study should be recognized. This study was retrospective and we do not have information into why PCI of the occluded vein graft was undertaken as opposed to other treatment options. Data is not available on the number of patients who were treated by other means such as PCI of the native vessel, redo CABG, or medical therapy alone. Patients in this study who underwent PCI likely represent a small select group with totally occluded SVG. These patients were treated in the drug-eluting stent era which now spans over the past decade and a half; the study population of this report represents less than 1% of patients undergoing PCI at our institution during this time. Accordingly, the outcomes of these patients could have been affected by the selection bias of the operators.

CONCLUSION

PCI of totally occluded SVG can be performed with a relatively high rate of procedural success. However, the vast majority of patients will experience a major clinical event within a few years following the procedure. Therefore, the clinical utility of PCI for totally occluded SVG continues to be limited due to poor long-term outcome.

Table 3 Procedural features and outcomes

Feature	n (%)
Anticoagulation	
Heparin only	12 (34)
Bivalirudin	8 (23)
Heparin + GP IIb IIIa inhibitor	15 (43)
Thrombectomy	20 (57)
Distal protection device	9 (26)
Number of stents (mean ± SD)	2.1 ± 1.3
Total stent length (mean ± SD)	52 ± 35 mm
Stent type	
Drug-eluting	19 (55)
Bare metal	11 (31)
None	5 (14)
Procedural outcome	
Success	29 (83)
Failed	6 (17)
Procedural complications	
Distal embolization	1 (3)
No reflow	5 (15)
In-hospital MACE	
Death	2 (5.7)
Myocardial infarction	1 (2.9)
Stroke	0
Repeat PCI or CABG	0
Any MACE	3 (8.6)

CABG: Coronary artery bypass grafting; GP: Glycoprotein; m: mean; MACE: Major adverse cardiac event; SD: Standard deviation.

Table 4 Follow-up major adverse cardiac event

MACE type	n (%)
Death	5 (14)
Stroke	1 (3)
MI	15 (43)
Repeat bypass surgery	0
Repeat PCI	6 (17)
Graft reocclusionAny MACE	7 (20) 28 (80)

MACE: Major adverse cardiac event; MI: Myocardial infarction; PCI: Percutaneous coronary intervention.

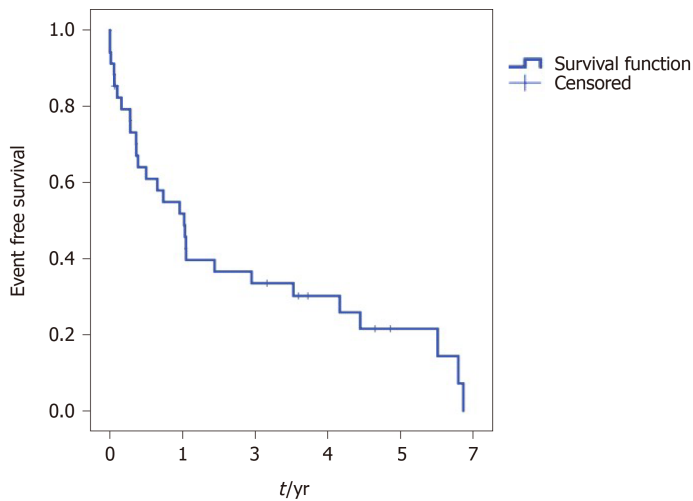


Figure 1 Major adverse cardiac event free survival after percutaneous coronary intervention of totally occluded saphenous vein grafts.

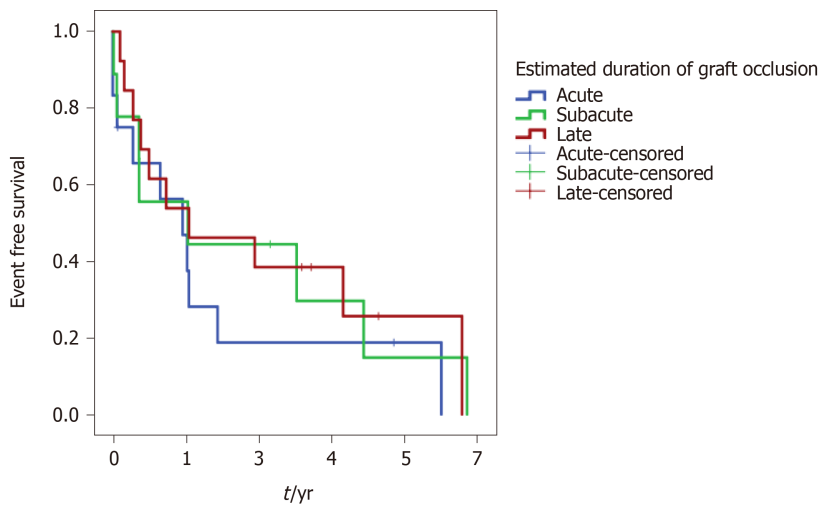


Figure 2 Duration of occlusion and major adverse cardiac event free survival.

ARTICLE HIGHLIGHTS

Research background

Percutaneous coronary intervention (PCI) of diseased saphenous vein grafts (SVG) continues to pose a clinical challenge. Given low success rates, high complication rates, and poor long term patency, current cardiovascular guidelines have a class III recommendation against PCI for chronically occluded SVG.

Research motivation

Contemporary outcomes of SVG intervention have incrementally improved with distal protection devices, intracoronary vasodilators, drug-eluting stents, and prolonged dual antiplatelet therapy. There is a paucity of studies on the outcome of PCI for totally occluded SVG using current techniques.

Research objectives

The goal of this study was to reassess the procedural and long term outcome of PCI for totally occluded SVG with contemporary techniques in the drug-eluting stent era.

Research methods

This was a retrospective observational study of 35 consecutive patients undergoing PCI of totally occluded SVG. The primary outcome was freedom from a major adverse cardiac event (MACE) defined as any of the following: Death, myocardial infarction,

stroke, repeat revascularization of the target vessel, or graft reocclusion. Mean follow-up was 1221 ± 1038 d.

Research results

The study group included 29 men and 6 women aged 69 ± 12 years. Mean SVG age was 12 ± 5 years. PCI was initially successful in 29/35 (83%) SVG occlusions. During long term follow-up, MACE-free survival was 30% at 3 years and 17% at 5 years.

Research conclusions

PCI of totally occluded SVG can be performed with a relatively high rate of procedural success. However, the vast majority of patients have a major clinical event within a few years following the procedure. Thus, the clinical utility of PCI for totally occluded SVG continues to be limited by poor long term outcomes.

Research perspectives

Although PCI of totally occluded SVG can be often initially accomplished, the long term clinical outcome remains poor. Future research is required to achieve a more sustained clinical benefit through further innovations in stent design and adjunct pharmacology.

ACKNOWLEDGEMENTS

The authors thank Scott Keith PhD, a biostatistician at the Thomas Jefferson University, for performing a statistical review.

REFERENCES

- 1 **Rodriguez MA**, Fischman DL, Savage MP. Advances in vein graft intervention. *Intervention Cardiol* 2010; **2**: 735-754 [DOI: [10.2217/ica.10.66](https://doi.org/10.2217/ica.10.66)]
- 2 **Lee MS**, Park SJ, Kandzari DE, Kirtane AJ, Fearon WF, Brilakis ES, Vermeersch P, Kim YH, Waksman R, Mehilli J, Mauri L, Stone GW. Saphenous vein graft intervention. *JACC Cardiovasc Interv* 2011; **4**: 831-843 [PMID: [21851895](https://pubmed.ncbi.nlm.nih.gov/21851895/) DOI: [10.1016/j.jcin.2011.05.014](https://doi.org/10.1016/j.jcin.2011.05.014)]
- 3 **Marmagkiolis K**, Grines C, Bilodeau L. Current percutaneous treatment strategies for saphenous vein graft disease. *Catheter Cardiovasc Interv* 2013; **82**: 406-413 [PMID: [22777812](https://pubmed.ncbi.nlm.nih.gov/22777812/) DOI: [10.1002/ccd.24554](https://doi.org/10.1002/ccd.24554)]
- 4 **Redfors B**, Génèreux P, Witzenbichler B, McAndrew T, Diamond J, Huang X, Maehara A, Weisz G, Mehran R, Kirtane AJ, Stone GW. Percutaneous Coronary Intervention of Saphenous Vein Graft. *Circ Cardiovasc Interv* 2017; **10** [PMID: [28495896](https://pubmed.ncbi.nlm.nih.gov/28495896/) DOI: [10.1161/CIRCINTERVENTIONS.117.004953](https://doi.org/10.1161/CIRCINTERVENTIONS.117.004953)]
- 5 **Levine GN**, Bates ER, Blankenship JC, Bailey SR, Bittl JA, Cercek B, Chambers CE, Ellis SG, Guyton RA, Hollenberg SM, Khot UN, Lange RA, Mauri L, Mehran R, Moussa ID, Mukherjee D, Nallamothu BK, Ting HH; American College of Cardiology Foundation; American Heart Association Task Force on Practice Guidelines; Society for Cardiovascular Angiography and Interventions. 2011 ACCF/AHA/SCAI Guideline for Percutaneous Coronary Intervention. A report of the American College of Cardiology Foundation/American Heart Association Task Force on Practice Guidelines and the Society for Cardiovascular Angiography and Interventions. *J Am Coll Cardiol* 2011; **58**: e44-122 [PMID: [22070834](https://pubmed.ncbi.nlm.nih.gov/22070834/) DOI: [10.1016/j.jacc.2011.08.007](https://doi.org/10.1016/j.jacc.2011.08.007)]
- 6 **Loop FD**, Lytle BW, Cosgrove DM, Woods EL, Stewart RW, Golding LA, Goormastic M, Taylor PC. Reoperation for coronary atherosclerosis. Changing practice in 2509 consecutive patients. *Ann Surg* 1990; **212**: 378-85; discussion 385 [PMID: [2396889](https://pubmed.ncbi.nlm.nih.gov/2396889/) DOI: [10.1097/0000658-199009000-00016](https://doi.org/10.1097/0000658-199009000-00016)]
- 7 **Fitzgibbon GM**, Kafka HP, Leach AJ, Keon WJ, Hooper GD, Burton JR. Coronary bypass graft fate and patient outcome: angiographic follow-up of 5,065 grafts related to survival and reoperation in 1,388 patients during 25 years. *J Am Coll Cardiol* 1996; **28**: 616-626 [PMID: [8772748](https://pubmed.ncbi.nlm.nih.gov/8772748/) DOI: [10.1016/0735-1097\(96\)00206-9](https://doi.org/10.1016/0735-1097(96)00206-9)]
- 8 **Savage MP**, Douglas JS Jr, Fischman DL, Pepine CJ, King SB 3rd, Werner JA, Bailey SR, Overlie PA, Fenton SH, Brinker JA, Leon MB, Goldberg S. Stent placement compared with balloon angioplasty for obstructed coronary bypass grafts. Saphenous Vein De Novo Trial Investigators. *N Engl J Med* 1997; **337**: 740-747 [PMID: [9287229](https://pubmed.ncbi.nlm.nih.gov/9287229/) DOI: [10.1056/NEJM199709113371103](https://doi.org/10.1056/NEJM199709113371103)]
- 9 **Brilakis ES**, O'Donnell CI, Penny W, Armstrong EJ, Tsai T, Maddox TM, Plomondon ME, Banerjee S, Rao SV, Garcia S, Nallamothu B, Shunk KA, Mavromatis K, Grunwald GK, Bhatt DL. Percutaneous Coronary Intervention in Native Coronary Arteries Versus Bypass Grafts in Patients With Prior Coronary Artery Bypass Graft Surgery: Insights From the Veterans Affairs Clinical Assessment, Reporting, and Tracking Program. *JACC Cardiovasc Interv* 2016; **9**: 884-893 [PMID: [26888888](https://pubmed.ncbi.nlm.nih.gov/26888888/) DOI: [10.1016/j.jcin.2016.05.014](https://doi.org/10.1016/j.jcin.2016.05.014)]

- 27085582 DOI: [10.1016/j.jcin.2016.01.034](https://doi.org/10.1016/j.jcin.2016.01.034)]
- 10 **Liu MJ**, Chen CF, Gao XF, Liu XH, Xu YZ. In-hospital outcomes of chronic total occlusion percutaneous coronary intervention in patients with and without prior coronary artery bypass graft: A protocol for systematic review and meta analysis. *Medicine (Baltimore)* 2020; **99**: e19977 [PMID: [32501965](https://pubmed.ncbi.nlm.nih.gov/32501965/) DOI: [10.1097/MD.00000000000019977](https://doi.org/10.1097/MD.00000000000019977)]
 - 11 **Megaly M**, Abraham B, Pershad A, Rinfret S, Alaswad K, Garcia S, Azzalini L, Gershlick A, Burke MN, Brilakis ES. Outcomes of Chronic Total Occlusion Percutaneous Coronary Intervention in Patients With Prior Bypass Surgery. *JACC Cardiovasc Interv* 2020; **13**: 900-902 [PMID: [32192982](https://pubmed.ncbi.nlm.nih.gov/32192982/) DOI: [10.1016/j.jcin.2019.11.033](https://doi.org/10.1016/j.jcin.2019.11.033)]
 - 12 **Shoab A**, Johnson TW, Banning A, Ludman P, Rashid M, Potts J, Kwok CS, Kontopantelis E, Azam ZA, Kinnaird T, Mamas MA. Clinical Outcomes of Percutaneous Coronary Intervention for Chronic Total Occlusion in Native Coronary Arteries vs Saphenous Vein Grafts. *J Invasive Cardiol* 2020; **32**: 350-357 [PMID: [32771995](https://pubmed.ncbi.nlm.nih.gov/32771995/)]
 - 13 **de Feyter PJ**, Serruys P, van den Brand M, Meester H, Beatt K, Suryapranata H. Percutaneous transluminal angioplasty of a totally occluded venous bypass graft: a challenge that should be resisted. *Am J Cardiol* 1989; **64**: 88-90 [PMID: [2525867](https://pubmed.ncbi.nlm.nih.gov/2525867/) DOI: [10.1016/0002-9149\(89\)90658-9](https://doi.org/10.1016/0002-9149(89)90658-9)]
 - 14 **Berger PB**, Bell MR, Grill DE, Simari R, Reeder G, Holmes DR Jr. Influence of procedural success on immediate and long-term clinical outcome of patients undergoing percutaneous revascularization of occluded coronary artery bypass vein grafts. *J Am Coll Cardiol* 1996; **28**: 1732-1737 [PMID: [8962559](https://pubmed.ncbi.nlm.nih.gov/8962559/) DOI: [10.1016/s0735-1097\(96\)00414-7](https://doi.org/10.1016/s0735-1097(96)00414-7)]
 - 15 **Abdel-Karim AR**, Banerjee S, Brilakis ES. Percutaneous intervention of acutely occluded saphenous vein grafts: contemporary techniques and outcomes. *J Invasive Cardiol* 2010; **22**: 253-257 [PMID: [20516502](https://pubmed.ncbi.nlm.nih.gov/20516502/) DOI: [10.1016/S0735-1097\(10\)61765-2](https://doi.org/10.1016/S0735-1097(10)61765-2)]
 - 16 **Nikolsky E**, Mehran R, Yu J, Witzenbichler B, Brodie BR, Kornowski R, Brener S, Xu K, Dangas GD, Stone GW. Comparison of outcomes of patients with ST-segment elevation myocardial infarction with vs without previous coronary artery bypass grafting (from the Harmonizing Outcomes With Revascularization and Stents in Acute Myocardial Infarction [HORIZONS-AMI] trial). *Am J Cardiol* 2013; **111**: 1377-1386 [PMID: [23465098](https://pubmed.ncbi.nlm.nih.gov/23465098/) DOI: [10.1016/j.amjcard.2013.01.285](https://doi.org/10.1016/j.amjcard.2013.01.285)]
 - 17 **Meliga E**, García-García HM, Kukreja N, Daemen J, Tanimoto S, Ramcharitar S, van Mieghem CA, Sianos G, van der Ent M, van der Giessen WJ, de Feyter P, van Domburg R, Serruys PW. Chronic total occlusion treatment in post-CABG patients: saphenous vein graft vs native vessel recanalization-long-term follow-up in the drug-eluting stent era. *Catheter Cardiovasc Interv* 2007; **70**: 21-25 [PMID: [17584913](https://pubmed.ncbi.nlm.nih.gov/17584913/) DOI: [10.1002/ccd.21100](https://doi.org/10.1002/ccd.21100)]
 - 18 **Al-Lamee R**, Ielasi A, Latib A, Godino C, Ferraro M, Arioli F, Mussardo M, Piraino D, Figini F, Carlino M, Montorfano M, Chieffo A, Colombo A. Clinical and angiographic outcomes after percutaneous recanalization of chronic total saphenous vein graft occlusion using modern techniques. *Am J Cardiol* 2010; **106**: 1721-1727 [PMID: [21126616](https://pubmed.ncbi.nlm.nih.gov/21126616/) DOI: [10.1016/j.amjcard.2010.08.013](https://doi.org/10.1016/j.amjcard.2010.08.013)]
 - 19 **Jim MH**, Ho HH, Ko RL, Siu CW, Yiu KH, Lau CP, Chow WH. Paclitaxel-eluting stents for chronically occluded saphenous vein grafts (EOS) study. *J Interv Cardiol* 2010; **23**: 40-45 [PMID: [20465719](https://pubmed.ncbi.nlm.nih.gov/20465719/) DOI: [10.1111/j.1540-8183.2009.00525.x](https://doi.org/10.1111/j.1540-8183.2009.00525.x)]
 - 20 **Garg N**, Hakeem A, Gopal F, Uretsky BF. Outcomes of percutaneous coronary intervention of chronic total saphenous vein graft occlusions in the contemporary era. *Catheter Cardiovasc Interv* 2014; **83**: 1025-1032 [PMID: [24030975](https://pubmed.ncbi.nlm.nih.gov/24030975/) DOI: [10.1002/ccd.25188](https://doi.org/10.1002/ccd.25188)]
 - 21 **Baim DS**, Wahr D, George B, Leon MB, Greenberg J, Cutlip DE, Kaya U, Popma JJ, Ho KK, Kuntz RE; Saphenous vein graft Angioplasty Free of Emboli Randomized (SAFER) Trial Investigators. Randomized trial of a distal embolic protection device during percutaneous intervention of saphenous vein aorto-coronary bypass grafts. *Circulation* 2002; **105**: 1285-1290 [PMID: [11901037](https://pubmed.ncbi.nlm.nih.gov/11901037/) DOI: [10.1161/01.CIR.0000012783.63093.0C](https://doi.org/10.1161/01.CIR.0000012783.63093.0C)]
 - 22 **Stone GW**, Rogers C, Hermiller J, Feldman R, Hall P, Haber R, Masud A, Cambier P, Caputo RP, Turco M, Kovach R, Brodie B, Herrmann HC, Kuntz RE, Popma JJ, Ramee S, Cox DA; FilterWire EX Randomized Evaluation Investigators. Randomized comparison of distal protection with a filter-based catheter and a balloon occlusion and aspiration system during percutaneous intervention of diseased saphenous vein aorto-coronary bypass grafts. *Circulation* 2003; **108**: 548-553 [PMID: [12874191](https://pubmed.ncbi.nlm.nih.gov/12874191/) DOI: [10.1161/01.CIR.0000080894.51311.0A](https://doi.org/10.1161/01.CIR.0000080894.51311.0A)]
 - 23 **Kaliyadan AG**, Chawla H, Fischman DL, Ruggiero N 2nd, Gannon M, Walinsky P, Savage MP. Importance of Adjunct Delivery Techniques to Optimize Deployment Success of Distal Protection Filters During Vein Graft Intervention. *J Invasive Cardiol* 2017; **29**: 54-58 [PMID: [27974668](https://pubmed.ncbi.nlm.nih.gov/27974668/)]
 - 24 **Klein LW**, Kern MJ, Berger P, Sanborn T, Block P, Babb J, Tommaso C, Hodgson JM, Feldman T; Interventional Cardiology Committee of the Society of Cardiac Angiography and Interventions. Society of cardiac angiography and interventions: suggested management of the no-reflow phenomenon in the cardiac catheterization laboratory. *Catheter Cardiovasc Interv* 2003; **60**: 194-201 [PMID: [14517924](https://pubmed.ncbi.nlm.nih.gov/14517924/) DOI: [10.1002/ccd.10620](https://doi.org/10.1002/ccd.10620)]
 - 25 **Huang RI**, Patel P, Walinsky P, Fischman DL, Ogilby JD, Awar M, Frankil C, Savage MP. Efficacy of intracoronary nicardipine in the treatment of no-reflow during percutaneous coronary intervention. *Catheter Cardiovasc Interv* 2006; **68**: 671-676 [PMID: [17034064](https://pubmed.ncbi.nlm.nih.gov/17034064/) DOI: [10.1002/ccd.20885](https://doi.org/10.1002/ccd.20885)]
 - 26 **Michaels AD**, Appleby M, Otten MH, Dauterman K, Ports TA, Chou TM, Gibson CM. Pretreatment with intragraft verapamil prior to percutaneous coronary intervention of saphenous vein graft lesions: results of the randomized, controlled vasodilator prevention on no-reflow (VAPOR) trial. *J Invasive Cardiol* 2002; **14**: 299-302 [PMID: [12042618](https://pubmed.ncbi.nlm.nih.gov/12042618/)]

- 27 **Fischell TA**, Subraya RG, Ashraf K, Perry B, Haller S. "Pharmacologic" distal protection using prophylactic, intragraft nicardipine to prevent no-reflow and non-Q-wave myocardial infarction during elective saphenous vein graft intervention. *J Invasive Cardiol* 2007; **19**: 58-62 [PMID: [17268038](#)]
- 28 **Mehilli J**, Pache J, Abdel-Wahab M, Schulz S, Byrne RA, Tiroch K, Hausleiter J, Seyfarth M, Ott I, Ibrahim T, Fusaro M, Laugwitz KL, Massberg S, Neumann FJ, Richardt G, Schömig A, Kastrati A; Is Drug-Eluting-Stenting Associated with Improved Results in Coronary Artery Bypass Grafts? (ISAR-CABG) Investigators. Drug-eluting vs bare-metal stents in saphenous vein graft lesions (ISAR-CABG): a randomised controlled superiority trial. *Lancet* 2011; **378**: 1071-1078 [PMID: [21872918](#) DOI: [10.1016/S0140-6736\(11\)61255-5](#)]
- 29 **Colleran R**, Kufner S, Mehilli J, Rosenbeiger C, Schüpke S, Hoppmann P, Joner M, Mankierious N, Fusaro M, Cassese S, Abdel-Wahab M, Neumann FJ, Richardt G, Ibrahim T, Schunkert H, Laugwitz KL, Kastrati A, Byrne RA; ISAR-CABG Investigators. Efficacy Over Time With Drug-Eluting Stents in Saphenous Vein Graft Lesions. *J Am Coll Cardiol* 2018; **71**: 1973-1982 [PMID: [29724350](#) DOI: [10.1016/j.jacc.2018.03.456](#)]
- 30 **Patel NJ**, Bavishi C, Atti V, Tripathi A, Nalluri N, Cohen MG, Kini AS, Sharma SK, Dangas G, Bhatt DL. Drug-Eluting Stents Versus Bare-Metal Stents in Saphenous Vein Graft Intervention. *Circ Cardiovasc Interv* 2018; **11**: e007045 [PMID: [30571204](#) DOI: [10.1161/CIRCINTERVENTIONS.118.007045](#)]
- 31 **Savage MP**, Fischman DL. Love in Vain? *Circ Cardiovasc Interv* 2018; **11**: e007458 [PMID: [30571218](#) DOI: [10.1161/CIRCINTERVENTIONS.118.007458](#)]
- 32 **Yeh RW**, Kereiakes DJ, Steg PG, Cutlip DE, Croce KJ, Massaro JM, Mauri L; DAPT Study Investigators. Lesion Complexity and Outcomes of Extended Dual Antiplatelet Therapy After Percutaneous Coronary Intervention. *J Am Coll Cardiol* 2017; **70**: 2213-2223 [PMID: [29073947](#) DOI: [10.1016/j.jacc.2017.09.011](#)]
- 33 **Sachdeva A**, Bavisetty S, Beckham G, Shen AY, Aharonian V, Mansukhani P, Stone GW, Leon M, Moses J, Moore N, Hyett R, Contreras R, Brar SS. Discontinuation of long-term clopidogrel therapy is associated with death and myocardial infarction after saphenous vein graft percutaneous coronary intervention. *J Am Coll Cardiol* 2012; **60**: 2357-2363 [PMID: [23141495](#) DOI: [10.1016/j.jacc.2012.09.014](#)]
- 34 **Tajti P**, Burke MN, Karpaliotis D, Alaswad K, Werner GS, Azzalini L, Carlino M, Patel M, Mashayekhi K, Egred M, Krestyaninov O, Khelimskii D, Nicholson WJ, Ungi I, Galassi AR, Banerjee S, Brilakis ES. Update in the Percutaneous Management of Coronary Chronic Total Occlusions. *JACC Cardiovasc Interv* 2018; **11**: 615-625 [PMID: [29550088](#) DOI: [10.1016/j.jcin.2017.10.052](#)]
- 35 **Brilakis ES**, Mashayekhi K, Tsuchikane E, Abi Rafeh N, Alaswad K, Araya M, Avran A, Azzalini L, Babunashvili AM, Bayani B, Bhindi R, Boudou N, Boukhris M, Božinović NŽ, Bryniarski L, Bufe A, Buller CE, Burke MN, Büttner HJ, Cardoso P, Carlino M, Christiansen EH, Colombo A, Croce K, Damas de Los Santos F, De Martini T, Dens J, Di Mario C, Dou K, Egred M, ElGuindy AM, Escaned J, Furkalo S, Gagnor A, Galassi AR, Garbo R, Ge J, Goel PK, Goktekin O, Grancini L, Grantham JA, Hanratty C, Harb S, Harding SA, Henriques JPS, Hill JM, Jaffer FA, Jang Y, Jussila R, Kalnins A, Kalyanasundaram A, Kandzari DE, Kao HL, Karpaliotis D, Kassem HH, Knaapen P, Kornowski R, Krestyaninov O, Kumar AVG, Laanmets P, Lamelas P, Lee SW, Lefevre T, Li Y, Lim ST, Lo S, Lombardi W, McEntegart M, Munawar M, Navarro Lecaro JA, Ngo HM, Nicholson W, Olivecrona GK, Padilla L, Postu M, Quadros A, Quesada FH, Prakasa Rao VS, Reifart N, Saghatelian M, Santiago R, Sianos G, Smith E, C Spratt J, Stone GW, Strange JW, Tammam K, Ungi I, Vo M, Vu VH, Walsh S, Werner GS, Wollmuth JR, Wu EB, Wyman RM, Xu B, Yamane M, Ybarra LF, Yeh RW, Zhang Q, Rinfret S. Guiding Principles for Chronic Total Occlusion Percutaneous Coronary Intervention. *Circulation* 2019; **140**: 420-433 [PMID: [31356129](#) DOI: [10.1161/CIRCULATIONAHA.119.039797](#)]



Published by **Baishideng Publishing Group Inc**
7041 Koll Center Parkway, Suite 160, Pleasanton, CA 94566, USA
Telephone: +1-925-3991568
E-mail: bpgoffice@wjgnet.com
Help Desk: <https://www.f6publishing.com/helpdesk>
<https://www.wjgnet.com>

