

3-8-2022

Acute occlusion of aortic endovascular aneurysm repair stent graft with bilateral limb ischemia

Min Choi

Thomas Jefferson University

Dawn Salvatore

Thomas Jefferson University

Paul J DiMuzio

Thomas Jefferson University

Michael Nooromid

Thomas Jefferson University

Babak Abai

Thomas Jefferson University

Follow this and additional works at: <https://jdc.jefferson.edu/surgeryfp>

 Part of the [Surgery Commons](#)

[Let us know how access to this document benefits you](#)

Recommended Citation

Choi, Min; Salvatore, Dawn; DiMuzio, Paul J; Nooromid, Michael; and Abai, Babak, "Acute occlusion of aortic endovascular aneurysm repair stent graft with bilateral limb ischemia" (2022). *Department of Surgery Faculty Papers*. Paper 211.

<https://jdc.jefferson.edu/surgeryfp/211>

This Article is brought to you for free and open access by the Jefferson Digital Commons. The Jefferson Digital Commons is a service of Thomas Jefferson University's [Center for Teaching and Learning \(CTL\)](#). The Commons is a showcase for Jefferson books and journals, peer-reviewed scholarly publications, unique historical collections from the University archives, and teaching tools. The Jefferson Digital Commons allows researchers and interested readers anywhere in the world to learn about and keep up to date with Jefferson scholarship. This article has been accepted for inclusion in Department of Surgery Faculty Papers by an authorized administrator of the Jefferson Digital Commons. For more information, please contact: JeffersonDigitalCommons@jefferson.edu.

Acute occlusion of aortic endovascular aneurysm repair stent graft with bilateral limb ischemia

Min H. Choi, BS, Dawn M. Salvatore, MD, Paul J. DiMuzio, MD, Michael J. Nooromid, MD, and B. Abai, MD, Philadelphia, PA

ABSTRACT

Endovascular aneurysm repair has dramatically changed the management of abdominal aortic aneurysms as an alternative to open repair. However, complications can occur, including stent graft migration, kinking, and occlusion, leading to compromise of the excluded aneurysm walls and acute limb ischemia. In the present report, we have described a case of migration and kinking of an abdominal aortic stent graft in the main body that led to occlusion of the abdominal aorta and bilateral acute limb ischemia. The patient required emergent explantation of the stent graft and open repair of the abdominal aneurysm with a rifampin-soaked Dacron graft, which achieved a favorable outcome. (*J Vasc Surg Cases Innov Tech* 2022;8:190-2.)

Keywords: Abdominal aneurysm; Aortic; Endovascular stent graft

Endovascular aneurysm repair (EVAR) was first described by Ukrainian surgeon Nicholas Volodos in 1986, and the first successful EVAR was performed in 1991 by Dr Juan Carlos Parodi.¹ Elkouri et al² showed that cardiac and pulmonary complications were significantly less frequent and less severe after EVAR of abdominal aortic aneurysms (AAAs) compared with open repair. However, EVAR can also result in complications, with the development of an endoleak the most common. EVAR-related complications include kinking or occlusion (prevalence, 2%-4%), endoleak (prevalence, 15%-30%), migration (prevalence, 1%-10%), and infection (prevalence, 0.4%-3%).³ Chang et al⁴ demonstrated an incidence of kinking for the AFX Strata stent graft of 2.8%, AFX Duraply stent graft of 10.3%, and AFX2 stent graft of 0% (Endologix, Irvine, CA). In the present report, we have described the acute presentation of a patient with aortic EVAR stent graft migration, kinking, and occlusion that led to bilateral lower limb ischemia. Prompt surgical intervention with open repair and graft bypass resulted in a favorable outcome. The patient provided written informed consent for the report of his case details and imaging studies.

CASE REPORT

A 66-year-old man with a history of EVAR with an Endologix AFX stent graft 3 years previously to treat impending rupture of an AAA had presented as a transfer from an outside hospital with acute back and abdominal pain and weakness in his legs. The patient had also undergone repair of a type III endoleak with a 34-mm diameter and 100-mm length with an AFX2 endovascular unibody modular stent graft 1 year previously at an outside hospital. The patient had reportedly leaned down to pick up a battery in his garage the day before his presentation, which had instigated severe, acute, nonradiating low back pain. On further examination, he had bilateral lower extremity weakness and paresthesia, with no Doppler signals to the dorsalis pedis and posterior tibial arteries bilaterally. His legs were cool to the touch with a mottled appearance. Bilateral femoral artery Doppler signals were present. The left popliteal artery had a Doppler signal; however, the right popliteal artery Doppler signal could not be examined owing to the patient's pain. A computed tomography angiogram demonstrated a thrombosed AAA EVAR stent graft with the development of a saccular outpouching from the AAA measuring 6.0 × 5.1 × 4.4 cm (Figs 1 and 2). The stent graft had migrated and become kinked and occluded. Retrograde filling of the internal and external iliac arteries from collateral flow via the inferior epigastric arteries was present. Given the acute limb ischemia with Rutherford class IIb symptoms, the patient was taken emergently to the operating room for open surgical treatment.

Open AAA repair was chosen for following reasons. First, it was an emergent situation with concerns for managing large fresh thrombi and clearing the aorta endovascularly. Second, the patient required fasciotomies. Finally, a risk of failure was present with endovascular therapy, with multiple issues, including a severely kinked stent and a large thrombus burden from the aorta to the bilateral iliac arteries. The AAA was appropriately exposed. Dissection was taken down toward each iliac limb until a clamp could be placed around each of the limbs. The

From the Department of Vascular and Endovascular Surgery, Thomas Jefferson University.

Author conflict of interest: none.

Correspondence: Min H. Choi, BS, Department of Vascular and Endovascular Surgery, Thomas Jefferson University, 111 South 11th Street, Suite 6210, Philadelphia, PA 19107 (e-mail: minmichaelchoi@gmail.com).

The editors and reviewers of this article have no relevant financial relationships to disclose per the Journal policy that requires reviewers to decline review of any manuscript for which they may have a conflict of interest.

2468-4287

© 2022 The Authors. Published by Elsevier Inc. on behalf of Society for Vascular Surgery. This is an open access article under the CC BY-NC-ND license (<http://creativecommons.org/licenses/by-nc-nd/4.0/>).

<https://doi.org/10.1016/j.jvscit.2022.02.009>

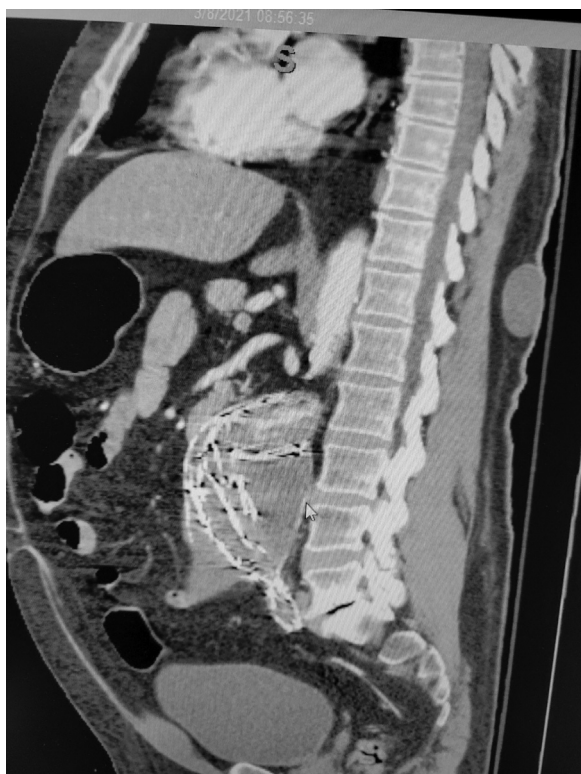


Fig 1. Sagittal section of a computed tomography angiogram showing a kinked, occluded, and thrombosed Endologix aortic stent graft with a sacular abdominal aneurysm measuring 6.0 × 5.1 × 4.4 cm.

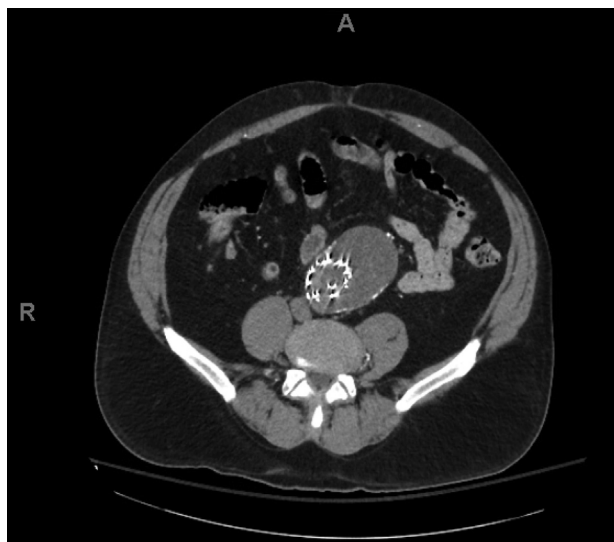

Fig 2. Axial section of a computed tomography angiogram showing a thrombosed Endologix aortic stent graft with a sacular abdominal aneurysm measuring 6.0 × 5.1 × 4.4 cm from the 12- to 3-o'clock position.

infrarenal aorta was clamped, and the sac was cleared. The aortic portion of the EVAR stent graft was explanted, which had a large thrombus within the lumen (Fig 3). The bilateral iliac

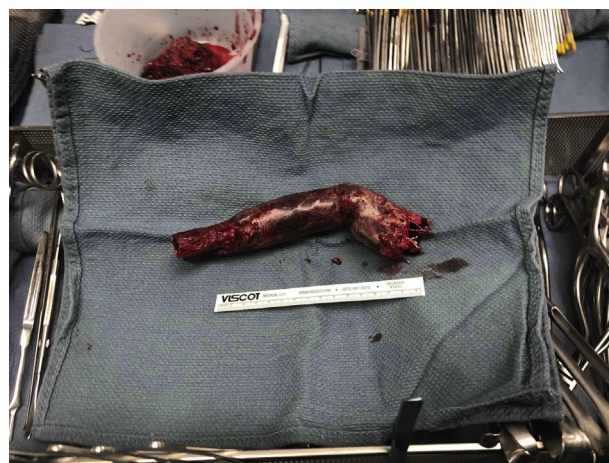

Fig 3. Explanted Endologix aortic stent graft showing kinked deformation. Top left corner, a bucket containing mural thrombosis that had been inside the aneurysm.

stents were left in place. We used 5F Fogarty catheters on each iliac limb, and multiple large thrombi were excavated, restoring the back bleeding in each of the iliac arteries. A rifampin-soaked Dacron 18-mm × 40-cm tube graft was cut in length to fit and used to create an end-to-end aortic–aortic bypass from the infrarenal aorta to the aortic bifurcation (Fig 4). The native terminal and proximal aortic walls were healthy enough to sew on a graft. Soaking a Dacron graft with rifampin is the standard of care at our institution for all open abdominal aortic repairs. Prophylactic fasciotomy was performed to prevent the development of compartment syndrome. The patient's bilateral dorsalis pedis and posterior tibial artery Doppler signals were audible. The patient's recovery was uneventful, and he was discharged on postoperative day 6. The 6-week follow-up examination showed the fasciotomy wounds healing well, and the patient was ambulating well.

DISCUSSION

Although occlusion of an AAA EVAR stent graft secondary to kinking is rare, it can occur and, as developed in our patient, can lead to severe complications if not detected and treated promptly. Usually, the kinking of an AAA EVAR stent graft will occur at the level of the iliac artery limbs, with incidence of 1.5%, and contributes to lower extremity occlusion.⁵ In the present case report, however, we have addressed a unique complication of AAA EVAR stent graft kinking at the level of the mid-body, which led to acute occlusion of the stent graft and bilateral iliac arteries. The graft in the present patient seemed to have migrated >5 mm from its original position, meeting the definition of stent displacement. Device migration will often result from dilatation of the aneurysm neck but can also occur because of tortuous anatomy of the aorta, degeneration of the aortic wall, and improper graft sizing.³ Also, device migration has been associated with the development of endoleaks, because it will remodel the AAA sac, which could explain

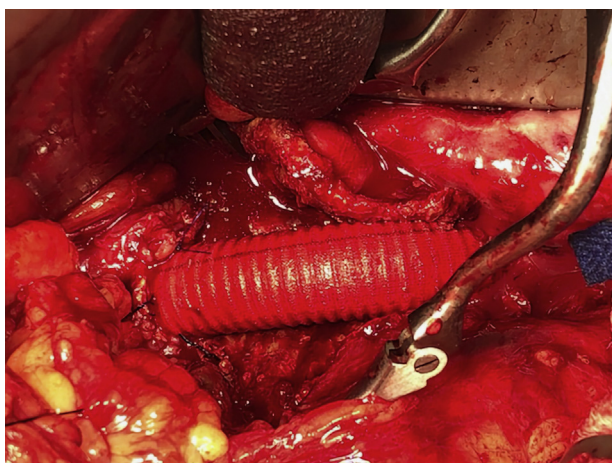


Fig 4. Finished product of end-to-end aortic–aortic bypass with a rifampin-soaked Dacron graft from the infrarenal aorta to the aortic bifurcation. A Dacron tube graft of 18 mm × 40 cm had been cut in length to fit.

the cause in the present patient. Therefore, an endoleak causing the development of a saccular aneurysm, compounded by the coincidental bending of the patient's abdomen in his garage, could have contributed to device migration, kinking, and thrombus formation. Another likely postulation that could explain the cause is migration of the graft owing to aortic neck dilation. Aortic neck dilation after EVAR has been shown to be associated with graft migration in $\leq 35.3\%$ of patients.⁶

The design of the stent graft is another aspect that could play a role in calculating the risk of kinking. Baum et al⁷ concluded that unsupported stent grafts were 15 times more likely than were stent grafts supported with nitinol Z stents to require reintervention because of kinking. The Endologix stent graft used in the present case does not have fixation points but uses anatomic fixation by straddling iliac stents at the aortobifurcation. This could explain the possible vulnerability of device migration resulting in kinking or occlusion. Ultimately, the prevention of device migration can be limited by the anatomy. A severely tortuous and angulated aorta and iliac arteries can cause the stent graft to improperly adhere to the vessel walls. However, Oh et al⁸ demonstrated that deploying stent graft limbs extensively above or below severely angulated vessels could prevent kinking of the stent graft.

In terms of an alternative approach to repairing a kinked endograft, Ricotta et al⁹ successfully treated a patient using an endovascular technique for an endograft that had migrated and kinked, causing a type Ia

endoleak. They used a snare accessed from the left brachial artery, pulling two balloons accessed from the bilateral femoral arteries cephalad to unfold the kinked graft. However, unlike our patient, their patient did not have a large burden of thrombi from the abdominal aorta to the bilateral iliac arteries. For our patient, with acute and severe graft kinking and occlusion, emergent open abdominal aorta repair was indicated. Urgent reconstruction of the abdominal aorta restored the blood circulation to the bilateral lower extremities, returned the baseline motor and sensory function, and eliminated future graft-related complications.

CONCLUSIONS

In the present case report, we have addressed a unique complication of an AAA EVAR stent graft that had migrated and kinked at the main body of the graft, leading to occlusion of the aorta and acute bilateral lower extremity ischemia. Although a rarer phenomenon than iliac limb kinking, main body abdominal aortic stent graft kinking can occur and requires swift explantation of the occluded graft and replacement via open repair to achieve a favorable outcome.

REFERENCES

- England A, McWilliams R. Endovascular aortic aneurysm repair (EVAR). *Ulster Med J* 2013;82:3-10.
- Elkouri S, Gloviczki P, McKusick MA, Panneton JM, Andrews J, Bower TC, et al. Perioperative complications and early outcome after endovascular and open surgical repair of abdominal aortic aneurysms. *J Vasc Surg* 2004;39:497-505.
- Daye D, Walker TG. Complications of endovascular aneurysm repair of the thoracic and abdominal aorta: evaluation and management. *Cardiovasc Diagn Ther* 2018;8(Suppl 1):S138-56.
- Chang RW, Rothenberg KA, Harris JE, Gologorsky RC, Hsu JH, Rehling TF, et al. Midterm outcomes for 605 patients receiving Endologix AFX or AFX2 endovascular AAA systems in an integrated healthcare system. *J Vasc Surg* 2021;73:856-66.
- Coelho A, Nogueira C, Lobo M, Gouveia R, Campos J, Augusto R, et al. Impact of post-EVAR graft limb kinking in EVAR limb occlusion: aetiology, early diagnosis, and management. *Eur J Vasc Endovasc Surg* 2019;58:681-9.
- Diehm N, Dick F, Katzen BT, Schmidli J, Kalka C, Baumgartner I. Aortic neck dilatation after endovascular abdominal aortic aneurysm repair: a word of caution. *J Vasc Surg* 2008;47:886-92.
- Baum RA, Shetty SK, Carpenter JP, Soulen MC, Velazquez OC, Shlansky-Goldberg RD, et al. Limb kinking in supported and unsupported abdominal aortic stent-grafts. *J Vasc Interv Radiol* 2000;11:1165-71.
- Oh PC, Kim M, Shin EK, Kang WC. Prevention of kinked stent graft limb due to severe angulated proximal neck during endovascular repair for abdominal aortic aneurysm. *Ann Thorac Cardiovasc Surg* 2018;24:106-9.
- Ricotta JJ, Malgor RD. Novel technique for endovascular salvage of a folded aortic endograft. *J Vasc Surg* 2010;52:785-9.

Submitted Oct 13, 2021; accepted Feb 11, 2022.