

11-1-2019

## False in Name Only-Gastroduodenal Artery Pseudoaneurysm in a Recurrently Bleeding Patient: Case Report and Literature Review.

M. Binetti  
*St. Orsola University Hospital*

A. Lauro  
*St. Orsola University Hospital*

R. Golfieri  
*St. Orsola University Hospital*

S Vaccari  
*St. Orsola University Hospital.*

V D'Andrea  
Follow this and additional works at: <https://jdc.jefferson.edu/surgeryfp>  
*Imberto I Hospital*

 Part of the [Surgery Commons](#)

**Let us know how access to this document benefits you**

*See next page for additional authors*

### Recommended Citation

Binetti, M.; Lauro, A.; Golfieri, R.; Vaccari, S; D'Andrea, V; Marino, I. R.; Cervellera, M.; Renzulli, M.; and Tonini, V., "False in Name Only-Gastroduodenal Artery Pseudoaneurysm in a Recurrently Bleeding Patient: Case Report and Literature Review." (2019). *Department of Surgery Faculty Papers*. Paper 175.

<https://jdc.jefferson.edu/surgeryfp/175>

This Article is brought to you for free and open access by the Jefferson Digital Commons. The Jefferson Digital Commons is a service of Thomas Jefferson University's [Center for Teaching and Learning \(CTL\)](#). The Commons is a showcase for Jefferson books and journals, peer-reviewed scholarly publications, unique historical collections from the University archives, and teaching tools. The Jefferson Digital Commons allows researchers and interested readers anywhere in the world to learn about and keep up to date with Jefferson scholarship. This article has been accepted for inclusion in Department of Surgery Faculty Papers by an authorized administrator of the Jefferson Digital Commons. For more information, please contact: [JeffersonDigitalCommons@jefferson.edu](mailto:JeffersonDigitalCommons@jefferson.edu).

---

## Authors

M. Binetti, A. Lauro, R. Golfieri, S Vaccari, V D'Andrea, I. R. Marino, M. Cervellera, M. Renzulli, and V. Tonini

**False in Name Only – Gastroduodenal artery pseudoaneurysm in a recurrently bleeding patient:**

**case report and literature review**

Binetti M.<sup>1</sup>, Lauro A.<sup>1</sup>, Golfieri R.<sup>2</sup>, Vaccari S.<sup>1</sup>, D'Andrea V.<sup>3</sup>, Marino I.R.<sup>4</sup>, Cervellera M.<sup>1</sup>, Renzulli M.<sup>2</sup> §

*and* Tonini V.<sup>1</sup> §

*Affiliations:*

1. Emergency Surgery Department- St. Orsola University Hospital- Bologna (ITALY)
2. Radiology Unit, Department of Experimental- Diagnostic and Speciality Medicine, St. Orsola University Hospital, Bologna (ITALY)
3. Department of Surgical Sciences – La Sapienza University –Umberto I Hospital- Rome (ITALY)
4. Sidney Kimmel Medical College, Thomas Jefferson University- Philadelphia, PA (USA)

§ Renzulli M. and Tonini V. equally contributed as joint senior Authors.

*Corresponding author:*

Professore Augusto Lauro

[augustola@yahoo.com](mailto:augustola@yahoo.com)

*Abbreviations :*

ALT Alanine Aminotransferase  
AST Aspartate Aminotransferase  
bpm beats per minute  
C-RP C-reactive protein  
EGD Esophagogastric-duodenal endoscopy  
GI Gastrointestinal  
GDA Gastroduodenal artery  
Hbg Hæmoglobin  
IV Intravenous  
NG Nasogastric  
WBC White Blood Cell count  
COPD Chronic obstructive pulmonary disease  
PLT Platelet count

**Conflict of interest** = none of the authors have any conflicts of interest pertaining to this work.

**Abstract (85 words):**

INTRODUCTION: Although the diagnosis of visceral pseudoaneurysm is unusual, it requires emergent attention due to the risk of rupture. We describe a 70-year old man with a gastroduodenal artery (GDA) pseudoaneurysm manifest as recurrent hæmorrhage.

AREAS COVERED: We highlight the possible ætiologies, clinical presentations, diagnostic tools and treatment options for this condition. In this instance, the patient was successfully treated by selective angio-embolization.

EXPERT COMMENTARY: A visceral pseudoaneurysm should be considered in patients with abdominal pain and GI hæmorrhage. At present, angio-embolization is first-line therapy.

**Keywords:**

Recurrent bleeding, gastroduodenal artery, pseudoaneurysm, angio-embolization

**Case report and evolution:**

A 70-year old man was admitted on May, 2019 to the Sant' Orsola University Hospital Emergency Department due to rectal bleeding. On admission, his blood pressure was 160/85 mmHg, pulse rate 123 bpm, SpO<sub>2</sub> 94% breathing room air, temperature 37 °C. Clinical evaluation revealed a benign abdominal exam without signs of peritonitis; rectal evaluation revealed traces of blood. Past medical history was notable for active smoking and alcoholism, asthma complicated by COPD, and previous rib fractures.

Admission blood tests included: Hgb 12.2 g/dL, Plt 321,000/ mm<sup>3</sup>, INR 1.10, aPTT ratio 0.86, WBC 19,240/mm<sup>3</sup>, urea 100 mg/dL, creatinine 0.67 mg/dL, sodium 137 mmol/L, potassium 4.4 mmol/L, total bilirubin 0.84 mg/dL, AST 23 U/L, ALT 32 U/L, amylase 108 U/L and C-RP 0.60 mg/dL. Abdominal X-rays showed gastric dilation without distension of the abdominal loops and without free air. Initial treatment was conservative with NG tube insertion and IV pantoprazole. Further blood tests showed a drop in hæmoglobin level (11.3 g/dL). The patient was admitted to the Medicine Department.

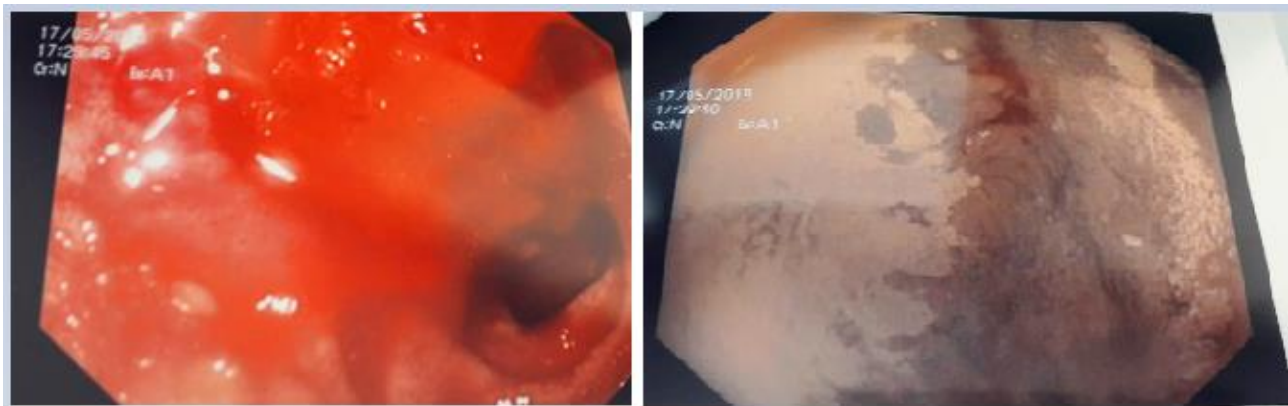
An EGD was performed: a deep, anterior duodenal bulb ulcer was seen (15-20 mm) with fibrinous aspect and stigmata of previous bleeding (**Figure 1**). In the 2<sup>nd</sup> part of the duodenum, there were

superficial erosions; next to the Z-line a little single erosion (4 mm) was discovered. During the next 12 hours, control blood tests showed a progressive decrease in haemoglobin level: 10.5 g/dL and then 8.1 g/dL. An emergency EGD was repeated: in the gastric lumen there was abundant blood without lesions, whereas active bleeding was observed from a duodenal ulcer covered by a clot. Epinephrine treatment of the lesion margins was performed followed by the transfusion of 2U of blood.

The day after, another emergency EGD was performed for further rectal bleeding associated with hypotension. Treatment with epinephrine plus Hemospray™ was performed. A few hours later, further episodes of rectal bleeding occurred. The patient was admitted to the Emergency Surgery Unit and an exploratory laparotomy was carried out. A 3x3 cm mass in the 2<sup>nd</sup> portion of the duodenum, indissociable from the hepatic peduncle, was identified. A gastrotomy showed the stomach lumen full of coagulated blood. Haemostasis was achieved by suturing the duodenal ulcer adding fibrin glue. Another seven blood units were transfused. The patient was transferred to the Intensive Care Unit.

After three days, the patient was admitted again to Emergency Surgery Unit where, the same day, a new episode of rectal bleeding recurred. An abdominal CT scan documented a 16 mm pseudoaneurysm of the gastroduodenal artery without active bleeding, likely responsible of the recurrent intestinal bleeding (**Figure 2**). The patient was brought to the radiology suite where selective arteriography was performed. By placing the angiographic catheter in the common hepatic artery, the GDA was not visualized due to a blood flow reversal in this vessel caused by the stenosis of the celiac trunk. Since the lesion was documented when the tip of the catheter was positioned in the GDA proximal to the origin of the pseudoaneurysm, the GDA was embolized by using micro-coils positioned proximal and distal to the origin of the pseudoaneurysm. After the embolization, an angiographic study was used to positioning the catheter in the superior mesenteric artery. During this check, a small branch of the inferior pancreatic-duodenal arch feeding the pseudoaneurysm was identified. Nevertheless, this artery was smaller than the calibre of the microcatheter (2.4 F) and, therefore it was not possible to catheterize this vessel in order to perform a selective embolization with standard techniques. Finally, considering the haemodynamic instability of the patient and the number of episodes of recurrent bleeding, a decision was taken to dissect this small branch by using the micro-guide and the micro-catheter. Definitive angiographic control after the dissection demonstrated the complete exclusion of the pseudoaneurysm from the circulation, with the patency of the remaining

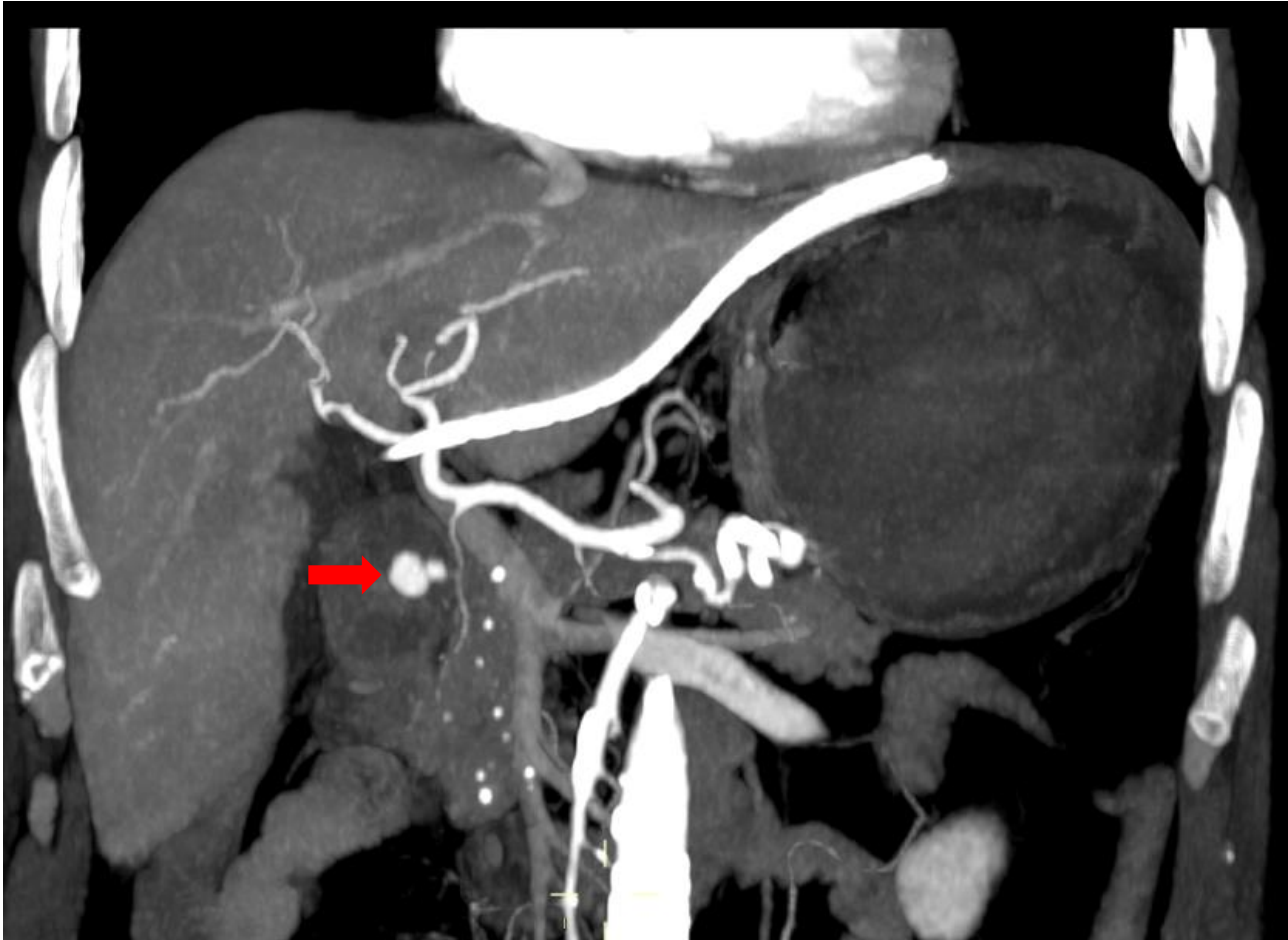
pancreatic-duodenal arteries (**Figure 3**). In the following days, no recurrent bleeding occurred. The patient was haemodynamically stable and was finally re-transferred to the Medicine Department. The patient was discharged in good clinical conditions 15 days after the angio-embolization procedure. An abdominal CT scan, performed 2 weeks after discharge, confirmed the complete absence of the pseudoaneurysm, with no signs of duodenal wall ischemia (**Figure 4**).



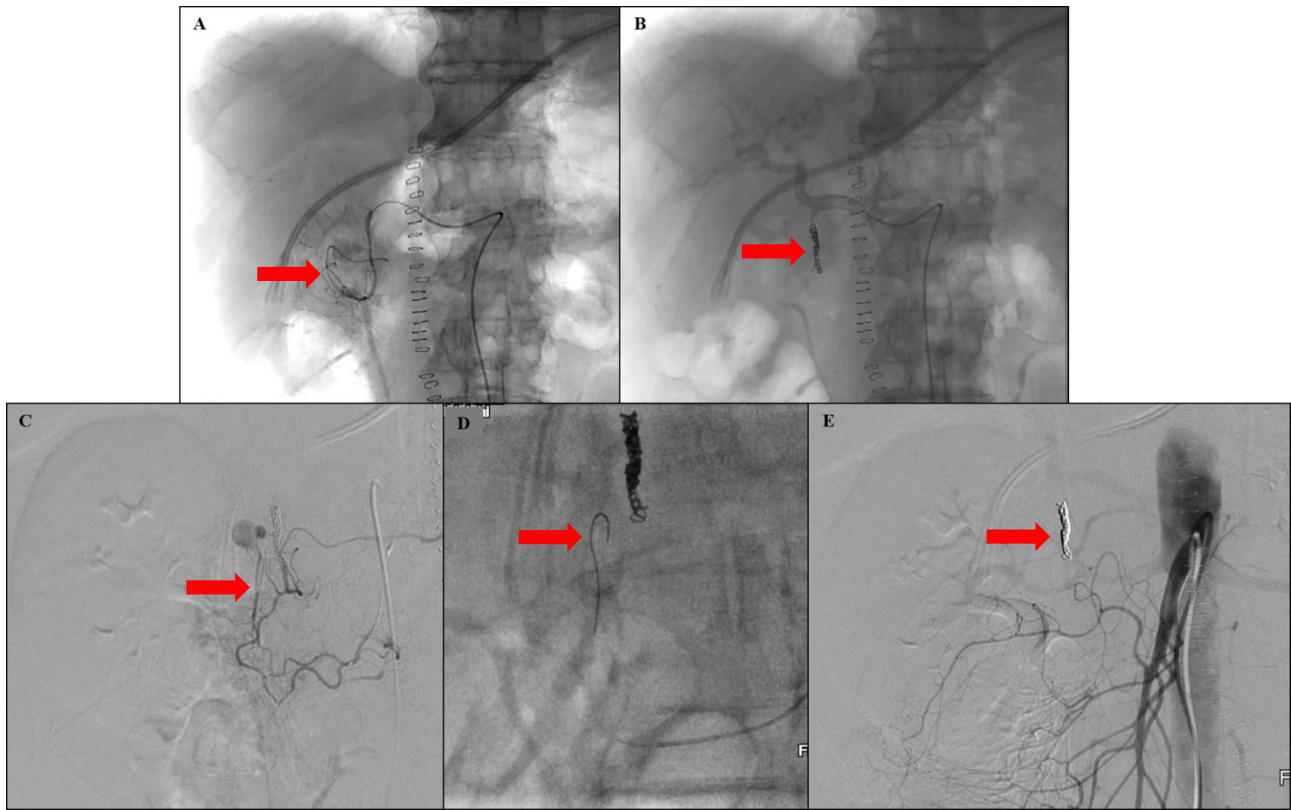
**a.** *gastric bleeding*

**b.** *site of ulcer*

**Fig. 1: EGD procedure.**



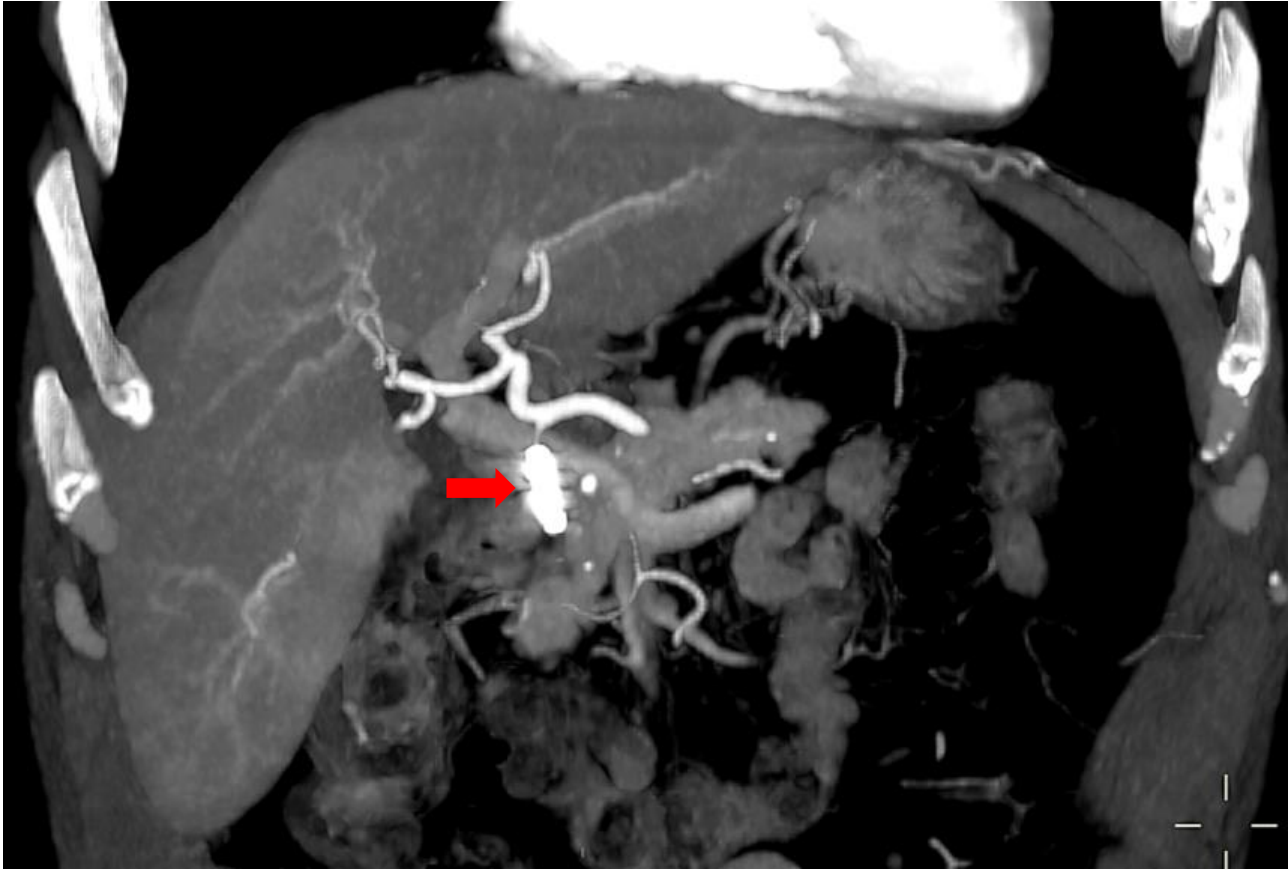**Fig. 2: Abdominal CT showing GDA pseudoaneurysm.**



**Fig. 3: Selective arteriography** of the GDA demonstrated the origin of the pseudoaneurysm (A).

Therefore, the GDA was embolized by using micro-coils (B) Angiography performed from the superior mesenteric artery demonstrated a small branch of the inferior pancreatic-duodenal arch feeding the pseudoaneurysm (C), which was dissected by using the micro-guide and micro-catheter (D). The final angiography from the superior mesenteric artery documented the complete exclusion of the pseudoaneurysm from the circulation (E).





**Fig. 4: Abdominal CT** showing the absence of the GDA pseudoaneurysm. The micro-coils were correctly positioned in the GDA (red arrow).

#### **Discussion :**

A pseudoaneurysm results from a previous injury affecting the layers of the vasculature. It is also termed “false aneurysm” since the blood remains within the arterial wall (1). Although pseudoaneurysm of the mesenteric vasculature is rare, it requires emergent care due to the risk of rupture that is not related to pseudoaneurysm size (2). Few cases of pseudoaneurysm and true aneurysm of the superior mesenteric artery (3), coeliac trunk (3), cystic artery (4) and right hepatic artery (5) are described in the literature. The splenic artery is the most common artery affected (3). A GDA pseudoaneurysm was present in this case (**Figure 5**). GDA pseudoaneurysms represent 1.5% of all visceral pseudoaneurysms (6). Our patient was older than is usually reported in literature (**Table 1**).

It is important to differentiate between true aneurysm and pseudoaneurysm. True aneurysms depend on vessel abnormalities, whereas pseudoaneurysms are often related to vascular erosion or vascular

injury (7). Chronic pancreatitis represents one of the most important aetiologies of GDA aneurysm (8). Less frequent causes are vascular abnormalities (9) and trauma (10). Ethanol abuse and peptic ulcer disease are often associated (11). Occasionally, spontaneous GDA pseudoaneurysm occurs (12). In our case report, the patient had a history of active alcoholism and was initially diagnosed with a deep peptic ulcer.

The most frequent clinical presentation of GDA pseudoaneurysm is gastrointestinal bleeding (52%) and/or abdominal pain (46%) (13). Though the rupture of the pseudoaneurysm is extremely rare, its mortality rate is ~ 20-43% in untreated patients (14). Our patient was admitted to Emergency Department after a first episode of gastrointestinal bleeding due in part to the high risk of rupture.

The two most useful tools for the diagnosis are the abdominal CT scan and visceral arteriography. Arteriography has a higher sensitivity than the CT scan (100% vs. 67%) and also can be therapeutic as well as diagnostic (15). Among patients with a diagnosis of pancreatitis, the evidence of a homogeneously enhancing structure next to pseudocyst or vascular structure may suggest the presence of a pseudoaneurysm (16).

The timing of the treatment is crucial, in order to avoid GDA pseudoaneurysm rupture. The optimal approach is still controversial. In the past, surgical approach was the “gold standard” (14), although currently, a non-invasive approach is preferred for stable patients (17). GDA angio-embolization is performed by a transfemoral route with super-selective catheterization of the GDA. Different microcoils are placed proximally and distally to a pseudoaneurysm in order to completely exclude the lesion from the circulation. The procedure is successful if immediate haemostasis is achieved with no recurrent bleeding up to 48 hours after embolization (18). The embolization success rate is ~ 79-100% (17,19-39), with a possible complication including visceral ischemia (17). In case of embolization failure or for unstable patients, an open surgical approach is preferred, with a variety of procedures available including pseudoaneurysm resection, partial and total gastrectomy, and pancreatectomy (2, 15-17, 25-26,29).

In summary, GDA pseudoaneurysm, although rare, should be considered among the possible diagnoses in a patient with recurrent acute gastrointestinal bleeding. Due to the risk of rupture, it is essential to

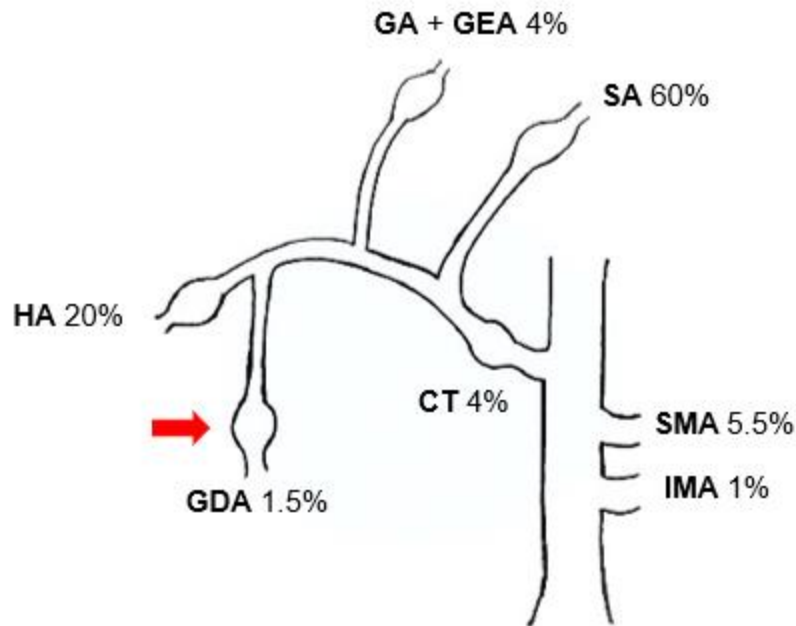
achieve the diagnosis as soon as possible. A conservative approach with angio-embolization is currently the treatment of choice.

#	Authors (ref)	Median age of patient	Clinical presentation	First treatment	Type of treatment	Success of procedure
1	Gupta et al. (18)	40	bleeding	endovascular	angioembolization/ thrombin injection	yes
2	Abdelgabar et al. (3)	78	abdominal pain, vomiting, bleeding	endovascular	angioembolization	yes
3	Sharma et al. (6)	28	acute pancreatitis	endovascular	angioembolization	yes
4	Galanakis et al. (20)	79	epigastric pain	endovascular	angioembolization	yes
5	Gião Antunes et al. (13)	54	epigastric pain, vomiting	-	-	-
6	Santos-Rancaño et al. (21)	48	hematemesis, melaena	endovascular	angioembolization	yes
7	Elazary et al. (22)	18	recurrent GI bleeding	endovascular	angioembolization	yes
8	Chong et al. (10)	48	acute pancreatitis, melaena	endovascular	angioembolization	yes
9	Carrafiello et al. (14)	69	acute pancreatitis	endovascular	angioembolization/ thrombin injection	yes
10	Geoghegan et	24	chronic pancreatitis	endovascular	angioembolization	no

	al.(23)					
11	Klauß et al. (24)	47	upper abdominal pain	endovascular	angioembolization	yes
12	Volpi et al. (25)	69	upper GI bleeding	endovascular	angioembolization	yes
13	Dirks et al. (26)	59	recurrent bleeding	endovascular	angioembolization	yes
14	Germanos et al. (27)	49	chronic pancreatitis	endovascular	angioembolization	yes
15	Jovanović et al. (28)	47	jaundice	surgical	Billroth II gastrectomy	
16	Vizsy et al. (29)	62	hematemesis, melaena , jaundice	surgical	GDA ligation	yes yes
17	Singh et al. (30)	35	abdominal pain, hematemesis	surgical	GDA ligation	yes
18	Yen et al. (31)	43	jaundice, pruritus	endovascular	angioembolization	yes
19	Akbari et al. (32)	88	epigastric pain	endovascular	angioembolization	yes
20	Androulakakis et al. (33)	77	abdominal pain, vomiting	-	-	-
21	Kueper et al. (34)	60	abdominal discomfort	endovascular	angioembolization	yes
22	Lykoudis et al.	65	epigastric pain, nausea	endovascular	stent graft	

	(35)					yes
23	Marjanovic et al.(36)	56	palpable mass, epigastric pain	endovascular	stent graft	yes
24	Piffaretti et al. (37)	30	bleeding, hypotension	endovascular	angioembolization/ thrombin injection	yes
25	Savage et al. (38)	67	hemorrhagic shock	surgical	surgical resection	yes
26	Sun et al. (39)	63	bleeding	surgical	surgical excision	yes

**Table 1: GDA pseudoaneurysms** described in medical literature.



**SA** = Splenic Artery, **SMA** = Superior Mesenteric Artery, **IMA** = Inferior Mesenteric Artery, **CT** = Celiac Trunk, **GDA** = Gastroduodenal Artery, **HA** = Hepatic Arteries, **GA + GEA** = Gastric + Gastroepiploic Arteries.

**Fig. 5:** the **most common sites** of GI aneurysmal disease.

#### Key messages:

- GDA pseudoaneurysm isn't a common diagnosis, but its rupture is a very dangerous complication.
- Clinical presentation is mainly represented by abdominal pain and gastrointestinal bleeding.
- Nowadays for stable patients angio-embolization is considered the treatment of choice.

#### References:

1. Awada Z, Al Moussawi H, Alsheikh M, et al. Gastroduodenal Artery Pseudoaneurysm Rupture Post-Billroth II Surgery: Case Report. **Cureus**. 2019;11:e3833.
2. Matsuno Y, Mori Y, Umeda Y, et al. Surgical repair of true gastroduodenal artery aneurysm: a case report. **Vasc Endovascular Surg**. 2008;42:497–499.

3. Abdelgabar A, d'Archambeau O, Maes J, et al. Visceral artery pseudoaneurysms: two case reports and a review of the literature. **J Med Case Reports**. 2017;11:126.
4. She WH, Tsang S, Poon R, et al. Gastrointestinal bleeding of obscured origin due to cystic artery pseudoaneurysm. **Asian J Surg**. 2017;40:320–323.
5. Fujio A, Usuda M, Ozawa Y, et al. A case of gastrointestinal bleeding due to right hepatic artery pseudoaneurysm following total remnant pancreatectomy: A case report. **Int J Surg Case Rep**. 2017;41:434–437.
6. Sharma M, Somani P, Sunkara T, et al. Endoscopic ultrasound-guided coil embolization and thrombin injection of a bleeding gastroduodenal artery pseudoaneurysm. **Endoscopy**. 2019;51:E36–37.
7. Iyori K, Horigome M, Yumoto S, et al. Aneurysm of the gastroduodenal artery associated with absence of the celiac axis: report of a case. **Surg Today**. 2004;34:360–362.
8. Bergert H, Hinterseher I, Kersting S, et al. Management and outcome of hemorrhage due to arterial pseudoaneurysms in pancreatitis. **Surgery**. 2005;137:323–328.
9. Koyazounda A, Jaillot P, Persico J, et al. Aneurysm of the gastroduodenal artery ruptured into the peritoneum. Treatment by embolization. **Presse Medicale Paris Fr** 1983. 1994;23:661–664.
10. Chong WW, Tan SG, Htoo MM, et al. Endovascular treatment of gastroduodenal artery aneurysm. **Asian Cardiovasc Thorac Ann**. 2008;16:68–72.
11. Shanley CJ, Shah NL, Messina LM, et al. Uncommon splanchnic artery aneurysms: pancreaticoduodenal, gastroduodenal, superior mesenteric, inferior mesenteric, and colic. **Ann Vasc Surg**. 1996;10:506–515.
12. Sethi H, Peddu P, Prachalias A, et al. Selective embolization for bleeding visceral artery pseudoaneurysms in patients with pancreatitis. **Hepatobiliary Pancreat Dis Int**. 2010;9:634–638.
13. Gião Antunes A, Peixe B, Guerreiro H, et al. Spontaneous thrombosis of a gastroduodenal artery pseudoaneurysm manifesting as a subepithelial lesion. **Rev Gastroenterol México Engl Ed**. 2018;83:354–356.
14. Carrafiello G, Laganà D, Recaldini C, et al. Combined percutaneous thrombin injection and endovascular treatment of gastroduodenal artery pseudoaneurysm (PAGD): case report. **Emerg Radiol**. 2007;14:51–54.



15. Habib N, Hassan S, Abdou R, et al. Gastroduodenal artery aneurysm, diagnosis, clinical presentation and management: a concise review. **Ann Surg Innov Res.** 2013;7:4.
16. Burke JW, Erickson SJ, Kellum CD, et al. Pseudoaneurysms complicating pancreatitis: detection by CT. **Radiology.** 1986;161:447–450.
17. Kasirajan K, Greenberg RK, Clair D, et al. Endovascular management of visceral artery aneurysm. **J Endovasc Ther.** 2001;8:150-155.
18. Gupta V, Irrinki S, Sakaray YR, et al. Treatment strategies for bleeding from gastroduodenal artery pseudoaneurysms complicating the course of chronic pancreatitis-A case series of 10 patients. **Indian J Gastroenterol Off J Indian Soc Gastroenterol.** 2018;37:457–463.
19. Hsu J-T, Yeh C-N, Hung C-F, et al. Management and outcome of bleeding pseudoaneurysm associated with chronic pancreatitis. **BMC Gastroenterol.** 2006;6:3.
20. Galanakis V. Pseudoaneurysm of the gastroduodenal artery: an unusual cause for hyperamylasaemia. **BMJ Case Rep.** 2018;2018.
21. Santos-Rancaño R, Antona EM, Montero JVM, et al. A Challenging Case of a Large Gastroduodenal Artery Pseudoaneurysm after Surgery of a Peptic Ulcer. **Case Reports in Surgery.** 2015;2015:370937.
22. Elazary R, Abu-Gazala M, Schlager A, et al. Therapeutic angiography for giant bleeding gastroduodenal artery pseudoaneurysm. **World J Gastroenterol.** 2010;16:1670–1672.
23. Geoghegan T, Tuite D, McAuley G, et al. Percutaneous thrombin injection for the treatment of a post-pancreatitis pseudoaneurysm of the gastroduodenal artery. **Eur Radiol.** 2004;14:2144–2145.
24. Klauß M, Heye T, Stampfl U, et al. Successful arterial embolization of a giant pseudoaneurysm of the gastroduodenal artery secondary to chronic pancreatitis with literature review. **J Radiol Case Rep.** 2012;6:9–16.
25. Volpi MA, Voliovici E, Pinato F, et al. Pseudoaneurysm of the Gastroduodenal Artery Secondary to Chronic Pancreatitis. **Ann Vasc Surg.** 2010;24:1136.e7-1136.e11.
26. Dirks K, Schuler A, Lutz H, et al. An unusual cause of gastrointestinal hemorrhage: pseudoaneurysm of the gastroduodenal artery in chronic pancreatitis. **Z Gastroenterol.** 1999;37:489–493.

27. Germanos S, Soonawalla Z, Stratopoulos C, et al. Pseudoaneurysm of the Gastroduodenal Artery in Chronic Pancreatitis. **J Am Coll Surg.** 2009;208:316.
28. Jovanović M, Colović R, Grubov N, et al. Pseudoaneurysm of gastroduodenal artery due to duodenal ulcer causing jaundice and interstitial pancreatitis but not bleeding. **Srp Arh Celok Lek.** 2004;132:108–111.
29. Vizsy L, Beznicza H, Petoházi A, et al. Successfully operated ruptured gastroduodenal artery pseudoaneurysm. **Orv Hetil.** 2006;147:1279–1281.
30. Singh O, Gupta SS, Raikwar RS, et al. A rare case of ‘Spontaneous rupture of partially thrombosed pseudoaneurysm of gastroduodenal artery associated with chronic pancreatitis’. **Indian J Surg.** 2009;71:282–283.
31. Yen Y-T, Lai H-W, Lin C-H, et al. Endovascular Salvage for Contained Rupture of Gastroduodenal Artery Aneurysm Presented with Obstructive Jaundice. **Ann Vasc Surg.** 2015;29:1017.e1-1017.e5.
32. Akbari K, Wood C, Ahmad N, et al. Gastroduodenal artery aneurysm. **BMJ Case Rep.** 2014;2014.
33. Androulakis Z, Paspatis G, Hatzidakis A, et al. Gastric outlet obstruction caused by a giant gastroduodenal artery aneurysm: a case report. **Eur J Gastroenterol Hepatol.** 2001;13:59–61.
34. Kueper MA, Ludescher B, Koenigsrainer I, et al. Successful coil embolization of a ruptured gastroduodenal artery aneurysm. **Vasc Endovascular Surg.** 2007;41:568-571.
35. Lykoudis PM, Stafyla VK, Koutoulidis V, et al. Stenting of a gastroduodenal artery aneurysm: report of a case. **Surg Today.** 2012;42:72–74.
36. Marjanovic IR, Jevtic M, Misovic S, et al. Endovascular Reconstruction of Giant Gastroduodenal Artery Aneurysm With Stent Graft: Case Report. **Vasc Endovascular Surg.** 2010;44:392-394.
37. Piffaretti G, Tozzi M, Carrafiello G, et al. A case of gastroduodenal artery aneurysm in a HIV-positive patient treated by combined percutaneous thrombin injection and endovascular coil embolization. **J Cardiovasc Surg.** 2008;49:659–661.
38. Savage J, Hsee L. Spontaneous gastroduodenal artery aneurysm rupture in acute surgery. **N Z Med J.** 2012;125:155-157.
39. Sun MS, Wang HP, Lin JT . Gastroduodenal artery aneurysm mimicking a bleeding submucosal tumor. **Gastrointest Endosc.** 2001;54:621.