Jefferson
Thomas Jefferson University
HOME OF SIDNEY KIMMEL MEDICAL COLLEGE

The Medicine Forum

Volume 3 Article 5

2001

A Case of Hypercalcemia

Daniel Lin
Thomas Jefferson University

Follow this and additional works at: https://jdc.jefferson.edu/tmf

Part of the Endocrinology, Diabetes, and Metabolism Commons

Let us know how access to this document benefits you

Recommended Citation
Lin, Daniel (2001) "A Case of Hypercalcemia," *The Medicine Forum*: Vol. 3, Article 5.
DOI: https://doi.org/10.29046/TMF.003.007
Available at: https://jdc.jefferson.edu/tmf/vol3/iss1/5

This Article is brought to you for free and open access by the Jefferson Digital Commons. The Jefferson Digital Commons is a service of Thomas Jefferson University's Center for Teaching and Learning (CTL). The Commons is a showcase for Jefferson books and journals, peer-reviewed scholarly publications, unique historical collections from the University archives, and teaching tools. The Jefferson Digital Commons allows researchers and interested readers anywhere in the world to learn about and keep up to date with Jefferson scholarship. This article has been accepted for inclusion in The Medicine Forum by an authorized administrator of the Jefferson Digital Commons. For more information, please contact: JeffersonDigitalCommons@jefferson.edu.

A Case of Hypercalcemia

Daniel Lin, MD, Resident, Department of Internal Medicine 200-2003

A 79-year-old man with a past medical history of diet-controlled type 2 diabetes mellitus, hypertension, and chronic lower extremity venous stasis ulcers requiring two skin grafts was admitted to the hospital due to dehydration. He was in his usual state of health of intermittently being wheelchair bound due to leg ulcers until four days earlier, when he accidentally spilled hot tea on his left arm while in the kitchen. In his attempt to maneuver the wheelchair away from the spill, the wheelchair turned over, pinning him on the floor and against the cabinets. He remained in that position for four days until he was found by a neighbor in semi-conscious state lying in urine and feces. The patient was agitated and combative when aroused and was transported to the emergency room.

Upon questioning in the emergency room, the patient stated that he had not hit his head during the fall, but did hurt his back. He denied any recent fevers, chills, sweats, weight loss, chest pain, shortness of breath, abdominal pain, dysuria, hematuria, nausea, vomiting, diarrhea, or melena. The patient reported that his diabetes and hypertension had been well controlled, however, he does not check his blood glucose or blood pressure at home. The patient denied any allergies to medications. His medication list included hydralazine, glipizide, chlorthalidone, and a multivitamin every day. He denied any tobacco use, as well as illicit drug use. He consumed minimal alcohol. The patient had no knowledge of his family medical history.

On physical examination, the patient appeared confused and mildly uncomfortable. His temperature was 96.5 degrees Fahrenheit, blood pressure of 172/90 mm/Hg, pulse of 74 bpm, and respiratory rate of 20. His oxygen saturation was 96 % on room air. Pupils were equal and reactive and no nystagmus was seen. Cardiac and abdominal exam were normal. There were decreased breath at the bases bilaterally, but with poor inspiratory effort. There was mild gynecomastia, but no lymphadenopathy. A stage I sacral decubitus ulcer measuring 2 cm by 4 cm was noted. There was no costovertebral angle tenderness, however, there was lumber spine tenderness. Lower extremities were without clubbing or edema, with strong distal pulses. Skin exam revealed venous stasis changes of the lower extremities. Prior skin graft donor sites were seen on the anterior thighs bilaterally. Neurologic examination was difficult due to the patient's poor cooperative effort. Cranial nerve exam revealed weak abduction of the left eye. His speech was slurred. Muscle tone was noted to be slightly rigid, with generalized 4/5 strength. The patient had cogwheeling of his upper extremities as well as a resting tremor. Sensation was intact. Biceps and patellar reflexes were 1+ bilaterally, however four beat clonus was appreciated in the feet. Babinski reflexes were absent. Gait could not be assessed. Mini-mental status examination with a score of 17/30 was obtained. The patient was unable to perform serial sevens, recall three words after three minutes, and write or draw sufficiently.

Laboratory work-up revealed an elevated white blood cell count (WBC) of 16,000 ml^3, with a neutrophil count of 96%. His hemoglobin, platelet count, prothrombin time and partial thromboplastin time were all within normal limits. His blood urea nitrogen (BUN) was elevated to 57 mg/dL and had a creatinine of 1.9 mg/dL. Total calcium was elevated at 14.2 mg/dL. Intact parathyroid hormone (PTH) was low at 6 pg/ml, and PTH-related peptide (PTH-rP) was elevated at 3.6 pmol/L. His CPK was elevated to 3,555 IU/L, with a CK-MB of 24.2 ng/ml. Myoglobin was also elevated at 9,771 ng/ml. His AST was high at 123 IU/L, with the remainder of the liver function tests being normal. Urinalysis showed 2+ blood, 1+ ketones, 2 white blood cells/hpf, 5 red blood cells/hpf, 2+ bacteria. The remainder of his chemistries, TSH, and PSA were normal

Posteroanterior and lateral chest radiographs revealed a right subpulmonic pleural effusion. Spinal series radiographs revealed degenerative disk disease without fractures. A computed tomographic (CT) scan of the head without intravenous contrast revealed disproportionate enlargement of the ventricles as compared to the sulci, and mild general volume loss. No hemorrhage, infarct, or other acute changes were seen. A CT scan of the thorax without intravenous contrast was performed (Figures 1 and 2), which demonstrated a right pleural effusion, bibasilar atelectasis, and multiple bilateral lung nodules 5 to 10 mm seen in all lung lobes. There were no enlarged hilar or mediastinal lymph nodes, but there was some right hilar nodal calcification. A nodular infiltrative soft

(Continued on next page)

(Continued from previous page)

tissue mass was seen in the superior aspect of the right retroperitoneal space, involving both the right adrenal gland and kidney. The mass extended into the right perirenal space, inferior right pleural space, and posterior right flank. The spleen, liver, and left adrenal gland were unremarkable. No lytic bone lesions were observed. The left kidney was not visualized.

The patient was treated for acute symptomatic hypercalcemia. An ultrasound guided fine needle aspiration of the right kidney mass was performed. Thirty milliliters of bloody fluid was obtained. Microscopic examination of the specimen revealed malignant neoplastic epithelial cells with focal spindle features consistent with renal cell carcinoma. He was diagnosed with Stage IV renal cell carcinoma with mixed with sarcomatoid features.

Discussion

The differential diagnosis for this patient was initially made for acute symptomatic hypercalcemia. When the CT scan of the thorax was performed the differential diagnosis was narrowed to include concomitant retroperitoneal and pulmonary masses, although the possibility the masses were unrelated to the hypercalcemia could not be disregarded.

Hypercalcemia can result from many causes (Table 1). In the general population primary hyperparathyroidism and malignancy are by far the most common causes of hypercalcemia. Given our patient's demographics, history, and physical exam, we can eliminate many of the possibilities. The most likely diagnoses are sarcoidosis and malignancy.

The patient had no significant history suggesting an inherited disorder. There was also no history or findings of paradoxical hypertension, hypotension, sweating, palpitations, or tachycardia to suggest thyrotoxicosis, pheochromocytomas, or acute adrenal insufficiency. Also, there was no evidence to suggest an infectious granulomatous disease, such as fever and lymphadenopathy. Primary hyperparathyroidism was also discounted given the low concentration of intact parathyroid hormone.

The finding of an elevated PTHrP, as well as the lack of excess antacid ingestion history made milk-alkali syndrome unikely in this patient. Hypercalcemia caused by immobilization often manifests after four weeks of immobilization, but can be seen as early as ten days[2]. It would be unusual to see the degree of hypercalcemia in our patient after immobilization for four days.

Occult sarcoidosis was initially a possibility in this patient with pulmonary nodules, retroperitoneal mass, and hypercalcemia. Chest radiograph and CT of the thorax did not reveal hilar adenopathy, though this finding would be consistent with stage three disease. Sarcoidosis can present as a focal mass anywhere in the body, and the retroperitoneal

Figure 1. CT Thorax without IV contrast. Note the right pleural effusion and multiple enhancing pulmonary nodules (arrows).

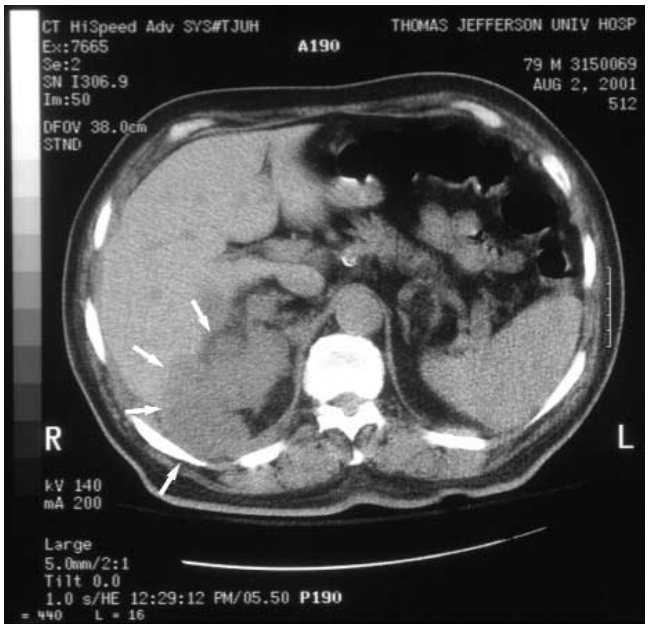

Figure 2. CT Thorax without IV contrast. Note the large homogenous mass (arrows) in the right retroperitoneum involving the adrenal and kidney. It extends into the right pleural space.

http://jdc.jefferson.edu/tmf/vol3/iss1/5
DOI: https://doi.org/10.29046/TMF.003.007

(Continued from previous page)

Table 1. Differential Diagnosis of Hypercalcemia

- Primary hyperparathyroidism
  - Sporadic (adenoma, hyperplasia, carcinoma)
  - Familial (isolated, cystic, MEN I/II)
- Malignancy
  - PTHrP production
  - 1,25 dihydroxyvitamin D production
  - Miscellaneous factor production (cytokines, growth factors)
- Vitamin D disorders
  - Exogenous vitamin D toxicity
  - Endogenous vitamin D production
    - Williams syndrome
    - Granulomatous disease
      - Sarcoidosis
      - Tuberculosis
      - Histoplasmosis
      - Coccidiomycosis
      - Leprosy
    - Lymphoma
- Nonparathyroid disorders
  - Thyrotoxicosis
  - Pheochromocytoma
  - Acute adrenal insufficiency
  - VIPoma
- Medications
  - Thiazides
  - Lithium
  - Estrogens/anti-estrogens/testosterone
  - Milk-alkali syndrome
  - Vitamin A toxicity
- Familial hypocalciuric hypercalcemia
- Immobilization
- Parenteral nutrition
- Aluminum excess
- Renal disease

mass could have represented this. However, 90% of patients develop lymphadenopathy, which was not found in this patient[3]. Sarcoidosis can cause hypercalcemia in approximately 10% of patients by renal overproduction of 1,25-dihydroxyvitamin D by macrophages in sarcoid granulomas[4]. There have been case reports of PTHrP production by sarcoid granulomas, but these are by far the exception rather than the rule[5]. Thus while the finding of suppressed PTH would have been expected, the finding of elevated PTHrP in the serum was unexpected, and pointed against a diagnosis of sarcoidosis.

Given the serologic laboratory values for this patient, he has humoral hypercalcemia of malignancy (HHM), which results from secretion of a humoral factor that mimics some or all of the effects of PTH, the most common being PTHrP[6]. Aside from parathyroid carcinoma, ectopic PTH production is extremely rare. Malignancies that are associated with HHM include multiple myeloma, lymphoma, renal cell cancer, squamous cell carcinomas of any organ, transitional cell carcinoma, and ovarian cancer.

Diseases with ectopic production of PTHrP, such as adenocarcinoma of the lung, squamous cell carcinoma, and renal cell cancer, are expected to have hypercalcemia with suppressed PTH levels, as well as low levels of 1,25-dihydroxyvitamin D since PTHrP does not stimulate renal production of 1,25-dihydroxyvitamin D through renal 1-hydroxylase[7]. This is in contrast to primary hyperparathyroidism, where high levels of PTH and 1,25-dihydroxyvitamin D are expected. PTHrP causes hypercalcemia by increasing bone resorption and increasing urinary distal tubular calcium reabsorption[8].

The severity of hypercalcemia should be judged by its concentration and clinical manifestations. Since clinically significant hypercalcemia is associated with an elevated ionized calcium concentration, it is best to measure and follow ionized serum calcium concentrations. If total serum calcium measurements are used, formulas are available to correct serum calcium concentrations for albumin levels. Hypoalbuminemia will result in underestimation of the severity of hypercalcemia, whereas paraproteinemia will result in overestimation of the severity of hypercalcemia[9].

Neurologic symptoms include altered mental status, weakness, and decreased deep tendon reflexes. Mental status changes range from decreased concentration and personality changes; to hallucinations and psychosis; to lethargy, confusion, stupor, and coma. Localizing neurologic deficits are not typical of hypercalcemia. Treatment of hypercalcemia results in reversal of neurologic symptoms within several days to weeks. Unless the total serum calcium concentration is above 14 mg/dL, or other

(Continued on next page)

(Continued from previous page)

system manifestations of hypercalcemia are present, a workup for mental status change should be done[10].

Treatment of hypercalcemia is fourfold: correct dehydration, increase renal calcium excretion, decrease bone resorption, and correct the underlying disorder. Therapy for hypercalcemia should always begin with infusion of saline. The restoration of extracellular volume will aid renal excretion of calcium. In addition, all diuretics should be held, especially thiazides. Loop diuretics and ethacrynic acid should be held until the patient is felt to be euvolemic, as both delivery of the diuretic and calcium to the ascending limb requires an adequate glomerular filtration rate (GFR).

Bisphosphonates bind to hydroxyapatite in bone, prevent its resorption, and inhibit the function of osteoclasts. Pamidronate is commonly used at Thomas Jefferson, and doses vary from 60 to 90 mg intravenously over 4 hours or 24 hours. Serum calcium generally decreases to normal levels with 5 to 7 days and remain normal for a month if the underlying disorder is not treated. Adverse reactions from pamidronate include low grade fever, transient leukopenia, and nephrotoxicity from precipitated calcium pamidronate if infused over less than 4 hours.

Other medical therapies for acute hypercalcemia include glucocorticoids plicamycin, gallium nitrate, and calcitonin. Plicamycin and gallium nitrate are limited by their adverse effects. Calcitonin provides rapid but short-lived reduction of serum calcium concentration, and so is often used in urgent situations, as well as in severe metastatic bony pain. If possible, patients should ambulate, as immobilization causes hypercalcemia as well. In our patient it is expected that his serum calcium will rise to hypercalcemic levels over time, since PTHrP is not affected by calcium lowering therapy[11].

Malignant tumors of the kidney account for approximately 2-3% of all cancers. Among kidney neoplasms, renal cell carcinoma accounts for 70-85% of the total. Renal cell carcinoma is twice as common in males than females. The average age of diagnosis is sixty. The incidence of renal cell carcinoma has been rising, but the cause for this increase is not yet known. Although almost half of all cases are diagnosed incidentally during ultrasonography[12], it is known that the increasing incidence is not entirely accounted for by increasing use of imaging modalities[13].

Several studies have examined risk factors for developing renal cell carcinoma. The major risk factors consistently shown to increase risk of renal cell cancer are tobacco use and obesity[2]. Risk from tobacco use is dose dependent and declines with years of smoking cessation, such that there is a 20-30% risk reduction after 10-15 years of cessation. Body mass index (BMI) above the fourth quartile carries an odds ratio of 1.1-4.6. Other factors that have inconsistently been associated with renal cell cancer are hypertension, diuretic use, renal disease, and occupational exposure.

Genetic susceptibility is also a well-documented association[14]. Familial forms all follow a dominant pattern of inheritance and manifest earlier in life. Von Hippel-Lindau (VHL) disease, tuberous sclerosis, and autosomal dominant polycystic kidney disease (ADPKD) carry increased risk of developing renal cell carcinoma. There are also nonsyndromic forms of renal cell cancer that are seen with mutations of chromosome 7, as well as translocations between chromosomes 3 and 2, 6, 8, or 11.

The presentation of renal cell carcinoma is quite variable, and has therefore been called the "internist's tumor."[15] Signs and symptoms are often absent until the cancer has become large or metastatic. Hematuria, abdominal pain, and a palpable flank mass are the three most common presentations, seen in 50%, 40%, and 30% of patients, respectively. However, the triad is only seen in 10% of patients. Anemia and hypertension are sometimes seen as well. Other symptoms are constitutional and nonspecific, including fevers, sweats, weight loss, and malaise. Obstructive phenomena may be seen, such as varicoceles due to testicular vein obstruction. Renal cell carcinoma may metastasize anywhere in the body. It can present as a painless mass in the vaginal wall, or thyroid. It could also present with visual disturbances or epistaxis from metastasis to the orbit or nasal structures, respectively.

There are numerous paraneoplastic syndromes seen in renal cell carcinoma (Table 2)[16]. The presence of a paraneoplastic syndrome does not indicate metastatic disease. Renal cell carcinomas can produce a variety of compounds causing the different metabolic syndromes. Hypercalcemia is the most common metabolic syndrome seen in renal cell carcinoma, seen in 3% of patients with stage 1 disease, and up to 18.9% of patients with stage 4

(Continued on next page)

h t://jdc.jefferson.edu/tmf/vol3/iss1/5
D https://doi.org/10.29046/TMF.003.007

(Continued from previous page)

disease. The mechanism of hypercalcemia is production of PTHrP by the cancer, causing bone resorption and renal calcium reabsorption.

The diagnosis of renal cell carcinoma begins with the identification of a renal mass on an imaging study. Unless there is strong suspicion that the renal mass is secondary to another disease, it should be treated as malignant renal cell cancer. After further imaging has revealed the lack of metastatic foci, surgical resection is often recommended because of the definite risk of metastasis if the mass were malignant and was observed. If it is uncertain whether a renal mass represents renal cell carcinoma or another process such as lymphoma or recurrence of a prior cancer, percutaneous aspiration offers a method of diagnosis. If imaging is suspicious for metastatic foci, some authors advocate fine needle aspiration of metastasis to aid with staging[17].

Because of the highly variable presentation and silent progression of renal cell carcinoma, only 40% of patients have disease confined to the kidney, and up to 30% of patients present with metastatic disease. Common sites of metastasis are lung, bone, liver, adrenal, and brain, but renal cell carcinoma may be found anywhere. Prognosis with metastatic disease is dismal, with the survival curve declining rapidly until 12 to 18 months, reaching a plateau, and then slowly declining for 5 to 10 years.

As with most other cancers, the most important prognostic factor in renal cell carcinoma is stage. Five year survival for stage 1 and 2 disease are 60 to 90% and 50 to 60%, respectively. Five year survival for stage 3 and 4 disease are 20 to 40% and 0 to 10%, respectively. Other prognostic factors can be divided into tumor-related and patient-related factors[18]. Other tumor-related factors include grade and proliferative activity. Patient-related prognostic factors include weight loss, malaise, erythrocyte sedimentation rate (ESR), anemia, and hypercalcemia. Hypercalcemia has also been shown to negatively affect prognosis, but only in stage 4 disease[19].

Though uncommon, few patients follow a different natural history than the progressive decline often seen. Some patients experience complete remissions of varying lengths of time, from 4 to 120 months. Up to seven percent report spontaneous regression of metastases following primary tumor resection[20], although regression without surgery has been reported. Spontaneous regression is more commonly seen with lung metastases.

Table 2. Paraneoplastic Syndromes in Renal Cell Carcinoma

Metabolic syndromes
Hypercalcemia
Renin secretion
Gonadotropin production
Prolactin production
Enteroglucagon production
Insulin production
Prostaglandin production
Hyperglycemia
Hepatic syndromes
Stauffer syndrome
Liver granulomas
Neuromuscular syndromes
Polyneuromyopathy
Polymyositis
Myopathy
Hematologic syndromes
Anemia
Erythrocytosis
Leucocytosis
Thrombocytosis
Coagulopathy
Amyloidosis
Autoimmune hemolysis
Renal syndromes
Membranous glomerulonephritis
Minimal change glomerulonephritis
Cutaneous syndromes
Dermatitis herpetiformis
Leukocytoclastic vasculitis
Hypertrichosis lanuginosa acquisita

Local disease is always treated with surgical resection. Radical nephrectomy, consisting of resection of the kidney, perirenal fat, and ipsilateral adrenal gland continues to be the recommended treatment in nonmetastatic disease. Lymphadenectomy is often done to provide information regarding local spread of the cancer. Partial nephrectomy may be an option in patients with bilateral renal involvement or those with an anatomically or func-

(Continued on next page)

(Continued from previous page)

tionally solitary kidney that is affected. Surgery is rarely indicated in metastatic disease unless the goal is to improve quality of life or treat local symptoms.

Treatment of metastatic disease is difficult, as hormonal and chemotherapeutic agents are ineffective. Interleukin-2 (IL-2) is currently the only Food and Drug Administration (FDA) approved systemic therapy for metastatic renal cell carcinoma. However, trials with IL-2 are still ongoing. It is anticipated that of complete responders and partial responders, 60% and 10% will remain in remission after 10 years of follow up, respectively[21,22]. It must be noted that the majority of patients did not respond to IL-2, and were exposed to the adverse effects of IL-2. The combination of surgical and systemic medical therapy remains to be studied, but preliminary results show that a multidisciplinary approach may be justified.

References

1. Chan. Differential Diagnosis of Hypercalcemia. Curr Probl Surg 1997; 34(6):445-523.
2. Gopal H. Symptomatic Hypercalcemia of Immobilization in a Patient with End-Stage Renal Disease. Am J Kid Dis 2000; 35(5):969-72.
3. Newman L. Sarcoidosis. NEJM 1997; 336(17):1224-34.
4. Sharma O. Vitamin D, Calcium, and Sarcoidosis. Chest 1996; 109(2):535-539.
5. Zeimer H. Parathyroid-Hormone-Related Protein in Sarcoidosis. Am J Pathol 1998; 152(1):17-21.
6. Sandhu D. Humoral Hypercalcemia in Renal Carcinoma Due to Parathyroid Homrmone Related Protein. Brit J Urol 1993; 72:848-50.
7. Walther M. Hypercalcemia in Patients with Metastatic Renal Cell Carcinoma: Effect of Nephrectomy and Metabolic Evaluation. J Urol 1997; 158:733-9.
8. Mundy G. Pathophysiology of Cancer-Associated Hypercalcemia. Semin Oncol 1990; 17(2S5):S10-S15.
9. Bajorunas D. Clinical Manifestations if Cancer-Related Hypercalcemia. Semin Oncol 1990; 17(2S5):16-25.
10. Bilezikian J. Management of Acute Hypercalcemia. NEJM 1992 326(18):1196-1203.
11. Schilling T. Parathyroid Hormone Related Protein (PTHrP) Does Not Regulate 1,25-Dihydroxyvitamin D Serum Levels in Hypercalcemia of Malignancy. J Clin Endocrinol Metab 1993; 76(3):801-3.
12. Dhote R. Risk Factors for Adult Renal Cell Carcinoma: A Systematic Review and Implications for Prevention. BJU Int 2000; 86:20-7.
13. McLaughlin J. Epidemiologic Aspects of Renal Cell Carcinoma. Semin Oncol 2000; 27(2):115-23.
14. Bonsib S. Risk and Prognosis in Renal Neoplasms. Urol Clin of North America 1999; 26(3):643-60.
15. Motzer R. Renal-Cell Carcinoma. NEJM 1996; 225(12):865-75.
16. Papac R. Renal Cell Carcinoma. Am J Clin Oncol 1999; 22(3):223-31.
17. Nicol D. Issues in the Diagnosis of Renal Cell Carcinoma. BJU Int 2000; 86:298-303.
18. Rini B. Prognostic Factors in Renal Cell Carcinoma. Semin Oncol 2000; 27(2):213-20.
19. Fahn H. The Incidence and Prognostic Significance of Humoral Hypercalcemia in Renal Cell carcinoma. J Urol 1991; 145:248-50.
20. Young R. Metastatic Renal-Cell Carcinoma: What Causes Occasional Dramatic Regressions? NEJM 1998; 338(18):1305-7.
21. Figlin R. Renal Cell Carcinoma: Current Status and Future Plans. Cancer J 2000; 6(S1):S52-S54.
22. Fisher R. Long-Term Survival Update for High-Dose Recombinant Interkeukin-1 in Patients with Renal Cell Carcinoma. Cancer J 2000; 6(S1):S55-S57.

https://jdc.jefferson.edu/tmf/vol3/iss1/5
DOI: https://doi.org/10.29046/TMF.003.007