

3-1-2023

## A Case of Malignant Atrophic Papulosis with Septic Complications

Mengjiao Tao

Kaiwen Zhuang

Yaowen Jiang

Wayne Bond Lau

*Thomas Jefferson University*

Yarong He

Follow this and additional works at: <https://jdc.jefferson.edu/emfp>



Part of the [Emergency Medicine Commons](#)

[Let us know how access to this document benefits you](#)

---

### Recommended Citation

Tao, Mengjiao; Zhuang, Kaiwen; Jiang, Yaowen; Lau, Wayne Bond; and He, Yarong, "A Case of Malignant Atrophic Papulosis with Septic Complications" (2023). *Department of Emergency Medicine Faculty Papers*. Paper 222.

<https://jdc.jefferson.edu/emfp/222>

This Article is brought to you for free and open access by the Jefferson Digital Commons. The Jefferson Digital Commons is a service of Thomas Jefferson University's [Center for Teaching and Learning \(CTL\)](#). The Commons is a showcase for Jefferson books and journals, peer-reviewed scholarly publications, unique historical collections from the University archives, and teaching tools. The Jefferson Digital Commons allows researchers and interested readers anywhere in the world to learn about and keep up to date with Jefferson scholarship. This article has been accepted for inclusion in Department of Emergency Medicine Faculty Papers by an authorized administrator of the Jefferson Digital Commons. For more information, please contact: [JeffersonDigitalCommons@jefferson.edu](mailto:JeffersonDigitalCommons@jefferson.edu).



# A case of malignant atrophic papulosis with septic complications

Mengjiao Tao<sup>1\*</sup>, Kaiwen Zhuang<sup>2</sup>, Yaowen Jiang<sup>3</sup>, Bond Lau Wayne<sup>4</sup>,  
Yarong He<sup>1,3</sup>

<sup>1</sup>West China School of Medicine, Sichuan University, Chengdu, China

<sup>2</sup>Department of Dermatology and Venerology, West China Hospital, Sichuan University, Chengdu, China

<sup>3</sup>Department of Emergency Medicine, Emergency Medical Laboratory, West China Hospital, Sichuan University, Chengdu, China

<sup>4</sup>Department of Emergency Medicine, Thomas Jefferson University, Philadelphia, PA, USA

Dear Editor,

We would like to share the interesting case of a 38-year-old woman who presented to the emergency department of an outside hospital with a rash accompanied by severe abdominal pain, diarrhea, and fever. The rash had been intermittent for 2 years, was located over the neck, trunk, arms, and legs, and was not accompanied by tenderness or itching. Skin biopsy and pathological examination performed 1 year prior showed partial epidermal atrophy, local fibrous hyperplasia and hyaline degeneration of the dermis, and multiple mucus deposits between surrounding collagen, at which point a diagnosis of Degos disease was made. The patient experienced prominent recurrence of the rash in the preceding 20 days. The patient denied cough, sputum, headache, paralysis, or paresthesia. Based on her history and test results, a diagnosis of malignant atrophic papulosis (MAP) and acute peritonitis with ascites was made at the local hospital. After receiving ceftriaxone and glucocorticoids, her condition did not improve significantly. She was transferred to our emergency department. The patient was conscious with a Glasgow Coma Scale of 15 and her vital signs were temperature 38.9 °C, heart rate 137 beats/min, respiratory rate 33 breaths/min, blood pressure 107/73 mmHg, and pulse oximetry 99% on room air. Physical examination showed generalized, painless, nonpruritic, ring-shaped pigmented plaques, the majority of which were crusted over, particularly the scattered abdominal lesions (Fig. 1).

The patient's white blood cell count was elevated ( $11.35 \times 10^9/L$ ), as was procalcitonin (0.51 ng/mL). Chest and abdominal computed tomography revealed a thickened intestinal wall, swollen mesentery, ascites, bilateral pleural effusion, and diffuse bilateral pulmonary consolidation (Fig. 2). The patient was COVID-19 negative. A peripheral smear and culture of the patient's abdominal fluid revealed increased mesothelial cells, eosinophils, neutrophils, and lymphocytes, without tumor cells. Blood culture results from the outside hospital were positive for *Enterococcus faecium* and *Enterococcus avium* (received on the 1st day after admission).

The patient's history, physical examination, and blood and culture results suggested a diagnosis of MAP and sepsis from intestinal inflammation with ascites and pneumonia. Methylprednisolone (40 mg/day), heparin (5,000 U/day), and imipenem were immediately initiated. The gastrointestinal (GI) team found no signs of intestinal perforation or necrosis and thus surgery was not recommended. Immunotherapy against C5 (e.g., eculizumab) was refused by the patient and her family. She clinically deteriorated, developing respiratory failure and shock on treatment day 2.

eISSN: 2383-4625

Received: 24 November 2022

Revised: 1 January 2023

Accepted: 1 January 2023

Correspondence to: Yarong He  
Department of Emergency Medicine,  
Emergency Medical Laboratory, West  
China Hospital, Sichuan University,  
No. 37 Guoxue Alley, Wuhou District,  
Chengdu 610041, China  
Email: heyarong321@163.com

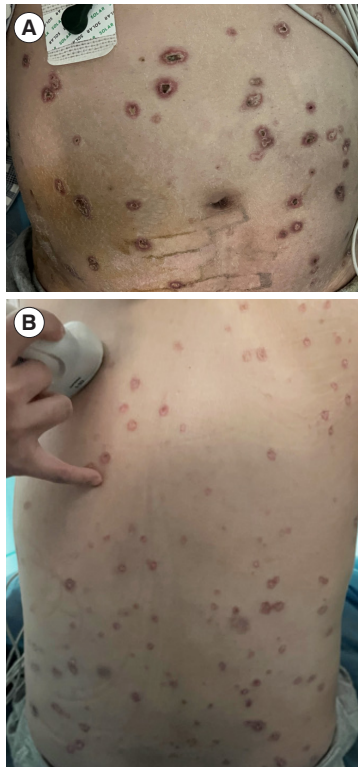
\*Current affiliation: Department of  
Neurology, Children's Hospital of  
Capital Institute of Pediatrics, Beijing,  
China



How to cite this article:

Tao M, Zhuang K, Jiang Y, Wayne BL, He Y.  
A case of malignant atrophic papulosis with  
septic complications. Clin Exp Emerg Med  
2023;10(1):119-121. <https://doi.org/10.15441/ceem.22.402>

This is an Open Access article distributed  
under the terms of the Creative Commons  
Attribution Non-Commercial License (<https://creativecommons.org/licenses/by-nc/4.0/>).

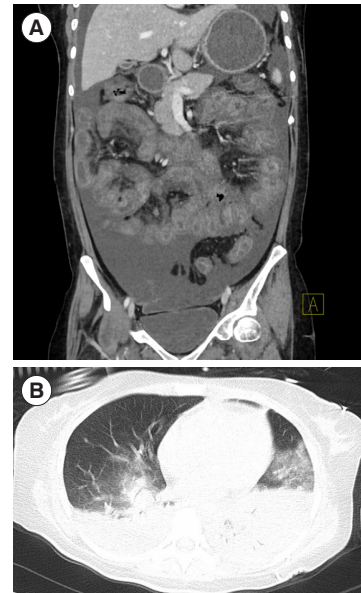


**Fig. 1.** Abdominal and back examination reveals skin lesions at various stages. (A) Anterior trunk. (B) Posterior trunk.

In compliance with her family's wishes, the patient was discharged home without exploratory laparotomy. She expired 2 days later.

This study is in compliance with the Declaration of Helsinki. It was approved by the Human Ethical Committee of West China Hospital of Sichuan University (No. 2,019,201). Written informed consent for publication of the research details and clinical images was obtained from the patient's parents.

Degos disease is a rare, multisystem, immune-related vasculopathy with a cutaneous form (benign atrophic papulosis) and a systemic variant, MAP [1]. Approximately 200 cases have been reported in the literature [2]. Lesions may appear at different stages in various locations, with the trunk being the most common. The GI tract and the central nervous system are most often affected in MAP, though there are reports of possible involvement of other organs, such as the respiratory system and the eyes [3]. Common causes of death include GI perforation leading to hemorrhage and cerebrovascular accidents [3,4]. The underlying mechanisms of the systemic manifestations of Degos disease are not well understood [5]. One hypothesis is that ischemia-induced proliferation and swelling of endothelial cells with dysregulated C5-9 membrane attack complexes may be responsible [6]. The diagnosis of atrophic papulosis is made clinically and supported



**Fig. 2.** Abdominal and chest computed tomography images. (A) A coronal view of the abdomen shows a thickened intestinal wall, swollen mesentery, and ascites. (B) A transverse view of the chest shows bilateral pleural effusion and diffuse bilateral pulmonary consolidation.

by histologic findings [3]. The median survival time of MAP is 2 to 3 years; the 5-year survival rate is < 50% [7]. Intestinal perforations are uncommon in MAP (up to 2.1%) [8]. Almost 60% of cases of death are due to the most common complications, which are peritonitis caused by intestinal perforation and cerebral infarction [9].

In this patient, the diagnosis and treatment of sepsis were delayed given her initial presentation at an outside hospital. We lost the opportunity to administer antibiotics in a timely manner in line with the surviving sepsis campaign [10]. Notably, there is no proven therapy against MAP. Immunosuppressants, anticoagulants, and antiplatelet medications are the first-line therapeutic approach in newly diagnosed patients. Eculizumab is a salvage therapy in critically ill MAP patients [6], but there is questionable mortality benefit in patients with perforation [9]. Our patient's sporadic use of prednisone limited steroidal efficacy against vascular inflammation. It is likely that our patient developed systemic symptoms from destabilized gastrointestinal lesions, leading to peritonitis and sepsis, i.e., life-threatening organ dysfunction caused by a dysregulated host response to infection [10]. Our patient did not undergo laparotomy. Numerous reports have documented patient death from MAP despite surgical interventions [9,11,12]. Therefore, whether surgery is a definitive, efficacious treatment for MAP warrants further exploration.

In conclusion, the prognosis for systemic MAP is poor, especially when the gastrointestinal system is involved. No therapy

with substantial mortality benefit has been established. Early identification and appropriate sepsis management remain the best practice. Timely medical treatment of MAP and its complications is a significant challenge. Emergency physicians and dermatologists must remain vigilant for serious complications when treating Degos disease, particularly sepsis.

## CONFLICT OF INTEREST

No potential conflict of interest relevant to this article was reported.

## FUNDING

This work was supported by grants received by YH from a project of Science & Technology Department of Sichuan Province (No. 2020YJ0033) and Technology Innovation Project of Key R&D Support Plans of Chengdu Science and Technology Municipality (No. 2021-YF05-01576-SN).

## AUTHOR CONTRIBUTIONS

Conceptualization: MT, YH; Data curation: YH, KZ; Funding acquisition: YH; Investigation: MT, KZ, YH; Resources: MT, KZ, YJ; Supervision: YH, KZ, YJ, BLW; Writing–original draft: MT, KZ, YH; Writing–review & editing: YH, YJ, BLW. All authors read and approved the final manuscript.

## ORCID

Mengjiao Tao	<a href="https://orcid.org/0000-0002-8416-068X">https://orcid.org/0000-0002-8416-068X</a>
Kaiwen Zhuang	Not available
Yaowen Jiang	Not available
Bond Lau Wayne	Not available
Yarong He	<a href="https://orcid.org/0000-0001-5358-4589">https://orcid.org/0000-0001-5358-4589</a>

## REFERENCES

- Stephan C, Kurban M, Abbas O. Dowling–Degos disease: a review. *Int J Dermatol* 2021;60:944–50.
- Tadokoro Y, Kitamura T, Horai T, Miyaji K. Degos disease complicated by constrictive pericarditis in remote phase: a case report. *J Cardiothorac Surg* 2022;17:59.
- Lu JD, Sachdeva M, Silverberg OM, Shapiro L, Croitoru D, Levy R. Clinical and laboratory prognosticators of atrophic papulosis (Degos disease): a systematic review. *Orphanet J Rare Dis* 2021;16:203.
- Rice AS, Zedek D. Malignant atrophic papulosis. StatPearls Publishing; 2022.
- Theodoridis A, Konstantinidou A, Makrantonaki E, Zouboulis CC. Malignant and benign forms of atrophic papulosis (Kohlemeier–Degos disease): systemic involvement determines the prognosis. *Br J Dermatol* 2014;170:110–5.
- Magro CM, Wang X, Garrett–Bakelman F, Laurence J, Shapiro LS, DeSancho MT. The effects of eculizumab on the pathology of malignant atrophic papulosis. *Orphanet J Rare Dis* 2013;8:185.
- Tummidhi S, Nagendran P, Gedela S, Ramani JR, Shankaralingappa A. Degos disease: a case report and review of the literature. *J Med Case Rep* 2020;14:204.
- Vardeh H, Magro CM, Brown L, et al. Gastrointestinal pathology associated with dermatomyositis: presentation of 3 cases and a general review. *AJSP: Rev Rep* 2016;21:293–300.
- Gonzalez Valverde FM, Menarguez Pina F, Ruiz JA, et al. Presentation of Degos syndrome as acute small–bowel perforation. *Arch Surg* 2003;138:57–8.
- Evans L, Rhodes A, Alhazzani W, et al. Surviving Sepsis Campaign: international guidelines for management of sepsis and septic shock 2021. *Crit Care Med* 2021;49:e1063–143.
- Zheng XY, Huang DY, Xin Y, Wang XF. Malignant atrophic papulosis with severe gastrointestinal perforation and omental necrosis: a case report. *J Int Med Res* 2010;38:1164–9.
- Ai W, Liang Z, Li F, Yu H. Degos disease with multiple intestinal perforations: a missed–opportunity case report and literature review. *Front Cardiovasc Med* 2022;9:910288.