

3-1-2024

Midterm Outcomes of Suture Anchor Fixation for Displaced Olecranon Fractures

Michael Gutman
Thomas Jefferson University

Jacob Kirsch
Thomas Jefferson University

Jonathan Koa
Thomas Jefferson University

Mohamad Fares
Thomas Jefferson University

Joseph Abboud
Thomas Jefferson University

Follow this and additional works at: <https://jdc.jefferson.edu/orthofp>



Part of the [Orthopedics Commons](#), and the [Surgery Commons](#)

[Let us know how access to this document benefits you](#)

Recommended Citation

Gutman, Michael; Kirsch, Jacob; Koa, Jonathan; Fares, Mohamad; and Abboud, Joseph, "Midterm Outcomes of Suture Anchor Fixation for Displaced Olecranon Fractures" (2024). *Department of Orthopaedic Surgery Faculty Papers*. Paper 218.
<https://jdc.jefferson.edu/orthofp/218>

This Article is brought to you for free and open access by the Jefferson Digital Commons. The Jefferson Digital Commons is a service of Thomas Jefferson University's [Center for Teaching and Learning \(CTL\)](#). The Commons is a showcase for Jefferson books and journals, peer-reviewed scholarly publications, unique historical collections from the University archives, and teaching tools. The Jefferson Digital Commons allows researchers and interested readers anywhere in the world to learn about and keep up to date with Jefferson scholarship. This article has been accepted for inclusion in Department of Orthopaedic Surgery Faculty Papers by an authorized administrator of the Jefferson Digital Commons. For more information, please contact: JeffersonDigitalCommons@jefferson.edu.



Midterm outcomes of suture anchor fixation for displaced olecranon fractures

Michael J. Gutman, Jacob M. Kirsch, Jonathan Koa, Mohamad Y. Fares, Joseph A. Abboud

Department of Orthopedic Surgery, Rothman Orthopaedic Institute at Thomas Jefferson University Hospitals, Philadelphia, PA, USA

Background: Displaced olecranon fractures constitute a challenging problem for elbow surgeons. The purpose of this study is to evaluate the role of suture anchor fixation for treating patients with displaced olecranon fractures.

Methods: A retrospective review was performed for all consecutive patients with displaced olecranon fractures treated with suture anchor fixation with at least 2 years of clinical follow-up. Surgical repair was performed acutely in all cases with nonmetallic suture anchors in a double-row configuration utilizing suture augmentation via the triceps tendon. Osseous union and perioperative complications were uniformly assessed.

Results: Suture anchor fixation was performed on 17 patients with displaced olecranon fractures. Functional outcome scores were collected from 12 patients (70.6%). The mean age at the time of surgery was 65.6 years, and the mean follow-up was 5.6 years. Sixteen of 17 patients (94%) achieved osseous union in an acceptable position. No hardware-related complications or fixation failure occurred. Mean postoperative shortened disabilities of the arm, shoulder, and hand (QuickDASH) score was 3.8 ± 6.9 , and mean Oxford Elbow Score was 47.5 ± 1.0 , with nine patients (75%) achieving a perfect score.

Conclusions: Suture anchor fixation of displaced olecranon fractures resulted in excellent midterm functional outcomes. Additionally, this technique resulted in high rates of osseous union without any hardware-related complications or fixation failures.

Level of evidence: IV.

Keywords: Olecranon fracture; Suture anchor; Old age; Hardware; Mayo classification

INTRODUCTION

Olecranon fractures in elderly patients can present unique challenges for orthopedic surgeons [1,2]. Nonoperative treatment may be appropriate in carefully selected patients with stable fracture patterns; however, functional outcomes are often modest and may result in compromised independence and functional status [1]. Alternatively, operative intervention has been associated with high rates of reoperation and complications in up to 80%

of elderly patients with displaced olecranon fractures [3-7].

Complications in elderly patients typically result from hardware failure secondary to poor fixation in significantly osteoporotic bone. This can lead to fracture displacement, wound complications, and infection requiring subsequent reoperation. Advances in locking plate technology have improved outcomes compared with tension-band techniques, but adequate fixation in small osteoporotic bone fragments remains challenging [8,9].

Additionally, wound dehiscence and symptomatic hardware

Received: June 22, 2023 Revised: August 1, 2023 Accepted: August 4, 2023

Correspondence to: Joseph A. Abboud

Department of Orthopedic Surgery, Rothman Orthopaedic Institute at Thomas Jefferson University Hospitals, 925 Chestnut St, 5th floor, Philadelphia, PA 19107, USA

Tel: +1-267-339-3738, Fax: +1-267-479-1379, E-mail: abboudj@gmail.com, ORCID: <https://orcid.org/0000-0002-3845-7220>

© 2024 Korean Shoulder and Elbow Society.

This is an Open Access article distributed under the terms of the Creative Commons Attribution Non-Commercial License (<http://creativecommons.org/licenses/by-nc/4.0/>) which permits unrestricted non-commercial use, distribution, and reproduction in any medium, provided the original work is properly cited.

necessitating additional intervention are not uncommon in elderly patients with olecranon fractures treated with a plate [10]. An alternative form of olecranon fracture fixation was described by Bateman et al. [11], which involved transosseous fracture repair with suture anchors. This technique was specifically designed to be utilized with small fracture fragments and, in elderly patients with osteoporotic bone, to mitigate the risk of hardware prominence and fixation failure. No intraoperative complications or reoperations were reported in their initial series of six patients at a mean follow-up of 5 years [11].

We sought to provide an updated clinical series, with a larger population size, younger mean age, and longer follow-up of use of suture anchor fixation in elderly patients with displaced olecranon fractures, and we evaluated the expanding role for this technique in younger patients with small fracture fragments.

METHODS

This study was approved by Institutional Board of Thomas Jefferson University (No. #20E.370). Informed consent was waived for retrospective chart review of the patients but obtained prior to collection of prospective outcomes via questionnaire administration. A retrospective review was performed for all consecutive patients with displaced olecranon fractures treated with suture

anchor fixation at a single institution and with at least 2 years of clinical follow-up. Seventeen consecutive patients with Mayo IIa or IIb olecranon fractures were treated with this technique between January 1, 2006, and November 1, 2018.

Surgical repair was performed acutely in all cases with nonmetallic suture anchors in a double-row configuration utilizing suture augmentation with the triceps tendon as previously described [11]. In brief, two fully threaded 5.5 mm (or 6.5 mm) biocomposite suture anchors (Arthrex) were placed in the cancellous bone of the proximal ulna at the interface closest to the cortical wall (Fig. 1). The two suture anchors were placed in different spots of the ulna, both are hugging the cortical wall as much as possible for proper fixation. The suture limbs were passed parallelly in a transosseous fashion through the proximal fragment and then through the triceps tendon in a Krackow fashion (Fig. 1). The fracture was then reduced, and two 3.0-mm biocomposite PushLock anchors (Arthrex) were placed distally in the ulnar shaft in a transosseous-equivalent fashion (Fig. 1). The reduction was evaluated visually or with ultrasound to ensure there was no step-off. After surgery, patients were placed in a splint at 30° of flexion for 2–3 weeks. If the patients' radiographs demonstrated sustained reduction and progressive healing, occupational therapy was initiated to improve active range of motion with the goal of reaching full flexion and extension at

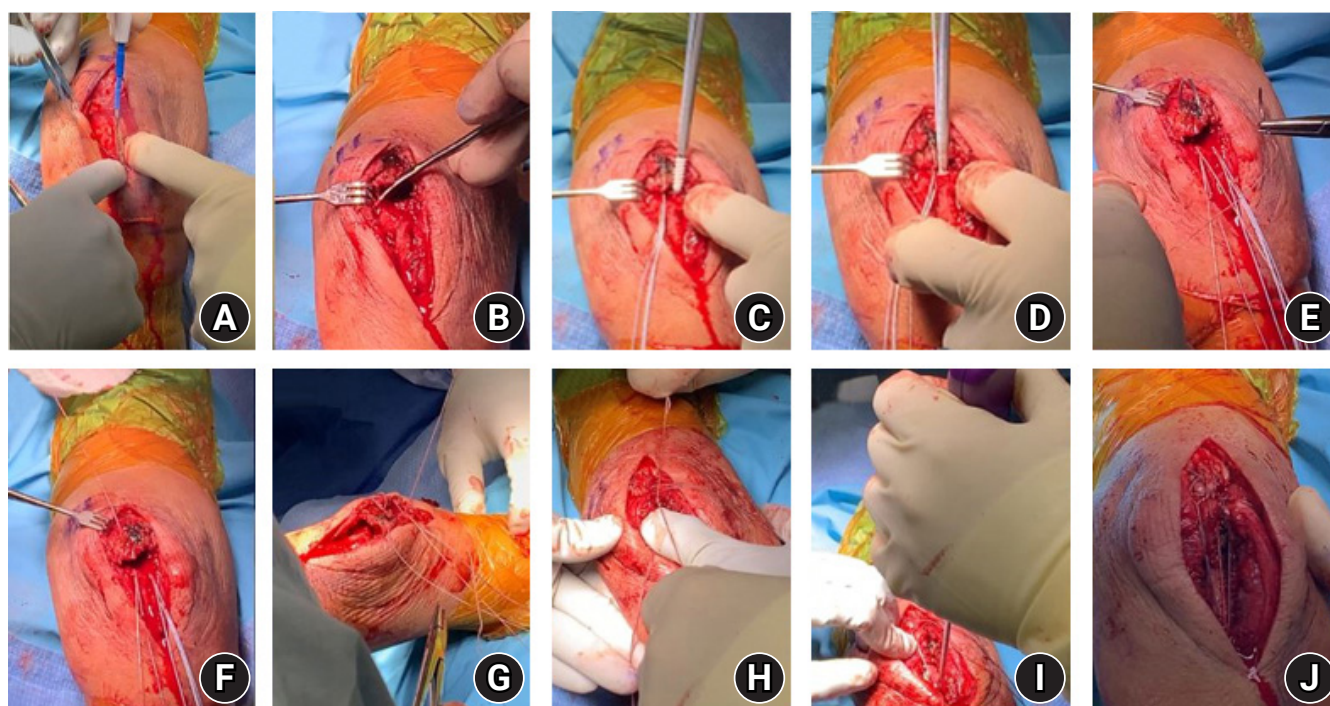


Fig. 1. (A-J) Surgical technique for olecranon fracture fixation using suture anchors.

12–16 weeks postoperatively.

Baseline demographic information was obtained through electronic medical records. Patients underwent radiography preoperatively, immediately postoperatively, and at final follow-up. Radiographs were uniformly assessed by the senior surgeon to evaluate osseous union, adequate reduction, and hardware failure. To assess clinical outcomes, patients were contacted via telephone to complete questionnaires regarding their current elbow function. Clinical outcome questionnaires that were used for this purpose included the shortened disabilities of the arm, shoulder, and hand (QuickDASH) score; the Oxford Elbow Score (OES); and the 12-item short form health survey (SF-12). We used descriptive statistics (mean and range) to report on the demographic characteristics of the patients. We also used descriptive statistics to report on the postoperative clinical and radiographic outcomes of the included patients in the study.

Independent t-tests were conducted to compare outcomes between patients under 60 years old and those aged 60 and above, as well as between different sexes. Statistical analysis was carried out using IBM SPSS software version 25.0 (IBM Corp.).

RESULTS

Seventeen patients with a mean age of 65.6 years (range, 22–88 years) at the time of surgery were analyzed after inclusion and exclusion criteria were applied. Functional outcome scores were collected in 12 patients (Table 1) with a mean clinical follow-up time of 5.6 years (range, 2.0–12.9 years). Two patients were unable to be contacted, one patient declined, one patient had dementia, and one patient was deceased.

Adequate reduction and fixation were achieved for all patients in the operating room. There were no intraoperative complications noted by the senior surgeon (JAA). One patient developed a postoperative infection that required two reoperations. No hardware failure or fixation failure occurred in this series. At final follow-up, 16 of 17 patients (94.1%) achieved osseous union in an acceptable position (Fig. 2) and one patient had partial union. Despite partial osseous union, this patient had excellent functional outcomes (QuickDASH, 4.8; OES, 46) without addi-

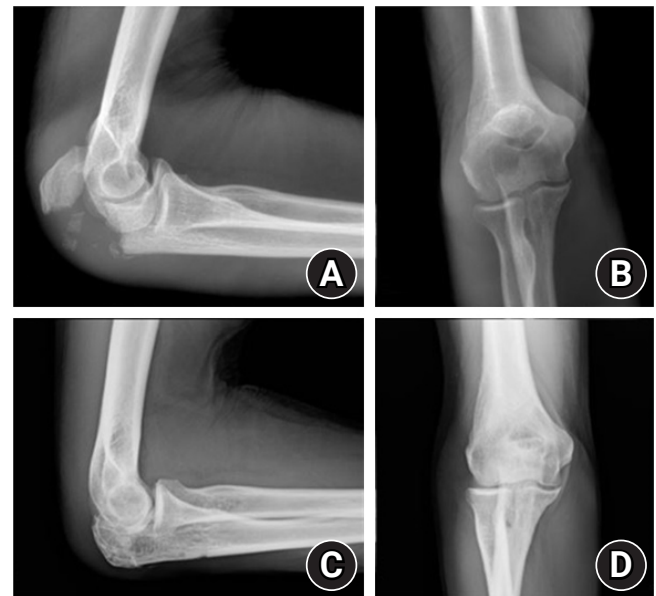

Fig. 2. Preoperative (A) lateral, (B) anteroposterior, and (C, D) postoperative radiographs of a displaced olecranon fracture treated with suture anchor fixation.

Table 1. Demographics and follow-up scores

Patient ID	Sex	Age at OP (yr)	Age at follow-up (yr)	Follow-up time (yr)	OES	QuickDASH score	PCS-12	MCS-12
1	F	62.2	69.6	7.4	48	0	59.5	52.8
2	F	79.6	86.5	7.0	48	25.0	16.2	49.5
3	F	63.7	76.6	12.9	48	4.5	59.5	55.0
4	F	88.8	93.3	4.5	48	4.5	47.6	61.2
5	F	78.2	88.7	10.5	48	0	56.8	55.0
6	F	73.6	80.8	7.2	48	2.3	51.4	61.6
7	F	58.4	63.5	5.1	48	0	55.9	58.7
8	M	85.6	89.2	3.5	46	4.8	51.4	61.6
9	M	22.5	24.9	2.4	48	0	57.8	48.1
10	F	49.2	51.5	2.3	47	2.3	56.2	59.8
11	M	40.0	41.6	2.1	48	2.3	56.8	57.9
12	F	41.9	43.2	2.0	45	0	55.5	57.8
Mean ± SD		65.6 ± 18.7	67.5 ± 22.5	5.6 ± 3.5	47.5 ± 1.0	3.8 ± 6.9	52.0 ± 11.8	56.6 ± 4.6

OP: operation, OES: Oxford Elbow Score, QuickDASH: shortened disabilities of the arm, shoulder, and hand, PCS-12: physical component score of the 12-item short form health survey, MCS-12: mental component score of the 12-item short form health survey, SD: standard deviation.

tional intervention. No patients in this series had any clinical complaints of symptomatic hardware and none required additional secondary intervention for hardware-related issues.

Excellent long-term patient reported outcomes were achieved according to QuickDASH score and OES. The mean OES was 47.5 (range, 45–48), with nine patients (75%) achieving a perfect score. The mean postoperative QuickDASH score was 3.8 (range, 0–25). One patient (Table 1, patient 2) had a higher QuickDASH score of 25. This patient's score reflected her recent hip fracture, which was unrelated to her elbow function. This patient had no complaints regarding her elbow function (OES score of 48). The increased disability caused by the hip fracture limited the patient's ability to perform "recreational activities" and "heavy household chores," which were not solely dependent on upper extremity function [12,13]. Patients younger than 60 years achieved equivalent OES ($P=0.459$) and QuickDASH ($P=0.185$) to those older than 60 years. There was no difference between genders in OES ($P=0.785$) or QuickDASH ($P=0.536$) scores. The mean scores of the SF-12 physical component and mental component were 52 ± 11.8 and 56.6 ± 4.6 , respectively. Patient two achieved the lowest scores in both the physical and mental components of the SF-12 survey (Table 1). This is attributed to her recent hip fracture, which impaired her physical health and emotional outlook.

DISCUSSION

Olecranon fractures can pose significant challenges in elderly patients and patients with small fracture fragments. Suture anchors allow sufficient fixation of small fracture fragments that may be insufficiently captured by a plate while minimizing the chance for hardware-related complications. This study demonstrated excellent subjective and objective outcomes, which appear durable with midterm and long-term follow-up. While previously thought to be ideal for elderly patients with osteoporotic bone, younger patients with small fracture fragments achieved excellent outcomes as well. Suture anchor repair does not require implant removal, which is especially advantageous in the elderly orthopedic population. Furthermore, this technique provides greater biomechanical stability in osteoporotic bone due to the addition of a "triceps offloading suture" [14,15].

Traditionally, surgical treatment options for olecranon fractures included plate fixation and tension-band wiring (TBW) [12,16]. Biomechanical studies have suggested that plate fixation is superior to TBW regarding fracture compression [13,17]. However, clinical outcomes have been comparable between the two methods [8]. Duckworth et al. [8] performed a randomized

control trial comparing plate fixation to TBW, and they found no differences in DASH or Mayo Elbow Score between plate fixation and TBW or nonunion rates. However, the TBW cohort had a significantly higher reoperation rate following symptomatic hardware removal. Although plate fixation is associated with higher cost for primary surgery, the increased rate of hardware removal associated with TBW results in lower long-term costs [8,18]. Previous studies have shown hardware removal of TBW and plate fixation as high as 82% and 62.5%, respectively [6,19].

The high reoperation rate is especially concerning in the elderly population. TBW is associated with high rates of complications, including fixation loss, nonunion, infection, and reoperation for prominent hardware [5]. Plate fixation has demonstrated lower complication rates but is associated with risk for displacement, wound complications, and reoperation [10]. Suture fixation is superior to these other methods due to decreased risk of complications. As seen in our study, reduction was successfully maintained for all patients. The union rate in our study (94%) is similar to that seen by Campbell et al. [10] with plate fixation. Furthermore, a major advantage of suture anchor repair is that the implanted hardware does not require removal. In the setting of simple olecranon fractures, the use of all-suture fixation techniques has been suggested in the literature. One study by Ernstbrunner et al. [20] showed that tension-band tape had equivalent or superior biomechanical performance compared with other techniques like TBW. Additionally, one randomized control trial protocol, published in 2023, aimed to compare the clinical efficacy and cost-effectiveness of suture fixation versus TBW for simple olecranon fracture fixation in adults [21]. The investigators aimed to provide high-quality evidence for the use of tension suture repair for olecranon fracture fixation [21]. Even though our study utilized suture anchor repair for complex fractures, it provides a foundation for future research exploring suture fixation techniques for olecranon injuries.

A biomechanical study found no difference in displacement rates between TBW and suture anchor repairs for olecranon fractures in patients with osteoporotic bone [22]. Previously, Bateman et al. [11] demonstrated that suture anchor fixation had excellent outcomes in elderly patients. In this updated case series by Bateman et al. [11], two patients had perfect OES 10 years postoperatively. Furthermore, suture anchor fixation had excellent outcomes in both elderly and younger patients [11]. Although our outcomes were studied over a shorter period of time in younger patients, we extrapolate that, based on the combination of current functional outcomes in these patients and the excellent longer outcomes seen in the older patients of this study,

patients will have excellent outcomes regardless of age.

In this case series, fracture reduction was successfully maintained in all patients. Osseous union occurred in all but one patient. Previous studies with TBW and plate fixation have shown loss of reduction in as high as 53% of patients [7,19,23,24]. No patients in our current study experienced symptomatic hardware requiring removal. Furthermore, all patients achieved excellent functional outcomes according to OES, with 75% reporting perfect scores. Suture anchor fixation was shown to be an efficient and advantageous surgical method for elderly patients with medical comorbidities, especially compared with other possible techniques like plate fixation, which commonly requires hardware removal.

This study has some limitations. Our case series did not have a large population size and only had a follow-up rate of 70%. However, this case series is the largest to describe outcomes after suture anchor repair. A larger cohort study performed in a randomized fashion is necessary to determine complications and to assess outcomes. Additionally, larger studies are required to assess the functional outcomes of suture anchor repair in patients younger than 60 years. Last, this treatment method was only used in patients with Mayo IIa and IIb fractures, and this technique would likely not be successful in other types of olecranon fractures.

CONCLUSIONS

Suture anchor fixation of displaced olecranon fractures in patients with comminuted Mayo IIa and IIb fractures resulted in excellent midterm functional outcomes. Additionally, this technique resulted in high rates of osseous union without any hardware-related complications or fixation failures. Considering the limitations and complications observed with other treatment modalities used for displaced olecranon fractures, suture anchor fixation is a great option for a complex elbow injury.

NOTES

ORCID

Mohamad Y. Fares <https://orcid.org/0000-0001-8228-3953>
 Jacob M. Kirsch <https://orcid.org/0000-0003-1918-8974>
 Jonathan Koa <https://orcid.org/0000-0002-3922-359X>
 Joseph A. Abboud <https://orcid.org/0000-0002-3845-7220>

Author contributions

Conceptualization: MJG, JMK, MYF, JAA. Investigation: MJG, JMK, JK, JAA. Methodology: MJG, JAA. Supervision: JMK, JK,

JAA. Visualization: MYF. Writing – original draft: MJG, JMK. Writing – review & editing: JK, MYF, JAA.

Conflict of interest

JAA would like to disclose royalties from: DJO Global, Zimmer-Biomet, Smith and Nephew, Stryker, Globus Medical, Inc., Slack Orthopedics, OsteoCentric Technologies, Bioventus; research support as a PI from: Lima Corporation - Italy, Orthofix, Arthrex, OREF, Department of Defense; Stock ownership: Shoulder JAM LLC, Marlin Medical Alliance LLC, Aevumed, Oberd, OTS Medical; Royalties, financial or material support from publishers: Wolters Kluwer; and board member/committee appointments for a society: Mid Atlantic Shoulder and Elbow Society, American Shoulder and Elbow Society, Shoulder360, Pacira.

Funding

None.

Data availability

Contact the corresponding author for data availability.

Acknowledgments

None.

REFERENCES

1. Duckworth AD, Bugler KE, Clement ND, Court-Brown CM, McQueen MM. Nonoperative management of displaced olecranon fractures in low-demand elderly patients. *J Bone Joint Surg Am* 2014;96:67–72.
2. Duckworth AD, Clement ND, Aitken SA, Court-Brown CM, McQueen MM. The epidemiology of fractures of the proximal ulna. *Injury* 2012;43:343–6.
3. Bailey CS, MacDermid J, Patterson SD, King GJ. Outcome of plate fixation of olecranon fractures. *J Orthop Trauma* 2001;15:542–8.
4. Buijze G, Kloen P. Clinical evaluation of locking compression plate fixation for comminuted olecranon fractures. *J Bone Joint Surg Am* 2009;91:2416–20.
5. Duckworth AD, Clement ND, McEachan JE, White TO, Court-Brown CM, McQueen MM. Prospective randomised trial of non-operative versus operative management of olecranon fractures in the elderly. *Bone Joint J* 2017;99:964–72.
6. Edwards SG, Cohen MS, Lattanza LL, et al. Surgeon perceptions and patient outcomes regarding proximal ulna fixation: a multicenter experience. *J Shoulder Elbow Surg* 2012;21:1637–43.

7. Romero JM, Miran A, Jensen CH. Complications and re-operation rate after tension-band wiring of olecranon fractures. *J Orthop Sci* 2000;5:318–20.
8. Duckworth AD, Clement ND, White TO, Court-Brown CM, McQueen MM. Plate versus tension-band wire fixation for olecranon fractures: a prospective randomized trial. *J Bone Joint Surg Am* 2017;99:1261–73.
9. Snoddy MC, Lang MF, An TJ, et al. Olecranon fractures: factors influencing re-operation. *Int Orthop* 2014;38:1711–6.
10. Campbell ST, DeBaun MR, Goodnough LH, Bishop JA, Gardner MJ. Geriatric olecranon fractures treated with plate fixation have low complication rates. *Curr Orthop Pract* 2019;30:353–5.
11. Bateman DK, Barlow JD, VanBeek C, Abboud JA. Suture anchor fixation of displaced olecranon fractures in the elderly: a case series and surgical technique. *J Shoulder Elbow Surg* 2015;24:1090–7.
12. Hak DJ, Golladay GJ. Olecranon fractures: treatment options. *J Am Acad Orthop Surg* 2000;8:266–75.
13. Hutchinson DT, Horwitz DS, Ha G, Thomas CW, Bachus KN. Cyclic loading of olecranon fracture fixation constructs. *J Bone Joint Surg Am* 2003;85:831–7.
14. Wild JR, Askam BM, Margolis DS, Geffre CP, Krupinski EA, Truchan LM. Biomechanical evaluation of suture-augmented locking plate fixation for proximal third fractures of the olecranon. *J Orthop Trauma* 2012;26:533–8.
15. Izzj J, Athwal GS. An off-loading triceps suture for augmentation of plate fixation in comminuted osteoporotic fractures of the olecranon. *J Orthop Trauma* 2012;26:59–61.
16. Baecher N, Edwards S. Olecranon fractures. *J Hand Surg Am* 2013;38:593–604.
17. Wilson J, Bajwa A, Kamath V, Rangan A. Biomechanical comparison of interfragmentary compression in transverse fractures of the olecranon. *J Bone Joint Surg Br* 2011;93:245–50.
18. Powell AJ, Farhan-Alanie OM, McGraw IW. Tension band wiring versus locking plate fixation for simple, two-part Mayo 2A olecranon fractures: a comparison of post-operative outcomes, complications, reoperations and economics. *Musculoskelet Surg* 2019;103:155–60.
19. Chalidis BE, Sachinis NC, Samoladas EP, Dimitriou CG, Pournaras JD. Is tension band wiring technique the "gold standard" for the treatment of olecranon fractures? A long term functional outcome study. *J Orthop Surg Res* 2008;3:9.
20. Ernstbrunner L, Rupasinghe HS, Almond M, et al. A new all-suture tension band tape fixation technique for simple olecranon fractures versus conventional tension band wire fixation: a comparative biomechanics study. *J Shoulder Elbow Surg* 2022;31:1376–84.
21. Cook E, James S, Watts AC, The SOFFT team. A randomized controlled trial to compare clinical and cost-effectiveness of suture fixation versus tension band wiring for simple olecranon fracture fixation in adults: the Simple Olecranon Fracture Fixation Trial (SOFFT) protocol. *Bone Jt Open* 2023;4:27–37.
22. von Keudell A, Kachooei A, Mohamadi A, et al. Biomechanical properties of an intramedullary suture anchor fixation compared to tension band wiring in osteoporotic olecranon fractures: a cadaveric study. *J Orthop* 2020;17:144–9.
23. Hume MC, Wiss DA. Olecranon fractures: a clinical and radiographic comparison of tension band wiring and plate fixation. *Clin Orthop Relat Res* 1992;229–35.
24. Karlsson MK, Hasserijs R, Karlsson C, Besjakov J, Josefsson PO. Fractures of the olecranon: a 15- to 25-year followup of 73 patients. *Clin Orthop Relat Res* 2002;205–12.