

12-5-2022

Safety and Efficacy of Salvage Therapy With Laser Interstitial Thermal Therapy for Malignant Meningioma Refractory to Cesium-131 Brachytherapy: Illustrative Case

Clifford Yudkoff
Thomas Jefferson University

Aria Mahtabfar
Thomas Jefferson University

Keenan Piper
Thomas Jefferson University

Kevin Judy
Thomas Jefferson University

Follow this and additional works at: <https://jdc.jefferson.edu/neurosurgeryfp>



Part of the [Neurology Commons](#), and the [Surgery Commons](#)

[Let us know how access to this document benefits you](#)

Recommended Citation

Yudkoff, Clifford; Mahtabfar, Aria; Piper, Keenan; and Judy, Kevin, "Safety and Efficacy of Salvage Therapy With Laser Interstitial Thermal Therapy for Malignant Meningioma Refractory to Cesium-131 Brachytherapy: Illustrative Case" (2022). *Department of Neurosurgery Faculty Papers*. Paper 208. <https://jdc.jefferson.edu/neurosurgeryfp/208>

This Article is brought to you for free and open access by the Jefferson Digital Commons. The Jefferson Digital Commons is a service of Thomas Jefferson University's [Center for Teaching and Learning \(CTL\)](#). The Commons is a showcase for Jefferson books and journals, peer-reviewed scholarly publications, unique historical collections from the University archives, and teaching tools. The Jefferson Digital Commons allows researchers and interested readers anywhere in the world to learn about and keep up to date with Jefferson scholarship. This article has been accepted for inclusion in Department of Neurosurgery Faculty Papers by an authorized administrator of the Jefferson Digital Commons. For more information, please contact: JeffersonDigitalCommons@jefferson.edu.

Safety and efficacy of salvage therapy with laser interstitial thermal therapy for malignant meningioma refractory to cesium-131 brachytherapy: illustrative case

Clifford Yudkoff, BS, Aria Mahtabfar, MD, Keenan Piper, BS, and Kevin Judy, MD

Department of Neurosurgery, Thomas Jefferson University and Jefferson Hospital for Neuroscience, Philadelphia, Pennsylvania

BACKGROUND Anaplastic meningioma are rare, cancerous tumors of the central nervous system that often require multimodal therapy for tumor control. Both laser interstitial thermal therapy (LITT) and brachytherapy with implanted cesium-131 metallic seeds have demonstrated efficacy in the treatment of recurrent and resistant anaplastic meningioma; however, their safety as a dual therapy has never been reported.

OBSERVATIONS In this report, the authors present a case of a 53-year-old female who received LITT in combination with brachytherapy after surgical and radiation treatment options had been exhausted. The authors discuss the unique safety concern of thermal injury with this treatment combination and demonstrate their method for the safe administration of these treatments together. Furthermore, the authors provide a review of the literature on LITT as an emerging therapy for anaplastic meningioma.

LESSONS The use of LITT in combination with brachytherapy remains an option for salvage therapy in patients with recurrent meningioma that provides durable local control of tumor.

<https://thejns.org/doi/abs/10.3171/CASE22379>

KEYWORDS LITT; anaplastic meningioma; brachytherapy; cesium

Meningiomas are one of the most common intracranial tumors that neurosurgeons encounter, accounting for approximately 38% of primary brain tumors and affecting an estimated 30,000 to 40,000 people in the United States. Recurrence of high-grade tumors is common, which requires continual advancements in the neurosurgical management of these neoplasms.^{1–3} Anaplastic or World Health Organization (WHO) grade III meningiomas account for approximately 1%–3% of meningiomas but are highly recurrent and require multimodal treatment for control.⁴

Innovative technologies have led to less invasive and more precise techniques to control intracranial neoplasms. Laser interstitial thermal therapy (LITT) is one such development that has been used safely and effectively in a variety of pathologies, including glioblastoma; metastatic disease; and other primary central nervous system neoplasms, such as meningioma.^{5–9} LITT delivers thermal energy through a magnetic resonance imaging (MRI) thermometry-guided fiberoptic probe, which induces coagulative necrosis to reduce

tumor bulk with extreme accuracy. LITT has become increasingly popular due to low rates of intraoperative complications; short hospital stays; significant reduction of tumor volume; and favorable outcomes, including increased overall survival and progression-free survival.^{6–8} In addition, LITT allows ablation of tumors not amenable to resection due to tumor location or poor patient functional status.^{6,10}

Although LITT is very well tolerated, as demonstrated by the LAANTERN (Laser Ablation of Abnormal Neurological Tissue Using Robotic Neuroplate System) trial,¹¹ complications are reported in the literature, including transient neurological deficit, infection, seizures, and cerebrospinal fluid leak.^{6,10} The neurological deficits seen postoperatively are typically attributed to an increase in cerebral edema.⁷ A study performed by Pruitt et al.¹² in 46 patients undergoing LITT for a variety of intracranial pathologies showed that direct thermal injury was the only cause of prolonged neurological deficit. Therefore, it stands to reason that the presence of thermally conductive materials around the surgical site should be taken into consideration. There is a dearth of literature surrounding the potential

ABBREVIATIONS FSRT = fractionated stereotactic radiotherapy; LITT = laser interstitial thermal therapy; MRI = magnetic resonance imaging; SRS = stereotactic radiosurgery; WHO = World Health Organization.

INCLUDE WHEN CITING Published December 5, 2022; DOI: 10.3171/CASE22379.

SUBMITTED September 9, 2022. **ACCEPTED** October 7, 2022.

© 2022 The authors, CC BY-NC-ND 4.0 (<http://creativecommons.org/licenses/by-nc-nd/4.0/>).

detrimental effects of implanted intracranial metallic objects on LITT ablation. It is reasonable to assume that the presence of thermally conductive metal may distract the thermal flow and cause inadvertent damage to surrounding structures.

Local radiotherapy or brachytherapy has also emerged as an effective treatment for recurrent meningiomas whereby metallic implants, typically cesium-131 (¹³¹Cs) seeds containing gold and titanium, deliver local radiation to the neoplasm, minimizing exposure to surrounding healthy tissue.^{13,14} Brachytherapy provides an alternative method of providing irradiation when other treatments, such as external beam radiation therapy, have been exhausted due to maximum safe dosages.^{14,15} As new modalities for the treatment of recurrent and aggressive meningiomas appear, it is crucial to understand how these emerging interventions may interact with and limit one another. We believe this to be the first report to discuss the use of thermal ablation in the presence of intracranial metallic objects.

Here, we describe a multimodal treatment strategy for a patient with recurrent meningiomas using laser ablation in the presence of implanted cesium seeds containing gold and titanium and review the safety of LITT in the presence of intracranial metallic objects. We hope this report will help inform decision making for patients with multiple recurrences of meningiomas.

Illustrative Case

Presentation

A 53-year-old female was initially diagnosed with a right occipital meningioma. She subsequently underwent gross total resection with adjuvant radiation of 60 Gy in 30 fractions, completed 3 months after diagnosis. The pathology was consistent with a WHO grade III meningioma. She was noted to have radiographic progression 6 months after completing treatment and underwent subsequent subtotal resection. The pathology at this time revealed anaplastic meningioma with sarcomatous features requiring fractionated stereotactic radiotherapy (FSRT) of 35 Gy in 10 fractions with adjuvant temozolomide completed 2 months later. She then had a short interval recurrence 4 months after FSRT, requiring further resection and brachytherapy with implantation of thirteen ¹³¹Cs seeds. She began chemotherapy with sunitinib but did not tolerate the chemotherapy well. Radiographic progression was noted 10 months later, and she was switched to bevacizumab. She achieved stable

disease for 22 months until evidence of progression was seen on follow-up scans requiring additional brachytherapy with implantation of sixteen ¹³¹Cs seeds. Three months later, further progression was seen on surveillance scans, for which she required 18 Gy of stereotactic radiosurgery (SRS). Her clinical course is summarized in Fig. 1.

Investigations and Differential Diagnosis

On a surveillance scan 2 months after SRS, a new focus of enhancement was seen in the posterior-inferior portion of the right occipital resection cavity, concerning for local recurrence (Fig. 2A). The differential diagnosis included recurrent malignant meningioma, and necrosis or newly developed glioma was possible. After multidisciplinary discussion, laser ablation was recommended because she had exhausted all her radiation options and additional craniotomy for resection would be tenuous, given her extensive surgical history. Of note, due to the implanted cesium seeds constructed of ¹³¹Cs-impregnated gold enveloped in a titanium casing (Fig. 2B and C), LITT carried unknown risks to the patient. She was agreeable to the surgery, so we proceeded with thermal ablation as planned.

Treatment

The patient was taken to the operating room for LITT ablation 53 months after her initial diagnosis. A Cosman-Roberts-Wells head frame was placed and attached to the Renishaw robot. Mapping of the trajectory of the laser catheters was performed with the O-arm and coregistered with the patient's MRI scan. We then performed a stereotactic biopsy of the tumor. With robot assistance, we placed 2 laser catheters, judiciously avoiding the cesium seeds. Positioning of the laser catheters was confirmed by O-arm. The presence of the cesium seeds created some artifact that required additional sequences to be taken to confirm the trajectory of the laser (Fig. 3). We then proceeded with ablation of the tumor and obtained adequate coverage. The patient tolerated the procedure well, was able to be extubated at the end of the procedure, and was taken to the post-anesthesia care unit in stable condition.

Outcome and Follow-Up

Biopsy revealed a combination of anaplastic meningioma and therapy-related changes. Overall, our patient experienced 9 months of progression-free survival and was clinically stable at her 9-month

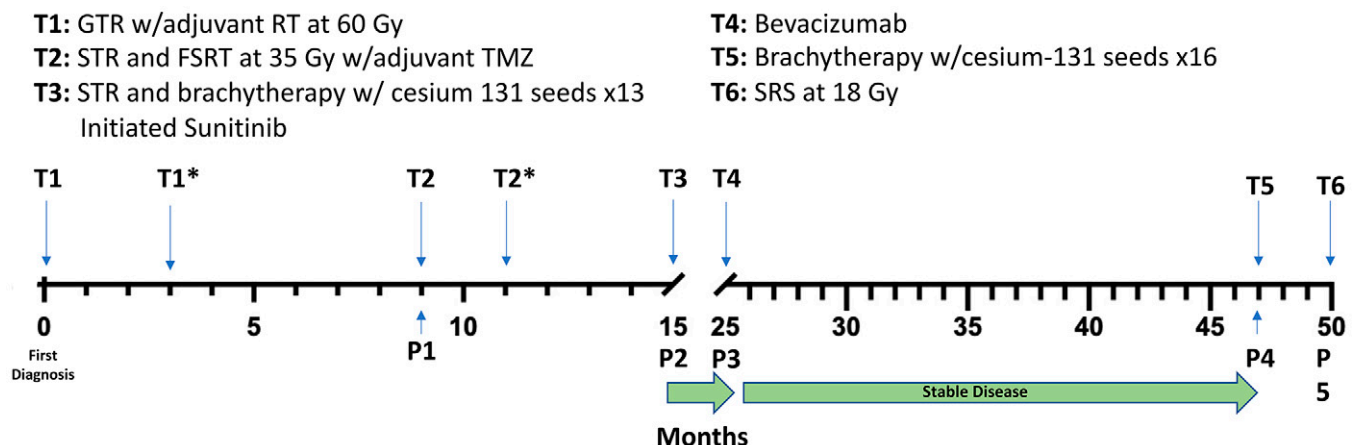


FIG. 1. Timeline in months showing interventions above axis and disease course below axis. Asterisks indicate intervention completed. GTR = gross total resection; P = radiological progression; RT = radiation therapy; STR = subtotal resection; TMZ = temozolomide.

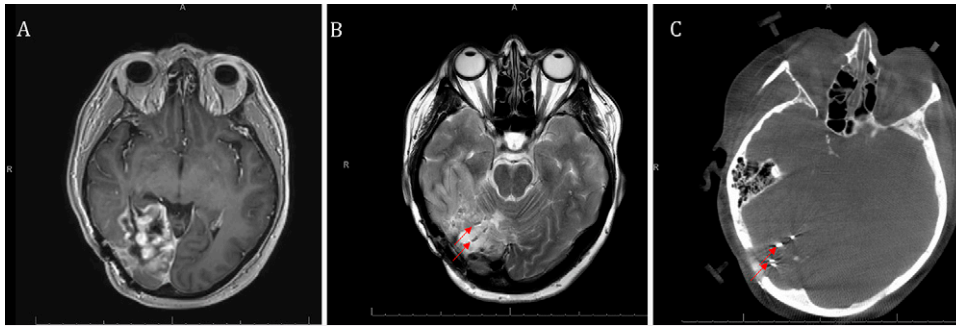


FIG. 2. Imaging before LITT. **A:** Axial postcontrast T1-weighted MRI showing recurrence of right occipital meningioma. Axial T2-weighted MRI (**B**) and computed tomography (**C**) showing cesium brachytherapy implants in prior resection bed. *Red arrows* point to cesium seeds.

follow-up. She experienced no postoperative complications and was discharged home on postoperative day 2 with a neurological examination unchanged from admission. Postoperative scans showed significant reduction of the volume of enhancement of the mass (Fig. 4). At her 1-month follow-up, our patient was doing remarkably well with a Karnofsky performance status of 90. MRI at this time showed no evidence of recurrence and good treatment response (Fig. 5A). Of note, imaging further revealed peritumoral edema that required treatment with dexamethasone (Fig. 5B). Despite multiple attempts to taper, she had continuing requirements of dexamethasone at 10 months to manage symptoms related to the peritumoral edema. At 9 months postoperatively, the patient returned with worsening headaches and confusion, with an MRI showing increased enhancing parieto-occipital tumor with mass effect (Fig. 5C). Palliative bevacizumab was initiated because no surgical or radiation options remained.

Discussion

Observations

Here we report a case of durable salvage therapy via LITT in the presence of implanted intracranial metallic objects for a highly recurrent meningioma refractory to multiple treatment modalities. To our knowledge, this is the first discussion of the implications of implanted intracranial metallic objects for LITT. The only other mention of LITT in a patient with intracranial metallic objects is in a case

series of 16 patients with metastatic brain cancer requiring brachytherapy, 1 of whom received LITT after implantation of cesium seeds.¹⁶ However, the authors do not provide any additional details or discussion about this finding.

Use of LITT in our patient required extra consideration due to the previous attempt at controlling the meningioma via implantation of gold-plated ¹³¹Cs seeds. Theoretically, the presence of implanted metal with LITT posed an extra risk for inadvertent thermal injury to surrounding structures. Despite this, and with careful placement of the laser probes around the seeds, LITT remained accurate and effective at ablating the area of recurrence with radiological evidence of complete eradication of tumor. There were no intra- or postoperative complications, and, in the follow-up period, our patient endured 9 months of progression-free survival. At the time of this report, she is 17 months post-therapy and is still alive. She did require a prolonged course of dexamethasone for edema, although it is hard to determine whether this is standard cytotoxic edema from LITT, additional damage from the implants, natural disease progression, or an intrinsic patient variable.

Currently, there are no standard guidelines for treating malignant meningiomas. Primary treatment consists of a form of surgical therapy with adjunctive radiation therapy, with extent of resection serving as a strong predictor of outcome.¹⁷ In addition, adjuvant radiotherapy with primary resection has been shown to confer an overall survival benefit.¹⁸ Typical treatment for recurrence includes

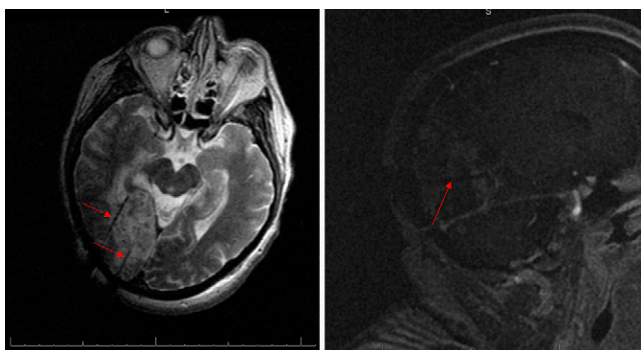


FIG. 3. Intraoperative MRI-guided laser probe placement confirming location of probes within tumor bed and avoiding cesium seeds. **Left:** Axial view. **Right:** Sagittal view. *Red arrows* point to laser probes.

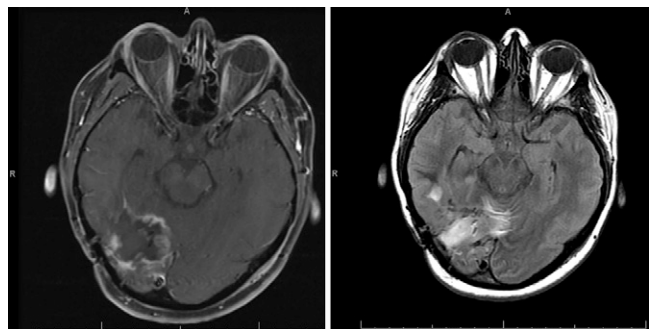


FIG. 4. Post-thermal ablation. **Left:** Axial postcontrast T1-weighted MRI showing reduced enhancing tumor. **Right:** Axial T2-weighted fluid-attenuated inversion recovery MRI showing cesium seeds as well as edema around ablation site immediately postoperatively.

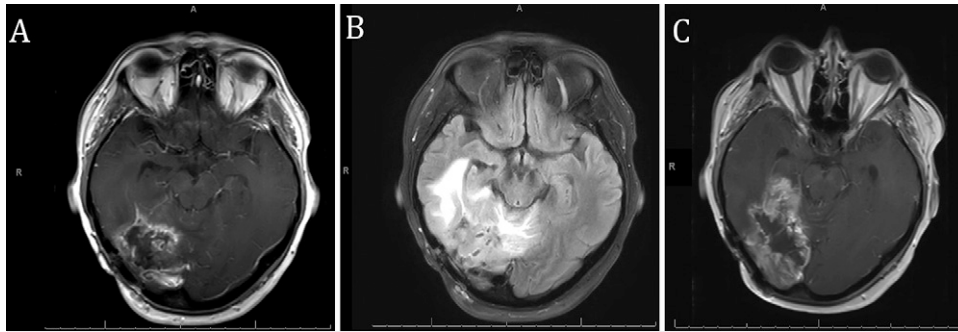


FIG. 5. A: Axial postcontrast T1-weighted MRI showing no evidence of recurrence within resection bed at 1 month. **B:** Axial T2-weighted fluid-attenuated inversion recovery MRI showing increased edema around ablation site at 1 month. **C:** Axial postcontrast T1-weighted MRI showing tumor recurrence at 9 months postoperatively.

repeat resection, radiation therapy, SRS, Gamma Knife, chemotherapy, brachytherapy, and LITT. Repeat resection has been associated with a survival benefit.¹⁹ Potential pharmacological agents also may be effective against recurrence. A phase II clinical trial has demonstrated efficacy with the tyrosine kinase inhibitor sunitinib against WHO grades II and III meningiomas, with a median progression-free survival of 5.2 months and overall survival of 24.6 months.²⁰ Despite this, the recurrence-free and overall survival for malignant meningiomas remains poor. In one study by Rosenberg et al.,²¹ of 13 patients with WHO grade III meningiomas, 5-year survival was 47.2% and decreased to 12.2% at 8 years with a median time to recurrence of 9.6 months. Sughrue et al.,¹⁹ in a study of 63 patients with WHO grade III meningioma, observed 2-, 5-, and 10-year survival of 82%, 61%, and 40%, respectively. Although it is difficult to precisely delineate our patient's expected survival because her tumor is not accurately categorized by any previous study, her highly aggressive and recurrent tumor carries a poor prognosis.

There is scarce reporting on the use of LITT in malignant meningioma. Two case series of LITT for meningiomas observed a total of 2 cases of anaplastic meningioma in which LITT was able to provide 2 and 3 months of progression-free survival, respectively.^{8,22} A separate study by Rammo et al.⁹ followed 2 patients with WHO grade III meningioma treated with LITT. One patient experienced progression at 11.4 weeks with repeat LITT at that time, which provided an additional 10.4 weeks of progression-free survival. At the time of analysis at 25 months, this patient was still alive. The second patient had progression at 5.7 weeks after LITT and an overall survival of 9 months. Neither patient experienced any complications with LITT. Our experience with LITT highly corroborates other experiences described in the literature, despite the presence of intracranial metallic objects in our patient, which reasonably indicates that the cesium seeds did not significantly impact our patient's outcome.

LITT is well characterized to cause cerebral edema due to the induction of coagulation necrosis causing a local reaction, as well as the disruption of the blood-brain barrier.²³ Several studies have observed that this perilesional edema typically peaks at approximately 3 days and gradually decreases over a period of 2–8 weeks.^{23,24} Steroids are the mainstay treatment for cerebral edema after LITT. Maraka et al.²⁵ studied cerebral edema after LITT in 8 patients in whom the steroid dose was tapered over a median of 60.5 days, with a range from 44 to 111 days. In a separate study by Ahluwalia et al.²⁶ in 42 patients undergoing LITT for radiation necrosis or brain lesions, after LITT, only 30% of

patients were able to be weaned off steroids at 12 weeks. Our patient failed multiple attempts to wean corticosteroids and was steroid dependent even at her 10-month follow-up, which is certainly on the longer end of the spectrum than what is typically expected for cerebral edema after LITT. This is most likely a reflection of cerebral edema from LITT with a component of microscopic progression of the tumor rather than inadvertent damage from LITT. In addition, Pruitt et al.¹² described the potential complication of indirect thermal injury due to LITT, or LITT hyperthermia, to cause new or worsened neurological deficits, endocrinological disturbances, infection, and acutely worsened edema, none of which we observed in our patient.

Lessons

We conclude that LITT remains a viable salvage treatment strategy for patients with recurrent meningioma even in the presence of intracranial metal objects. Because brachytherapy is a popular option to control local recurrence of meningioma, more patients may begin to present with intracranial metallic objects. It is important to understand the interactions between these evolving therapies so that one therapy does not preclude another.

References

1. Aghi MK, Carter BS, Cosgrove GR, et al. Long-term recurrence rates of atypical meningiomas after gross total resection with or without postoperative adjuvant radiation. *Neurosurgery*. 2009;64(1):56–60.
2. Lam Shin Cheung V, Kim A, Sahgal A, Das S. Meningioma recurrence rates following treatment: a systematic analysis. *J Neurooncol*. 2018;136(2):351–361.
3. Walcott BP, Nahed BV, Brastianos PK, Loeffler JS. Radiation treatment for WHO grade II and III meningiomas. *Front Oncol*. 2013;3:227.
4. Saraf S, McCarthy BJ, Villano JL. Update on meningiomas. *Oncologist*. 2011;16(11):1604–1613.
5. Ivan ME, Diaz RJ, Berger MH, et al. Magnetic resonance-guided laser ablation for the treatment of recurrent dural-based lesions: a series of five cases. *World Neurosurg*. 2017;98:162–170.
6. Rivera M, Norman S, Sehgal R, Juthani R. Updates on surgical management and advances for brain tumors. *Curr Oncol Rep*. 2021;23(3):35.
7. Melnick K, Shin D, Dastmalchi F, et al. Role of laser interstitial thermal therapy in the management of primary and metastatic brain tumors. *Curr Treat Options Oncol*. 2021;22(12):108.

8. Shah AH, Semonche A, Eichberg DG, et al. The role of laser interstitial thermal therapy in surgical neuro-oncology: series of 100 consecutive patients. *Neurosurgery*. 2020;87(2):266–275.
9. Rammo R, Scarpace L, Nagaraja T, Lee I. MR-guided laser interstitial thermal therapy in the treatment of recurrent intracranial meningiomas. *Lasers Surg Med*. 2019;51(3):245–250.
10. Salem U, Kumar VA, Madewell JE, et al. Neurosurgical applications of MRI guided laser interstitial thermal therapy (LITT). *Cancer Imaging*. 2019;19(1):65.
11. Rennert RC, Khan U, Bartek J, et al. Laser Ablation of Abnormal Neurological Tissue Using Robotic Neuroplate System (LAANTERN): procedural safety and hospitalization. *Neurosurgery*. 2020;86(4):538–547.
12. Pruitt R, Gamble A, Black K, Schulder M, Mehta AD. Complication avoidance in laser interstitial thermal therapy: lessons learned. *J Neurosurg*. 2017;126(4):1238–1245.
13. Koch MJ, Agarwalla PK, Royce TJ, et al. Brachytherapy as an adjunct for recurrent atypical and malignant meningiomas. *Neurosurgery*. 2019;85(5):E910–E916.
14. Brachman DG, Youssef E, Dardis CJ, et al. Resection and permanent intracranial brachytherapy using modular, biocompatible cesium-131 implants: results in 20 recurrent, previously irradiated meningiomas. *J Neurosurg*. 2018;131(6):1819–1828.
15. Wernicke AG, Smith AW, Taube S, et al. Cesium-131 brachytherapy for recurrent brain metastases: durable salvage treatment for previously irradiated metastatic disease. *J Neurosurg*. 2017;126(4):1212–1219.
16. Nakaji P, Smith K, Youssef E, et al. Resection and surgically targeted radiation therapy for the treatment of larger recurrent or newly diagnosed brain metastasis: results from a prospective trial. *Cureus*. 2020;12(11):e11570.
17. Aizer AA, Bi WL, Kandola MS, et al. Extent of resection and overall survival for patients with atypical and malignant meningioma. *Cancer*. 2015;121(24):4376–4381.
18. Hanft S, Canoll P, Bruce JN. A review of malignant meningiomas: diagnosis, characteristics, and treatment. *J Neurooncol*. 2010;99(3):433–443.
19. Sughrue ME, Sanai N, Shangari G, Parsa AT, Berger MS, McDermott MW. Outcome and survival following primary and repeat surgery for World Health Organization grade III meningiomas. *J Neurosurg*. 2010;113(2):202–209.
20. Hsu RY, Lareau CR, Kim JS, Korupolu S, Born CT, Schiller JR. The effect of C-Arm position on radiation exposure during fixation of pediatric supracondylar fractures of the humerus. *J Bone Joint Surg Am*. 2014;96(15):e129.
21. Rosenberg LA, Prayson RA, Lee J, et al. Long-term experience with World Health Organization grade III (malignant) meningiomas at a single institution. *Int J Radiat Oncol Biol Phys*. 2009;74(2):427–432.
22. Ruiz A, Diaz RJ, Buttrick S, et al. Preliminary experience on laser interstitial thermal ablation therapy in the treatment of extra-axial masses: indications, imaging characterization and outcomes. *Cureus*. 2018;10(6):e2894.
23. Leuthardt EC, Duan C, Kim MJ, et al. Hyperthermic laser ablation of recurrent glioblastoma leads to temporary disruption of the peritumoral blood brain barrier. *PLoS One*. 2016;11(2):e0148613.
24. Medvid R, Ruiz A, Komotar RJ, et al. Current applications of MRI-guided laser interstitial thermal therapy in the treatment of brain neoplasms and epilepsy: a radiologic and neurosurgical overview. *AJNR Am J Neuroradiol*. 2015;36(11):1998–2006.
25. Maraka S, Asmaro K, Walbert T, Lee I. Cerebral edema induced by laser interstitial thermal therapy and radiotherapy in close succession in patients with brain tumor. *Lasers Surg Med*. 2018;50(9):917–923.
26. Ahluwalia M, Barnett GH, Deng D, et al. Laser ablation after stereotactic radiosurgery: a multicenter prospective study in patients with metastatic brain tumors and radiation necrosis. *J Neurosurg*. 2018;130(3):804–811.

Disclosures

The authors report no conflict of interest concerning the materials or methods used in this study or the findings specified in this paper.

Author Contributions

Conception and design: Judy, Yudkoff, Mahtabfar. Acquisition of data: Judy, Yudkoff, Mahtabfar. Analysis and interpretation of data: all authors. Drafting the article: Yudkoff, Mahtabfar, Piper. Critically revising the article: all authors. Reviewed submitted version of manuscript: all authors. Approved the final version of the manuscript on behalf of all authors: Judy. Statistical analysis: Judy. Administrative/technical/material support: Judy, Yudkoff, Mahtabfar. Study supervision: Judy, Yudkoff, Mahtabfar.

Correspondence

Kevin Judy: Thomas Jefferson University and Jefferson Medical College, Philadelphia, PA. kevin.judy@jefferson.edu.