

1-16-2023

Total Hip Arthroplasty in the Setting of Post-traumatic Arthritis Following Acetabular Fracture: A Systematic Review

Conor S O'Driscoll
Tallaght University Hospital

Martin S Davey
Galway University Hospital

Andrew J Hughes
Thomas Jefferson University

John M O'Byrne
Irish National Orthopaedic Hospital

Michael Leonard
Tallaght University Hospital

Follow this and additional works at: https://jdc.jefferson.edu/rothman_institute



Part of [Open Access Commons](#)

[Let us know how access to this document benefits you](#)

Recommended Citation

O'Driscoll, Conor S; Davey, Martin S; Hughes, Andrew J; O'Byrne, John M; Leonard, Michael; and O'Daly, Brendan J, "Total Hip Arthroplasty in the Setting of Post-traumatic Arthritis Following Acetabular Fracture: A Systematic Review" (2023). *Rothman Institute Faculty Papers*. Paper 192.
https://jdc.jefferson.edu/rothman_institute/192

This Article is brought to you for free and open access by the Jefferson Digital Commons. The Jefferson Digital Commons is a service of Thomas Jefferson University's [Center for Teaching and Learning \(CTL\)](#). The Commons is a showcase for Jefferson books and journals, peer-reviewed scholarly publications, unique historical collections from the University archives, and teaching tools. The Jefferson Digital Commons allows researchers and interested readers anywhere in the world to learn about and keep up to date with Jefferson scholarship. This article has been accepted for inclusion in Rothman Institute Faculty Papers by an authorized administrator of the Jefferson Digital Commons. For more information, please contact: JeffersonDigitalCommons@jefferson.edu.

Authors

Conor S O'Driscoll, Martin S Davey, Andrew J Hughes, John M O'Byrne, Michael Leonard, and Brendan J O'Daly



Systematic Review

Total Hip Arthroplasty in the Setting of Post-Traumatic Arthritis Following Acetabular Fracture: A Systematic Review

Conor S. O'Driscoll, MB, BAO, BCh, MRCS ^{a, b, c, *},
 Martin S. Davey, MB, BAO, BCh, MCh, MRCS ^{b, c},
 Andrew J. Hughes, MB, BAO, BCh, MCh, FRCS ^{a, c, d},
 John M. O'Byrne, MB, BAO, BCh, MCh, FRCS, FFSEM ^{c, e},
 Michael Leonard, MB, BAO, BCh, MCh, FRCS ^a,
 Brendan J. O'Daly, MB, BAO, BCh, MSc, FRCS ^{a, f}

^a Irish National Pelvic and Acetabular Centre, Tallaght University Hospital, Dublin, Ireland

^b Department of Trauma & Orthopaedics, Galway University Hospital, Galway, Ireland

^c Department of Trauma & Orthopaedics, Royal College of Surgeons Ireland, Dublin, Ireland

^d Rothman Orthopedic Institute, Thomas Jefferson University Hospital, Philadelphia, PA, USA

^e Irish National Orthopaedic Hospital, Cappagh, Dublin, Ireland

^f School of Medicine, University College Dublin, Dublin, Ireland

ARTICLE INFO

Article history:

Received 5 July 2022

Received in revised form

31 October 2022

Accepted 30 November 2022

Available online xxx

Keywords:

Acetabular fracture

Post-traumatic arthritis

Total hip arthroplasty

Prosthetic joint infection

Patient-reported outcomes

ABSTRACT

Background: Acetabular fractures are frequently associated with post-traumatic arthritis (PTA), for which total hip arthroplasty (THA) has emerged as the established procedure. The purpose of this systematic review is to report the patient outcomes, complications, and implant survival of delayed THA for patients with PTA following acetabular fracture.

Methods: A systematic review was performed in December 2021 as per Preferred Reporting Items for Systematic Review and Meta-Analysis Guidelines to identify all studies reporting outcomes of delayed THA performed for PTA with a history of acetabular fracture. From an initial screen of 893 studies, 29 studies which met defined inclusion criteria including minimum 12 months of follow-up and minimum 10 THA were included in the final review.

Results: A total of 1220 THA were reported across 29 studies, with 1174 THA completing a minimum of 1-year follow-up at a mean of 86 months. All 29 studies reported upon complications, with a control included in 6 for comparison. Higher complication rates were observed both in patients who had prior open reduction internal fixation and conservative treatment, most notably infection which was observed following 3.6% THA. The total joint revision rate was 9.7%. An improvement was noted in all 25 studies which recorded patient-reported outcomes, with a mean rise in the Harris hip score from 45 to 86 across 18 studies. **Conclusions:** THA may reduce reported pain levels and improve functional outcomes in selected patients experiencing PTA following acetabular fractures. There is an increased risk of complications, necessitating careful consideration when planning the operation and open discussion with prospective patients and caregivers.

© 2022 The Authors. Published by Elsevier Inc. on behalf of The American Association of Hip and Knee Surgeons. This is an open access article under the CC BY-NC-ND license (<http://creativecommons.org/licenses/by-nc-nd/4.0/>).

Search Strategies and Materials Available Online. Prospero Registration: CRD42022327855 - <https://www.crd.york.ac.uk/PROSPERO/>.

All authors contributed to the study conception and design. Material preparation, data collection and analysis were performed by Conor O'Driscoll, Martin Davey and Andrew Hughes. The first draft of the manuscript was written by Conor O'Driscoll

and all authors commented on previous versions of the manuscript. All authors read and approved the final manuscript.

* Corresponding author. Royal College of Surgeons of Ireland, 123 St. Stephens Green, Dublin 2, Ireland. Tel.: +353857884714.

E-mail address: coodrisc@tcd.ie

<https://doi.org/10.1016/j.artd.2022.101078>

2352-3441/© 2022 The Authors. Published by Elsevier Inc. on behalf of The American Association of Hip and Knee Surgeons. This is an open access article under the CC BY-NC-ND license (<http://creativecommons.org/licenses/by-nc-nd/4.0/>).

Introduction

Acetabular fractures are uncommon fractures historically associated with high-energy trauma in the young patient [1], however are increasingly seen following low-energy trauma in the elderly [2,3]. Associated injuries to acetabular and femoral cartilage as well as the femoral blood supply are common [4] and frequently lead to painful and debilitating post-traumatic arthritis (PTA) [5,6]. Furthermore, a high proportion of patient progress clinically toward requirement of total hip arthroplasty (THA) [7-9], with a number of demographic factors including age and female gender [8,9], alongside technical factors such as residual fracture displacement and gap [10,11], associated with progression to THA.

THA has been shown to yield excellent clinical results for patients regarding return to activities of daily living and reported pain relief [12]. However, surgeons and patients must be cognizant that anatomic distortion following initial injury alongside changes in bone stock may precipitate potential complication of the task of performing THA postacetabular fracture, leading to higher complication rates when contrasted to those reported for primary THA [12]. This is further compounded for those patients in whom THA follows initial open reduction internal fixation (ORIF), with additional challenges posed such as possible occult infection [13], in-situ metal work, and high rates of heterotopic ossification [14]. In their previous systematic review, Stibolt et al. [15] reported the results of 448 patients following THA in the setting of acetabular trauma, with varying rates of surgical revisions reported up to 32% despite significant improvements in functional outcomes in the medium term. However, in recent years, the literature on this topic has grown exponentially, and therefore, the authors of this study believe an updated review is warranted.

This study aids orthopaedic surgeons when planning and consenting patients for THA in the setting of PTA postacetabular fracture. This is achieved by providing a comprehensive review of the current literature which may serve as a reference, both pertaining to clinical outcomes in terms of patient-reported outcomes, implant survivorship and complications, as well as describing implants and techniques utilized. A secondary aim is to highlight the implications of previous acetabular fracture ORIF in subsequent THA procedures.

Material and methods

Search strategy

In December 2021, a systematic review of the literature was performed by 2 independent reviewers (COD and MSD) with the search being performed with respect to Preferred Reporting Items for Systematic Review and Meta-Analysis Guidelines [16]. The PubMed (MEDLINE), Cochrane, and Embase databases were screened from their inception to 26 December 2021 inclusive. Predetermined search terms were decided by all authors prior to study commencement, with search terms utilized for each of the aforementioned databases incorporating; THA population, post-traumatic arthritis, and outcome (see attached in appendix). Following removal of duplicate studies, both independent reviewers manually screened the titles and abstracts of the returned studies whilst applying our predetermined exclusion criteria, with the senior author (BOD) acting as an arbitrator in cases of discrepancy of opinion. Following removal of excluded studies, both independent reviewers applied the predetermined inclusion criteria to the remaining studies to evaluate all potential studies for definitive inclusion. Thereafter, the reference lists of all included studies were screened for further studies that potentially may meet the inclusion criteria.

Eligibility criteria

The predetermined exclusion criteria decided upon by all authors included the following: (1) acute THA less than 4 weeks following injury in the setting of trauma, (2) case reports, (3) less than 10 patients included, (4) review articles, (5) cadaveric studies, (6) biomechanical studies, and (7) abstract only studies. The predetermined inclusion criteria decided upon by all authors included the following: (1) studies reporting clinical outcomes following THA in the setting of PTA following acetabular fracture, (2) studies published in the English language, (3) minimum of 12-month follow-up, and (4) published in a peer-review journal with full text available.

Outcomes of interest

The results from each study were tabulated following a quality assessment using the Grading of Recommendation, Assessment, Development and Evaluation tool [17] and Oxford Center for Evidence-Based Medicine criteria [18].

A predesigned data collection template was then collated including (1) study population, including fracture classification (Letournel and Judet), study type, follow-up period, patient demographics, injury severity where recorded, (2) implants utilized and surgical technique, (3) patient-reported outcomes, (4) complications, and (5) arthroplasty revision rate.

Statistical analysis

Descriptive statistics were performed using Stata software, version 16.1 (StataCorp, College Station, TX). Categorical variables were analyzed using Fisher's exact, whereas continuous variables were analyzed using unpaired t-tests where available data sets. A *P* value of less than 0.05 was deemed to be statistically significant.

Results

Search results

A total of 893 articles were collated in the initial database search, which was subsequently reduced to 764 following duplicate removal. Following abstract screening, 73 full text articles were assessed leaving 29 studies included in the final review. The Preferred Reporting Items for Systematic Review and Meta-Analysis Flow Chart with reasons for exclusion is illustrated in [Figure 1](#).

Patient Demographics and Study Characteristics

Overall, 1220 THAs were reported in the 29 studies, with 1174 THAs completing a minimum 1-year follow-up at a mean of 86 months. Regarding patient demographics, 70% of THA were performed for male patients, with a mean age of 49 years. The average interval between initial acetabular fracture and THA was 71 months. A total of 6 studies with 274 THAs included 620 elective primary THAs as a control, whereas 21 studies with 581 THAs individually reported the results of THA following initial ORIF and 6 studies with 158 THAs reported results following conservative (nonoperative) management. The findings of these studies are shown in [Table 1](#).

Acetabular injury

Where recorded, 353 of 401 (88%) acetabular fractures followed a high-energy mechanism of injury, such as road traffic collisions. An associated hip dislocation at time of initial injury was reported

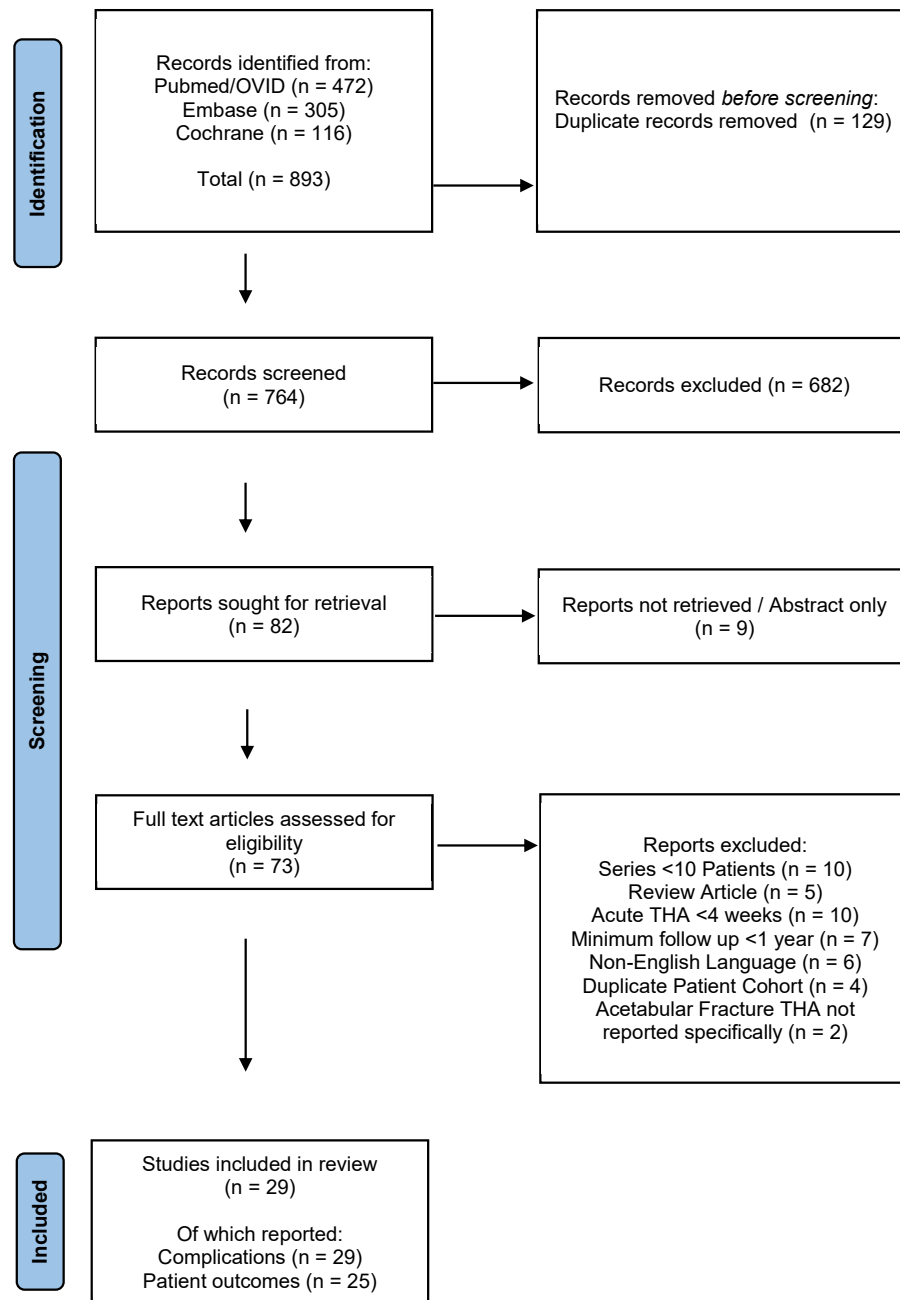


Figure 1. Search results PRISMA flow chart. PRISMA, Preferred Reporting Items for Systematic Review and Meta-Analysis

at a rate of 43% across 294 cases in 8 studies (125 of 294). Regarding fracture type, the Letournel and Judet Classification [45] was used to categorize acetabular fracture pattern in 985 cases across 24 studies, with 48% (477 of 985) assessed as “elementary” and 52% (508 of 985) “associated” type. Where recorded individually, in 16 studies, the ORIF group more commonly followed complex associated fracture types at 60% (298 of 504), while in 7 studies, conservative groups followed elementary type fractures in 54% (74 of 136) of cases. The most common fracture configuration was posterior wall, 30% (277 of 915), followed by associated both column, 14% (127 of 915), posterior column with posterior wall, 12% (107 of 915), posterior wall with transverse, 12% (105 of 915), and transverse, 8% (77 of 915).

At the time of THA surgery, 10 studies with 455 cases reported upon acetabular malunion which was observed in 48 of 455 (10%)

of hips. Femoral head avascular necrosis was observed in 11 of 385 (3.1%) studies, with evidence of previous or existing infection reported in 5 studies at 12% (26 of 218). Acetabular bone deficiency was assessed in 10 studies using the American Association of Orthopedic Surgeons (AAOS) or Paprosky classifications. Across 8 studies with 374 cases, AAOS type I deficiency was reported in 22% (81 of 374), type II in 18% (66 of 374), type III in 15% (57 of 374), and type IV/V in 1.3% (5 of 373). Four ORIF studies reported type I, 17% (26 of 157), type II, 17% (27 of 157), type III, 11% (17 of 157), and type IV, 0.6% (1 of 157) [12,24,35,44], while in 2 conservative group studies, the reported rates were type I, 9% (5 of 57), type II, 25% (14 of 57), type III, 16% (9 of 57), and type IV, 5% (3 of 57) [12,26]. A total of 14 studies reported 64 patients affected by sciatic nerve palsy, related both to the injury itself and primary ORIF. These findings are illustrated in Table 2.

Table 1
Patient demographics and study characteristics.

Study	Number followed (initial THA)	Follow-up (mo)	Years (THA)	Location	Age (y)	Gender (male)	Time post injury (mo)	Control	Oxford level of evidence	Grade rating
Nicol 2021 [19]	14	60 ± 48	2007-2018	The Ottawa Hospital, Ottawa, Canada	76 ± 8	8	22 ± 24 (5-77)	NA	4	Low
Lucchini 2021 [20]	68	142 ± 19.2 (122-212)	2000-2008	Orthopedico Rizzoli, Bologna, Italy	47.7 ± 11.6 (22-75)	60	143 ± 228 (4-480)	NA	4	Low
Kumar 2021 [21]	18	28 (12-60)	2015-2020	King George's Medical University, Lucknow, India	44.7 (20-68)	14	30 (3-60).	NA	4	Low
Kassem 2021 [22]	45	124 (84-180)	NA	Elhadara University Hospital/Elmansoura University Hospital, Egypt	41.4 (32-61)	39	33 (6-80)	NA	4	Very low
Gracia 2021 [23]	39	70 (24-132) ORIF 50 Cons 90	2004-2014	Hôpital Pierre-Paul Riquet, Toulouse, France	54 (20-85); ORIF 59, Cons 49, Control 70	30	29 (4-115)	NA	4	Low
Rezaie 2020 [13]	72	35 (12-146)	2000-2017	Rothman Orthopaedic Institute, Philadelphia, USA	57 (25-89)	37	28 ± 32 (1-141)	Primary THA (n=216)	3	Low
Moon 2020 [24]	37	79 (24-145)	2002-2017	Asan Medical Center, Seoul, South Korea	56.2 (24-81)	27	58 (4-336)	NA	4	Low
Busch 2020 [25]	48 (67)	54 ± 23 (14-88)	2007-2012	BG Trauma Center, Tübingen, Germany	58.5 ± 12.4 (25-87); ORIF 56.2, Cons 63.1	NA	107.3 ± 141.9 (1-504)	NA	4	Low
Garcia Rey 2020 [26]	78	133 (60-276) ORIF 122 Cons 140	1986-2012	Hospital La Paz, Madrid, Spain	56.9 (23-84); ORIF 52.9, Cons 59.3	48	69.4	NA	4	Very low
Do 2020 [27]	25	50 (24-222)	2000-2016	Pusan National University Hospital, Busan, South Korea	58 (36-85)	19	70 (7-213)	NA	4	Very low
Dawson 2019 [4]	25	22	2013-2017	Tallaght University Hospital, Dublin Ireland	53.8	17	28	NA	4	Very low
Taheriazam 2019 [28]	49	44 (24-60)	1998-2015	Erfan and Milad Hospital, Tehran, Iran	(17-68)	43	74 (38-205)	NA	4	Very low
Lee 2019 [29]	57	94 ± 29	2003-2012	Eulji Medical Centre, Seoul, South Korea	52 ± 13.6	31	228 (2-720)	Primary THA (n=57)	3	Low
Wang 2018 [30]	33	138 ± 36 (96-204)	1997-2008	Affiliated Hospital of Jiangnan University, Jiangsu, China	45.1 ± 9.3 (25-68)	21	58 (4-240)	NA	4	Low
Salama 2017 [31]	21	26 (24-36)	2011-2014	San Luigi Hospital of Orbassano, Turin Italy	57 (29-75)	12	NA	NA	4	Very low
Clarke-Jensson 2017 [32]	52	Median 88 (12-252)	1995-2004	Multicentre, 6 Norwegian Hospitals	Median 54 (11-82)	35	48 (1-169)	NA	4	Low
Gavaskar 2017 [33]	44 (47)	ORIF 82 ± 117 Cons 85 ± 16	2006-2010	Parvathy Hospital, Chennai, India	47.9	31	29.2	NA	4	Very low
Morison 2016 [34]	74	120 (24-288)	1987-2011	St Michaels Hospital, Toronto, Canada	51 (25-75)	50	48 (12-288)	Primary THA (n=74)	3	Low
Yuan 2015 [35]	28 (30)	60 (25-120)	1999-2010	Mayo Clinic, Rochester, USA	45 (23-75)	21	107 (4-504)	NA	4	Low
Chiu 2015 [36]	56	120 (60-180)	1996-2010	Taipei Veterans Hospital, Taipei, Taiwan	54.1 (19-86)	39	27 (6-114)	NA	4	Low
Schnaser 2014 [37]	17	77 ± 33	2000-2011	Metrohealth Medical Centre, Cleveland, USA	69 (60-81)	13	35 (9-144)	Primary THA (n=44)	3	Very low
Lizaur Utrilla 2012 [38]	24	101 (60-180)	1992-2005	Hospital General Elda, Alicante, Spain	56.4 (28-77)	19	36 (5-168)	Primary THA (n=48)	3	Low
Lai 2011 [39]	31	76 (37-101)	2000-2003	West China Hospital, Chengdu, China	51 (27-74); ORIF 50, Cons 52	22	67 (9-210)	NA	4	Low
Zhang 2011 [40]	51 (55)	64 (32-123)	1998-2007	Jishuitan Hospital, Beijing, China	46.6 (22-65)	42	79.2 (7-360)	NA	4	Very low
Ranawat 2009 [12]	32	59 (48-116)	1995-2003	Hospital for Special Surgery, New York, USA	52 (20-87)	23	36 (1-227),	NA	4	Low
Bellarbarba 2001 [41]	30	63 (24-140)	1984-1995	Rush-Presbyterian-St Luke's., Chicago, USA	51 (26-86); ORIF 50, Cons 52	14	37 (8-444)	Primary THA (n=204)	3	Very low
Sarkar 2001 [42]	22 (37)	48 (15-168)	1982-2000	University of Ulm, Germany	44 (20-74)	NA	37 (4-235)	NA	4	Very low
Huo 1999 [43]	21	65 (48-104)	1985-1993	Keggi Orthopaedic Foundation, Connecticut, USA	52 (23-78)	19	164 (8-480)	NA	4	Low
Weber 1998 [44]	63 (66)	115 (24-240)	1970-1993	Mayo Clinic, Rochester, USA	52 (19-80)	NA	108	NA	4	Very low

ORIF, open reduction internal fixation group; Cons, conservative (nonoperative) group.

Table 2
Acetabular injury.

Study	Number followed (onital THA)	Fracture management	High mechanism injury	Elemental (Letournel fracture classification)	Associated (Letournel fracture classification)	Other
Nicol 2021 [19]	14	ORIF	10	2; AC 1, Tr 1	12; PC+PW 1, T-Type 2, AC+PH 4, ABC 5	NA
Lucchini 2021 [20]	68	ORIF 50, conservative 18	NA	57; PW 35, PC 3, Tr 19	11; PC+PW 3, T-Type 3, AC+PH 1, ABC 4	Existing sciatic nerve palsy 13
Kumar 2021 [21]	18	ORIF	18	6	NA	Associated dislocation 18, malunion acetabular 2, AVN femoral head 5. existing sciatic nerve palsy 1
Kassem 2021 [22]	45	ORIF 36, conservative 9	NA	33; PW 27, PC 6	12; PC+PW 6, PW+Tr 3, ABC 3	AVN femoral head 10
Gracia 2021 [23]	39	ORIF 19, conservative 20	31, ORIF 13, Cons 18	17; PW 10, PC 1, AC 1, Tr 5. ORIF 8; PW 4, AC 1, Tr 3. Cons 9; PW 6, PC 1, Tr 2	22; T-Type 4, PW+Tr 3, AC+PH 3, ABC 5. ORIF 11; T-Type 3, AC+PH 3, ABC 5. Cons 11; T-Type 1, PW+Tr 3, AC+PH 2, ABC 5.	Associated dislocation 11, ORIF 4, conservative 7. AVN femoral head 3
Rezaie 2020 [13]	72	ORIF	NA	29; PW 21, PC 3, AC 3, Tr 2	41; PC+PW 12, T-Type 1, PW+Tr 11, AC+PH 5, ABC 8	Associated dislocation 37. acetabular malunion 12. AVN femoral head 40
Moon 2020 [24]	37	ORIF	37	18; PW 10, PC 3, AC 2, Tr 3	19; PC+PW 3, T-Type 3, PW+Tr 7, AC+PH 1, ABC 5	Acetabular malunion 4. AVN femoral head 6
Busch 2020 [25]	48 (67)	ORIF 47, conservative 21	NA	29; PW 10, PC 5, AC 5, Tr 9	38; PC+PW 2, T-Type 6, PW+Tr 10, AC+PH 3, ABC 17	Bone loss (AAOS) type I 18, type II 8, type III 15
Garcia Rey 2020 [26]	78	ORIF 29, conservative 49	NA	27; PW 7, PC 9, AW 2, AC 1, Tr 8. ORIF 6; PW 2, PC 3, AC 1. Cons 21; PW 5, PC 6, AW 2, Tr 8	38; PC+PW 12, T-Type 3, PW+Tr 13, ABC 10. ORIF 20; PC+PW 6, T-Type 1, PW+Tr 9, ABC 4. Cons 18; PC+PW 6, T-Type 2, PW+Tr 4, ABC 6	Bone loss (AAOS) ORIF type I 5, type II 9, type III 10. conservative type I 3, II 14, III 9, IV/V 3. existing sciatic nerve palsy 4
Do 2020 [27]	25	ORIF	17	16; PW 13, AC 1, Tr 2	9; PC+PW 1, T-Type 1, AC+PH 1, ABC 6	NA
Dawson 2019 [4]	25	ORIF	23	9; PW 4, PC 3, AC 2	16; PC+PW 3, T-Type 3, PW+Tr 4, ABC 6	Associated dislocation 6. acetabular malunion 1. previous infection 1
Taheriazam 2019 [28]	49	ORIF	NA	NA	NA	Previous infection 2. existing sciatic nerve palsy 4
Lee 2019 [29]	57	ORIF 26, conservative 31	NA	NA	NA	NA
Wang 2018 [30]	33	ORIF 21, conservative 12	NA	NA	NA	Acetabular malunion 4 conservative 4. AVN femoral head 10. existing sciatic nerve palsy 2
Salama 2017 [31]	21	ORIF 17, conservative 4	NA	9	12	AVN femoral head 2. bone loss (Paprovsky) class I 13, class II 6, class III 2
Clarke-Jensson 2017 [32]	52	ORIF	NA	18; PW 12, PC 2, AW 1, AC 2, Tr 1	34; PC+PW 2, T-Type 1, PW+Tr 16, AC+PH 9, ABC 6	NA
Gavaskar 2017 [33]	44 (47)	ORIF 27, conservative 20	NA	28; PW 9, PC 5, AW 1, AC 4, Tr 9. ORIF 16; PW 8, PC 2, AC 1, Tr 5. Cons 12; PW 1, PC 3, AW 1, AC 3, Tr 4	28; PW 9, PC 5, AW 1, AC 4, Tr 9. ORIF 16; PW 8, PC 2, AC 1, Tr 5. Cons 12; PW 1, PC 3, AW 1, AC 3, Tr 4	Acetabular malunion 11, ORIF 2, conservative 9
Morison 2016 [34]	74	ORIF 58, conservative 16	NA	35; PW 23, PC 5, AC 2, Tr 5	39; PC+PW 8, T-Type 8, PW+Tr 7, AC+PH 4, ABC 12	Existing sciatic nerve palsy 10
Yuan 2015 [35]	28 (30)	ORIF	NA	8; PW 6, Tr 2	13; PC+PW 3, T-Type 5, PW+Tr 5	Associated dislocation 6. AVN femoral head 9. previous infection 5. bone loss (AAOS) type I 1, type II 9, type III 1, type IV 1. existing sciatic nerve palsy 7
Chiu 2015 [36]	56	ORIF	NA	NA	NA	Acetabular malunion 0. bone loss (Paprovsky) class I 8, class II 7, class III 5
Schnaser 2014 [37]	17	ORIF 14, conservative 3	8	3; PW 2, Tr 1. ORIF 2; PW 2. Conservative 1; Tr 1	14; PC+PW 5, T-Type 2, AC+PH 2, ABC 5. ORIF 12; T-Type 2, AC+PH 2, ABC 3. Cons 2; ABC 2	Associated dislocation 10
Lizaur Utrilla 2012 [38]	24	ORIF 9, conservative 15	24	10; PW 8, AC 2. ORIF 4; PW 2, AC 2. Cons 6; PW 6.	14; PC+PW 9, T-Type 5. ORIF 5; PC+PW 5. Cons 9; PC+PW 4, T-Type 5.	Associated dislocation 6, ORIF 3, conservative 3. acetabular malunion 0. bone loss (AAOS) type I 5, type II 6, type III 9.
Lai 2011 [39]	31	ORIF 19, conservative 12	30	15, ORIF 8, Cons 7	16, ORIF 11, Cons 5	Bone loss (AAOS) type I 9, type II 3, type III 2. existing sciatic nerve palsy 2
Zhang 2011 [40]	51 (55)		49			

(continued on next page)

Table 3
Surgical technique.

Study	Initial THA	Acetabular implant (uncemented)	Other	Removal metal	Bone grafting	Surgical approach	Blood loss (mL)	Operative time (min)
Nicol 2021 [19]	14	14	Revision type implant 2	NA	NA	Posterior 10, anterolateral 10, lateral 2. ORIF - Kocher Langenbach 2, ilioinguinal 8, stoppa 5, dual 2, hip dislocation 1	NA	153 ± 59
Lucchini 2021 [20]	68	68	NA	8	NA	Anterolateral 68	NA	NA
Kumar 2021 [21]	18	18	NA	15	NA	Posterior 18	530 (350-800)	120 (90-160)
Kassem 2021 [22]	45	28	2-stage procedure 6	10	30	Posterior 45	2025 ORIF 2153 Cons 1514	125 (100-180) ORIF 165 Cons 127
Gracia 2021 [23]	39	35	Dual mobility 18, plate construct 2	7	14	Posterior 39	560 (300-1000) ORIF 425 Cons 688	92 (55-134), ORIF 75, Cons 108.
Rezaie 2020 [13]	72	NA	Cage 2	20	14	Posterior 17, lateral 49, anterior 6. ORIF - Kocher Langenbach 50, ilioinguinal 15, dual 5	483 ± 529 Control 216	153 ± 82 Control 113
Moon 2020 [24]	37	37	NA	NA	NA	Posterior 37	NA	NA
Busch 2020 [25]	67	63	Screw fixation 29, Reinforcement ring 25	NA	55	Lateral 57. ORIF - Kocher Langenbach 25, ilioinguinal 16, dual 5	NA	NA
Garcia Rey 2020 [26]	78	62	Plate construct 2	NA	16	Posterior 78	NA	NA
Do 2020 [27]	25	25	Elevated liner 7	NA	NA	Posterior 25, ORIF - Kocher Langenbach 14, Stoppa 11	NA	NA
Dawson 2019 [4]	25	19	Screw fixation 19, 2-stage procedure 1	NA	9	Posterior 13, anterolateral 12. ORIF - Kocher Langenbach 19, ilioinguinal 4, dual 2	585	91
Taheriazam 2019 [28]	49	47	2-stage procedure 2	NA	NA	NA	NA	NA
Lee 2019 [29]	57	57	NA	NA	NA	Posterior 45, anterolateral 4, dual 7, triradiate 1	795.6 ± 587.8 Control 632	145.3 ± 41.7 Control 123.7
Wang 2018 [30]	33	33	Plate construct 4	4	13	Posterior 45, anterolateral 4, dual 7, triradiate 1	1093. ORIF 1289 Cons 750	172 ORIF 189 Cons 143
Salama 2017 [31]	21	21	Plate construct 2	3	5	Posterior 21. ORIF - Kocher Langenbach 21	NA	96 (55-200)
Clarke-Jensson 2017 [32]	52	19	NA	NA	NA	NA	NA	NA
Gavaskar 2017 [33]	47	47	Screw fixation 47, plate construct 6	NA	19	Posterior 39, anterolateral 8	535 ORIF 448 Cons 652	98 ORIF 86 Cons 115
Morison 2016 [34]	74	74	NA	NA	NA	Posterior 74	NA	NA
Yuan 2015 [35]	30	30	Elevated liner 8, 2-stage procedure 5	NA	10	Posterior 9, anterolateral 21	956	NA
Chiu 2015 [36]	56	56	NA	38	5	Posterior 35, anterolateral 21	NA	NA
Schnaser 2014 [37]	17	16	Screw fixation 10, cage 1	NA	NA	Posterior 12, anterolateral 5. ORIF - Kocher Langenbach 8, ilioinguinal 6	668 ± 547 Control 270	NA
Lizaur Utrilla 2012 [38]	24	24	Screw fixation 24	0	15	Anterolateral 24. ORIF - Kocher Langenbach 7, ilioinguinal 2	NA	81 ± 8.8 (65-96) Control 72.7
Lai 2011 [39]	31	31	NA	NA	14	Posterior 31	648 ORIF 726, Cons 525	123 ORIF 138 Cons 98
Zhang 2011 [40]	55	47	Screw fixation 35, reinforcement ring 5	26	26	Posterior 51, lateral 2, dual 2	NA	NA
Ranawat 2009 [12]	32	32	Screws fixation 17, elevated liner 19	14	16	NA	718 (100-2000) ORIF 721 Cons 711	NA
Bellabarba 2001 [41]	30	30	Elevated liner 9	NA	NA	Posterior 13, transtrochanteric 5	898 (250-2900) ORIF 1150 Cons 647 Control 413	179 (90-300) ORIF 202 Cons 157 Control 122
Sarkar 2001 [42]	37	28	NA	NA	NA	Posterior 22, anterolateral 14, iliofemoral 1	NA	120 (60-225)
Huo 1999 [43]	21	21	NA	NA	9	NA	960 (500-2200)	97 (60-190)
Weber 1998 [44]	66	22	NA	40	15	Posterior 11, anterolateral 19, transtrochanteric 36. ORIF Kocher Langenbach 41, dual 5	NA	170 (90-315)

Table 4
Functional outcomes

Study	Number functional outcome	Follow-up (mo)	Function (preoperative)	Function (postoperative)
Nicol 2021 [19]	14	60 ± 48	NA	Oxford 33.6 ± 8.5 (21-47)
Lucchini 2021 [20]	68	142 ± 19.2 (122-212)	HHS 37.6 ± 14.1 (15-70.5)	HHS 88.4 ± 11.6 (43.5-96.9)
Kumar 2021 [21]	18	28 (12-60)	NA	HHS 89.72 ± 4.24 (82-95)
Kassem 2021 [22]	45	124 (84-180)	Oxford 16.0 ± 4.12 (8-24)	Oxford 39.80 ± 3.08 (33-44)
Gracia 2021 [23]	39	70 (24-132), ORIF 50 (24-132), Cons 90 (24-120)	NA	HHS 85 (60-95), ORIF 83 (60-90), Cons 86.9 (60-95), Oxford 40 (19-48) ORIF 39 (19-47) Cons 40.95 (19-47)
Moon 2020 [24]	37	79 (24-145)	HHS 42.9 (17-70)	HHS 83.5 (29-97)
Busch 2020 [25]	48	54 ± 23 (14-88)	NA	HHS 75.7 ± 21.3 (26.9-100)
Garcia Rey 2020 [26]	78	133 (60-276), ORIF 122 (60-240), Cons 140 (60-276)	HHS 52.0 ORIF 50.2 ± 6.4 Cons 53.1 ± 4.9	HHS 90.6 ORIF 89.5 ± 10.5 Cons 91.3 ± 11.9
Do 2020 [27]	25	50 (24-222)	HHS 41 (18-47)	HHS 88 (77-100)
Taheriazam 2019 [28]	49	44 (24-60)	HHS 47 (31-66)	HHS 89 (79-95)
Lee 2019 [29]	57	94 ± 29 Min 5 years	UCLA Score 3.6 ± 1.3	UCLA 4.9 ± 1.9
Wang 2018 [30]	33	138 ± 36 (96-204)	HHS 44.0 ± 11.9 (27-58) ORIF 45.9 ± 12.1 (27-58) Cons 40.8 ± 11.3 (29-58)	HHS 88.6 ± 5.1 (74-94) ORIF 89.0 ± 5.4 (74-94) Cons 87.9 ± 4.8 (79-94)
Salama 2017 [31]	21	26 (24-36)	HHS 38 (0-70)	HHS 92 (75-100) ORIF 99 (75-100) Cons 85 (79-100)
Clarke-Jensson 2017 [32]	39	Median 88 (12-252)	HHS 53 ± 10	HHS 82 ± 16, Pelvic Centre 88 ± 13, Non-specialist institution 75 ± 6
Gavaskar 2017 [33]	44	ORIF 82 ± 117 Cons 85 ± 16	Oxford ORIF 16.7 ± 2.8 Cons 9 ± 3.7	Oxford ORIF 41.9 ± 3.1, Cons 41.5 ± 3.5
Yuan 2015 [35]	28	60 (25-120)	HHS 39 (3-71)	HHS 82 (21-100)
Schnaser 2014 [37]	17	77 ± 33	NA	HHS 70 ± 25 (19-95)
Lizaur Utrilla 2012 [38]	24	101 (60-180)	HHS 35.1 ± 7.9 (22-52)	HHS 77 ± 16.5 (45-94)
Lai 2011 [39]	31	76 (37-101)	HHS 49 ORIF 50 ± 16 Cons 48 ± 12	HHS 89 ± 5 ORIF 87 ± 6 Cons 91 ± 3
Zhang 2011 [40]	51	64 (32-123)	HHS 49.5 (22-78) ORIF 49.5 (30-78) Cons 54.3 (22-76)	NA
Ranawat 2009 [12]	32	59 (48-116)	HHS 28 (0-56)	HHS 82 (20-100) ORIF 84 Cons 74
Bellabarba 2001 [41]	30	63 (24-140)	HHS 41 (19-55) ORIF 40 (29-55) Cons 41 (19-52)	HHS 82 (20-100) ORIF 84 Cons 74
Sarkar 2001 [42]	22	48 (15-168)	NA	HHS Very Good 10, Good 3, Fair 2, Poor 7
Huo 1999 [43]	21	65 (48-104)	HHS 30	HHS 90
Weber 1998 [44]	63	115 (24-240)	HHS 49	NA

Summary results

Summary results are displayed in [Table 6](#).

Discussion

The most important finding in this study was the improvement in patient-reported clinical outcomes in all studies reporting such in patients who underwent THA in the setting of PTA following acetabular fractures. This study found that clinical improvement was reported throughout short-term and into medium-term follow-up in studies reporting outcomes of patients following THA for PTA following acetabular fractures. In their study of 78 THAs, Garcia Rey et al [26] reported an increase in the HHS from the 6-month and 2-year follow-up, in both ORIF (83.0 to 89.6) and conservative (84.6 to 91.0) cohorts. These scores were maintained for both ORIF and conservative groups at the long-term follow-up (89.5 and 91.3, respectively). Therefore, satisfactory early patient-reported outcomes appear to correlate positively with potentially promising clinical outcomes in the medium- and long-term post-THA for PTA in patients with previous acetabular fractures.

Surgery setting was cited by Clarke-Jensson et al [32] as a possible factor in surgical outcomes. Their study of 52 THAs across 6 Norwegian hospitals, included 40 THA performed in a specialist pelvic institution. A higher postoperative HHS score was noted for those THA performed in the pelvic center, 88 ± 13, compared to those performed in a non-specialist institution, 75 ± 6. This follows findings from general THA studies which have found an association between THA outcomes and complications with both surgeon and hospital volume [46-48].

As highlighted by Aali Rezaie et al [13] who observed markedly raised infection rates in their acetabular fracture THA cohort (6.9% 5 of 72) vs control (0.5% 1 of 204), infection is a major concern when performing THA for patients with a history of prior acetabular fracture. Evidence or suspicion of existing infection was commented on in several studies and posed challenges both in identification and management [4,12,22,28,35,42]. Ranawat et al [12] identified 8 patients with a history of infection composed of 5 from their ORIF cohort and 3 from their conservative cohort. Despite a rigorous preoperative protocol including laboratory investigations, hip aspiration and 5 intraoperative cultures all returning negative, 75% of this group (6/8-4/5 ORIF, 2/3 conservative) went on to experience an infection following THA, while the 24 other patients in the study were unaffected by infection. Similarly, Yuan et al [35] in a study of 30 THA, identified 5 patients with a history of infection following ORIF, for whom THA was performed in a staged format after an antibiotic holiday of 2 weeks with normal inflammatory markers following initial removal of metal with a mean interval of 12 months. Despite these 3 of the 5 hips progressed to prosthetic joint infection necessitating resection arthroplasty, with no infection reported in their other patients. It is thus advisable that surgeons counsel patients with PTA following acetabular fractures appropriately regarding the potential risk of infection and its implications. Clinical and biochemical screening for infection should be incorporated in to the routine preoperative workup of this at-risk patient cohort. Two-stage procedure with use of an antibiotic impregnated cement was used successfully on the basis of intraoperative findings or history of infection for 9 THAs in 3 studies, with no infection reported in these cases at follow-up, and thus should be considered as a means to mitigate this devastating complication [4,22,28].

Table 5
Revision and complications.

Study	Number followed	Follow-up (mo)	Revision	Infection	Infection revision	Dislocation	Dislocation/instability revision	Aseptic loosening revision	Acetabular loosening revision	Femoral loosening revision	Sciatic nerve palsy
Nicol 2021 [19]	14	60 ± 48	3	1	1	NA	0	1	1	0	NA
Lucchini 2021 [20]	68	142 ± 19.2 (122–212)	8	0	0	2	0	2	0	2	NA
Kumar 2021 [21]	18	28 (12–60)	0	1	0	NA	0	0	0	0	NA
Kassem 2021 [22]	45	124 (84–180)	2	0	0	0	0	2	2	0	1
Gracia 2021 [23]	39	70 (24–132) ORIF 50 Cons 90	7	4 ORIF 2 Cons 2	4 ORIF 2 Cons 2	1 ORIF 1	0	2 ORIF 1 Cons 1	NA	NA	1 ORIF 1
Rezaie 2020 [13]	72	35 (12–146)	NA	5	NA	NA	NA	NA	NA	NA	6
Moon 2020 [24]	37	79 (24–145)	4	3	2	3	1	1	1	0	NA
Busch 2020 [25]	48	54 ± 23 (14–88)	8	1	1	NA	1	5	4	1	NA
Garcia Rey 2020 [26]	78	133 (60–276) ORIF 122 Cons 140	6 ORIF 3 Cons 3	0	0	2 ORIF 1 Cons 1	0	6 ORIF 3 Cons 3	5 ORIF 3 Cons 2	1 Cons 1	NA
Do 2020 [27]	25	50 (24–222)	0	0	0	3	0	0	0	0	NA
Dawson 2019 [4]	25	22	0	1	0	0	0	0	0	0	0
Taheriazam 2019 [28]	49	44 (24–60)	NA	2	2	0	0	NA	NA	NA	0
Lee 2019 [29]	57	94 ± 29	0	0	0	1	0	0	0	0	0
Wang 2018 [30]	33	138 ± 36 (96–204)	3 ORIF 2 Cons 1	1 ORIF1	1 ORIF 1	1 ORIF 1	0	0	0	0	0
Salama 2017 [31]	21	26 (24–36)	0	0	0	0	0	0	0	0	NA
Clarke-Jensson 2017 [32]	52	Median 88 (12–252)	11	3	3	4	4	2	2	0	NA
Gavaskar 2017 [33]	44	ORIF 82 ± 117 Cons 85 ± 16	3 ORIF 1 Cons 2	1 ORIF1	1 ORIF1	2 ORIF 1 Cons 1	1 Cons 1	1 Cons 1	1 Cons 1	0	2 Cons 2
Morison 2016 [34]	74	120 (24–288)	24 ORIF 21 Cons 3	5	2	8	7	NA	13 ORIF 2 Cons 11	1	1
Yuan 2015 [35]	28	60 (25–120)	3	3	3	2	0	0	0	0	0
Chiu 2015 [36]	56	120 (60–180)	3	3	0	NA	0	3	3	0	NA
Schnaser 2014 [37]	17	77 ± 33	1	0	0	2	1	0	0	0	NA
Lizaur Utrilla 2012 [38]	24	101 (60–180)	4	1	1	1	1	2	2 Cons 2	1 Cons 1	0
Lai 2011 [39]	31	76 (37–101)	0	0	0	2 ORIF 1 Cons 1	0	0	0	0	1 ORIF 1
Zhang 2011 [40]	51	64 (32–123)	1	0	0	1	0	1	1	1	3
Ranawat 2009 [12]	32	59 (48–116)	6	6 ORIF 4 Cons 2	2	3	1	3	1	2	NA
Bellabarba 2001 [41]	30	63 (24–140)	1	1	0	0	0	1	1	0	NA
Sarkar 2001 [42]	22	48 (15–168)	10	2	2	2	4	3	1	2	NA
Huo 1999 [43]	21	65 (48–104)	1	0	0	0	0	0	0	0	1
Weber 1998 [44]	63	115 (24–240)	17	0	0	0	1	16	9	10	1

Table 6
Summary results.

Demographic	Initial THA: 1220 THA (followed > 12 months): 1174	Mean follow-up: 86 months	Gender (% male): 70%	Time interval following fracture: 71 months
Number of studies: 29				
Injury				
High mechanism: 88% (353/401, 14 studies)	Associated dislocation, 43% (125/294, 8 studies)	Elementary Letournel and Judet: 48% (477/985), 24 studies, PW 30%, PC 6%, AW 0.4%, AC 3%, Tr 8% Previous infection: 1.2% (26/218, 6 studies)	Associated Letournel and Judet: 52% (508/985, 24 studies), PC+PW 12%, Tr 7%, PW+Tr 11%, AC+PH 5%, ABC 14% Bone loss, AAOS classification: 56% (209/374, 8 studies) type-1 2.2%, type-2 18%, type-3 15%, type-4/5 1%	Initial management: ORIF 75% (919/1220), conservative 25% (301/1220) Sciatic nerve injury 10% (64/661, 14 studies)
Acetabular malunion: 10% (48/455, 10 studies)	Femoral head AVN: 30% (118/385, 11 studies)			
Technique				
Uncemented implants: acetabulum 88% (1014/1148, 28 studies), femoral 84% (690/824, 20 studies)	Bone grafting: 39% (294/745, 18 studies) removal of metal: 21% (190/919)	THA approach (24 studies): posterior 64% (670/1042), anterolateral 21% (218/1042)	ORIF approach (9 studies): Kocher Langenbach 63% (187/296), ilioinguinal 17% (51/296), other including dual 20% (58/296)	Mean blood loss: 822 ml (14 studies). Operative time 131 minutes (16 studies)
Functional Harris Hip Score preoperative: 45 (14 studies, 516 THA)	Harris Hip Score postoperative: 86 (18 studies 638 THA)			
Revision				
Total: 9.7% (102/1053, 27 studies at mean 91 months)	Aseptic loosening revision: 5.4% (51/948, 25 studies at mean 89 months)	Infection revision: 2.3% (25/1102 28 studies at mean 89 months)	Dislocation/instability revision: 2.2% (22/105, 26 studies at mean 88 months)	
Modern (THA 2000-2020): 7.7% (34/444, 13 studies at mean 77 months)				
Complications				
Infection: 3.6% (42/1152, 28 studies at mean 86 months), ORIF 5.4% (29/540, 17 studies at mean 76 months)	Dislocation: 4.4% (42/944, 23 studies at mean 92 months), ORIF 4.7% (16/342, 11 studies at mean 82 months)	Intraoperative sciatic nerve injury: 2.5% (17/668, 15 studies)	Heterotopic ossification: 27.8% (195/702, 17 studies)	

Planning THA following previous acetabular fracture whilst hoping to minimize potential dislocation events is not without its challenges, with potential issues centered on implant positioning amid altered bony anatomy, following acetabular protrusion and bone loss reported in the literature, as well as soft-tissue balancing in the presence of previous injury and resultant scarring [49]. Computed tomography was widely utilized in many recent studies in an effort to quantify bone loss at the preoperative planning stage, which may be managed by bone grafting, intracavitary augments, or cup-cage constructs, and identify potential nonunion; which may represent harbingers for potential dislocations [4,20-22,26,33,42]. This study found that dislocation rates following THA for PTA following acetabular fractures were 4.4%, with a subsequent revision rate of 2.2%. These rates are in excess of modern primary THA rates [50], with 5 studies including primary THA as control, and reporting significantly higher rates in the acetabular fracture THA group.

There has been a shift toward uncemented implants for conversion THA following acetabular fracture following high aseptic loosening rates for cemented reported in an early study by Weber et al [44]. Though at shorter follow-up period than their uncemented group, the revision rates due to aseptic loosening observed for cemented were higher than their uncemented counterparts in both acetabular, 20% (9 of 44 at 179 months) vs 0% (0 of 22 at 47 months), and femoral, 17% (8 of 46 at 139 months) vs 10% (2 of 20 at 55 months), implants. A more recent study by Scott et al [49] of 49 cemented also found a high rate of revision due to aseptic loosening of 8% (4 of 48 at mean follow-up 78 months [6-300]). Novel implant designs were used across multiple studies, such as multihole cups with screw augmentation to aid the surgeon gain initial stability [4,12,25,33,38-40] and highly porous tantalum implants which were used by Yuan et al to aid osseointegration [35].

Iatrogenic injury to the sciatic nerve is of utmost concern and obtaining surgical notes and records of the index surgery is important when planning the procedure. Fifteen studies with 668 patients commented upon the presence, or absence, of sciatic nerve palsy postoperatively after 17 THAs, primarily in the ORIF group. Preoperative palsy was recorded in 64 cases, which related both to the initial injury and the index ORIF surgery [12].

There are a number of limitations regarding the findings of this review. Bias may have been introduced in the reporting of complications by virtue of the retrospective nature of included studies which are heterogenic by nature. Additionally, over the studied time frame, there may have been variation in diagnostic criteria and tools which may have affected reporting of results. Our initial search found a number of studies from the same institution with overlapping patient groups [51-54], whereby the series of the largest cohort was selected for inclusion. Statistical analysis for subgroups was limited due to discrepancies in reporting of results amongst included studies.

Conclusion

THA may be beneficial in selected patients experiencing PTA following acetabular fractures, to reduce reported pain levels and improve functional outcomes. There is an increased risk of complications which requires careful consideration when planning the operation and open discussion with prospective patients and caregivers.

Conflicts of interest

The authors declare there are no conflicts of interest. For full disclosure statements refer to <https://doi.org/10.1016/j.artd.2022.101078>.

References

- [1] Matta JM, Merritt PO. Displaced acetabular fractures. *Clin Orthop Relat Res* 1988;230:83–97.
- [2] Melhem E, Riouallon G, Habboubi K, Gabbas M, Jouffroy P. Epidemiology of pelvic and acetabular fractures in France. *Orthop Traumatol Surg Res* 2020;106:831–9. <https://doi.org/10.1016/j.otsr.2019.11.019>.
- [3] Lundin N, Huttunen TT, Berg HE, Marciano A, Felländer-Tsai L, Enocson A. Increasing incidence of pelvic and acetabular fractures. A nationwide study of 87,308 fractures over a 16-year period in Sweden. *Injury* 2021. <https://doi.org/10.1016/j.injury.2021.03.013>.
- [4] Dawson P, Dunne L, Raza H, Quinn M, Leonard M. Total hip arthroplasty for the treatment of osteoarthritis secondary to acetabular fractures treated by open reduction and internal fixation. *Eur J Orthop Surg Traumatol* 2019;29:1049–54. <https://doi.org/10.1007/s00590-019-02406-6>.
- [5] Frietman B, Biert J, Edwards MJR. Patient-reported outcome measures after surgery for an acetabular fracture. *Bone Joint J* 2018;100-B:640–5. <https://doi.org/10.1302/0301-620X.100B5.BJJ-2017-0871.R3>.
- [6] Giannoudis PV, Grotz MR, Papakostidis C, Dinopoulos H. Operative treatment of displaced fractures of the acetabulum. A meta-analysis. *J Bone Joint Surg Br* 2005;87:2–9.
- [7] Chung TC, Chen TS, Hsu YC, Kao FC, Tu YK, Liu PH. Long-term total hip arthroplasty rates in patients with acetabular and pelvic fractures after surgery: a population-based cohort study. *PLoS One* 2020;15:e0231092. <https://doi.org/10.1371/journal.pone.0231092>.
- [8] Khoshbin A, Hoit G, Henry PDG, et al. Risk of total hip arthroplasty after acetabular fracture fixation: the importance of age. *J Arthroplasty* 2021;36:3194–3199.e1. <https://doi.org/10.1016/j.arth.2021.04.025>.
- [9] Henry PDG, Si-Hyeong Park S, Paterson JM, Kreder HJ, Jenkinson R, Wasserstein D. Risk of hip arthroplasty after open reduction internal fixation of a fracture of the acetabulum: a matched cohort study. *J Orthop Trauma* 2018;32:134–40. <https://doi.org/10.1097/BOT.0000000000001048>.
- [10] Verbeek DO, van der List JP, Tissue CM, Helfet DL. Predictors for long-term hip survivorship following acetabular fracture surgery: importance of gap compared with step displacement. *J Bone Joint Surg Am* 2018;100:922–9. <https://doi.org/10.2106/JBJS.17.00692>.
- [11] Giannoudis PV, Tzioupis C, Papatheanassopoulos A, Obakponwwe O, Roberts C. Articular step-off and risk of post-traumatic osteoarthritis. *Evid Today Inj* 2010;41:986–95. <https://doi.org/10.1016/j.injury.2010.08.003>.
- [12] Ranawat A, Zelken J, Helfet D, Buly R. Total hip arthroplasty for posttraumatic arthritis after acetabular fracture. *J Arthroplasty* 2009;24:759–67. <https://doi.org/10.1016/j.arth.2008.04.004>.
- [13] Aali Rezaie A, Blevis K, Kuo FC, Manrique J, Restrepo C, Paivizi J. Total hip arthroplasty after prior acetabular fracture: infection is a real concern. *J Arthroplasty* 2020;35:2619–23. <https://doi.org/10.1016/j.arth.2020.04.085>.
- [14] Griffin SM, Sims SH, Karunakar MA, Seymour R, Haines N. Heterotopic ossification rates after acetabular fracture surgery are unchanged without indomethacin prophylaxis. *Clin Orthop Relat Res* 2013;471:2776–82. <https://doi.org/10.1007/s11999-013-2871-4>.
- [15] Stibolt Jr RD, Patel HA, Huntley SR, Lehtonen EJ, Shah AB, Naranje SM. Total hip arthroplasty for posttraumatic osteoarthritis following acetabular fracture: a systematic review of characteristics, outcomes, and complications. *Chin J Traumatol* 2018;21:176–81. <https://doi.org/10.1016/j.cjtee.2018.02.004>.
- [16] Liberati A, Altman DG, Tetzlaff J, et al. The PRISMA statement for reporting systematic reviews and meta-analyses of studies that evaluate healthcare interventions: explanation and elaboration. *BMJ* 2009;339:b2700. <https://doi.org/10.1136/bmj.b2700>.
- [17] Guyatt GH, Oxman AD, Vist GE, et al. GRADE: an emerging consensus on rating quality of evidence and strength of recommendations. *BMJ* 2008;336:924–6. <https://doi.org/10.1136/bmj.39489.470347.AD>.
- [18] Howick J, Chalmers I, Glasziou P, et al. The 2011 Oxford CEBM levels of evidence. 2011. p. 12. <https://www.cebm.ox.ac.uk/resources/levels-of-evidence/ocbm-levels-of-evidence> [accessed 02.02.22].
- [19] Nicol GM, Sanders EB, Kim PR, Beaulé PE, Gofton WT, Grammatopoulos G. Outcomes of total hip arthroplasty after acetabular open reduction and internal fixation in the elderly-acute vs delayed total hip arthroplasty. *J Arthroplasty* 2021;36:605–11. <https://doi.org/10.1016/j.arth.2020.08.022>.
- [20] Lucchini S, Castagnini F, Giardina F, et al. Cementless ceramic-on-ceramic total hip arthroplasty in post-traumatic osteoarthritis after acetabular fracture: long-term results. *Arch Orthop Trauma Surg* 2021;141:683–91. <https://doi.org/10.1007/s00402-020-03711-0>.
- [21] Kumar D, Singh S, Srivastava S, Singh SK, Singh A, Sharma Y. Outcome of total hip arthroplasty in patients with failed open reduction and internal fixation of acetabular fractures. *J Clin Orthop Trauma* 2021;20:101480. <https://doi.org/10.1016/j.jcot.2021.101480>.
- [22] Kassem MS, Elsayed MA. Total hip replacements following acetabular fractures. 7 to 15 years clinical and radiological results. *Acta Orthop Belg* 2021;87:419–26.
- [23] Gracia G, Laumonerie P, Tibbo ME, Cavaignac E, Chiron P, Reina N. Outcomes of acute versus delayed total hip arthroplasty following acetabular fracture. *Eur J Orthop Surg Traumatol* 2021. <https://doi.org/10.1007/s00590-021-03157-z> [Epub ahead of print].
- [24] Moon JK, Lee J, Yoon PW, Chang JS, Kim JW. Efficacy of total hip arthroplasty after operatively treated acetabular fracture. *Arch Orthop Trauma Surg* 2020;140:973–9. <https://doi.org/10.1007/s00402-020-03447-x>.
- [25] Busch A, Stöckle U, Schreiner A, de Zwaart P, Schäffler A, Ochs BG. Total hip arthroplasty following acetabular fracture: a clinical and radiographic outcome analysis of 67 patients. *Arch Orthop Trauma Surg* 2020;140:331–41. <https://doi.org/10.1007/s00402-019-03272-x>.
- [26] García-Rey E, Sirianni R, García-Cimbrelo E, Sedel L. Total hip arthroplasty after acetabular fracture: does initial treatment make any difference to the outcome? A 5- to 23-year follow-up with clinical and radiological analysis. *Hip Int* 2020;30:339–46. <https://doi.org/10.1177/1120700019836413>.
- [27] Do MU, Shin WC, Moon NH, Kang SW, Suh KT. Cementless total hip arthroplasty after failed internal fixation of acetabular fractures: a single center experience of 25 consecutive patients. *J Orthop Surg (Hong Kong)* 2020;28:2309499020910666. <https://doi.org/10.1177/2309499020910666>.
- [28] Taheriazam A, Saeidinia A. Conversion to total hip arthroplasty in post-traumatic arthritis: short-term clinical outcomes. *Orthop Res Rev* 2019;11:41–6. <https://doi.org/10.2147/ORR.S184590>.
- [29] Lee YK, Kim KC, Kim JW, et al. Use of ceramic-on-ceramic bearing in total hip arthroplasty for posttraumatic arthritis of the hip. *J Orthop Surg (Hong Kong)* 2019;27:2309499019836378. <https://doi.org/10.1177/2309499019836378>.
- [30] Wang T, Sun JY, Zha JJ, Wang C, Zhao XJ. Delayed total hip arthroplasty after failed treatment of acetabular fractures: an 8- to 17-year follow-up study. *J Orthop Surg Res* 2018;13:208. <https://doi.org/10.1186/s13018-018-0909-8>.
- [31] Salama W, Ditto P, Mousa S, et al. Cementless total hip arthroplasty in the treatment after acetabular fractures. *Eur J Orthop Surg Traumatol* 2018;28:59–64. <https://doi.org/10.1007/s00590-017-2021-x>.
- [32] Clarke-Jenssen J, Westberg M, Røise O, et al. Reduced survival for uncemented compared to cemented total hip arthroplasty after operatively treated acetabular fractures. *Injury* 2017;48:2534–9. <https://doi.org/10.1016/j.injury.2017.08.071>.
- [33] Gavaskar AS, Gopalan H, Karthik B, Srinivasan P, Tummala NC. Delayed total hip arthroplasty for failed acetabular fractures: the influence of initial fracture management on outcome after arthroplasty. *J Arthroplasty* 2017;32:872–6. <https://doi.org/10.1016/j.arth.2016.09.007>.
- [34] Morison Z, Moojen DJ, Nauth A, et al. Total hip arthroplasty after acetabular fracture is associated with lower survivorship and more complications. *Clin Orthop Relat Res* 2016;474:392–8. <https://doi.org/10.1007/s11999-015-4509-1>.
- [35] Yuan BJ, Lewallen DG, Hanssen AD. Porous metal acetabular components have a low rate of mechanical failure in THA after operatively treated acetabular fracture. *Clin Orthop Relat Res* 2015;473:536–42. <https://doi.org/10.1007/s11999-014-3852-y>.
- [36] Chiu FY, Lin YP, Hung SH, Su YP, Liu CL. Cementless acetabular reconstruction for arthropathy in old acetabular fractures. *Orthopedics* 2015;38:e934–9. <https://doi.org/10.3928/01477447-20151002-63>.
- [37] Schnaser E, Scarcella NR, Vallier HA. Acetabular fractures converted to total hip arthroplasties in the elderly: how does function compare to primary total hip arthroplasty? *J Orthop Trauma* 2014;28:694–9. <https://doi.org/10.1097/BOT.000000000000145>.
- [38] Lizaur-Utrilla A, Sanz-Reig J, Serna-Berna R. Cementless acetabular reconstruction after acetabular fracture: a prospective, matched-cohort study. *J Trauma Acute Care Surg* 2012;73:232–8. <https://doi.org/10.1097/TA.0b013e31824cf39e>.
- [39] Lai O, Yang J, Shen B, Zhou Z, Kang P, Pei F. Midterm results of uncemented acetabular reconstruction for posttraumatic arthritis secondary to acetabular fracture. *J Arthroplasty* 2011;26:1008–13. <https://doi.org/10.1016/j.arth.2011.02.026>.
- [40] Zhang L, Zhou Y, Li Y, Xu H, Guo X, Zhou Y. Total hip arthroplasty for failed treatment of acetabular fractures: a 5-year follow-up study. *J Arthroplasty* 2011;26:1189–93. <https://doi.org/10.1016/j.arth.2011.02.024>.
- [41] Bellabarba C, Berger RA, Bentley CD, et al. Cementless acetabular reconstruction after acetabular fracture. *J Bone Joint Surg Am* 2001;83:868–76. <https://doi.org/10.2106/00004623-200106000-00008>.
- [42] Sarkar MR, Billharz E, Wachter N, Kinzl L, Bischoff M. Long-term outcome of secondary joint replacement after acetabular fracture. *Eur J Trauma* 2001;27:301–8. <https://doi.org/10.1007/s00068-001-1157-9>.
- [43] Huo MH, Solberg BD, Zatorski LE, Keggi KJ. Total hip replacements done without cement after acetabular fractures: a 4- to 8-year follow-up study. *J Arthroplasty* 1999;14:827–31. [https://doi.org/10.1016/s0883-5403\(99\)90033-5](https://doi.org/10.1016/s0883-5403(99)90033-5).
- [44] Weber M, Berry DJ, Harmsen WS. Total hip arthroplasty after operative treatment of an acetabular fracture. *J Bone Joint Surg Am* 1998;80:1295–305. <https://doi.org/10.2106/00004623-199809000-00008>.
- [45] Mauffrey C, Stacey S, York PJ, Ziran BH, Archdeacon MT. Radiographic evaluation of acetabular fractures: review and update on methodology. *J Am Acad Orthop Surg* 2018;26:83–93. <https://doi.org/10.5435/JAOS-D-15-00666>.
- [46] Malik AT, Jain N, Scharshmidt TJ, Li M, Glassman AH, Khan SN. Does surgeon volume affect outcomes following primary total hip arthroplasty? A systematic review. *J Arthroplasty* 2018;33:3329–42. <https://doi.org/10.1016/j.arth.2018.05.040>.
- [47] Jölbäck P, Rolfson O, Cnudde P, et al. High annual surgeon volume reduces the risk of adverse events following primary total hip arthroplasty: a registry-based study of 12,100 cases in Western Sweden. *Acta Orthop* 2019;90:153–8. <https://doi.org/10.1080/17453674.2018.1554418>.
- [48] Koltsov JCB, Marx RG, Bachner E, McLawhorn AS, Lyman S. Risk-Based hospital and surgeon-volume categories for total hip arthroplasty. *J Bone Joint Surg Am* 2018;100:1203–8. <https://doi.org/10.2106/JBJS.17.00967>.

- [49] Scott CEH, MacDonald D, Moran M, White TO, Patton JT, Keating JF. Cemented total hip arthroplasty following acetabular fracture. *Bone Joint J* 2017;99-B:1399–408. <https://doi.org/10.1302/0301-620X.99B10.BJJ-2016-1261.R2>.
- [50] Agarwal S, Eckhard L, Walter WL, et al. The use of computer navigation in total hip arthroplasty is associated with a reduced rate of revision for dislocation: a study of 6,912 navigated THA procedures from the Australian orthopaedic association national joint replacement registry. *J Bone Joint Surg Am* 2021;103:1900–5. <https://doi.org/10.2106/JBJS.20.00950>.
- [51] Romness DW, Lewallen DG. Total hip arthroplasty after fracture of the acetabulum. Long-term results. *J Bone Joint Surg Br* 1990;72:761–4. <https://doi.org/10.1302/0301-620X.72B5.2211750>.
- [52] Berry DJ, Halasy M. Uncemented acetabular components for arthritis after acetabular fracture. *Clin Orthop Relat Res* 2002;164–7. <https://doi.org/10.1097/00003086-200212000-00020>.
- [53] von Roth P, Abdel MP, Harmsen WS, Berry DJ. Total hip arthroplasty after operatively treated acetabular fracture: a concise follow-up, at a mean of twenty years, of a previous report. *J Bone Joint Surg Am* 2015;97:288–91. <https://doi.org/10.2106/JBJS.N.00871>.
- [54] El-Bakoury A, Khedr W, Williams M, Eid Y, Hammad AS. The outcome of the uncemented acetabular component in delayed total hip arthroplasty following acetabular fractures. *Bone Jt Open* 2021;2:1067–74. <https://doi.org/10.1302/2633-1462.212.BJO-2021-0118.R1>.

Appendix

Search Terms

Medline Ovid Search Strategy

#1 Total hip replacement	'total hip arthroplasty' OR 'total hip replacement' OR THA OR THR OR "arthroplasty, replacement, hip" [Mesh]
#2 Post-traumatic arthritis	'post traumatic arthritis' OR 'post traumatic osteoarthritis' OR arthritis OR "Arthritis" [Mesh]
#3 History acetabular fracture	'acetabular fracture' OR 'acetabulum fracture'
#4 Outcome	Revision OR infection OR complication OR dislocation OR loosening OR fracture OR mortality OR revision OR 'functional outcome' OR 'postoperative complication' OR 'blood loss' OR "Postoperative Complications"[Mesh] OR "Joint Dislocations"[Mesh] OR "Periprosthetic Fractures"[Mesh] OR "Reoperation"[Mesh]

Cochrane Library #1 AND #2 AND #3 AND #4116

#1 Total hip replacement	"total hip arthroplasty" OR THA OR "total hip replacement" OR THR OR MeSH descriptor: [Arthroplasty, replacement, hip] explode all trees
#2 Post-traumatic arthritis	"post traumatic arthritis" OR "post traumatic osteoarthritis" OR arthritis OR MeSH descriptor: [Arthritis] explode all trees
#3 History acetabular fracture	acetabular OR acetabulum OR MeSH descriptor: [Acetabulum] explode all trees
#4 Outcome	"functional outcome" OR revision OR infection OR complication OR "postoperative complication" OR dislocation OR loosening OR "peri-prosthetic fracture" OR fracture OR mortality OR revision OR "blood loss" OR MeSH descriptor: [Reoperation] explode all trees OR MeSH descriptor: [Mortality] explode all trees OR MeSH descriptor: [Infections] explode all trees OR MeSH descriptor: [Intraoperative Complications] explode all trees OR MeSH descriptor: [Postoperative Complications] explode all trees OR MeSH descriptor: [Hip Dislocation] explode all trees OR MeSH descriptor: [Blood Loss, Surgical] explode all trees

Embase Search #1 AND #2 AND #3 AND #4

#1 Total hip replacement	"total hip arthroplasty" OR THA OR "total hip replacement" OR THR OR 'total hip replacement'/exp
#2 Post-traumatic arthritis	'post traumatic arthritis' OR 'post traumatic osteoarthritis' OR 'arthritis' OR 'arthritis'/exp
#3 History acetabular fracture	'acetabul* fracture' OR 'acetabulum fracture'/exp
#4 Outcome	'functional outcome' OR revision OR infection OR complication OR 'postoperative complication' OR dislocation OR loosening OR 'peri-prosthetic fracture' OR fracture OR mortality OR revision OR 'blood loss' OR 'revision arthroplasty'/exp OR 'mortality'/exp OR 'infection'/exp OR 'postoperative complication'/exp OR 'perioperative complication'/exp OR 'hip dislocation'/exp