

2-15-2023

Atezolizumab-Induced Psoriasiform Drug Eruption Successfully Treated with Ixekizumab: A Case Report and Literature Review

Laura Gleason
Thomas Jefferson University

E Hunter
Thomas Jefferson University

Alexa J. Cohen
Thomas Jefferson University

Jayson Suriano
Thomas Jefferson University

Neda Nikbakht
Thomas Jefferson University
Follow this and additional works at: <https://jdc.jefferson.edu/dcbfp>

 Part of the [Dermatology Commons](#)

[Let us know how access to this document benefits you](#)

Recommended Citation

Gleason, Laura; Hunter, E; Cohen, Alexa J.; Suriano, Jayson; and Nikbakht, Neda, "Atezolizumab-Induced Psoriasiform Drug Eruption Successfully Treated with Ixekizumab: A Case Report and Literature Review" (2023). *Department of Dermatology and Cutaneous Biology Faculty Papers*. Paper 179.
<https://jdc.jefferson.edu/dcbfp/179>

This Article is brought to you for free and open access by the Jefferson Digital Commons. The Jefferson Digital Commons is a service of Thomas Jefferson University's [Center for Teaching and Learning \(CTL\)](#). The Commons is a showcase for Jefferson books and journals, peer-reviewed scholarly publications, unique historical collections from the University archives, and teaching tools. The Jefferson Digital Commons allows researchers and interested readers anywhere in the world to learn about and keep up to date with Jefferson scholarship. This article has been accepted for inclusion in Department of Dermatology and Cutaneous Biology Faculty Papers by an authorized administrator of the Jefferson Digital Commons. For more information, please contact: JeffersonDigitalCommons@jefferson.edu.

UC Davis

Dermatology Online Journal

Title

Atezolizumab-induced psoriasiform drug eruption successfully treated with ixekizumab: a case report and literature review

Permalink

<https://escholarship.org/uc/item/89n6g1hh>

Journal

Dermatology Online Journal, 29(1)

Authors

Gleason, L
Hunter, E
Cohen, A
et al.

Publication Date

2023

DOI

10.5070/D329160215

Copyright Information

Copyright 2023 by the author(s). This work is made available under the terms of a Creative Commons Attribution-NonCommercial-NoDerivatives License, available at <https://creativecommons.org/licenses/by-nc-nd/4.0/>

Peer reviewed

Atezolizumab-induced psoriasiform drug eruption successfully treated with ixekizumab: a case report and literature review

L Gleason BS, E Hunter BS, A Cohen BS, J Suriano BA, N Nikbakht MD PhD

Affiliations: Department of Dermatology and Cutaneous Biology, Thomas Jefferson University, Philadelphia, Pennsylvania, USA

Corresponding Author: Neda Nikbakht MD PhD, Department of Dermatology and Cutaneous Biology, 33 South 9th Street, Suite 740, Philadelphia, PA 19107, Tel: 215-503-4834, Fax: 215-503-5788, Email: neda.nikbakht@jefferson.edu

Abstract

Immune-related cutaneous adverse events (ircAE) are commonly seen with immune checkpoint inhibitors such as atezolizumab. Atezolizumab-induced psoriasis has been previously reported as an ircAE, especially in patients with pre-existing psoriasis. The severity of the reaction influences treatment of the cutaneous eruption. Biologics should be considered as a treatment option for severe refractory psoriasiform eruptions even in patients with complex medical conditions like chronic infections and malignancy. This is the first reported case of successful treatment of atezolizumab-induced psoriasiform eruption with ixekizumab, a neutralizing IL17A monoclonal antibody, to the best of our knowledge. Herein, we present a 63-year-old man with a history of human immunodeficiency virus and psoriasis who presented with atezolizumab-induced psoriasiform eruption while being treated for metastatic hepatocellular carcinoma. After initiating ixekizumab, atezolizumab was restarted without cutaneous eruption.

Keywords: atezolizumab, ixekizumab, psoriasis

Introduction

Psoriasiform drug eruption describes a group of cutaneous disorders that clinically and histologically simulate psoriasis, a commonly encountered, chronic, immune-mediated inflammatory condition. Anti-programmed death 1 or its receptor (PD1/PDL1) immunotherapy, like atezolizumab, are commonly

associated with immune-related cutaneous adverse events (ircAEs) such as psoriasiform drug eruptions [1,2]. The severity of the ircAE is assessed using the Common Terminology Criteria for Adverse Events grading scale [2]. Typically, Grade 1-2 cutaneous eruptions related to PD1/PDL1 inhibitors are mild-to-moderate rashes that cover less than 30% of the body surface area and are associated with mild symptoms, such as pruritus, burning or tightness. These lesions are usually reversible with high-potency topical corticosteroids and phototherapy [2,3]. In contrast, Grade 3-4 lesions cover greater than 30% of the body surface area and are associated with severe symptoms or life-threatening consequences. Therefore, the severity of the ircAE greatly influences the approach to treatment. If patients experience Grade 3 or 4 cutaneous eruptions, immune checkpoint inhibitors may be discontinued and biologic treatment may be pursued [2,3]. The decision to treat with a biologic becomes difficult when patients have concurrent complex medical conditions like chronic infections and malignancy. We report successful treatment of atezolizumab-induced psoriasiform drug eruption with ixekizumab in the setting of HIV and metastatic hepatocellular carcinoma.

Case Synopsis

A 63-year-old man with a history of HIV and psoriasis presented to the dermatology clinic for evaluation of an acute diffuse eruption involving 80% of the body surface area a week following the third cycle of

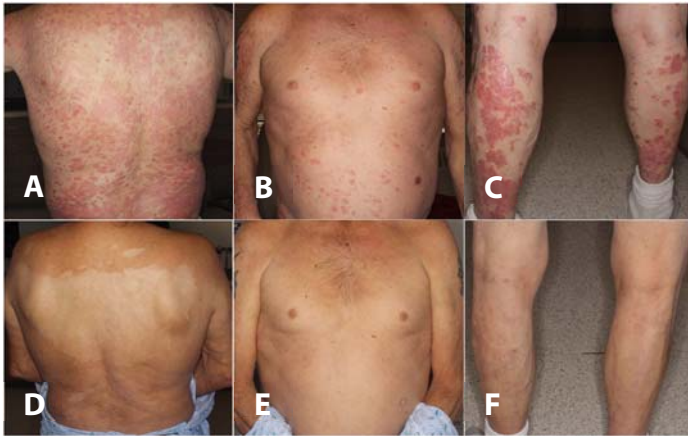

Figure 1. Salmon-colored papules and plaques coalescing into confluent plaques on the patient's **A)** back, **B)** chest, and **C)** lower extremities. **D-F)** Resolution of plaques following four months of treatment with ixekizumab.

combination treatment with atezolizumab (PDL1 inhibitor) and bevacizumab (vascular endothelial growth factor [VEGF] inhibitor) for metastatic hepatocellular carcinoma. The patient's previous history of psoriasis consisted of limited scalp involvement. The rash rapidly developed over the course of a few days and was associated with severe pruritus and skin tightness. Owing to the diffuse involvement and severe symptoms, his oncologist discontinued atezolizumab for the fourth cycle of treatment and prescribed oral prednisone and clobetasol for the rash.

On presentation to the dermatology clinic, physical examination revealed multiple salmon-colored papules and plaques coalescing into confluent plaques on the patient's upper extremities, trunk, back, and lower extremities (**Figure 1A-C**). Skin biopsy revealed parakeratosis and acanthosis with neutrophils in the stratum corneum and dilated papillary vessels with a perivascular inflammatory cell infiltrate (**Figure 2**). With clinical correlation, atezolizumab-induced psoriasiform drug eruption was diagnosed. The patient's lesions did not respond to topical therapies and systemic corticosteroids, so ixekizumab, a neutralizing IL17A monoclonal antibody (loading dose of 160mg, followed by 80mg once every two weeks), was started. The patient was able to restart atezolizumab for the fifth treatment cycle. Four months following initiation of ixekizumab, the psoriasiform eruption had completely resolved and the patient was able to

continue combination treatment with atezolizumab without cutaneous eruption (**Figure 1D-F**). Unfortunately, the patient passed away a few months after follow-up due to complications related to metastatic disease.

Case Discussion

Atezolizumab, a monoclonal antibody targeting PD1/PDL1, has been approved in the United States for treatment for various types of cancers, such as urothelial carcinoma, non-small cell lung cancer, and hepatocellular carcinoma [4-6]. Atezolizumab is different from other anti-PD1 antibodies by blocking the PDL1 and PD1 interaction as well as the PDL1 and CD80 interaction [4]. Due to its interference with PD1, atezolizumab and other PD1 inhibitors commonly cause psoriasiform eruptions since cytotoxic CD8 T cells are activated and promote Th17, IL6, and IL17 development [1,7-9].

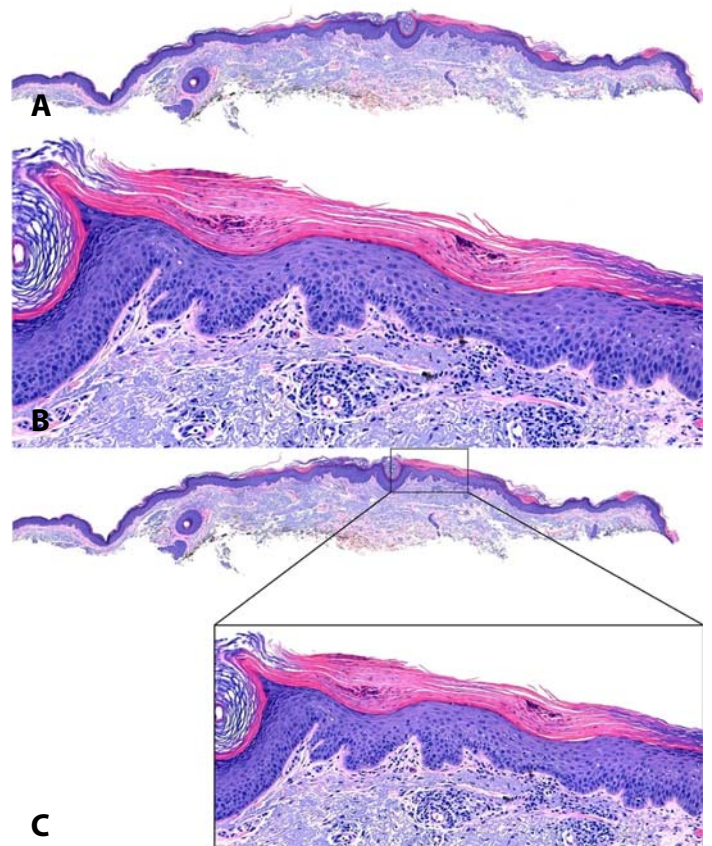


Figure 2. H&E histopathology of shave biopsy demonstrates parakeratosis and acanthosis, 40 \times . Inset, higher magnification reveals neutrophils in the stratum corneum, dilated vessels within the papillary dermis, and a perivascular inflammatory cell infiltrate, 100 \times .

Table 1. Characteristics, treatment, and outcomes associated with atezolizumab-induced psoriasis.

Sex, age (years), reference	History of psoriasis	Indication for PD1 inhibitor	Anti-PD1 discontinued	Treatment	Outcome
Male, 53 [13]	Yes	Non-small cell lung cancer	Yes	Flumethasone ointment Desloratadine 5mg daily	Improved
Male, 63 This report	Yes	Metastatic hepatocellular carcinoma	Yes	Clobetasol ointment Prednisone 20mg daily Ixekizumab	Improved
Male, 65 [14]	Yes	Lung cancer (type unspecified)	No	Phototherapy	Improved
Male, 70 [15]	No	Squamous cell carcinoma of the lung	No	Calcipotriol- betamethasone dipropionate combination ointment	Improved
Male, 75 [16]	Yes	Metastatic urothelial carcinoma	Yes	Clobetasol cream Prednisone 30mg daily Bilastine 20mg BID	Improved

In cases of unresectable or metastatic hepatocellular carcinoma, atezolizumab is used in combination with bevacizumab, a VEGF inhibitor [6]. Cutaneous adverse events have been described with VEGF inhibitors as well. Overall, cutaneous toxicities vary within the drug class. However, bevacizumab has been reported to increase the risk of hand-foot skin syndrome, also known as palmar-plantar erythrodysesthesia, when used in conjunction with multikinase inhibitors [10]. Furthermore, bevacizumab has been reported to cause cutaneous tumor lysis syndrome during the treatment of metastatic salivary duct carcinoma in combination with temsirolimus [11]. It is unlikely that the psoriasiform eruption described in the current case is due to bevacizumab since VEGF inhibitors have not been reported to cause psoriasiform eruptions. Furthermore, VEGF inhibitors have been hypothesized as a potential therapeutic agent for psoriasis and Akman et al. describe complete remission of psoriasis following bevacizumab therapy for metastatic colon cancer [12].

Several cases documented atezolizumab-induced psoriasis [13-16], (**Table 1**). Our case is the fifth reported occurrence of atezolizumab-induced psoriasis but the first to be treated with ixekizumab (**Table 1**), to the best of our knowledge. Four (80%) patients had a previous history of psoriasis, indicating that personal psoriasis-related history can be a significant risk factor for atezolizumab-induced

psoriasis (**Table 1**). The eruptions improved in all patients by a variety of treatment modalities. Atezolizumab was not discontinued in two patients whose eruptions improved with either phototherapy or topical corticosteroids (**Table 1**). Four (80%) patients were treated with topical corticosteroids and two out of four of those patients were also treated with oral prednisone (**Table 1**).

In our case, the patient's eruption did not improve after a trial of clobetasol ointment and oral prednisone. The patient started ixekizumab, which is indicated as a monotherapy treatment option for patients with refractory moderate-to-severe plaque psoriasis [17]. Ixekizumab specifically binds and inhibits IL17A, interfering with the formation of a psoriasiform eruption by disrupting the psoriatic inflammatory loop [17]. After initiating ixekizumab, atezolizumab was restarted without another cutaneous eruption. Additionally, ixekizumab has been shown to effectively treat psoriasis in patients with HIV by intervening with the formation of the cutaneous eruption without interfering with the effectiveness of antiretroviral therapy [18]. It should be noted that patients with HIV receiving antiretroviral therapies should have a low viral load before initiating biologic treatment [19]. Overall, this is the first reported case to utilize ixekizumab to treat refractory atezolizumab-induced psoriasiform eruption in the setting of complex medical conditions.

Conclusion

This case provides evidence that ixekizumab is a safe and effective treatment for atezolizumab-induced psoriasis in patients with complex medical conditions who do not respond to typical treatments. Furthermore, providers need to be aware of potential psoriasis exacerbations when

treating with atezolizumab, especially in patients who have a history of psoriasis.

Potential conflicts of interest

The authors declare no conflicts of interest

References

- Balak D, Hajdarbegovic E. Drug-induced psoriasis: clinical perspectives. *Psoriasis (Auckl)*. 2017;7:87-94. [PMID: 29387611].
- Geisler AN, Phillips GS, Barrios DM, et al. Immune checkpoint inhibitor-related dermatologic adverse events. *J Am Acad Dermatol*. 2020;83:1255-1268. [PMID: 32454097].
- Phillips GS, Wu J, Hellmann MD, et al. Treatment Outcomes of Immune-Related Cutaneous Adverse Events. *J Clin Oncol*. 2019;37:2746-58. [PMID: 31216228].
- Ning Y, Suzman D, Maher VE, et al. FDA Approval Summary: Atezolizumab for the Treatment of Patients with Progressive Advanced Urothelial Carcinoma after Platinum-Containing Chemotherapy. *Oncologist*. 2017; 22:743-749. [PMID: 28424325].
- Weinstock C, Khozin S, Suzman D, et al. U.S. Food and Drug Administration Approval Summary: Atezolizumab for Metastatic Non-Small Cell Lung Cancer. *Clin Cancer Res*. 2017;23:4534-4539. [PMID 28611199].
- Casak SJ, Donoghue M, Fashoyin-Aje L, et al. FDA Approval Summary: Atezolizumab Plus Bevacizumab for the Treatment of Patients with Advanced Unresectable or Metastatic Hepatocellular Carcinoma. *Clin Cancer Res* 2021; 27: 1836-1841. [PMID 33139264].
- Shah NJ, Kelly WJ, Liu SV, Choquette K, Spira A. Product review on the Anti-PDL1 antibody atezolizumab. *Hum Vaccin Immunother*. 2018;14:269-276. [PMID: 29194007].
- Tanaka R, Ichimura Y, Kubota N, et al. Activation of CD8 T cells accelerates anti-PD1 antibody-induced psoriasis-like dermatitis through IL6. *Commun Biol*. 2020;3. [PMID: 33060784].
- Lynde CW, Poulin Y, Vender R, Bourcier M, Khalil S. Interleukin 17A: toward a new understanding of psoriasis pathogenesis. *J Am Acad Dermatol*. 2014;71:141-50. [PMID: 24655820].
- Zhu Y, Zhang X, Lou X, et al. Vascular endothelial growth factor (VEGF) antibody significantly increases the risk of hand-foot skin reaction to multikinase inhibitors (MKIs): A systematic literature review and meta-analysis. *Clin Exp Pharmacol Physiol*. 2018;45:659-667. [PMID: 29543385].
- Cohen PR, Prieto VG, Kurzrock R. Tumor Lysis Syndrome: Introduction of a Cutaneous Variant and a New Classification System. *Cureus*. 2021;11;13. [PMID: 33859885].
- Akman A, Yilmaz E, Mutlu H, Ozdogan M. Complete remission of psoriasis following bevacizumab therapy for colon cancer. *Clin Exp Dermatol*. 2008;34:202-204. [PMID: 19077094].
- Mao M, Shi M, Li T, Wang Q, Wu L. Atezolizumab-induced psoriasis in a patient with metastatic lung cancer—a case report. *Transl Cancer Res*. 2020;9:3776-82. [PMID: 35117743].
- Bonigen J, Raynaud-Donzel C, Hureauux J, et al. Anti-PD1-induced psoriasis: a study of 21 patients. *J Eur Acad Dermatol Venereol* 2017;31:254-7 [PMID: 27739129].
- Iijima S, Miyazaki K, Sato S, Kodama T. A case of de novo psoriasis induced by atezolizumab in a patient with advanced lung cancer. *J Cutan Immunol Allergy*. 2019;2:178-9. [DOI: 10.1002/cia2.12087].
- Santos-Juanes J, Munguia-Calzada P, Alvarez-Fernandez C. Plaque Psoriasis Flare and Peripheral Edema in a Patient Treated with Atezolizumab. *Actas Dermosifiliogr* 2019;110:410-1. [PMID: 30366590].
- Farahnik B, Beroukhi K, Zhu TH, et al. Ixekizumab for the Treatment of Psoriasis: A Review of Phase III Trials. *Dermatol Ther*. 2016;6:25-37. [PMID: 26910853].
- Pangilinan MCG, Sermswan P, Asawanonda P. Use of Anti-IL17 Monoclonal Antibodies in HIV Patients with Erythrodermic Psoriasis. *Case Rep Dermatol*. 2020;12:132-7. [PMID: 32999648].
- Menter A, Strober BE, Kaplan DH, et al. Joint AAD-NPF guidelines of care for the management and treatment of psoriasis with biologics. *J Am Acad Dermatol*. 2019;80:1029-72. [PMID: 30772098].