

7-1-2022

Effect of Preoperative MRI Coracoid Dimensions on Postoperative Outcomes of Latarjet Treatment for Anterior Shoulder Instability.

Ryan W. Paul
Thomas Jefferson University

Dennis A DeBernardis
Rowan University

Daniel Hameed
Thomas Jefferson University

Ari Clements
Thomas Jefferson University

Sarah Kamel, MD
Thomas Jefferson University
Follow this and additional works at: https://jdc.jefferson.edu/rothman_institute

 Part of the [Medicine and Health Sciences Commons](#)

See next page for additional authors

[Let us know how access to this document benefits you](#)

Recommended Citation

Paul, Ryan W.; DeBernardis, Dennis A; Hameed, Daniel; Clements, Ari; Kamel, MD, Sarah; Freedman, MD, Kevin; and Bishop, Meghan, "Effect of Preoperative MRI Coracoid Dimensions on Postoperative Outcomes of Latarjet Treatment for Anterior Shoulder Instability." (2022). *Rothman Institute Faculty Papers*. Paper 178.

https://jdc.jefferson.edu/rothman_institute/178

This Article is brought to you for free and open access by the Jefferson Digital Commons. The Jefferson Digital Commons is a service of Thomas Jefferson University's [Center for Teaching and Learning \(CTL\)](#). The Commons is a showcase for Jefferson books and journals, peer-reviewed scholarly publications, unique historical collections from the University archives, and teaching tools. The Jefferson Digital Commons allows researchers and interested readers anywhere in the world to learn about and keep up to date with Jefferson scholarship. This article has been accepted for inclusion in Rothman Institute Faculty Papers by an authorized administrator of the Jefferson Digital Commons. For more information, please contact: JeffersonDigitalCommons@jefferson.edu.

Authors

Ryan W. Paul; Dennis A DeBernardis; Daniel Hameed; Ari Clements; Sarah Kamel, MD; Kevin Freedman, MD; and Meghan Bishop

Effect of Preoperative MRI Coracoid Dimensions on Postoperative Outcomes of Latarjet Treatment for Anterior Shoulder Instability

Ryan W. Paul,* BS, Dennis A. DeBernardis,* DO, Daniel Hameed,† BA, Ari Clements,‡ BA, Sarah I. Kamel,§ MD, Kevin B. Freedman,* MD, and Meghan E. Bishop,||¶ MD

Investigation performed at Rothman Orthopaedic Institute, New York, New York, USA

Background: Preoperative coracoid dimensions may affect the size of the bone graft transferred to the glenoid rim and thus the postoperative outcomes of Latarjet coracoid transfer.

Purpose: To determine the effect of coracoid length and width as measured on preoperative magnetic resonance imaging (MRI) on outcomes after Latarjet treatment of anterior shoulder instability.

Study Design: Cohort study; Level of evidence, 3.

Methods: Included were patients who underwent primary Latarjet surgery between 2009 and 2019 and had preoperative MRI scans and minimum 2-year postoperative outcomes. Longitudinal coracoid length was measured on axial MRI sequences as the distance from the coracoclavicular ligament insertion to the distal tip. Comparisons were made between shorter and longer coracoids and between narrower and wider coracoids. The outcomes of interest were recurrent instability, reoperation, complications, return to sport (RTS), and American Shoulder and Elbow Surgeons (ASES) score. Independent-samples *t* test, Mann-Whitney test, chi-square test, and Fisher exact test were used to compare outcomes between groups, and univariate correlation coefficients were calculated to evaluate the relationships between demographics and coracoid dimensions.

Results: Overall, 56 patients were included (mean age, 28.4 years). The mean \pm SD coracoid length was 21.6 ± 2.4 mm and width 10.0 ± 1.0 mm. Relative to patients with a longer coracoid (≥ 22 mm; $n = 26$), patients with a shorter coracoid (< 22 mm; $n = 30$) had similar rates of recurrent instability (shorter vs longer; 6.7% vs 3.8%), complications (10.0% vs 15.4%), reoperation (3.3% vs 7.7%), and RTS (76.5% vs 58.8%) and similar postoperative ASES scores (85.0 vs 81.6) ($P \geq .05$ for all). Likewise, relative to patients with a wider coracoid (≥ 10 mm; $n = 27$), patients with a narrower coracoid (< 10 mm; $n = 29$) had similar prevalences of recurrent instability (narrower vs wider; 6.9% vs 3.7%), complications (17.2% vs 7.4%), reoperation (3.5% vs 7.4%), and RTS (66.7% vs 68.4%) and similar postoperative ASES scores (87.1 vs 80.0) ($P \geq .05$ for all).

Conclusion: Patients undergoing Latarjet coracoid transfer had similar postoperative outcomes regardless of preoperative coracoid dimensions. These findings should be confirmed in a larger cohort before further clinical recommendations are made.

Keywords: shoulder; Latarjet; coracoid; instability; MRI

The shoulder is the most inherently unstable joint in the human body, with primary shoulder dislocation rates ranging from 23 to 24 per 100,000 person-years in the general population and 98 per 100,000 person-years for young men.^{18,20,29} Once a patient experiences a primary anterior shoulder dislocation, 39% will develop recurrent instability.²⁴ Surgical intervention is often recommended after primary anterior shoulder dislocation, especially in young

active patients, to minimize the chances of recurrent instability.^{3,17,22}

Several surgical interventions are available for patients with shoulder instability, such as Bankart repair, capsulorrhaphy, and bone graft fixations into a glenoid defect (usually a Latarjet procedure). Notably, Burkhart and De Beer⁷ found that 67% of patients with glenoid deformity (inverted glenoid pear appearance) develop recurrent instability, while only 6.5% without bony deformity experienced recurrent instability after arthroscopic stabilization. Recognition of the need to address bone defects of the glenoid has been well studied, and one such procedure is the Latarjet

The Orthopaedic Journal of Sports Medicine, 10(7), 23259671221083967

DOI: 10.1177/23259671221083967

© The Author(s) 2022

This open-access article is published and distributed under the Creative Commons Attribution - NonCommercial - No Derivatives License (<https://creativecommons.org/licenses/by-nc-nd/4.0/>), which permits the noncommercial use, distribution, and reproduction of the article in any medium, provided the original author and source are credited. You may not alter, transform, or build upon this article without the permission of the Author(s). For article reuse guidelines, please visit SAGE's website at <http://www.sagepub.com/journals-permissions>.

coracoid transfer. The Latarjet procedure utilizes a coracoid bone block for restoration of the glenoid surface but also provides stability through additional mechanisms. The procedure has been proposed to work by 3 stabilizing mechanisms: (1) the buttress effect of the coracoid bone, (2) the sling effect of the conjoint tendon and subscapularis, and (3) reinforcement by capsular duplication with the released coracoacromial ligament.^{5,8}

Preoperative coracoid dimensions—namely, the length and width of the coracoid—may affect the size of bone graft transferred to the glenoid rim and postoperative outcomes of Latarjet coracoid transfer. Young et al²⁸ advised the use of a coracoid bone graft length >25 mm for the Latarjet procedure to enable safe insertion of two 4.5-mm screws. However, a study examining the morphometric analysis of the coracoid process utilizing computed tomography (CT) demonstrated significant differences in dimensions based on age, sex, and ethnicity.¹⁴ Thus, it cannot be assumed that all patients have coracoid dimensions adequate for the Latarjet procedure, and the identification of preoperative coracoid dimensions may help clinicians identify strong candidates for surgery. If coracoid dimensions are insufficient, an alternative bone-grafting procedure may be considered, such as distal tibial allograft or iliac crest grafting.^{6,15,23}

While preoperative coracoid dimensions have been evaluated utilizing CT, the authors could not identify any studies measuring coracoid dimensions with magnetic resonance imaging (MRI) before Latarjet surgery. Also, no studies have evaluated postoperative outcomes based on preoperative coracoid dimensions in Latarjet cases. Finally, utilizing MRI instead of CT to evaluate preoperative coracoid dimensions may improve the safety and cost-effectiveness of surgical planning before Latarjet surgery. Therefore, the purpose of this study is to determine the effect of coracoid length and width, as measured on preoperative MRI, on outcomes after Latarjet treatment of anterior shoulder instability. We hypothesized that patients with longer and wider coracoid dimensions would have improved postoperative outcomes after Latarjet treatment for anterior shoulder instability.

METHODS

Inclusion/Exclusion Criteria

This retrospective cohort study was determined to be exempt from institutional review board approval due to the

minimal risk involved with retrospective survey completion and chart review. Patients who had undergone a primary Latarjet procedure as treatment for anterior glenohumeral joint instability from 2010 to 2019 were identified with Current Procedural Terminology code 23462. Common indications for a primary Latarjet procedure included significant glenoid bone loss, recurrent instability after Bankart repair, and participation in high-risk sport. All Latarjet procedures were performed according to the standard technique, with the coracoid osteotomy performed anterior to the coracoclavicular (CC) ligaments and fixation of the coracoid graft to the anteroinferior glenoid with 2 screws. Graft orientation and any concomitant procedures, such as capsular shift or labral repair, were decided by the operating surgeon. Latarjet surgery cases with minimum 2-year follow-up and preoperative MRI of the affected shoulder were included. Patients were excluded if they had a history of ipsilateral shoulder infection, a lack of preoperative MRI, or a history of connective tissue disorder.

Data Collection

Physician chart notes and operative reports were reviewed to collect the following preoperative data: age, sex, hand dominance, surgery laterality, level of sport participation (none, recreational, competitive), contact sport participation, surgical history, and prevalence of chronic recurrent instability (history of ≥ 5 shoulder dislocations). Intraoperative data were also collected, including the number of screws used for fixation of the coracoid graft, concomitant surgery, and complications. Postoperative complications, recurrent instability, and reoperation were collected from postoperative physician and operative notes. Patients were contacted via RedCap (Vanderbilt University) to complete American Shoulder and Elbow Surgeons (ASES) scores and return to sport (RTS) outcomes at a minimum 2 years postoperatively. Patients who were participating in sport before surgery were included in RTS analysis.

Preoperative 2-dimensional MRI scans were analyzed for coracoid length and width by 3 independent reviewers: 2 research assistants and an orthopaedic surgery resident (R.W.P., D.A.D., D.H.) trained in coracoid dimension measurements by a musculoskeletal radiologist. Instead of measuring longitudinal coracoid length according to previously published CT techniques,^{14,19} coracoid length was measured on axial MRI sequences as the distance from the CC ligament insertion to the distal tip to maximize clinical

*Address correspondence to Meghan E. Bishop, MD, Rothman Orthopaedic Institute, 645 Madison Ave, Third and Fourth Floors, New York, NY 10022, USA (email: meghan.bishop@rothmanortho.com).

*Rothman Orthopaedic Institute, Philadelphia, Pennsylvania, USA.

†Cooper Medical School of Rowan University, Camden, New Jersey, USA.

‡Sidney Kimmel Medical College, Philadelphia, Pennsylvania, USA.

§Department of Radiology, Thomas Jefferson University Hospital, Philadelphia, Pennsylvania, USA.

||Rothman Orthopaedic Institute, New York, New York, USA.

Final revision submitted December 5, 2021; accepted December 15, 2021.

One or more of the authors has declared the following potential conflict of interest or source of funding: K.B.F. has received education payments from Liberty Surgical, consulting fees from DePuy/Medical Device Business Services, and speaking fees and honoraria from Vericel. M.E.B. has received grant funding from Arthrex, education payments from Arthrex and Smith & Nephew, and hospitality payments from Smith & Nephew. AOSSM checks author disclosures against the Open Payments Database (OPD). AOSSM has not conducted an independent investigation on the OPD and disclaims any liability or responsibility relating thereto.

Ethical approval was waived for this study from Thomas Jefferson University (No. 20E.1089).

applicability (Figure 1). Because the CC ligament insertion and the distal tip of the coracoid were often on different MRI slices, a specific measurement protocol was utilized by all 3 reviewers (Figure 2). Once the insertion of the CC ligament was identified, the cursor was placed on this insertion. The reviewer scrolled inferiorly until the tip of the coracoid was in view and then found the linear distance from the cursor's current location (insertion of CC ligament) to the coracoid

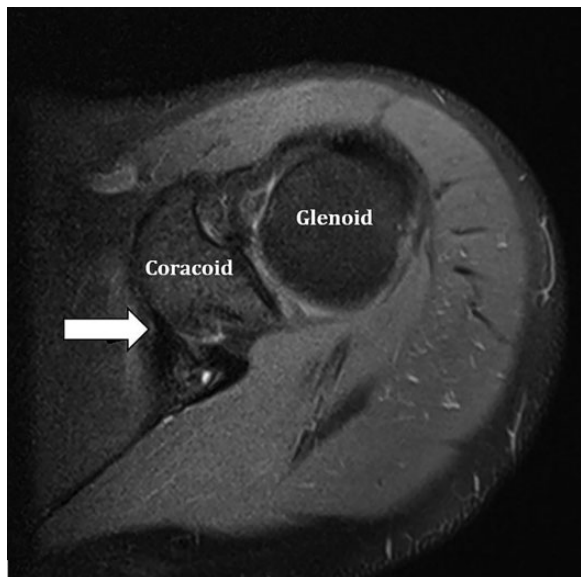


Figure 1. Identification of the coracoclavicular ligament on an axial T2 fat-saturated magnetic resonance imaging slice. The coracoclavicular ligament is the T2 hypointense structure (arrow) seen inserting on the medial margin of the coracoid base.

tip. Width measurements were obtained perpendicular to this coracoid length at 3 locations—5 mm anteriorly from the coracoid base, midpoint, and 5 mm posteriorly from the coracoid tip—to most closely approximate width across the whole transferable coracoid.

Glenoid bone loss was measured by 1 investigator (D.A.D.) utilizing sagittal oblique MRI sequences using the PICO method.²⁷ A circle of best fit was drawn over the intact margins of the glenoid rim to approximate the normal surface area. The area of the actual glenoid rim (glenoid defect not included) was divided by the area of the expected glenoid rim (a full circle with the glenoid defect) to find the percentage of remaining glenoid bone. Glenoid bone loss was then calculated by subtracting the percentage of remaining glenoid bone by 100%.

Statistical Analysis

Cases were split into short versus long coracoid (<22 vs \geq 22 mm) and narrower vs wider coracoid (<10 vs \geq 10 mm). These cutoffs were selected as the whole numbers nearest the means of coracoid length and width in this patient cohort, with several CT studies finding a mean coracoid length between 21 and 24 mm.^{14,16,19} Demographic and postoperative outcomes were compared between shorter and longer coracoids, narrower and wider coracoids, and male and female coracoid dimensions. Independent-samples *t* tests were utilized to calculate *P* values for parametric data, and Mann-Whitney tests were used to calculate *P* values for nonparametric data. Chi-square and Fisher exact tests were used to calculate *P* values for categorical data. Univariate correlations were performed to evaluate the relationships between demographics and coracoid dimensions. Relationships with correlation coefficients from 0.0 to 0.19 were considered

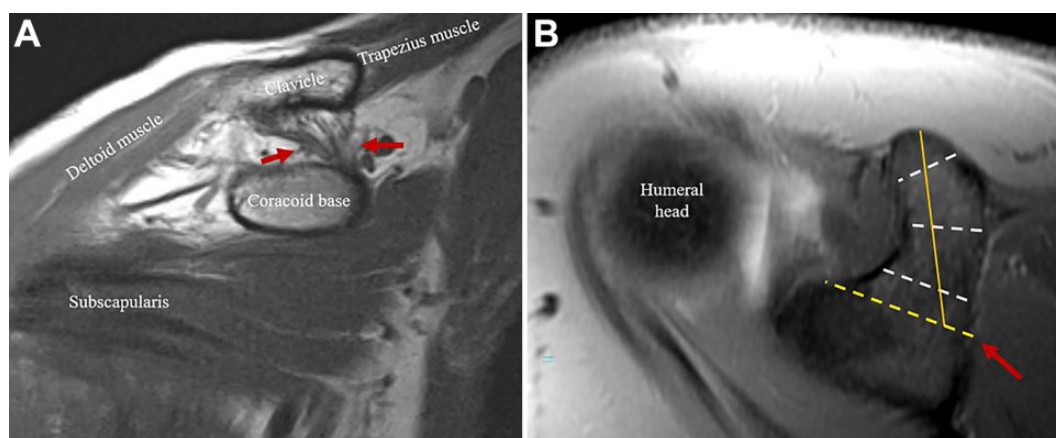


Figure 2. Demonstration of coracoid width measurements. (A) First, on the coronal oblique T1-weighted sequence, the coracoclavicular ligaments were identified (between the red arrows), outlined by fat, including the more lateral trapezoid ligament and medial conoid ligament. (B) Using scout localizers, the insertion of the coracoclavicular ligaments on the fluid-sensitive axial sequence was identified (red arrow). A line was drawn from this point to the anterior margin of the glenoid (yellow dotted line) denoting the width of the coracoid base. Coracoid width measurements were then collected at 3 locations: 5 mm anteriorly from the coracoid base, midpoint, and 5 mm posteriorly from the coracoid tip (white dotted lines). A straight line from the midpoint of the base to the tip (yellow solid line) was drawn to approximate coracoid length.

TABLE 1
Reasons Why Included Patients Underwent Latarjet Surgery^a

Reason	Patients, No. (%)
Recurrent shoulder instability after a failed Bankart repair	6 (10.7)
Recurrent shoulder instability and pain after a failed Bankart repair	6 (10.7)
Aspirations to return to a high-risk sport, with recurrent shoulder instability and significant glenoid bone loss, after a failed Bankart repair	6 (10.7)
Aspirations to return to a high-risk sport, with recurrent shoulder instability, after a failed Bankart repair	4 (7.1)
Shoulder instability, pain, and significant glenoid bone loss	4 (7.1)
Chronic shoulder instability and pain	4 (7.1)
Chronic shoulder instability and significant glenoid bone loss	3 (5.4)

^aOnly reasons that were similar among ≥ 3 patients are reported. Bone loss $\geq 15^\circ$ was considered significant.

TABLE 2
Differences in Demographics and Intraoperative Variables by Coracoid Length and Width^a

Variable	Coracoid Length		P Value	Coracoid Width		P Value
	Shorter (<22 mm; n = 30)	Longer (≥ 22 mm; n = 26)		Narrower (<10 mm; n = 29)	Wider (≥ 10 mm; n = 27)	
Age, y	27.3 \pm 10.3	29.7 \pm 9.8	.372	28.2 \pm 10.2	28.7 \pm 10.1	.856
Sex: male	24 (80.0)	23 (88.5)	.481	22 (75.9)	25 (92.6)	.146
Surgery on dominant side	15 (50.0)	11 (42.3)	.565	12 (41.4)	14 (51.9)	.432
Participation in contact sport	17 (63.0)	12 (50.0)	.516	14 (53.8)	15 (60.0)	.872
Chronic instability	28 (93.3)	26 (100)	.494	28 (96.6)	26 (96.3)	$\geq .999$
Bankart repair before Latarjet	17 (56.7)	17 (65.4)	.505	19 (65.5)	15 (55.6)	.446
Glenoid bone loss	11.8 \pm 7.7	15.8 \pm 8.5	.079	13.9 \pm 10.0	13.5 \pm 6.1	.863
Concomitant Bankart repair with Latarjet	8 (26.7)	6 (23.1)	.757	6 (20.7)	8 (29.6)	.440

^aCategorical data are presented as No. (%) and continuous data as mean \pm SD.

nonexistent, 0.20 to 0.39 weak, 0.40 to 0.59 moderate, and >0.59 strong. $P < .05$ was deemed significant. SPSS Version 27.0 (IBM Corporation) was utilized for ICC calculations, and all other statistical analyses were done using R Studio (Version 3.6.3).

Single-measures intraclass correlation coefficient (ICC) was determined to quantify interrater reliability among the 3 raters, using a 2-way mixed effects model and absolute agreement definition. We referenced scales introduced in previously published radiology literature for the interpretation of ICC values, in which <0.50 was considered weak reliability, 0.50 to 0.69 moderate, 0.70 to 0.89 good, and >0.90 excellent.¹⁹

RESULTS

A total of 56 patients who underwent a primary Latarjet procedure with available preoperative shoulder MRI were included in this study. Patients were 28.4 ± 10.1 years of age (mean \pm SD), with 9 women and 47 men. There were 34 (60.7%) patients who underwent a Bankart repair before their Latarjet surgery (Table 1).

Interrater reliability was good for measuring coracoid length (ICC, 0.79; 95% CI, 0.69-0.87) and coracoid width

(ICC, 0.76; 95% CI, 0.46-0.88). Also, no coracoid abnormalities were observed within this patient cohort.

There were no statistically significant demographic differences between groups for coracoid length (<22 vs ≥ 22 mm) and coracoid width (<10 vs ≥ 10 mm) (Table 2). Coracoid length averaged 21.6 ± 2.4 mm (range, 16.7-26.9 mm), coracoid width 10.0 ± 1.0 mm (range, 8.3-13.2 mm), and glenoid bone loss $13.7\% \pm 8.2\%$ (range, 0.0%-32.4%). There was no relationship between coracoid length and coracoid width ($R = 0.16$) (Figure 3). Coracoid length was weakly correlated with height ($R = 0.32$) and not correlated with weight ($R = 0.11$) or age ($R = -0.06$). Coracoid width was moderately correlated with height ($R = 0.42$), weakly correlated with weight ($R = 0.29$), and not correlated with age ($R = -0.01$).

All patients who underwent a Latarjet procedure with minimal glenoid bone loss had a preoperative history of chronic shoulder instability, and all these patients either failed an initial Bankart repair or were currently participating in a high-risk sport. There were 41 patients (73.2%) with harvestable coracoid length ≥ 20 mm. An overall 55 patients received 2 coracoid screws for fixation, and just 1 patient was limited to 1 screw. This patient had a coracoid length of 22.3 mm and a coracoid width of 11.7 mm.

Postoperative complications arose in 7 (12.5%) patients, with no statistically significant difference in complication rate based on coracoid length or width (all $P > .05$) (Table 3). Three patients required reoperation: (1) an 18-year-old nonathlete man (coracoid length, 20.1 mm; coracoid width, 10.7 mm) had an anterior humeral head subluxation that required Latarjet revision with iliac crest bone grafting and capsulorrhaphy 2.5 years after the primary Latarjet procedure; (2) a 24-year-old man (coracoid length, 23.5 mm; coracoid width, 9.6 mm) developed recurrent instability requiring hardware removal and open capsulorrhaphy

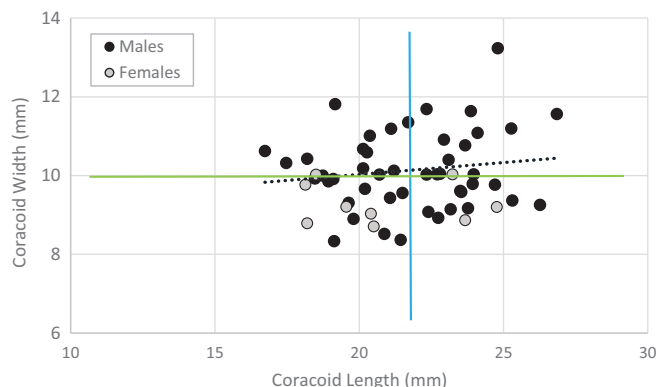


Figure 3. Scatterplot showing the coracoid dimensions of the 56 patients who underwent a Latarjet procedure. No relationship was observed between coracoid length and width ($R = 0.16$). Green line, coracoid width group cutoff (10 mm); blue line, coracoid length group cutoff (22 mm); black dotted line, trendline.

0.6 years postoperatively; and (3) a 21-year-old man (coracoid length, 24.8 mm; coracoid width, 13.2 mm) crashed into a wall while skateboarding and experienced a graft fracture requiring hardware removal with irrigation and debridement 1.6 years postoperatively. This was the only patient to experience a graft fracture. Last, 4 complications that did not require a reoperation involved persistent pain and shoulder locking, temporary nerve injury, surgical site infection, and persistent moderate to severe pain with numbness and tingling.

Long-term ASES and RTS outcomes were obtained for 36 (64.3%) patients at a mean follow-up of 4.8 years (range, 2.2-8.1 years). There were no differences in ASES score, RTS rate, or RTS time between groups by coracoid length and width (all $P > .05$) (Table 4).

Men and women did not differ in regard to mean coracoid length (21.8 ± 2.4 mm vs 20.8 ± 2.5 mm; $P = .288$) or glenoid bone loss ($13.6\% \pm 7.5\%$ vs $14.5\% \pm 11.9\%$; $P = .822$). However, men did have a wider coracoid than women (10.1 ± 1.0 mm vs 9.3 ± 0.5 mm; $P = .001$) (Figure 4). Despite this, women had similar postoperative outcomes to men (Table 5).

DISCUSSION

The study findings indicated that there were no significant differences in recurrent instability and reoperation rates, postoperative ASES scores, complications, or RTS between patients with smaller and larger coracoid length or width. Also, no strong relationships were observed between patient demographics (age, height, weight) and coracoid dimensions. Men and women had similar mean coracoid lengths and glenoid bone loss, but men had a wider mean

TABLE 3
Postoperative Complications, Recurrent Instability, and Reoperation by Coracoid Length and Width^a

Variable	Coracoid Length		P Value	Coracoid Width		P Value
	Shorter (<22 mm; n = 30)	Longer (≥22 mm; n = 26)		Narrower (<10 mm; n = 29)	Wider (≥10 mm; n = 27)	
All complications	3 (10.0)	4 (15.4)	.543	5 (17.2)	2 (7.4)	.266
Recurrent instability	2 (6.7)	1 (3.8)	.640	2 (6.9)	1 (3.7)	.596
Reoperation	1 (3.3)	2 (7.7)	.592	1 (3.5)	2 (7.4)	.605

^aData are presented as No. (%).

TABLE 4
Postoperative ASES scores, RTS Rates, and RTS Time by Coracoid Length and Width^a

Variable	Coracoid Length		P Value	Coracoid Width		P Value
	Shorter (<22 mm; n = 18)	Longer (≥22 mm; n = 18)		Narrower (<10 mm; n = 16)	Wider (≥10 mm; n = 20)	
ASES score	85.0 ± 18.0	81.6 ± 21.5	.612	87.1 ± 17.0	80.0 ± 21.5	.286
RTS	13 (76.5)	10 (58.8)	.298	10 (66.7)	13 (68.4)	≥.999
Time until RTS, mo	6.9 ± 4.1	6.1 ± 3.9	.626	7.1 ± 4.2	6.1 ± 3.9	.562

^aCategorical data are presented as No. (%) and continuous data as mean ± SD. ASES, American Shoulder and Elbow Surgeons; RTS, return to sport.

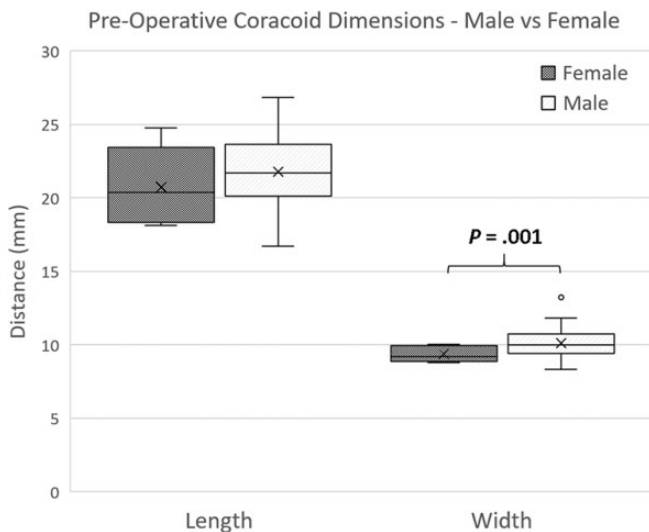


Figure 4. Difference between female and male patients in mean preoperative coracoid length and width as measured on magnetic resonance imaging. ×, mean; line, median; box, interquartile range; error bars, 95% CI; circle, outlier.

TABLE 5
Postoperative Variables Between Female and Male Patients^a

Variable	Female (n = 9)	Male (n = 47)	P Value
All complications	1 (11.1)	1 (2.1)	.183
Recurrent instability	1 (11.1)	7 (14.9)	.766
Reoperation	0 (0.0)	3 (6.4)	≥.999
RTS	3 (60.0)	20 (69.0)	.692
Time until RTS, mo	6.7 ± 6.4	6.5 ± 3.7	.964
ASES score	70.8 ± 24.6	84.8 ± 18.8	.342

^aCategorical data are presented as No. (%) and continuous data as mean ± SD. ASES, American Shoulder and Elbow Surgeons; RTS, return to sport.

coracoid width. Despite differing mean coracoid widths, men and women had statistically similar postoperative outcomes, but a small cohort of female patients (n = 9) limited the power of this analysis.

Two studies recently described reliable methods of evaluating preoperative coracoid dimensions, although these techniques utilized CT instead of MRI.^{14,19} Jia et al¹⁴ performed 3-dimensional reconstruction of 84 shoulder CT scans, but these coracoid length measurements did not account for the clinically relevant anatomy of the coracoclavicular (CC) ligament. Lamplot et al¹⁹ also evaluated multipanar reconstructed CT scans to evaluate preoperative coracoid dimensions and devised a protocol more specific to the typical osteotomy utilized during the Latarjet procedure.²¹ Specifically, the axial view was utilized to identify the anterior aspect of the coracoid base (located at the junction of the vertical inferior pillar and the horizontal superior pillar) and measure its distance from the tip of the

coracoid. While this method more closely accounts for the specific landmarks utilized during the Latarjet osteotomy, it still does not represent the intraoperative identification of the CC ligament insertion.

Clinicians frequently use MRI while treating shoulder instability owing to its easy visualization and diagnosis of labral tears.^{25,26} Meanwhile, the radiation exposure from a shoulder CT scan has a lifetime attributable risk of cancer around 0.7 per 1000 patients.¹³ Thus, the MRI protocol utilized in this study can improve patient safety and decrease health care costs by limiting the necessity of additional CT imaging.^{2,13} Surgeons who wish to evaluate coracoid dimensions preoperatively can use this MRI protocol with good interrater reliability to evaluate coracoid length and width during standard-of-care MRI evaluation.

It has been suggested that a coracoid bone graft length of 25 mm or more best enables the safe insertion of two 4.5-mm screws.²⁸ However, with this MRI protocol, the current study found that all but 1 patient received 2 screws despite most having a coracoid length <25 mm, with none experiencing an acute graft fracture and just 2 receiving a hardware removal procedure. This suggests that the 25-mm cutoff may not be as important as previously noted for a successful Latarjet procedure.⁴ For example, Boutsiadis et al⁴ found that 96% of patients with 25% glenoid bone loss had adequate coracoid dimensions to restore glenoid anatomy, while 76% with 30% glenoid bone loss had adequate coracoid dimensions. Yet, the Latarjet procedure provides stabilization through other mechanisms as well, such as the sling effect of the conjoint tendon and subscapularis and reinforcement by capsular duplication with the released coracoacromial ligament.^{5,8} Thus, measuring coracoid dimensions alone does not evaluate all the relevant stabilization mechanisms, and these other mechanisms may become more important in the setting of significant bone loss. Additionally, the Bristow procedure of coracoid fixation uses a smaller bone block than the Latarjet procedure and a single screw for fixation. While the Bristow procedure has been a successful shoulder stabilization procedure for patients without significant glenoid bone loss, a cadaveric study found that the Bristow procedure may lead to inferior stabilization in patients with significant glenoid bone loss, relative to the Latarjet procedure.¹⁰ Though further research is needed to clarify the bone graft dimensions needed to treat various amounts of glenoid bone loss, surgeons who are treating patients with significant glenoid bone loss may utilize this MRI protocol if they are concerned about the anatomy of the coracoid preoperatively.

Several meta-analyses have evaluated postoperative outcomes for Latarjet surgery.^{1,9,11,12} Recurrent dislocations were observed in 1.6% to 5.1% of patients across 4 meta-analyses.^{1,9,11,12} Meanwhile, recurrent instability (including dislocations and subluxations) occurs in 2.0% to 12.1% of patients and revision in 2.4% to 5.4%.^{1,11} The postoperative complication rate was 5% for complications that required reoperation¹ and 4% for all complications that were not instability related.⁹ Finally, 73% (258 of 353) of patients were able to return to sport (RTS) at a mean 5.3 months.¹² Most of these data are in line with the findings of the current study, with the main difference being a lower

RTS rate of 63.9%. This may be due to several factors. First, the current study included patients into the RTS analysis who were participating in sport before surgery and responded to long-term RedCap follow-up. Also, a meta-analysis revealed a minimum 15% (575 of 3917) of patients have a previous stabilization procedure,⁹ but the majority of patients in this study had a prior shoulder stabilization procedure, which may have contributed to lower RTS rates.

Limitations

This study has several limitations. First, the sample size of this retrospective cohort study was small and may lower the strength of the conclusions drawn. There were just 3 patients with recurrent instability in our cohort, which may have lessened the ability to detect any effect of coracoid size on outcome. The lack of patients with recurrent instability limits the validity of post hoc power analysis findings; thus, a post hoc power analysis was not performed. Also, only 9 female patients were included, restricting the statistical power of the male versus female analysis. For example, previous research with a larger sample size of female patients (n = 29) found that women have shorter coracoid lengths than men¹⁴; as such, larger studies comparing male versus female patients are necessary before clinical recommendations can be made. Plus, while the standard Latarjet procedure was utilized for all patients, details regarding graft orientation and indications for concomitant Bankart repair could not be standardized owing to the retrospective design of this study and the various surgeons who performed Latarjet surgery throughout our institution. Finally, intraoperative bone grafts were not measured, so their exact sizes were not determined. However, the general recommendation is to take a sufficient-length bone block that does not disrupt the integrity of the CC ligaments, which we adhered to in our measurement protocol.

CONCLUSION

Patients undergoing Latarjet coracoid transfer had similar postoperative outcomes regardless of preoperative coracoid dimensions. This MRI protocol for measuring coracoid dimensions has good interrater reliability and closely accounts for the specific landmarks utilized during the Latarjet osteotomy by focusing on identification of the CC ligament insertion. These findings should be confirmed in a larger cohort before further clinical recommendations are made.

REFERENCES

1. An VVG, Sivakumar BS, Phan K, Trantalis J. Asystematic review and meta-analysis of clinical and patient-reported outcomes following two procedures for recurrent traumatic anterior instability of the shoulder: Latarjet procedure vs Bankart repair. *J Shoulder Elbow Surg.* 2016; 25(5):853-863. doi:10.1016/j.jse.2015.11.001
2. Biswas D, Bible JE, Bohan M, Simpson AK, Whang PG, Grauer JN. Radiation exposure from musculoskeletal computerized tomographic scans. *J Bone Joint Surg Am.* 2009;91(8):1882-1889. doi:10.2106/JBJS.H.01199
3. Boone JL, Arciero RA. First-time anterior shoulder dislocations: has the standard changed? *Br J Sports Med.* 2010;44(5):355-360. doi:10.1136/bjism.2009.062596
4. Boutsiadis A, Bampis I, Swan J, Barth J. Best implant choice for coracoid graft fixation during the Latarjet procedure depends on patients' morphometric considerations. *J Exp Orthop.* 2020;7(1):15. doi:10.1186/s40634-020-00230-0
5. Bradley Edwards T, Walch G. The Latarjet procedure for recurrent anterior shoulder instability: rationale and technique. *Oper Tech Sports Med.* 2002;10(1):25-32. doi:10.1053/otsm.2002.28776
6. Bradley KE, Jansson HL, Lansdown DA, Zhang AL. Arthroscopic glenoid reconstruction with iliac crest bone block transfer in the beach chair position. *Arthrosc Tech.* 2021;10(4):e1155-e1164. doi:10.1016/j.eats.2021.01.010
7. Burkhart SS, De Beer JF. Traumatic glenohumeral bone defects and their relationship to failure of arthroscopic Bankart repairs: significance of the inverted-pear glenoid and the humeral engaging Hill-Sachs lesion. *Arthroscopy.* 2000;16(7):677-694. doi:10.1053/jars.2000.17715
8. Domos P, Lunini E, Walch G. Contraindications and complications of the Latarjet procedure. *Shoulder Elbow.* 2018;10(1):15-24. doi:10.1177/1758573217728716
9. Gilat R, Haunschild ED, Lavoie-Gagne OZ, et al. Outcomes of the Latarjet procedure versus free bone block procedures for anterior shoulder instability: a systematic review and meta-analysis. *Am J Sports Med.* 2021;49(3):805-816. doi:10.1177/0363546520925833
10. Giles JW, Degen RM, Johnson JA, Athwal GS. The Bristow and Latarjet procedures: why these techniques should not be considered synonymous. *J Bone Joint Surg Am.* 2014;96(16):1340-1348. doi:10.2106/JBJS.M.00627
11. Hurley ET, Lim Fat D, Farrington SK, Mullett H. Open versus arthroscopic Latarjet procedure for anterior shoulder instability: a systematic review and meta-analysis. *Am J Sports Med.* 2019;47(5):1248-1253. doi:10.1177/0363546518759540
12. Ialenti MN, Mulvihill JD, Feinstein M, Zhang AL, Feeley BT. Return to play following shoulder stabilization: a systematic review and meta-analysis. *Orthop J Sports Med.* 2017;5(9):2325967117726055. doi:10.1177/2325967117726055
13. Iordache SD, Goldberg N, Paz L, Peylan J, Hur RB, Steinmetz A. Radiation exposure from computed tomography of the upper limbs. *Acta Orthop Belg.* 2017;83(4):581-588.
14. Jia Y, He N, Liu J, et al. Morphometric analysis of the coracoid process and glenoid width: a 3D-CT study. *J Orthop Surg.* 2020;15:69. doi:10.1186/s13018-020-01600-1
15. John R, Coady CM, Wong I. Arthroscopic revision with autologous iliac crest bone graft for failed anatomic glenoid reconstruction using distal tibia allograft. *Arthrosc Tech.* 2019;8(11):e1333-e1338. doi:10.1016/j.eats.2019.07.009
16. Joshi D, Gupta LM, Tanwar M, Lal A, Chaudhary D. Anthropometric and radiologic measurements of coracoid dimensions and clinical implications in an Indian population. *Orthop J Sports Med.* 2018; 6(3):2325967118761635. doi:10.1177/2325967118761635
17. Kirkley A, Werstine R, Ratjek A, Griffin S. Prospective randomized clinical trial comparing the effectiveness of immediate arthroscopic stabilization versus immobilization and rehabilitation in first traumatic anterior dislocations of the shoulder: long-term evaluation. *Arthroscopy.* 2005;21(1):55-63. doi:10.1016/j.arthro.2004.09.018
18. Kraeutler MJ, McCarty EC, Belk JW, et al. Descriptive epidemiology of the MOON shoulder instability cohort. *Am J Sports Med.* 2018; 46(5):1064-1069. doi:10.1177/0363546518755752
19. Lamplot JD, Brusalis CM, Apostolakis JM, et al. Computed tomography-based preoperative planning provides a pathology and morphology-specific approach to glenohumeral instability with bone loss. *Arthroscopy.* 2021;37(6):1757-1766.e2. doi:10.1016/j.arthro.2021.01.021
20. Leroux T, Wasserstein D, Veillette C, et al. Epidemiology of primary anterior shoulder dislocation requiring closed reduction in Ontario, Canada. *Am J Sports Med.* 2014;42(2):442-450. doi:10.1177/0363546513510391

21. Lo IKY, Burkhart SS, Parten PM. Surgery about the coracoid: neurovascular structures at risk. *Arthroscopy*. 2004;20(6):591-595. doi:10.1016/j.arthro.2004.04.060
22. Minkus M, Königshausen M, Maier D, et al. Immobilization in external rotation and abduction versus arthroscopic stabilization after first-time anterior shoulder dislocation: a multicenter randomized controlled trial. *Am J Sports Med*. 2021;49(4):857-865. doi:10.1177/0363546520987823
23. Moroder P, Schulz E, Wierer G, et al. Latarjet procedure vs iliac crest bone graft transfer for treatment of anterior shoulder instability with glenoid bone loss: a prospective randomized trial. *J Shoulder Elbow Surg*. 2019;28(7):1298-1307. doi:10.1016/j.jse.2019.03.035
24. Olds M, Ellis R, Donaldson K, Parmar P, Kersten P. Risk factors which predispose first-time traumatic anterior shoulder dislocations to recurrent instability in adults: a systematic review and meta-analysis. *Br J Sports Med*. 2015;49(14):913-922. doi:10.1136/bjsports-2014-094342
25. Ruiz Santiago F, Martínez Martínez A, Tomás Muñoz P, Pozo Sánchez J, Zarza Pérez A. Imaging of shoulder instability. *Quant Imaging Med Surg*. 2017;7(4):422-433. doi:10.21037/qims.2017.08.05
26. Smith TO, Drew BT, Toms AP. A meta-analysis of the diagnostic test accuracy of MRA and MRI for the detection of glenoid labral injury. *Arch Orthop Trauma Surg*. 2012;132(7):905-919. doi:10.1007/s00402-012-1493-8
27. Walter WR, Samim M, LaPolla FWZ, Gyftopoulos S. Imaging quantification of glenoid bone loss in patients with glenohumeral instability: a systematic review. *AJR Am J Roentgenol*. 2019;212(5):1096-1105. doi:10.2214/AJR.18.20504
28. Young AA, Baba M, Neyton L, Godeneche A, Walch G. Coracoid graft dimensions after harvesting for the open Latarjet procedure. *J Shoulder Elbow Surg*. 2013;22(4):485-488. doi:10.1016/j.jse.2012.05.036
29. Zacchilli MA, Owens BD. Epidemiology of shoulder dislocations presenting to emergency departments in the United States. *J Bone Joint Surg Am*. 2010;92(3):542-549. doi:10.2106/JBJS.I.00450