

3-25-2016

A 22-year-old man with pleural tuberculosis associated hydropneumothorax: Case report and literature review.

Lauren A Sharan

Sidney Kimmel Medical College, Thomas Jefferson University

Thea Price, MD

Department of Surgery, Thomas Jefferson University

Boyd Hehn

Department of Medicine, Division of Pulmonary and Critical Care Medicine, Thomas Jefferson University

David Manoff, MD

Department of Medicine, Division of Pulmonary and Critical Care Medicine, Thomas Jefferson University

Scott W. Cowan, MD

Department of Surgery, Division of Thoracic Surgery, Thomas Jefferson University

Follow this and additional works at: <https://jdc.jefferson.edu/medfp>

 Part of the [Pulmonology Commons](#)

[Let us know how access to this document benefits you](#)

Recommended Citation

Sharan, Lauren A; Price, MD, Thea; Hehn, Boyd; Manoff, MD, David; and Cowan, MD, Scott W., "A 22-year-old man with pleural tuberculosis associated hydropneumothorax: Case report and literature review." (2016). *Department of Medicine Faculty Papers*. Paper 157.
<https://jdc.jefferson.edu/medfp/157>

This Article is brought to you for free and open access by the Jefferson Digital Commons. The Jefferson Digital Commons is a service of Thomas Jefferson University's [Center for Teaching and Learning \(CTL\)](#). The Commons is a showcase for Jefferson books and journals, peer-reviewed scholarly publications, unique historical collections from the University archives, and teaching tools. The Jefferson Digital Commons allows researchers and interested readers anywhere in the world to learn about and keep up to date with Jefferson scholarship. This article has been accepted for inclusion in Department of Medicine Faculty Papers by an authorized administrator of the Jefferson Digital Commons. For more information, please contact: JeffersonDigitalCommons@jefferson.edu.



Case report

A 22-year-old man with pleural tuberculosis associated hydropneumothorax: Case report and literature review

Lauren A. Sharan ^a, Thea P. Price ^b, Boyd Hehn ^c, David Manoff ^c, Scott W. Cowan ^{d,*}^a Sidney Kimmel Medical College, Thomas Jefferson University, Philadelphia, PA, USA^b Department of Surgery, Thomas Jefferson University, Philadelphia, PA, USA^c Department of Medicine, Division of Pulmonary and Critical Care Medicine, Thomas Jefferson University, Philadelphia, PA, USA^d Department of Surgery, Division of Thoracic Surgery, Thomas Jefferson University, Philadelphia, PA, USA

ARTICLE INFO

Article history:

Received 21 October 2015

Received in revised form

23 March 2016

Accepted 23 March 2016

Keywords:

Tuberculosis

Pleural effusion

Pleural tuberculosis

Fibrinolytic therapy

ABSTRACT

A 22-year-old Asian male presented with fever, non-productive cough, right-sided pleuritic chest pain and was found to have a large right hydropneumothorax. A chest tube was placed. Pleural fluid analysis revealed a lymphocytic predominant exudate and he was subsequently started on four-drug daily anti-tuberculosis therapy (isoniazid, ethambutol, rifampin, pyrazinamide). Pleural biopsy revealed acid-fast bacilli. Given his persistent pleural effusion, he was given four doses of intrapleural tissue plasminogen activator (tPA) and dornase alpha (DNase) via his chest tube over a period of 6 days resulting in clinical and radiologic improvement. Pleural biopsy and pleural fluid culture specimens later revealed *Mycobacterium tuberculosis*. Intrapleural tPA-DNase therapy has demonstrated improved resolution of infections and shortened hospitalizations for parapneumonic infectious effusions. However, there is little literature on the use of intrapleural fibrinolytics specifically for pleural tuberculosis associated effusions. Furthermore, the American Thoracic Society does not comment on therapeutic thoracentesis or intrapleural fibrinolytic therapy in their recommendations for treatment of pleural tuberculosis. In our case of pleural TB-associated hydropneumothorax, the use of intrapleural tPA-DNase therapy facilitated pleural fluid drainage and resulted in near-complete resolution of the effusion.

© 2016 Published by Elsevier Ltd. This is an open access article under the CC BY-NC-ND license (<http://creativecommons.org/licenses/by-nc-nd/4.0/>).

1. Introduction

Pleural tuberculosis (TB) is rare. The most recent epidemiologic study in 2003 reported 14,874 US TB cases of which 20.4% were exclusively extra-pulmonary. Of these patients, 18.5% reported pleura as the major site of disease. From 1993 to 2003, pleural TB comprised only 3.9% of all US TB cases [1]. Globally there is significant geographical variation, for example the incidence in Spain is nearly six times that of the US [2].

Little published data exists about the management of pleural TB associated effusions. We report a case of an Asian male with a large hydropneumothorax found to have acid-fast bacilli (AFB) on pleural

biopsy and ultimately *Mycobacterium tuberculosis* in pleural biopsy and fluid cultures.

2. Case report

A 22 year-old Asian male smoker presented with ten days of non-productive cough, subjective fevers, night sweats, right-sided pleuritic chest pain and increasing dyspnea. One week prior to presentation, he was empirically treated for pneumonia with levofloxacin without improvement. The patient was an exchange student from China whose last visit home was two months prior to presentation to our facility. Both of the patient's parents had been diagnosed with TB before his birth with unclear treatment status.

The patient's physical exam was remarkable for decreased right-sided breath sounds. Vital signs were: temperature, 98.4 °F; heart rate, 102/min, regular; BP, 102/58 mm Hg; respiratory rate, 28/min; oxygen saturation, 95% on room air.

Chest radiograph (CXR) showed a large right hydropneumothorax and right upper lobe infiltrate with scarring (Fig. 1).

Abbreviations: TB, tuberculosis; CT, chest tube; AFB, acid fast bacilli; HD, hospital day; CXR, chest radiograph; ADA, adenosine deaminase; INH, isoniazid; EMB, ethambutol; RIF, rifampin; PZA, pyrazinamide.

* Corresponding author. Thoracic Surgery, Thomas Jefferson University Hospital, 1025 Walnut Street, Suite 607, Philadelphia, PA 19107, USA.

E-mail address: Scott.Cowan@jefferson.edu (S.W. Cowan).

<http://dx.doi.org/10.1016/j.rmcr.2016.03.010>

2213-0071/© 2016 Published by Elsevier Ltd. This is an open access article under the CC BY-NC-ND license (<http://creativecommons.org/licenses/by-nc-nd/4.0/>).

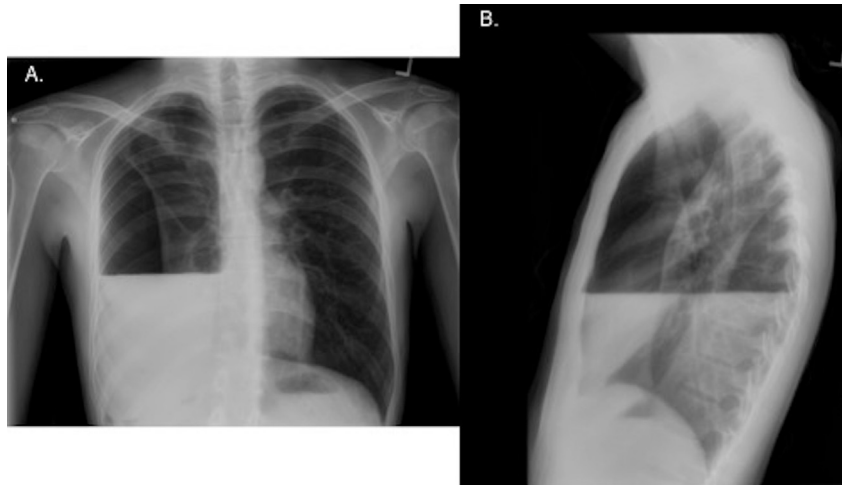


Fig. 1. Initial chest radiographs of patient upon presentation. A, Posteroanterior view showing large right hydropneumothorax. B, Lateral view showing hydropneumothorax.

A right-sided 32 French chest tube (CT) was placed in the emergency department (Fig. 2A). A chest computed tomography scan showed tree-in-bud nodularity in the right upper lobe, possible consolidation in the right lower lobe and calcified hilar lymphadenopathy. Additionally, there were foci of gas in the right-sided hydropneumothorax which could have represented a loculated component. Due to imaging findings suggesting prior granulomatous infection and patient history, there was high suspicion for TB and on airborne precautions were instituted.

A pleural drainage catheter was placed into the hydropneumothorax. Analysis of the pleural fluid obtained from this procedure revealed: pH, 7.70; glucose, 11 mg/dL; protein, 4.5 g/L; LDH, 1458 units/L; WBC, 1340 cells/ μ L (64% lymphocytes); RBC, 4000 cells/ μ L; adenosine deaminase (ADA), 57.5 units/L. Additionally, serum protein was 5.6 g/L.

Throughout his hospitalization, the patient had multiple AFB smears and cultures performed (2 concentrated sputum, 2 pleural fluid, 1 bronchoalveolar lavage), which were negative. A pleural biopsy demonstrated 1+ AFB on smear and necrotizing granulomatous inflammation. The patient was started on an anti-tuberculosis regimen (isoniazid (INH) 300 mg, ethambutol (EMB) 800 mg, rifampin (RIF) 450 mg and pyrazinamide (PZA) 1000 mg) because of his findings of a lymphocyte predominant exudative pleural effusion, AFB positive pleural biopsy with necrotizing granulomatous inflammation and history of exposure to TB.

Given the persistent pleural effusion, he was given four doses of tissue plasminogen activator (tPA) and dornase alfa (DNase) instilled via the chest tube over a period of 6 days resulting in

improved drainage and clinical and radiologic improvement (Table 1, Fig. 2B). Fibrinolytic therapy was terminated at the point of near complete resolution of the pleural effusion as evidenced by CXR. The chest tube was removed and the patient was discharged on hospital day 13. Two weeks after discharge, a follow-up CXR demonstrated a persistent small right-sided effusion, however; the patient was asymptomatic (Fig. 3). Ultimately, the pleural fluid and biopsy cultures were positive for *Mycobacterium tuberculosis*.

3. Discussion

Tuberculous pleuritis should be considered in patients with a lymphocyte-predominant exudative effusion. The etiology of an effusion can be difficult to classify and often requires both pleural fluid analysis and clinical correlation [3]. Our patient had a pleural fluid protein/serum protein ratio of 0.80 and elevated pleural fluid LDH indicating an exudate. Low pleural fluid glucose (40 mg/dL) narrowed our differential to rheumatoid pleurisy, empyema, malignancy, lupus pleuritis or tuberculous pleurisy [4]. In this patient, serum protein >4 g/dL made tuberculous pleural effusion more likely [5]. Our patient's pleural fluid did not show the typical pH of <7.30 as seen in most tuberculous effusions [6]. In one meta-analysis, the average pH for tuberculous effusions was 7.18 [7]. The pleural fluid ADA value was found to be elevated at 57.5 U/L. The ADA assay has a sensitivity of 92% and a specificity of 90 for diagnosing TB pleurisy [8].

The best diagnostic approach to suspected tuberculous pleuritis is debated. The yield of pleural fluid smears is 10% and of pleural

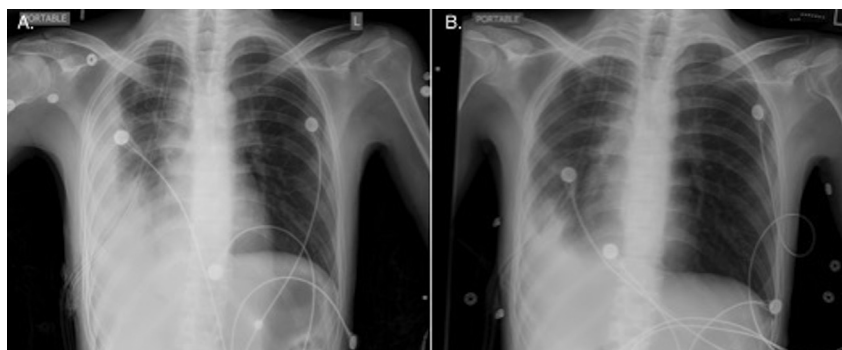


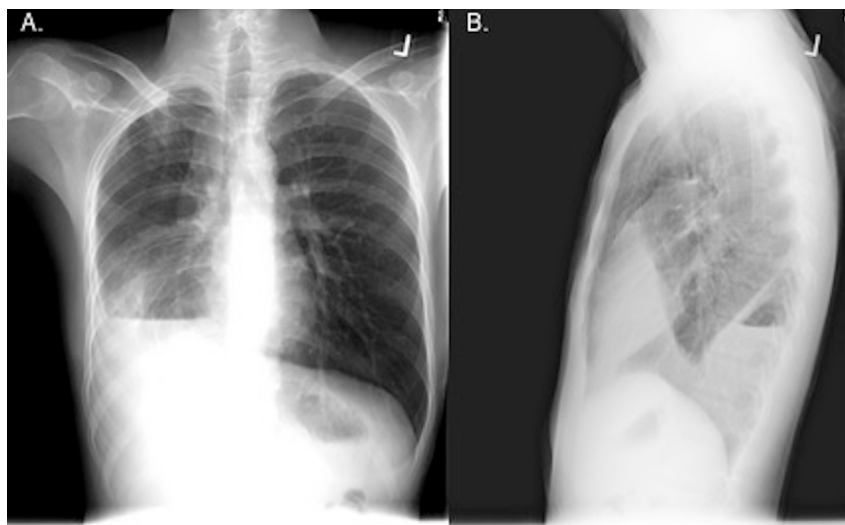
Fig. 2. Chest radiographs showing resolution of the hydropneumothorax. A, Following chest tube placement. B, Day 4 after chest tube placement.

Table 1

Dosages of intrapleural fibrinolytic therapy and resultant chest tube outputs.

Dose number	1 (HD#3)	2 (HD#4)	3 (HD#6) + DNase	4 (HD#9) + DNase
Dose	10 mg tPA in 30 ml 0.9% NaCl	10 mg tPA in 30 ml 0.9% NaCl	10 mg tPA in 30 ml 0.9% NaCl + 5 mg DNase in 30 ml sterile water	10 mg tPA in 30 ml 0.9% NaCl + 5 mg DNase in 30 ml sterile water
Chest tube output	170 mL	1100 mL	1600 mL	815 mL

Legend: HD = hospital day.

**Fig. 3.** Chest radiographs at patient's two-week follow-up visit. A, Posteroanterior view. B, Lateral view.

fluid cultures is 25–85% [1]. Pleural biopsy histopathology of granulomas or (+) culture has diagnostic yields ranging from 55 to 93% [1,9]. Evaluation for TB with thoracentesis plus closed pleural biopsy has a 95% sensitivity, which is roughly on par with

thoracoscopy [10]. Diagnostic modalities with highest yield are slow to show results making acute workup difficult.

The American Thoracic Society recommends a 6-month regimen for treatment of pleural TB consisting of a 2-month period of INH,

Table 2

Studies utilizing intrapleural infusions in treatment of tuberculous pleural effusions.

Author – year	Study design	Patients, N	Therapy	Endpoints	Conclusion
Cases Viedma et al. [22] 2006	Randomized, prospective	29	Group 1: intrapleural urokinase (125,000 UI) via intrathoracic tube repeated every 12 hours until quantity of pleural fluid <50 cm ³ (n = 12); Group 2: simple drainage with suction (n = 17)	Residual pleural thickening, amount of pleural fluid drained	Urokinase lessens residual pleural thickening, increases fluid drainage
Chung et al. [15] 2008	Double blind, randomized, placebo-controlled	64	Group 1: free-flowing effusions irrigated with 50 mL saline (n = 20); Group 2: loculated effusions irrigated with 250,000 IU streptokinase (n = 22); Group 3: loculated effusions irrigated with saline (n = 22) Therapy performed for 3 consecutive days for all groups	Followed for 12 months: clinical symptoms, radiologic effusion, lung function, residual pleural thickening, effusion volume removed	Streptokinase improves resolution of effusion, lessens residual pleural thickening, accelerates recovery of pulmonary function in loculated effusions
Park et al. [20] 1996	Case series	31 TB (n = 21)	When drainage <100 ml/day, 250,000 IU urokinase in 250 ml 0.9% NaCl divided into 80 ml aliquots and performed until drainage <50 ml/day	Radiographic appearance, fluid drainage	Urokinase not effective in effusions with honeycomb appearance or when parietal pleura >5 mm thickness
Kwak et al. [21] 2004	Randomized, prospective	43	Group 1: control group, anti-tuberculous agents alone (n = 22); Group 2: 100,000 IU urokinase dissolved in 150 ml of normal saline daily via a pig-tail catheter until drainage <50 ml/day (n = 21)	Residual pleural thickening	Urokinase reduces residual pleural thickening

RIF, PZA and EMB followed by INH and RIF daily for 4 months [11]. Corticosteroids have not reduced residual pleural thickening and are not recommended [11,12]. Therapeutic thoracentesis is not discussed in the guidelines and is controversial, however it is usually performed if a patient is more than mildly symptomatic [13]. Significantly less residual pleural thickening and accelerated recovery of pulmonary function has been seen in patients who received therapeutic thoracentesis for TB associated effusions [14,15]. However, other studies have concluded that residual pleural thickening is not influenced by this intervention [16]. Other drawbacks to thoracentesis include risk of transmission to health providers, bleeding, and pulmonary injury. In our patient's clinical situation a chest tube was placed on presentation for symptomatic relief.

Treatment of parapneumonic infectious effusions is comprised of antibiotic therapy and early pleural drainage [17]. A small percentage of these patients require additional therapy. The MIST-1 (Multi-Center Intrapleural Sepsis Trial) did not demonstrate any improvement in patient mortality, rate of surgery, or the length of the hospital stay with use of intrapleural tPA therapy alone [18]. However, the use of intrapleural tPA-DNase therapy in the MIST-2 trial resulted in improved resolution of infection, shortened hospitalization, and resolved effusion in 95% of patients without the need for surgery [19]. Unfortunately, none of the patients in the MIST-1 and MIST-2 trials had isolates of TB recovered making applicability to our case difficult.

A literature review on use of intrapleural tPA-DNase therapy in tuberculous pleural effusions has shown that this therapy improves fluid drainage and lessens residual pleural thickening (Table 2) [15,20–22]. However, there is little literature on the use of intrapleural fibrinolytics specifically for pleural TB associated effusions. In our case of pleural TB-associated hydropneumothorax, the use of intrapleural tPA-DNase therapy facilitated pleural fluid drainage and resulted in near-complete resolution of the effusion. Further studies examining the impact of intrapleural lytic therapy on cost, length of stay and patient outcomes in tuberculous effusions are necessary.

Disclosure

The following authors have no financial or nonfinancial

disclosures: Lauren A. Sharan, Thea P. Price, Boyd Hehn, David Manoff, Scott W. Cowan.

References

- [1] M.H. Baumann, et al., Pleural tuberculosis in the United States: incidence and drug resistance, *Chest* 131 (4) (2007) 1125–1132.
- [2] A. Gopi, et al., Diagnosis and treatment of tuberculous pleural effusion in 2006, *Chest* 131 (3) (2007) 880–889.
- [3] R.W. Light, Pleural effusions, *Med. Clin. North Am.* 95 (6) (2011) 1055–1070.
- [4] S.A. Sahn, J.T. Good Jr., In defense of low glucose level in pleural fluid, *Chest* 77 (2) (1980) 242.
- [5] R.W. Light, et al., Pleural effusions: the diagnostic separation of transudates and exudates, *Ann. Intern. Med.* 77 (4) (1972) 507–513.
- [6] J.T. Good Jr., et al., The diagnostic value of pleural fluid pH, *Chest* 78 (1) (1980) 55–59.
- [7] M.C. Houston, Pleural fluid pH: diagnostic, therapeutic, and prognostic value, *Am. J. Surg.* 154 (3) (1987) 333–337.
- [8] Q.L. Liang, et al., Diagnostic accuracy of adenosine deaminase in tuberculous pleurisy: a meta-analysis, *Respir. Med.* 102 (5) (2008) 744–754.
- [9] M. Sakuraba, et al., Thoracoscopic pleural biopsy for tuberculous pleurisy under local anesthesia, *Ann. Thorac. Cardiovasc. Surg.* 12 (4) (2006) 245–248.
- [10] M.H. Baumann, Closed needle biopsy of the pleura is a valuable diagnostic procedure, *J. Bronchology* 5 (4) (1998) 327–331.
- [11] Centers for Disease Control and Prevention, Treatment of Tuberculosis, *MMWR, American Thoracic Society, CDC, and Infectious Diseases Society of America*, 2003, 52(No. RR-11):[inclusive page numbers].
- [12] C. Wyser, et al., Corticosteroids in the treatment of tuberculous pleurisy. A double-blind, placebo-controlled, randomized study, *Chest* 110 (2) (1996) 333–338.
- [13] R.W. Light, Update on tuberculous pleural effusion, *Respirology* 15 (3) (2010) 451–458.
- [14] S. Bhuniya, et al., Role of therapeutic thoracentesis in tuberculous pleural effusion, *Ann. Thorac. Med.* 7 (4) (2012) 215–219.
- [15] C.L. Chung, et al., Early effective drainage in the treatment of loculated tuberculous pleurisy, *Eur. Respir. J.* 31 (6) (2008) 1261–1267.
- [16] Y.F. Lai, et al., Pigtail drainage in the treatment of tuberculous pleural effusions: a randomised study, *Thorax* 58 (2) (2003) 149–151.
- [17] R. Thomas, Y.C. Lee, Causes and management of common benign pleural effusions, *Thorac. Surg. Clin.* 23 (1) (2013) 25–42 v–vi.
- [18] N.A. Maskell, et al., U.K. Controlled trial of intrapleural streptokinase for pleural infection, *N. Engl. J. Med.* 352 (9) (2005) 865–874.
- [19] N.M. Rahman, et al., Intrapleural use of tissue plasminogen activator and DNase in pleural infection, *N. Engl. J. Med.* 365 (6) (2011) 518–526.
- [20] C.S. Park, et al., Transcatheter instillation of urokinase into loculated pleural effusion: analysis of treatment effect, *AJR Am. J. Roentgenol.* 167 (3) (1996) 649–652.
- [21] S.M. Kwak, et al., The effects of urokinase instillation therapy via percutaneous transthoracic catheter in loculated tuberculous pleural effusion: a randomized prospective study, *Yonsei Med. J.* 45 (5) (2004) 822–828.
- [22] E. Cases Viedma, et al., A study of loculated tuberculous pleural effusions treated with intrapleural urokinase, *Respir. Med.* 100 (11) (2006) 2037–2042.