

12-23-2022

## Late Descemet Membrane Detachment After Uneventful Cataract Surgery

Lovaglio Cançado Trindade  
*Medical Sciences Medical School-FELUMA*

Renata Attanasio de Rezende  
*São Vicente de Paulo Hospital*

Tiago Bisol  
*São Vicente de Paulo Hospital*

Christopher J Rapuano  
*Thomas Jefferson University*

Follow this and additional works at: <https://jdc.jefferson.edu/willsfp>

 Part of the [Ophthalmology Commons](#)


[Let us know how access to this document benefits you](#)

---

### Recommended Citation

Trindade, Lovaglio Cançado; Attanasio de Rezende, Renata; Bisol, Tiago; and Rapuano, Christopher J, "Late Descemet Membrane Detachment After Uneventful Cataract Surgery" (2022). *Wills Eye Hospital Papers*. Paper 175.  
<https://jdc.jefferson.edu/willsfp/175>

This Article is brought to you for free and open access by the Jefferson Digital Commons. The Jefferson Digital Commons is a service of Thomas Jefferson University's [Center for Teaching and Learning \(CTL\)](#). The Commons is a showcase for Jefferson books and journals, peer-reviewed scholarly publications, unique historical collections from the University archives, and teaching tools. The Jefferson Digital Commons allows researchers and interested readers anywhere in the world to learn about and keep up to date with Jefferson scholarship. This article has been accepted for inclusion in Wills Eye Hospital Papers by an authorized administrator of the Jefferson Digital Commons. For more information, please contact: [JeffersonDigitalCommons@jefferson.edu](mailto:JeffersonDigitalCommons@jefferson.edu).



# Late Descemet membrane detachment after uneventful cataract surgery

Bruno Lovaglio Cançado Trindade<sup>a,b,c,\*</sup>, Renata Attanasio de Rezende<sup>d,e,f</sup>, Tiago Bisol<sup>d,e,f</sup>, Christopher J. Rapuano<sup>g,h</sup>

<sup>a</sup> Medical Sciences Medical School–FELUMA, Belo Horizonte, Brazil

<sup>b</sup> Medical Sciences Eye Institute–FELUMA, Belo Horizonte, Brazil

<sup>c</sup> Cançado-Trindade Eye Institute, Belo Horizonte, Brazil

<sup>d</sup> PUC-Rio University, Rio de Janeiro, Brazil

<sup>e</sup> Instituto de Diagnóstico e Terapia Ocular, Rio de Janeiro, Brazil

<sup>f</sup> São Vicente de Paulo Hospital, Rio de Janeiro, Brazil

<sup>g</sup> Wills Eye Hospital, Philadelphia, PA, USA

<sup>h</sup> Sidney Kimmel Medical College of Thomas Jefferson University, Philadelphia, PA, USA

## ARTICLE INFO

### Keywords:

Descemet membrane

Cornea

Cataract surgery

## ABSTRACT

**Purpose:** To report 5 patients with late Descemet membrane (DM) detachment after uneventful cataract surgery. **Observations:** After a retrospective chart analysis of consecutive patients that developed DM detachment after uneventful cataract surgery, six eyes of five patients were enrolled. In all cases, patients reported good vision initially after cataract surgery. Within days to months, these patients developed late DM detachment with decreased vision. In one patient, the detachment affected both eyes. Filtered air or diluted sulfur hexafluoride were injected in the anterior chamber to tamponade the DM detachment. In five eyes, the cornea cleared after DM reattachment. In two eyes of the same patient, DM reattached spontaneously requiring no further surgical intervention. In one patient, the Descemet failed to reattach and required an endothelial keratoplasty. **Conclusion and importance:** Descemet membrane detachment may occur after uneventful cataract surgery. Filtered air or long-lasting intraocular gas may be used to reattach DM. Spontaneous DM reattachment may also occur and surgeons should be aware of this to avoid unnecessary procedures.

## 1. Introduction

The human cornea has a natural cleavage plane between deep stroma and Descemet membrane (DM).<sup>1</sup> This has been widely known and used in lamellar corneal surgery such as Descemet Membrane Endothelial Keratoplasty (DMEK) and Deep Anterior Lamellar Keratoplasty (DALK).<sup>2,3</sup> Dua et al. more recently described another cleavage plane between the posterior stroma and a pre-Descemet layer.<sup>4</sup> Unintentional Descemet membrane detachment may occur during or after intraocular surgery and its consequences are usually localized corneal edema and decreased visual acuity. Different mechanisms may be implicated in DM detachment such as the use of blunt keratomes, small incisions, excessive intraocular manipulation, premature injection of saline or ophthalmic viscosurgical devices (OVD) which may cleave off the membrane, endothelial pump failure and corneal dystrophies.<sup>5,6</sup> DM detachment after intraocular surgery usually occurs adjacent to the

incisions and may progress centrally leading to a more symptomatic presentation. More rarely, DM detachment may occur late after an uneventful intraocular surgery.<sup>7,8</sup> These detachments can present weeks or months after surgery and may compromise vision in an already “surgically-recovered” eye. Despite few published cases describing this complication, we believe this may be an underrecognized condition and the purpose of this paper is to report 5 patients with late DM detachment after uneventful cataract surgery.

## 2. Findings

### 2.1. Case 1

A 65-year-old white female presented 1.5 months after uneventful bilateral cataract and posterior chamber IOL implantation complaining of decreased visual acuity in both eyes with the right eye more

Abbreviations: SF6, sulfur hexafluoride.

\* Corresponding author. Rua Manaus 595, São Lucas - 30.150-350, Belo Horizonte, MG, Brazil.

E-mail address: [bruno.trindade@ioct.org](mailto:bruno.trindade@ioct.org) (B.L.C. Trindade).

<https://doi.org/10.1016/j.ajoc.2022.101783>

Received 16 August 2022; Received in revised form 14 December 2022; Accepted 18 December 2022

Available online 23 December 2022

2451-9936/© 2022 The Authors. Published by Elsevier Inc. This is an open access article under the CC BY-NC-ND license (<http://creativecommons.org/licenses/by-nc-nd/4.0/>).

significantly involved. She was initially treated for possible herpetic endotheliitis by other ophthalmologists with no improvement of her vision. Cataract surgeries were performed one week apart and patient reported excellent vision in both eyes for 2 weeks post-operatively. On presentation, her best-corrected visual acuity was limited to 20/120 in her right eye and 20/25 in her left. She had a large DM detachment involving the central and temporal aspect of the right cornea and a much less pronounced temporal peripheral DM detachment in her left eye (Fig. 1).

She had a history of Fuchs endothelial corneal dystrophy (FECD) with moderate corneal guttae noted in both eyes. She was treated with filtered air injection in the anterior chamber of her right eye. Despite an initial improvement of her edema and vision, 3 weeks after the air tamponade the DM re-detached and the cornea became edematous once again. At this same time, the detached DM in the untouched left eye had completely spontaneously resolved with corneal clearing and improvement of vision (Fig. 2).

Because of the total spontaneous resolution of the left eye, it was then decided to clinically monitor and not to rebubble the right eye. Three months later, a complete DM reattachment in the right eye was seen with total resolution of the corneal edema. Some central DM wrinkles remained limiting best-corrected vision to 20/30 (Fig. 3).

## 2.2. Case 2

A 65-year-old white female presented with ocular discomfort and decreased vision (BCVA 20/80) in her OD. She underwent uneventful cataract surgery using a 2.75 mm temporal clear corneal incision three weeks prior. Her first and fifth postoperative-day visits were unremarkable with a clear central cornea and only mild peri-incisional corneal edema was noted. Three weeks later, she had central corneal edema, Descemet's folds and trace cells in the anterior chamber with a normal intraocular pressure (17 mmHg OU). (Fig. 4A–C).

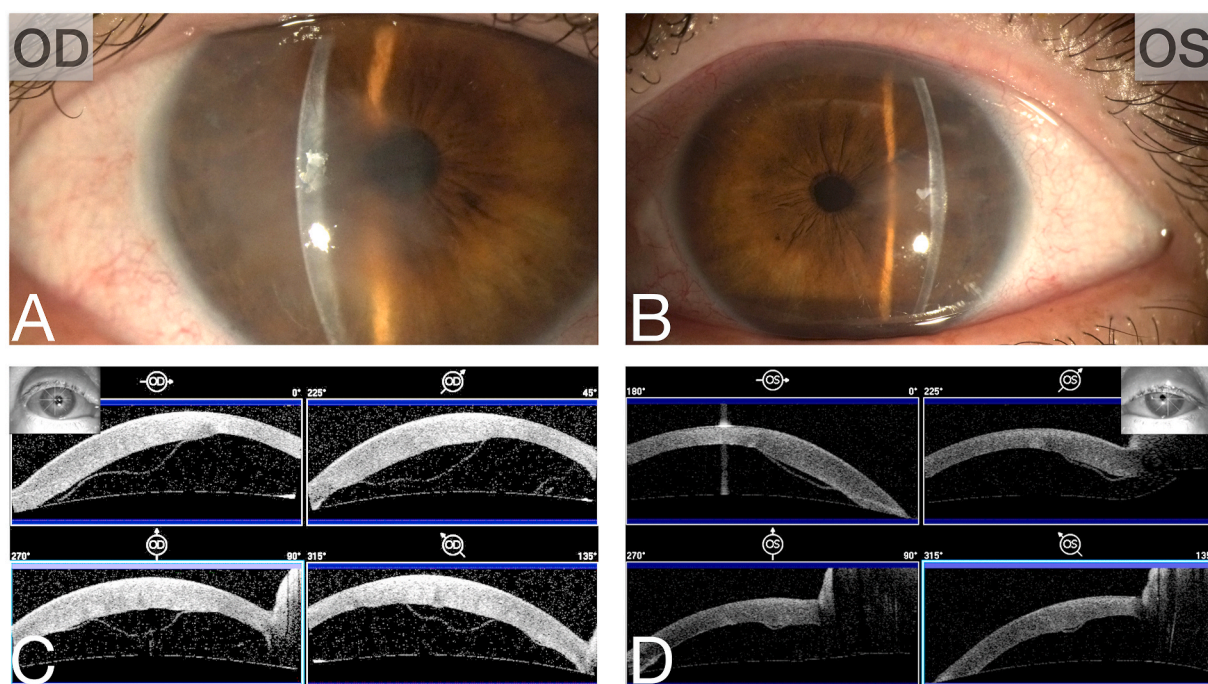
Herpetic endotheliitis was suspected and she was started on topical prednisolone 1% 6x/day and oral valacyclovir 500mg BID. Five days later, an anterior segment optical coherence tomography (AS-OCT) revealed DM detachment in the central cornea not contiguous to the

corneal incision site (Fig. 4D–F). Before surgery, her central corneal thickness was 600  $\mu\text{m}$  with a completely normal corneal endothelium showing 2250 cells/ $\text{mm}^2$  and no guttae on specular microscopy. Laboratory investigation showed positive IgG and negative IgM antibodies for HSV, VZV and CMV. Despite two weeks of topical steroids and systemic antivirals, the cornea edema and BCVA worsened (20/200). Injection of filtered air in the anterior chamber (AC) was then performed. After that, the DM detachment resolved with clearing of the corneal edema and improvement of visual acuity (Fig. 5).

Topical steroids were tapered and antivirals were discontinued. Two months later, her BCVA was 20/25 with a clear cornea and no edema, stromal fibrosis or DM scars. Six months later she underwent cataract surgery with posterior chamber IOL implantation in the other eye (OS) with no postoperative complications. During a five-year follow-up, she showed no Descemet detachment recurrence or any other corneal symptoms.

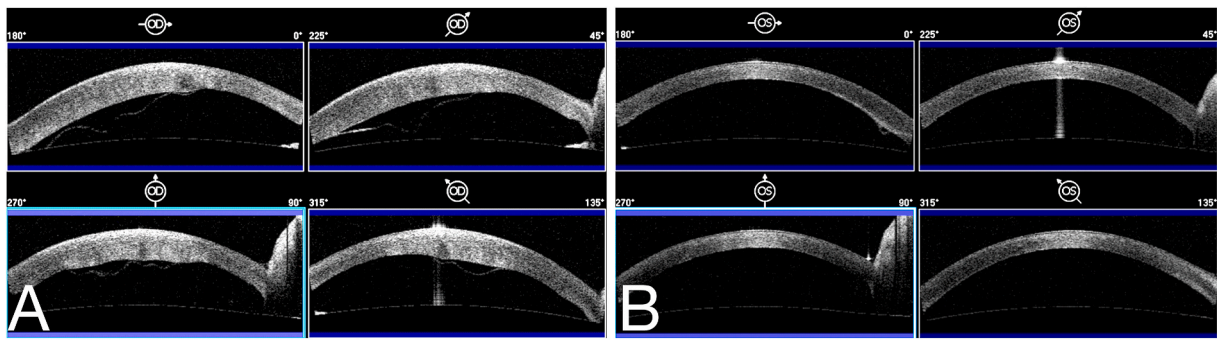
## 2.3. Case 3

A 61-year-old white female presented 4 months after YAG posterior capsulotomy in her right eye complaining of persistent decreased vision since the capsulotomy procedure. She had a history of cataract surgery with posterior-chamber IOL implantation 10 months before the capsulotomy procedure. There are no records of the cataract surgery but no complications were mentioned and patient described very good vision after her cataract surgery. She had history of FECD however, no symptoms related to this were found in her records before presentation. On presentation, she had a central DM detachment involving 60% of her cornea with severe central edema. She was treated with 18% sulfur hexafluoride ( $\text{SF}_6$ ) intracameral gas injection 6 weeks after DM detachment was diagnosed. The cornea failed to clear after gas injection due to persistent DM detachment and she underwent Descemet Stripping Endothelial Keratoplasty (DSEK) procedure 6 weeks later. After endothelial keratoplasty, her best-corrected visual acuity improved to 20/30.

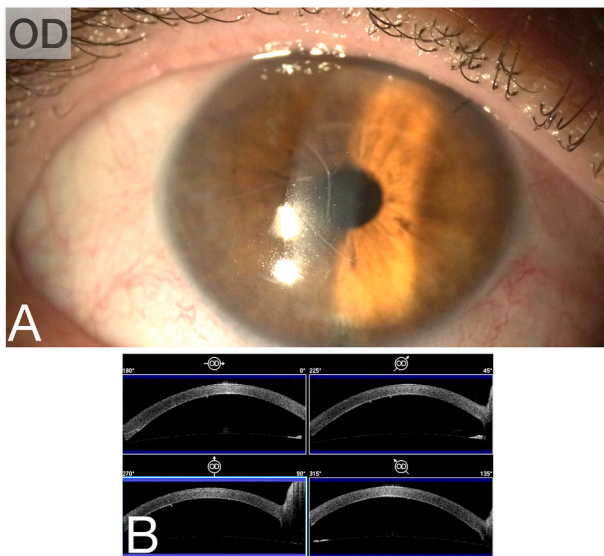


**Fig. 1.** A and B: Note the corneal edema caused by DM detachment in both eyes 1.5 months after uneventful cataract surgery. AS-OCT showing extensive DM detachment in the right eye (C) and more peripherally in the left eye (D).





**Fig. 2.** Note persistence of DM detachment in the right eye (A) 3 weeks after intracameral air injection. The left eye (B) had a spontaneous resolution of the DM detachment.



**Fig. 3.** Clearing of the corneal edema with re-attachment of the DM. Note some wrinkles in DM seen in biomicroscopy (A) and in the AS-OCT (B).

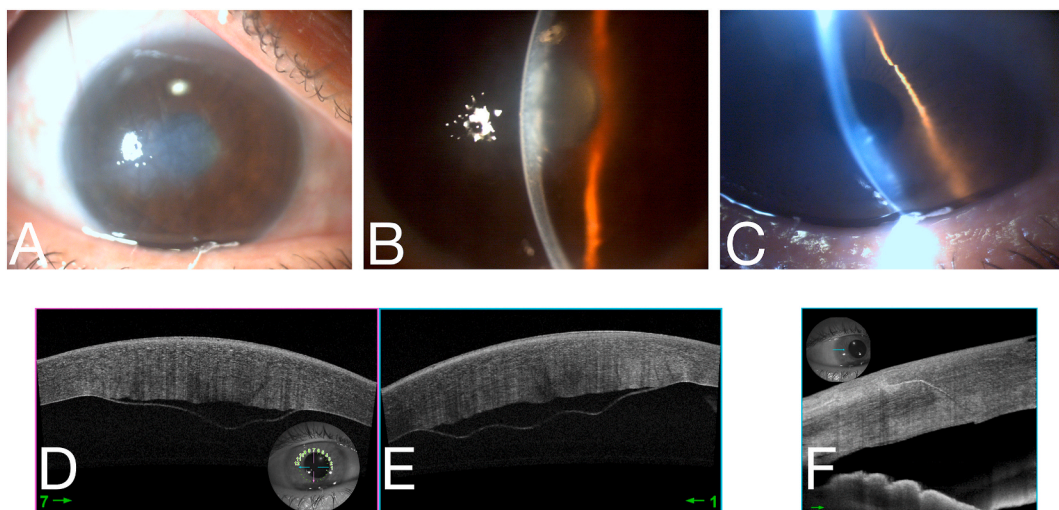
#### 2.4. Case 4

A 78-year-old white female presented 8 days after cataract surgery and posterior chamber IOL implantation with decreased vision in the left eye. She reported very good vision initially after surgery but it was worsening for the past couple of days. Surgery had been performed through a temporal clear corneal incision and no intraoperative complications were noted. She had no known endothelial dystrophy and the cornea of the fellow eye was noted to be completely normal. She presented with a 50% DM detachment that involved the superior and inferior cornea, sparing the central portion (Fig. 6).

Despite the central DM being attached, mild central corneal edema was noted and visual acuity was limited to 20/40. She was also treated with intracameral injection of 18% diluted SF<sub>6</sub> gas two days after DM detachment was seen. After gas absorption, the DM had fully reattached and the cornea became transparent. Her final uncorrected visual acuity, 4 months after DM detachment repair, was 20/40 pinholing to 20/30.

#### 2.5. Case 5

Another 78-year-old white female presented with decreased vision 2.5 months after cataract and posterior chamber IOL implantation in her right eye using a temporal clear corneal incision. No intraoperative complications were noted. The patient reported very good vision shortly after surgery. She presented with a 75% central DM detachment with severe corneal edema. Vision was limited to counting fingers at 3 feet. 18% diluted SF<sub>6</sub> gas was injected in the anterior chamber 6 weeks later. After gas injection, DM was 90% reattached with just a small residual



**Fig. 4.** A–C: Central corneal edema noted 3 weeks after uneventful cataract surgery. D and E: Note the central detachment of the Descemet membrane. F: OCT image of the incision site shows completely attached DM.

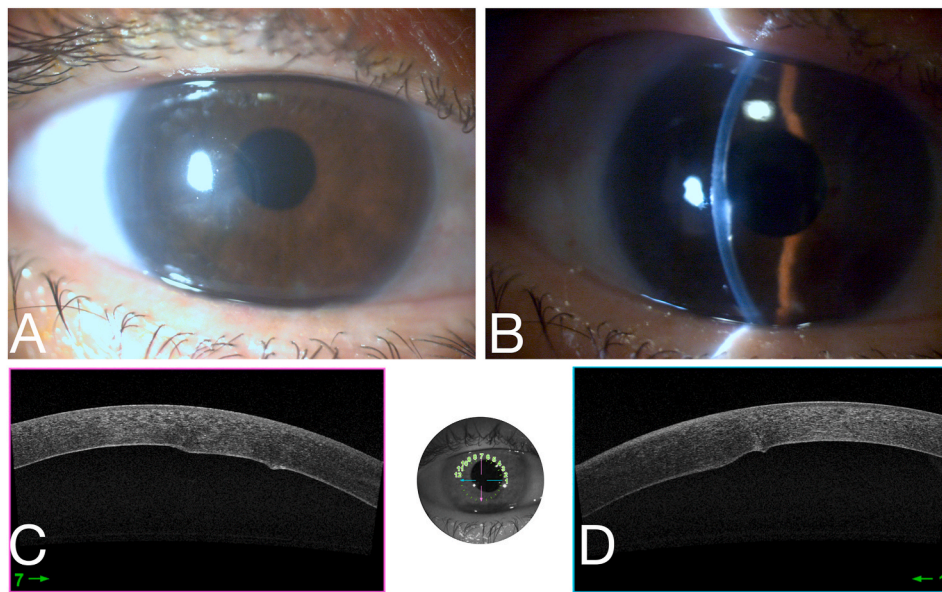


Fig. 5. Clearing of the corneal edema (A and B) with re-attachment of the DM seen on AS-OCT (C and D) 12 days after intracameral air injection.

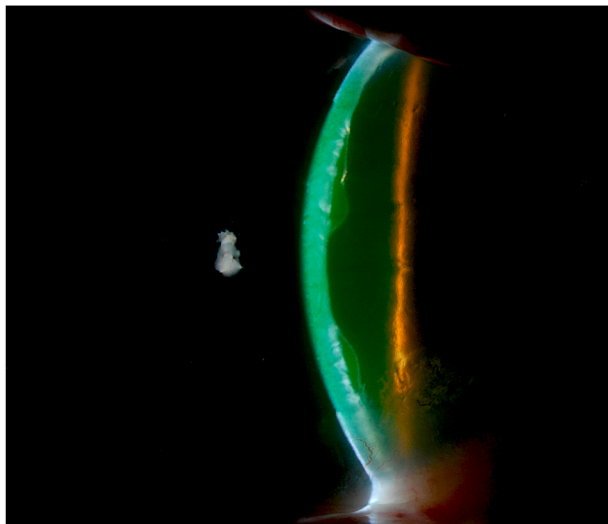


Fig. 6. Note the large, primarily peripheral DM detachment with a central portion still attached.

inferior persistent detachment noted that was clinically monitored. The cornea became transparent and visual acuity was restored to 20/20 2.5 months after detachment repair.

### 3. Discussion

Descemet membrane detachment during cataract surgery is a relatively common condition and it is usually noted adjacent to the main or sideport incisions. The incidence is variable but it has been reported to be as low as 0.04% to as high as 43%.<sup>5</sup> Clear corneal incisions, blunt keratomes, excessive intraocular manipulation, shallow anterior chamber among other conditions have been shown to cause this complication.<sup>5</sup> Most of these cases require no specific treatment and the peri-incisional corneal edema usually resolves within a few days after surgery. However, it is important to point out that mechanical detachments caused by premature saline or OVD injection among others may require prompt diagnosis and specific treatment such as evacuating the offending agent to reposition DM. It is more common in patients with

endothelial disorders such as in Fuchs endothelial corneal dystrophy in which the ultrastructure differences in DM may explain the higher chance of DM detachment.<sup>1</sup>

More recently, Dua et al. published a new classification of DM detachment in which detachments are divided between those that include and the ones that do not include the pre-Descemet layer (PDL) on the detached membrane.<sup>9</sup> The ones including the PDL are shown to be a taut hyperreflective line. When the detached membrane does not include the PDL, it is thin and undulating.

Although rare, late DM detachments have been reported in the literature before.<sup>7,8,10</sup> These detachments usually develop after uneventful cataract surgery however, other procedures have also been implicated including filtering surgery and YAG posterior capsulotomy.<sup>11,12</sup> The time between surgery and presentation of symptoms may vary from days to months.<sup>7,8,10,13</sup> The exact mechanism responsible for these detachments remains unclear but endothelial diseases may play a role. The detachment may involve the central cornea and usually produces a diffuse corneal edema with significant impact in visual acuity. Patients' complaints may include sudden decrease in visual acuity, foreign body sensation and tearing. Viral endotheliitis and bullous keratopathy are common differential diagnoses but a careful biomicroscopy and/or and AS-OCT can show the detached Descemet membrane. Bilateral involvement is rare and only a few cases have been published.<sup>7,8</sup> A functional deficiency of the anchoring TGF- $\beta$ 1 protein has been demonstrated to cause a weak attachment between the posterior stroma and DM and might explain the involvement of both eyes.<sup>14</sup> With this in mind, surgeons should be aware of fellow eye involvement in cases of late DM detachment after surgery.

Marcon et al. reported 15 eyes of 12 patients that developed DM detachment after different intraocular surgeries.<sup>7</sup> Out of the 15 eyes, 8 showed complete detachment regression with medical therapy alone with an average resolution time of 9.8 weeks after diagnosis. However, this series included cases of early-onset detachments that are more commonly found and known to have a higher chance of spontaneous re-attachment.

Gatziofias et al., reported a case of bilateral DM detachment 4 weeks after routine cataract surgery.<sup>8</sup> In this case, there was a large central DM detachment in both eyes not originating from the corneal incisions. Both corneas cleared after SF6 gas tamponade of the DM detachment.

We present 6 eyes of 5 patients with DM detachment occurring days to months after uneventful cataract surgery. These cases differ from the

more typical presentation since, in all, DM detachment developed later in the postoperative course and they had initial good visual acuity after surgery. In two patients (3 eyes), systemic antivirals were used to treat possible viral endotheliitis with no improvement of the DM detachment or of the corneal edema. Resolution of the DM detachment occurred in 3 of the 6 eyes after intracameral air or gas tamponade. In these patients, corneal edema subsided and visual acuity was restored. In one other eye, DM detachment was diagnosed 4 months after YAG posterior capsulotomy and 14 months after cataract surgery. Despite intracameral SF6 gas tamponade, DM failed to reattach and the patient required endothelial keratoplasty 6 weeks later. In one other patient, DM detachment was noted in both eyes, 1.5 months after cataract surgery. In this patient, there was complete and spontaneous resolution of the DM detachment 3 months after initial presentation in both eyes. In the less involved left eye, visual acuity was restored to 20/20 whereas in the right eye, some residual central Descemet wrinkles limited final acuity to 20/30.

#### 4. Conclusion

Postoperative Descemet detachment is a known condition that can preclude good vision. Successful reattachment has been shown to occur after filtered air or long-lasting gas injection in the anterior chamber such as with sulfur hexafluoride and perfluoropropane (C3F8). The ideal timing for treatment is still unclear but a sooner approach might be advisable to avoid stromal haze and possible further endothelial cell loss. However, spontaneous reattachment can occur and surgeons should be aware of this possibility to avoid unnecessary procedures. The decision regarding treatment alternatives should be individually tailored with a proper risk assessment for each patient.

#### Patient consent

Consent to publish this case report has been obtained from the patient(s) in writing.

#### Funding

No funding or grant support.

#### Authorship

All authors attest that they meet the current ICMJE criteria for

Authorship.

#### Declaration of competing interest

The following authors have no financial disclosure: (BLCT, RARB, TB, CJR).

#### Acknowledgements

None.

#### References

1. Ali M, Raghunathan V, Li JY, et al. Biomechanical relationships between the corneal endothelium and Descemet's membrane. *Exp Eye Res.* 2016;152:57–70.
2. Anwar M, Teichmann KD. Big-bubble technique to bare Descemet's membrane in anterior lamellar keratoplasty. *J Cataract Refract Surg.* 2002;28(3):398–403.
3. Tenkman LR, Price FW, Price MO. Descemet membrane endothelial keratoplasty donor preparation: navigating challenges and improving efficiency. *Cornea.* 2014;33(3):319–325.
4. Dua HS, Faraj LA, Said DG, et al. Human corneal anatomy redefined: a novel pre-Descemet's layer (Dua's layer). *Ophthalmology.* 2013;120(9):1778–1785.
5. Singhal D, Sahay P, Goel S, et al. Descemet membrane detachment. *Surv Ophthalmol.* 2020;65(3):279–293.
6. Assia EI, Levkovich-Verbin H, Blumenthal M. Management of Descemet's membrane detachment. *J Cataract Refract Surg.* 1995;21(6):714–717.
7. Marcon AS, Rapuano CJ, Jones MR, et al. Descemet's membrane detachment after cataract surgery: management and outcome. *Ophthalmology.* 2002;109(12):2325–2330.
8. Gatzlioufas Z, Schirra F, Low U, et al. Spontaneous bilateral late-onset Descemet membrane detachment after successful cataract surgery. *J Cataract Refract Surg.* 2009;35(4):778–781.
9. Dua HS, Sinha R, D'Souza S, et al. Descemet membrane detachment": a novel concept in diagnosis and classification. *Am J Ophthalmol.* 2020;218:84–98.
10. Chiu LY, Tseng HY. Descemet's membrane detachment following uneventful phacoemulsification surgeries: a case report. *Medicine (Baltim).* 2018;97(15), e0444.
11. Afriat M, Gueudry J, Cherif HY, et al. Descemet membrane detachment after Nd: YAG laser capsulotomy in a patient with fuchs dystrophy. *Cornea.* 2014;33(10):1103–1105.
12. Li YH, Shi JM, Fan F, et al. Descemet membrane detachment after trabeculectomy. *Int J Ophthalmol.* 2012;5(4):527–529.
13. Morkin MI, Hussain RM, Young RC, et al. Unusually delayed presentation of persistent Descemet's membrane tear and detachment after cataract surgery. *Clin Ophthalmol.* 2014;8:1629–1632.
14. Hirano K, Kojima T, Nakamura M, Hotta Y. Triple anterior chamber after full-thickness lamellar keratoplasty for lattice corneal dystrophy. *Cornea.* 2001;20(5):530–533.