

12-2021

## Reactive granulomatous dermatitis associated with ovarian cancer and a review of its role as a harbinger for malignancy

Alexander Sherban  
*Thomas Jefferson University*

Jisun Cha  
*Thomas Jefferson University*

Elizabeth Jones  
*Thomas Jefferson University*

Follow this and additional works at: <https://jdc.jefferson.edu/dcbfp>



Part of the [Dermatology Commons](#)

[Let us know how access to this document benefits you](#)

### Recommended Citation

Sherban, Alexander; Cha, Jisun; and Jones, Elizabeth, "Reactive granulomatous dermatitis associated with ovarian cancer and a review of its role as a harbinger for malignancy" (2021). *Department of Dermatology and Cutaneous Biology Faculty Papers*. Paper 162.

<https://jdc.jefferson.edu/dcbfp/162>

This Article is brought to you for free and open access by the Jefferson Digital Commons. The Jefferson Digital Commons is a service of Thomas Jefferson University's [Center for Teaching and Learning \(CTL\)](#). The Commons is a showcase for Jefferson books and journals, peer-reviewed scholarly publications, unique historical collections from the University archives, and teaching tools. The Jefferson Digital Commons allows researchers and interested readers anywhere in the world to learn about and keep up to date with Jefferson scholarship. This article has been accepted for inclusion in Department of Dermatology and Cutaneous Biology Faculty Papers by an authorized administrator of the Jefferson Digital Commons. For more information, please contact: [JeffersonDigitalCommons@jefferson.edu](mailto:JeffersonDigitalCommons@jefferson.edu).

# UC Davis

## Dermatology Online Journal

### Title

Reactive granulomatous dermatitis associated with ovarian cancer and a review of its role as a harbinger for malignancy

### Permalink

<https://escholarship.org/uc/item/5mt9v5r8>

### Journal

Dermatology Online Journal, 27(12)

### Authors

Sherban, Alexander  
Cha, Jisun  
Jones, Elizabeth

### Publication Date

2021

### DOI

10.5070/D3271256704

### Copyright Information

Copyright 2021 by the author(s). This work is made available under the terms of a Creative Commons Attribution-NonCommercial-NoDerivatives License, available at <https://creativecommons.org/licenses/by-nc-nd/4.0/>

Peer reviewed

# Reactive granulomatous dermatitis associated with ovarian cancer and a review of its role as a harbinger for malignancy

Alexander Sherban<sup>1</sup> BM, Jisun Cha<sup>2</sup> MD, Elizabeth Jones<sup>1</sup> MD FAAD

Affiliations: <sup>1</sup>Department of Dermatology and Cutaneous Biology, Thomas Jefferson University Hospital, Sidney Kimmel Medical College, Philadelphia, Pennsylvania, USA, <sup>2</sup>Schweiger Dermatology Group, New York, New York, USA

Corresponding Author: Elizabeth Jones MD FAAD, Jefferson Dermatology, 3521 Silverside Road, Suite 1L, Wilmington, DE 19810, Tel: 570-573-1745, Fax: 302-477-1994, Email: [Elizabeth.jones@jefferson.edu](mailto:Elizabeth.jones@jefferson.edu)

## Abstract

Reactive granulomatous dermatitis (RGD) is a rare dermatosis with a variety of cutaneous manifestations unified by a dermal granulomatous infiltrate on histology. Rheumatoid arthritis and autoimmune disease are classic associations, but an increasing number of cases have been attributed to covert malignancy. Only 41 cases of paraneoplastic RGD have been documented to our knowledge and we present an additional case that manifested eight months prior to the diagnosis of ovarian cancer and clinically mimicked morphea. Histopathologic examination identifying palisaded CD68+ cells and collagen degeneration are helpful in diagnosing this entity which may mimic a host of other cutaneous processes, including metastatic disease. Cancer-directed therapies have been successful in clearing paraneoplastic RGD with or without the addition of corticosteroids, as RGD severity may be driven by the underlying malignancy. This case highlights the importance of utilizing histopathology to confirm the diagnosis given its nonspecific clinical findings, as well as the importance of considering malignancy and metastatic disease in patients diagnosed with RGD regardless of their cancer history.

*Keywords: granulomatous dermatitis, paraneoplastic*

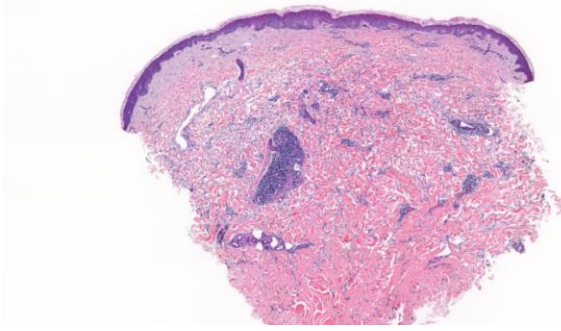
## Introduction

Reactive granulomatous dermatitis (RGD) encompasses a spectrum of rare cutaneous reactions with a variety of morphologies characterized by a

granulomatous infiltrate within the dermis [1,2]. Palisaded neutrophilic and granulomatous dermatitis (PNGD) and interstitial granulomatous dermatitis (IGD) were initially described as distinct dermatoses based on unique clinical and histologic features [1-2]. However, significant overlap in clinical presentation and histopathologic features were observed as more cases were identified, suggesting these two entities were poorly defined by earlier classifications and more likely driven by a similar disease process [1,2]. Although commonly attributed to connective tissue and autoimmune diseases, etiologies of reactive granulomatous dermatitis also include drugs and malignancy [1-17]. Herein, we review cases of paraneoplastic reactive granulomatous dermatitis and describe a patient that developed RGD eight months prior to a diagnosis of ovarian cancer and markedly improved following treatment with chemotherapy.

## Case Synopsis

A 66-year-old woman without significant medical history presented to the dermatology clinic for evaluation of an asymptomatic rash on her left abdomen that had been present for three months. It had not changed in appearance or size since it initially arose. The patient denied pruritus or pain. She had no similar prior cutaneous eruptions or autoimmune disease and denied any recent medication changes. She initially presented to her primary care physician who ordered Lyme serologies and provided topical clotrimazole and

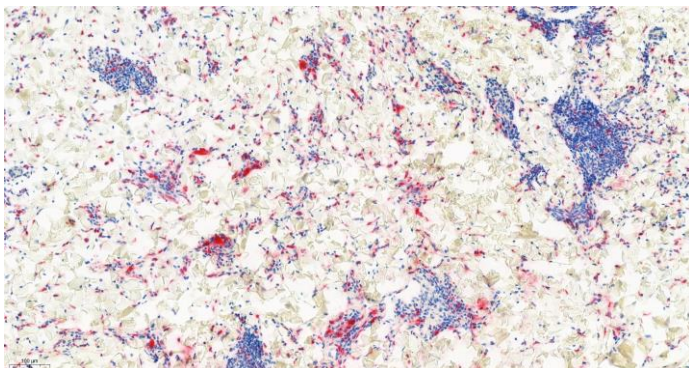


**Figure 1.** *Interstitial granulomatous dermatitis. The punch biopsy demonstrates perivascular lymphocytic inflammation and interstitial histiocytes with mucin deposition. H&E, 20x.*

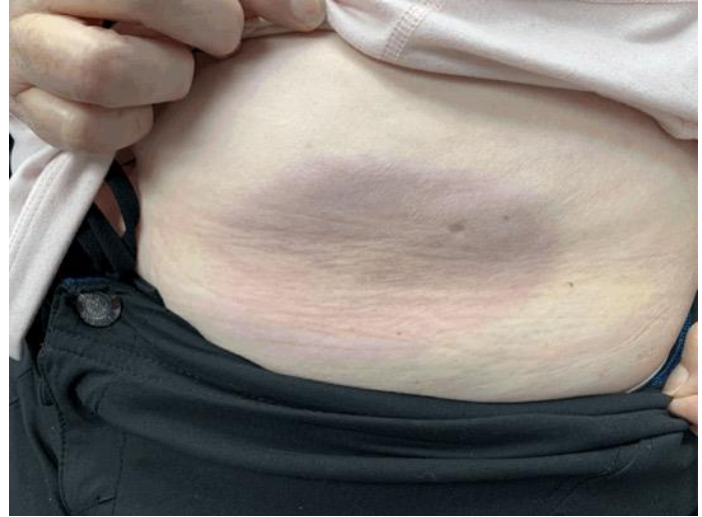betamethasone with no improvement. Upon dermatologic evaluation, the patient was found to have a well-defined, round and indurated plaque with lilac erythema on her left abdomen (**Figure 1**). A punch biopsy was performed to rule out morphea or Lyme disease.

Histopathology revealed perivascular and interstitial dermatitis with mild interstitial edema and mucin deposition. Mild sclerotic dermal changes were present with an infiltration of lymphocytes and histiocytes (**Figure 2**). Although these findings were not specific, the differential diagnosis included early morphea, granulomatous dermatitis, and much less likely, Lyme disease given the clinical correlation.

Lyme IgG and IgM were negative. The rash remained stable despite a 21-day course of oral doxycycline 100mg twice daily along with fluocinonide ointment. On follow up five months after initial presentation to the dermatology clinic, the patient stated the plaque had grown in size and become slightly more “firm.”



**Figure 2.** *Interstitial granulomatous dermatitis: CD68 immunostaining highlights interstitial histiocytes in the mid reticular dermis, 100x.*



**Figure 3.** *Interstitial granulomatous dermatitis as a round, indurated lilac-erythematous plaque on the left abdomen eight months prior to diagnosis of ovarian cancer.*

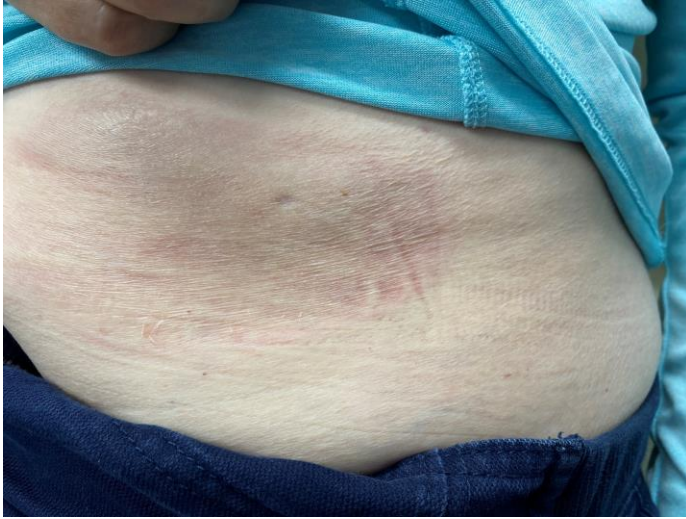No new lesions developed and she remained asymptomatic. Physical examination findings were unchanged from the initial visit. The patient remained on topical corticosteroids with persistence of cutaneous findings.

Eight months after initial presentation, the patient was diagnosed with left-sided ovarian epithelial carcinoma after experiencing episodes of left lower quadrant pain that prompted further investigation. The specimen was reexamined, and CD68 immunostaining revealed admixed interstitial histiocytes alongside other inflammatory cells. Immunostaining for pancytokeratin did not reveal any epithelial cells within the dermis to suggest cutaneous metastasis (**Figure 3**). As the patient underwent chemotherapy with carboplatin and paclitaxel, the abdominal plaque decreased in size with a notable reduction in erythema (**Figure 4**). Given these findings, the diagnosis was most consistent with paraneoplastic reactive granulomatous dermatitis, IGD-type secondary to ovarian cancer.

### Case Discussion

The term reactive granulomatous dermatitis (RGD) was proposed by Rosenbach et al. to unify PNGD, IGD, interstitial granulomatous drug reaction, and other granulomatous cutaneous reactions [1].





**Figure 4.** Interstitial granulomatous dermatitis of the left abdomen with a notable reduction in erythema and plaque size after initiation of chemotherapy.

Features shared by these once-considered unique processes has led to the use of the unifying term, whereas more classic presentations have been considered subtypes, such as RGD, IGD type [1].

### Clinical presentation

Interstitial granulomatous dermatitis was first described in 1993 by Ackerman et al. and grew to encompass a diverse array of clinical presentations [3-10]. Although IGD may be painful or pruritic, the majority of cases are asymptomatic [5,7]. Manifestations include annular lesions, red to purple firm nodules, or flesh-colored, pigmented, or erythematous papules [3-5]. Distribution is usually symmetrical, involving the lateral trunk, proximal extremities, groin, or buttocks [3-5]. Subcutaneous linear nodules known as “the rope sign” were considered pathognomonic, but they have only been reported in 10% of cases [5,7]. In fact, subcutaneous linear nodules have been observed in case reports of PNGD [1].

Palisaded neutrophilic and granulomatous dermatitis was initially described in 1994 by Chu et al. with manifestations including symmetric papules of extensor surfaces of upper extremities most commonly in females with systemic disease [1,4]. Lesions ranged from smooth to umbilicated, ulcerated, or crusted. Colors ranged from that of the patient’s normal, unaffected skin to erythematous

[1,4]. Since its initial description, several morphologic variants have emerged, leading to reliance on histopathology for definitive diagnosis [1]. Urticarial, edematous, and erythematous plaques, patches, and nodules with a variety of shapes ranging from annular to linear have been reported outside the typical areas of distribution, such as the lower extremities and head [1,4]. Although papules on the extensor surfaces were once considered characteristic of PNGD, they have been reported in cases of IGD [1].

### Histopathology

On histopathology, PNGD and IGD host a granulomatous infiltrate [1]. Histologic features of PNGD vary depending on the age of the lesion [15-18]. Early histologic changes include leukocytostatic vasculitis and a diffuse neutrophilic infiltrate before the development of palisading granulomas, CD68+ histiocytes, fibrin deposition, collagen degeneration, and neutrophilic karyorrhexis [1,2]. The interstitial granulomatous subtype of RGD is characterized by palisading CD68+ histiocytes, degenerating collagen, and a dense, diffuse interstitial infiltrate that may include neutrophils and eosinophils [5,6]. Typically, the absence of vasculitis has been used to differentiate IGD from PNGD and the absence of mucin has differentiated both from granuloma annulare [1-2]. It has been suggested that PNGD and IGD may represent the same disease process in different points in time, whereas the perivascular infiltrate and vasculitic changes seen in PNGD may precede the more diffuse dermal infiltrate observed in IGD [1,2].

### Pathophysiology

The underlying pathophysiology of RGD is not fully understood, but it is thought to be due to a delayed hypersensitivity reaction or an underlying inflammatory disorder that drives chronic perivascular immune complex deposition in dermal vessels [1,5,9]. This leads to a slow but persistent obstruction of small vessels that results in collagen break-down and the changes seen on histopathology [1,5].

### Etiology and review of paraneoplastic cases

Interstitial granulomatous dermatitis and PNGD were both strongly associated with autoimmune disease, such as rheumatoid arthritis (IGD) and connective tissue disease (PNGD), [1]. Since their description, RGD has been increasingly reported as a paraneoplastic phenomenon that may precede the diagnosis of an underlying hematologic or solid organ malignancy [1-35]. Forty-two cases of paraneoplastic reactive granulomatous dermatitis, including our own, have been reported in the literature to our knowledge [7-35]. Eighteen were reported as IGD, eleven as PNGD, and thirteen as cases of granulomatous dermatitis not otherwise specified [7-35]. [Tables 1-3](#) outline the reported cases in the literature of paraneoplastic RGD, IGD type, RGD, PNGD type, and RGD, not specified type.

The majority of reported cases have involved hematologic malignancies and lymphoma [12,14-35], whereas only eight cases, including the present, have involved solid organ malignancies [7-10,13]. Cases of granulomatous dermatitis not otherwise specified and the PNGD subtype all involved hematologic malignancies or lymphoma, with myelodysplastic syndrome (MDS) being the most common [12,14-35]. All reports of solid organ malignancies have been associated with the IGD subtype [7-10,13]. However, the majority of IGD cases (10/18) involved hematologic malignancies [7-10,13]. Reactive granulomatous dermatitis has predominantly affected females more than males in a 3:1 ratio, but paraneoplastic cases appear more evenly split with 22 cases involving males and 20 cases involving females [1,7-35].

Evidence from several cases underscores that RGD may serve as a harbinger for incipient malignancy. Our patient presented with RGD on her left abdomen eight months prior to her diagnosis of ovarian cancer. Six additional cases of paraneoplastic IGD preceded the diagnosis of malignancies, including lymphomas, esophageal cancer, acute leukemia, and multiple myeloma [9,14,15,17,18]. One case presented in a patient with a history of MDS, but the eruption preceded leukemic transformation suggesting that RGD may mirror disease severity

[14]. Similarly, three cases of PNGD preceded the diagnoses of acute myelomonocytic leukemia, multiple myeloma, lymphocytic lymphoma, and chronic myelomonocytic leukemia [24,26,27]. Four cases of unspecified granulomatous dermatitis preceded diagnoses of MDS and leukemias, with two cases occurring prior to acute leukemic transformation in patients with histories of MDS [32, 35-37]. In 1993, Vestey et al. reported two cases of granulomatous reactions (an atypical granuloma annulare and a sarcoid-like reaction) that preceded leukemic transformation from MDS [38]. The diagnosis of RGD has preceded the diagnosis of malignancy in as little as three months and as long as two years [7-35].

However, not all cases of paraneoplastic RGD precede the diagnosis of a neoplasia, with several cases presenting at the same time or years after the diagnosis of malignancy. Twelve cases of patients presenting with RGD led to simultaneous investigation and diagnosis of an underlying malignancy [11,13,16,19,21-25,30,34]. Nine cases were reported in which RGD was diagnosed up to 12 years after a diagnosis of malignancy [8,12,20,28,29,31,32].

Successful treatments of paraneoplastic RGD have included both topical and systemic corticosteroids, antineoplastic therapies, and various combinations [7-38]. In 1998, Schreckenberget al. reported a case of a 62-year-old man who developed an inflammatory plaque of the lower extremity consistent with RGD along with symptoms confirmed to be due to squamous cell carcinoma of the lung [13]. The patient underwent surgical excision of his lung tumor, and his RGD, IGD type resolved completely within four weeks [13]. Other cases have further suggested that RGD may be a cutaneous reflection of underlying malignancy severity or tumor burden, with successful anti-neoplastic therapies including bone marrow transplantation and chemotherapy leading to concomitant resolution of RGD and cancer remission [12,13,15-17,21,30,38].

This association is exemplified by a patient with esophageal cancer whose RGD did not respond to systemic corticosteroids or tumor directed chemotherapy and radiation therapy [7]. The patient

ultimately expired due to his malignancy, which may indicate his treatment refractory RGD mirrored his treatment refractory carcinoma.

Topical and systemic corticosteroids have had various success rates in clearing RGD lesions. A 44-year-old woman developed indurated erythematous plaques on her extremities and trunk consistent with RGD, IGD type, two years after the diagnosis and treatment of breast cancer [10]. Systemic corticosteroids led to complete resolution of her lesions 18 weeks after initiation of therapy [10]. However, such treatments not directed at the neoplasia may be better suited as adjuvants.

Twenty of the 42 paraneoplastic cases reported exhibited complete resolution of RGD [7-38]. Of these 20 cases, 15 were given anti-neoplastic treatments with or without corticosteroids [12,13,15-17,19,21,25,27,30,31,36,38]. Two patients with endometrial cancer and breast cancer achieved resolution of RGD with systemic corticosteroids alone, but it is important to note the latter presented with RGD two years after the diagnosis and treatment of breast cancer [9-10]. One patient with multiple myeloma achieved complete remission of his RGD after treatment with bisphosphonates [18]. A patient with IgA monoclonal gammopathy achieved complete resolution without any treatment [9] and a patient who developed RGD 1.8 years prior to the diagnosis of Hodgkin lymphoma achieved complete resolution of RGD without treatment and prior to the cancer diagnosis [9].

Anti-neoplastic therapies appear to be the most promising treatment. A case of RGD, IGD type, due to undiagnosed myelodysplastic syndrome (MDS) recurred after treatment with systemic corticosteroids but completely resolved following initiation of MDS-targeted-chemotherapy [15]. Another case of RGD, IGD type, presented two years prior to the diagnosis of MDS with progression to acute myelocytic leukemia [35]. The lesions persisted despite treatment with hydroxychloroquine, topical corticosteroids, and intramuscular corticosteroids

[35]. Once the malignancy was identified, the patient showed improvement in his RGD following initiation of chemotherapy [35]. A patient with chronic lymphocytic leukemia prior to RGD diagnosis was treated with intralesional and topical corticosteroids without response [12]. However, initiation of chemotherapy led to complete resolution of RGD and remission of chronic lymphocytic leukemia within 6 months [12].

Although RGD may be a paraneoplastic process, it is important to consider cutaneous metastasis in patients with cancer history or those at increased risk presenting with RGD-like lesions. Cutaneous metastases may mimic the histological appearance of RGD, as Hartman et al. reported three cases of cutaneous metastases with palisading atypical cells [39]. Immunohistochemical analysis with stains for pancytokeratin or epithelial membrane antigen can help differentiate cutaneous metastasis from RGD and more benign entities [39].

## Conclusion

Our case highlights a rare etiology of an already uncommon condition. Although RGD has a broad variety of clinical manifestations, it is important to utilize dermatopathology analysis and immunohistochemistry to achieve the correct diagnosis and rule out aggressive mimics or other dermatidides. Given the increasing reported cases of paraneoplastic RGD, it may be warranted to investigate possible underlying malignancy in older patients diagnosed with IGD without arthritis or autoimmune disease. Increased cancer surveillance to rule out recurrence should also be considered in patients who present with RGD and remote histories of cancer, even if successfully treated. Further investigation is needed to better understand the relationship between malignancy and IGD.

## Potential conflicts of interest

The authors declare no conflicts of interest.



## References

- Rosenbach M, English JC 3rd. Reactive Granulomatous Dermatitis: A Review of Palisaded Neutrophilic and Granulomatous Dermatitis, Interstitial Granulomatous Dermatitis, Interstitial Granulomatous Drug Reaction, and a Proposed Reclassification. *Dermatol Clin*. 2015;33:373-387. [PMID: 26143420].
- Rodríguez-Garijo N, Bielsa I, Mascaró JM Jr, et al. Reactive granulomatous dermatitis as a histological pattern including manifestations of interstitial granulomatous dermatitis and palisaded neutrophilic and granulomatous dermatitis: a study of 52 patients. *J Eur Acad Dermatol Venereol*. 2021;35:988-994. [PMID: 33098595].
- Ackerman AB. Clues to diagnosis in dermatopathology. *Am J Dermatopathology* 1992;14:74. [https://journals.lww.com/amjdermatopathology/Citation/1992/02000/CLUES\\_TO\\_DIAGNOSIS\\_IN\\_DERMATOPATHOLOGY.67.aspx](https://journals.lww.com/amjdermatopathology/Citation/1992/02000/CLUES_TO_DIAGNOSIS_IN_DERMATOPATHOLOGY.67.aspx).
- Chu P, Connolly MK, LeBoit PE. The histopathologic spectrum of palisaded neutrophilic and granulomatous dermatitis in patients with collagen vascular disease. *Arch Dermatol*. 1994;130:1278-1283. [PMID: 7944509].
- Bolognia, J. L., Schaffer, J. V., Cerroni, L., & Callen, J. P. *Dermatology*. Edinburgh: Elsevier. 2018
- Beretta-Piccoli BT, Mainetti C, Peeters M-A, Laffitte E. Cutaneous Granulomatosis: a Comprehensive Review. *Clin Rev Allergy Immunol*. 2018;54:131-146. [PMID: 29352388].
- Moyano Almagro B, López Navarro N, Contreras Steyls M, Gallego Dominguez E, Herrera Acosta E, Herrera Ceballos E. Interstitial granulomatous dermatitis and arthritis revealing oesophageal carcinoma. *Clin Exp Dermatol*. 2013;38:501-503. [PMID: 23777491].
- Kim S, Cho S, Lee J, Kim H. Interstitial Granulomatous Dermatitis in a Patient with Prostate Cancer. *Ann Dermatol*. 2017;29:337. [PMID: 28566913].
- Peroni A, Colato C, Schena D, Gisondi P, Girolomoni G. Interstitial granulomatous dermatitis: a distinct entity with characteristic histological and clinical pattern. *Br J Dermatol*. 2012;166:775-783. [PMID: 22059717].
- Busquets-Pérez N, Narvaez J, Valverde-García J. Interstitial granulomatous dermatitis with arthritis (Ackerman syndrome). *J Rheumatol*. 2006;33:1207-9. [PMID: 16755676].
- Swing DC Jr, Sheehan DJ, Sangüeza OP, Woodruff RW. Interstitial granulomatous dermatitis secondary to acute promyelocytic leukemia. *Am J Dermatopathol*. 2008;30:197-199. [PMID: 18360133].
- Riaz I, Kamal M, Segal R, Anwer F. First reported association of chronic lymphocytic leukaemia and interstitial granulomatous dermatitis. *BMJ Case Rep*. 2016:bcr2016215108. [PMID: 27194675].
- Schreckenber C, Asch PH, Sibilia J, Walter S, Lipsker D, Heid E, Grosshans E. Dermite granulomateuse interstitielle et polyarthrite rhumatoïde paranéoplasiques révélatrices d'un cancer du poumon [Interstitial granulomatous dermatitis and paraneoplastic rheumatoid polyarthritis disclosing cancer of the lung]. *Ann Dermatol Venereol*. 1998;125:585-8.
- Cornejo KM, Lum CA, Izumi AK. A cutaneous interstitial granulomatous dermatitis-like eruption arising in myelodysplasia with leukemic progression. *Am J Dermatopathol*. 2013;35:e26-e29. [PMID: 23221468].
- Patsinakidis N, Susok L, Hessam S, et al. Interstitial granulomatous dermatitis associated with myelodysplastic syndrome—complete clearance under therapy with F5-azacytidine. *Acta Derm Venereol* 2014;94:725–6. [PMID: 24573709].
- Choi MJ, Shin D, Kim YC, Oh SH, Kim M. Interstitial granulomatous dermatitis with arthritis accompanied by anaplastic large cell lymphoma. *J Dermatol*. 2014;41:363-364. [PMID: 2453390].
- Michailidou D, Voulgarelis M, Pikazis D. Exacerbation of interstitial granulomatous dermatitis with arthritis by anakinra in a patient with diffuse large B-cell lymphoma. *Clin Exp Rheumatol*. 2014;32:259-261. [PMID: 24480300].
- Thompson L, Abner S, Malone J, Callen JP. Interstitial Granulomatous Dermatitis as the Initial Manifestation of Myeloma. *JAMA Dermatology*. 2015;151:1141. [PMID: 26039702].
- Cases-Merida S, Lorente-Lavirgen A, Pérez-Gil A. Interstitial Granulomatous Dermatitis due to a Rare Myeloproliferative Neoplasia. *Indian J Dermatol*. 2018;63:264-267. [PMID: 29937566].
- Zabihi-Pour D, Bahrani B, Assaad D, Yeung J. Palisaded neutrophilic and granulomatous dermatitis following a long-standing monoclonal gammopathy: A case report. *SAGE Open Med Case Rep*. 2021;9:2050313X20979560. [PMID: 29937566].
- Kohlmann J, Schüürmann M, Simon JC, Treudler R. Palisaded neutrophilic and granulomatous dermatitis in a patient with chronic myelomonocytic leukaemia. *J Eur Acad Dermatol Venereol*. 2019;33:e241-e242. [PMID: 30773700].
- Pei S, Hinshaw MA. Palisaded Neutrophilic Granulomatous Dermatitis Leading to Diagnosis of Hodgkin Lymphoma: Report of Rare Case and Literature Review of Paraneoplastic Granulomatous Dermatitis. *Am J Dermatopathol*. 2019;41:835-845. [PMID: 30921008].
- Deen J, Banney L, Perry-Keene J. Palisading neutrophilic and granulomatous dermatitis as a presentation of Hodgkin lymphoma: A case and review. *J Cutan Pathol*. 2018;45:167-170. [PMID: 29226345].
- Federmann B, Bonzheim I, Yazdi AS, Schmidt J, Fend F, Metzler G. Generalized palisaded neutrophilic and granulomatous dermatitis—a cutaneous manifestation of chronic myelomonocytic leukemia? A clinical, histopathological, and molecular study of three cases. *Hum Pathol*. 2017;64:198-206. [PMID: 28442268].
- Calonje JE, Greaves MW. Cutaneous extravascular necrotizing granuloma (Churg-Strauss) as a paraneoplastic manifestation of non-Hodgkin's B-cell lymphoma. *J R Soc Med*. 1993;86:549-550. [PMID: 8410900].
- Finan MC, Winkelmann RK. Cutaneous extravascular necrotizing granuloma and lymphocytic lymphoma. *Arch Dermatol*. 1983;119:419-422. [PMID: 6687788].
- Winkelmann RK, Dicken CH. Cutaneous Churg-Strauss granuloma associated with lymphoproliferative disease. *Rev Argent Dermatol* 1980;61:1-4.
- Tabata MM, Novoa RA, Martires KJ. Paraneoplastic granulomatous dermatitis in a patient with Hodgkin's disease: a diagnostic pitfall. *BMJ Case Rep*. 2018;2018:bcr2018224961. [PMID: 30100570].
- Weed J, Ko C, Stahl M, et al. Reactive granulomatous dermatitis presenting as subcutaneous nodules and cords in a patient with advanced myelodysplastic syndrome. *Ann Hematol*. 2017;96:1037-1039. [PMID: 28220192].
- Beauverd Y, Cortés B, Masouye I, Chalandon Y. Complete remission of disseminated granulomatous dermatitis related to chronic eosinophilic leukemia following allogeneic stem cell transplantation. *Leuk Lymphoma*. 2017;58:470-472. [PMID: 27267816].
- Lozano-Masdemont B, Baniandrés-Rodríguez O, Parra-Blanco V, Suárez-Fernández R. Granulomatous Dermatitis as a Cutaneous Manifestation of Hematologic Disorders: The First Case Associated With Polycythemia Vera and a New Case Associated With Myelodysplasia. *Actas Dermo-Sifiliográficas (English Edition)*. 2016;107. [PMID: 26703820].



32. Yoneta K, Fujimoto N, Teramura K, Takayama S, Tanaka T. Disseminated granulomatous skin lesions associated with myelodysplastic syndrome treated successfully with tranilast: a case report and review of the literature. *Eur J Dermatol.* 2016;26:398-400. [PMID: 27229541].
33. Aung PP, Bowker B, Masterpol KS, Mahalingam M. Disseminated noninterstitial granulomatous dermatitis as a cutaneous manifestation of the preleukemic state in a patient with myelodysplasia and ulcerative colitis--apropos a case and review of the literature. *Am J Dermatopathol.* 2014;36:e117-e120. [PMID: 24950421].
34. Hagiwara A, Fujimura T, Furudate S, et al. Generalized granulomatous dermatitis accompanied by myelodysplastic syndrome. *Acta Derm Venereol.* 2014;94:223-224. [PMID: 23817627].
35. Balin SJ, Wetter DA, Kurtin PJ, et al. Myelodysplastic syndrome presenting as
36. generalized granulomatous dermatitis. *Arch Dermatol* 2011;147:331-5. [PMID: 21422341].
37. Anan T, Imamura T, Yokoyama S, Fujiwara S. Erythema nodosum and granulomatous lesions preceding acute myelomonocytic leukemia. *J Dermatol.* 2004;31:741-747. [PMID: 15628321].
38. Katz KA. Disseminated cutaneous granulomatous eruption occurring in the setting of myelodysplasia. *Dermatol Online J.* 2003;9:22. [PMID: 14594595].
39. Vestey JP, Turner M, Biddlestone L, et al. Disseminated cutaneous granulomatous eruptions associated with myelodysplastic syndrome and acute myeloid leukaemia. *Clin Exp Dermatol.* 1993;18:559-563. [PMID: 8252798].
40. Hartman R, Chu E, Acker S, et al. Cutaneous Metastases From Visceral Malignancies Mimicking Interstitial Granulomatous Processes. *Am J Dermatopathol.* 2013;35:601-605. [PMID: 237150821].

**Table 1.** Association of reactive granulomatous dermatitis, interstitial type and malignancy.

Author(s) year	Associated malignancy	Age	Gender	IGD morphology and distribution	Timing of IGD diagnosis relative to malignancy	Treatment	Outcome of IGD
Schreckenber 1998 [13]	Squamous cell carcinoma of the lung	62	M	Inflammatory plaque on proximal lower extremity	Simultaneous presentation and diagnosis of IGD and lung cancer	Surgical excision of primary tumor	Complete resolution 4 weeks after treatment
Busquets-Perez 2006 [10]	Breast cancer	44	F	Large indurated, erythematous plaques on lateral trunk and extremities	IGD diagnosed 2 years after breast cancer diagnosis and treatment	Systemic steroids	Complete resolution 18 weeks after treatment
Swing 2008 [11]	Acute promyelocytic leukemia	28	F	Symmetric erythematous, indurated plaques on hips and proximal lower extremity	Simultaneous presentation and diagnosis of IGD and APML	Multidrug regimen for leukemia, not specified	No response
Peroni 2012 [9]	Breast cancer	56	F	Symmetrical papules and plaques on upper and lower extremities	Not specified*	Systemic steroids	Partial resolution 4 weeks after treatment
Peroni 2012 [9]	Endometrial cancer	47	F	Symmetrical papules and plaques on upper extremities	Not specified*	Systemic steroids	Complete resolution 24 weeks after treatment
Peroni 2012 [9]	Squamous cell carcinoma of the hypopharynx	60	M	Symmetrical erythematous plaques on trunk and upper extremities	Not specified*	Systemic steroids Chemotherapy Radiation therapy	Complete resolution 4 weeks after treatment
Peroni 2012 [9]	IgA monoclonal gammopathy	69	F	Symmetrical erythematous plaques on trunk and upper extremities	Not specified*	None	Complete resolution 12 weeks after diagnosis of IGD
Peroni 2012 [9]	Hodgkin lymphoma	67	F	Diffuse erythematous macules	IGD diagnosed 1.8 years prior to diagnosis of Hodgkin lymphoma	None	Complete resolution 36 weeks after diagnosis of IGD

Almagro 2013 [37]	Esophageal cancer	67	M	Symmetrical erythematous, annular plaques on lateral trunk and upper extremities	IGD diagnosed 3 months prior to diagnosis of esophageal cancer	Systemic steroids Chemotherapy (cisplatin and 5-fluorouracil) Radiation therapy	IGD spread, tumor growth halted. Patient declined further treatment and expired 1 year after presentation
Cornejo 2013 [14]	Myelodysplastic syndrome	77	M	Diffuse erythematous macules and papules on extremities and trunk	IGD-like eruption diagnosed after MDS but prior to transformation to acute leukemia and leukemia cutis	Azacitidine	No response to initial treatment, and the patient expired
Pastinakidis 2014 [15]	Myelodysplastic syndrome	73	M	Symmetric erythematous annular, and urticarial plaques on trunk, proximal lower extremities, and upper extremities	IGD diagnosed prior to diagnosis of myelodysplastic syndrome	Chemotherapy (5-azacytidine)	Complete resolution 16 weeks after treatment
Choi 2014 [16]	Anaplastic large cell lymphoma	42	M	Erythematous to violaceous patches on the back and extremities	Simultaneous diagnosis of IGD and anaplastic large cell lymphoma	Chemotherapy (cyclophosphamide, doxorubicin, vincristine, and etoposide)	Complete resolution after treatment
Michailidou 2014 [17]	Diffuse large B-cell lymphoma	56	M	Symmetric, erythematous papule and plaques on the trunk	IGD presented prior to diagnosis of diffuse large B-cell lymphoma	Chemotherapy (R-CHOP)	Complete resolution after treatment
Thompson 2015 [18]	Multiple myeloma	50s	M	Symmetric, erythematous to violaceous patches and plaques on upper back, and upper extremities	IGD diagnosed prior to diagnosis of myeloma	Bisphosphonate	Complete resolution <sup>#</sup>
Riaz 2016 [12]	Chronic lymphocytic leukemia	66	F	Violaceous, annular plaque on proximal lower extremity and pink,	IGD diagnosed 6 years after diagnosis of chronic lymphocytic leukemia	Chemotherapy (bendamustine and rituximab)	Complete resolution 24 weeks after treatment

				subcutaneous plaques on the trunk and upper extremity.			
Kim 2017 [8]	Prostate cancer	86	M	Multiple irregular, erythematous to brown patches on back	IGD diagnosed after diagnosis of prostate cancer	Systemic Steroids Chemotherapy (Bicalutamide and Triptorelin Acetate)	"Marked improvement" 4 weeks after treatment
Cases-Merida 2018 [19]	Chronic myelo-proliferative disorder	56	M	Erythematous papules of neck, trunk, and extremities	Simultaneous presentation and diagnosis of IGD and cMPD	Imatinib	Complete resolution 8 weeks after treatment
Present Case	Ovarian carcinoma	66	F	Erythematous, indurated plaque on the trunk	IGD presented 8 months prior to diagnosis of ovarian carcinoma	Chemotherapy (carboplatin and paclitaxel)	Partial resolution following treatment

\*Peroni et al report presentation of IGD in "close temporal association with the diagnosis of neoplasia" without specifying if this preceded or followed cancer diagnosis.

#Length of treatment leading to resolution not listed.

APML, acute promyelocytic leukemia; cMPD, chronic myeloproliferative disorder; IGD, interstitial granulomatous dermatitis; R-CHOP, rituximab, cyclophosphamide, doxorubicin, vincristine, prednisone.



**Table 2.** Association of reactive granulomatous dermatitis, palisading neutrophilic type and malignancy.

Author(s) year	Associated malignancy	Age	Gender	Morphology and distribution	Timing of PNGD diagnosis relative to malignancy diagnosis	Treatment	Outcome
Zabihi-pour 2020 [20]	Monoclonal gammopathy of undetermined significance	84	M	Annular plaques on neck, back, and lower extremities	PNGD diagnosed 12 years after diagnosis of MGUS	Systemic steroids	Near complete resolution 3 weeks after treatment
Kohlmann 2019 [21]	CMML	58	M	Erythematous pruritic papules of trunk, extremities, and neck	Simultaneous presentation and diagnosis of CMML and PNGD	6 cycles of azacitidine Bone marrow transplantation	Complete resolution following the 5th cycle of azacitidine
Pei 2019 [22]	Hodgkin lymphoma	47	F	Symmetrical, erythematous papules and plaques on lower extremities and left hypothenar eminence	Simultaneous presentation and diagnosis of PNGD and Hodgkin lymphoma	Chemotherapy (not specified)	Not reported (patient undergoing treatment at time of publication)
Deen 2018 [23]	Hodgkin lymphoma	53	F	Erythematous papules of lower extremities, trunk, and hands	Simultaneous presentation and diagnosis of PNGD and Hodgkin lymphoma	Not reported	Not reported
Federmann 2017 [24]	CMML	68	M	Diffuse erythematous, linear arranged papule of trunk and extremities progressing to erythematous plaques of the extremities	PNGD diagnosed 5 years prior to the diagnosis of CMML	Not reported	Patient expired one month after diagnosis of CMML
Federmann 2017 [24]	CMML	66	F	Diffuse red to brown papules	Simultaneous presentation and diagnosis of CMML and PNGD	None	Partial response with relapse following systemic psoralen-UVA bath therapy
Federmann 2017 [24]	CMML	57	M	Diffuse red papules of trunk, sacrum, and extremities	Simultaneous presentation and diagnosis of CMML and PNGD	Methotrexate	Complete remission 7 years after treatment

Cajone 1993 [25]	Non-Hodgkin B-cell lymphoma	65	M	Symmetric ulcerated papules and nodules of extremities	Simultaneous presentation and diagnosis of non-Hodgkin B-cell lymphoma and PNGD	Systemic steroids Chlorambucil	Complete remission "within days" of treatment
Finan 1983 [26]	Lymphocytic lymphoma and monoclonal gammopathy	75	F	Symmetric tender, ulcerating nodules and papule of elbows and digits	PNGD presented four years prior to the diagnosis of lymphocytic lymphoma and monoclonal gammopathy	Chlorambucil	Not reported
Winkelman 1980 [22,27]	Multiple myeloma	47	F	Symmetric papules on buttock and extremities	PNGD presented prior to diagnosis of Multiple Myeloma	Mephalan Systemic steroids	Complete resolution 1 year after treatment
Winkelman 1980 [22,27]	Acute myelomonocytic leukemia	43	F	Urticarial and erythematous papules of extremities and back	PNGD presented prior to diagnosis of acute myelomonocytic leukemia	Not reported	Not reported

**Table 3.** Association of reactive granulomatous dermatitis, type not specified, and malignancy.

Author(s) year	Associated malignancy	Age	Gender	Morphology and distribution	Timing of GD diagnosis relative to malignancy diagnosis	Treatments impacting GD	Outcome
Tabata 2018 [28]	Hodgkin lymphoma	73	M	Erythematous, indurated plaque of left lower back	GD presentation and diagnosis after diagnosis and initiation of treatment of Hodgkin lymphoma	Topical and intralesional steroids	Partial resolution
Weed 2017 [29]	MDS	72	F	Tender, subcutaneous nodules and erythematous patches on the neck, extremities, and trunk Subcutaneous, linear cords on trunk and extremities	GD presented and diagnosed 5 years after the diagnosis of MDS	Systemic steroids	Partial resolution before the patient expired
Beauverd 2017 [30]	Chronic eosinophilic leukemia	53	F	Erythematous annular lesions on the head, trunk, and extremities	Simultaneous presentation and diagnosis of CEL and GD	Allogenic bone marrow transplant	Complete resolution following transplantation without recurrence 3 years after treatment
Lozano-Masdemont 2016 [31]	Polycythemia vera	72	F	Erythematous plaques on chest, back, and upper extremities	GD diagnosed 5 years after diagnosis of PV	Systemic steroids	Partial resolution†
Lozano-Masdemont 2016 [31]	MDS	74	M	Erythematous plaques on forehead,	GD diagnosed 1 year after the diagnosis of MDS	Systemic steroids Chemo-therapy (azacytidine)	Complete resolution 4 weeks after treatment
Yoneta 2016 [32]	MDS transforming to AML	80	M	Erythematous papule on neck	GD diagnosed "several years" after the diagnosis of MDS, but prior to transformation to AML	Tranilast	Partial resolution shortly after initiating treatment before the patient expired of AML
Aung 2014 [33]	MDS	68	F	Erythematous, indurated plaque on right upper extremity	GD diagnosed 11 months after diagnosis of MDS	Systemic steroids	Partial resolution prior to recurrence

							following treatment
Hagiwara 2014 [34]	MDS	65	M	Erythroderma with firm nodules on extremities and trunk	Simultaneous presentation and diagnosis of MDS and GD	Systemic steroids Nicotinic acid Doxycycline	No response of firm nodules Complete resolution of erythroderma
Balin 2011 [35]	MDS progressing to AML	71	M	Diffuse erythematous patches and coalescing papules on the trunk, upper, and lower extremities	GD diagnosed 2 years prior to diagnosis of MDS	Chemotherapy (lenalidomide)	Improvement 6 weeks after treatment
Anan 2004 [36]	Acute myelomonocytic leukemia	65	F	Erythematous, indurated patches on lower extremities and a tender, erythematous plaque on the trunk	GD diagnosed 5 months prior to diagnosis of acute myelomonocytic leukemia	Chemo-therapy (Enocitabine and dauunorubicin etoposide, mitoxantrone, and aclarubicin)	Complete resolution following treatment
Katz 2003 [37]	MDS	66	F	Erythematous nodules on head and neck	GD presented prior to diagnosis of MDS	Topical steroids	Partial resolution following treatment
Vestey 1993 [38]	MDS transforming to AML	66	M	Diffuse annular papule of the trunk and extremities	GD (atypical GA) presented and diagnosed prior to diagnosis of MDS and AML	Chemotherapy (doxorubicin, cytosine arabinoside, thioguanine)	Complete remission 4 weeks following treatment
Vestey 1993 [38]	MDS	71	M	Pearly papules of trunk and extremities	GD (sarcoid like reaction) presented prior to diagnosis of MDS	Not reported	Not reported

AML, acute myelocytic leukemia; GD, granulomatous dermatitis; MDS, myelodysplastic syndrome.