

3-31-2023

Anatomy Versus Physiology: Is Breast Lymphatic Drainage to the Internal Thoracic (Internal Mammary) Lymphatic System Clinically Relevant?

Priscilla Machado
Thomas Jefferson University

Ji-Bin Liu
Thomas Jefferson University

Laurence Needleman
Thomas Jefferson University

Christine Lee

Flemming Forsberg
Thomas Jefferson University
Follow this and additional works at: <https://jdc.jefferson.edu/radiologyfp>

 Part of the [Oncology Commons](#), and the [Radiology Commons](#)

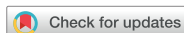[Let us know how access to this document benefits you](#)

Recommended Citation

Machado, Priscilla; Liu, Ji-Bin; Needleman, Laurence; Lee, Christine; and Forsberg, Flemming, "Anatomy Versus Physiology: Is Breast Lymphatic Drainage to the Internal Thoracic (Internal Mammary) Lymphatic System Clinically Relevant?" (2023). *Department of Radiology Faculty Papers*. Paper 154.
<https://jdc.jefferson.edu/radiologyfp/154>

This Article is brought to you for free and open access by the Jefferson Digital Commons. The Jefferson Digital Commons is a service of Thomas Jefferson University's [Center for Teaching and Learning \(CTL\)](#). The Commons is a showcase for Jefferson books and journals, peer-reviewed scholarly publications, unique historical collections from the University archives, and teaching tools. The Jefferson Digital Commons allows researchers and interested readers anywhere in the world to learn about and keep up to date with Jefferson scholarship. This article has been accepted for inclusion in Department of Radiology Faculty Papers by an authorized administrator of the Jefferson Digital Commons. For more information, please contact: JeffersonDigitalCommons@jefferson.edu.

Brief Communication



OPEN ACCESS

Received: Dec 8, 2022

Revised: Feb 21, 2023

Accepted: Mar 18, 2023

Published online: Mar 31, 2023

Correspondence to

Priscilla Machado


Department of Radiology, 7 Main, Suite 763M,
Thomas Jefferson University, 132 South 10th
Street, Philadelphia 19107, USA
Email: priscilla.machado@jefferson.edu


© 2023 Korean Breast Cancer Society


This is an Open Access article distributed under the terms of the Creative Commons Attribution Non-Commercial License (<https://creativecommons.org/licenses/by-nc/4.0/>) which permits unrestricted non-commercial use, distribution, and reproduction in any medium, provided the original work is properly cited.


ORCID iDs

Priscilla Machado 
<https://orcid.org/0000-0003-4107-2986>

Ji-Bin Liu 
<https://orcid.org/0000-0003-2979-9162>

Laurence Needleman 
<https://orcid.org/0000-0003-1683-4547>

Christine Lee 
<https://orcid.org/0000-0001-5298-6949>

Flemming Forsberg 
<https://orcid.org/0000-0003-2215-1371>

Funding

This work was supported by NIH grant R01 CA172336.

Conflict of interest

The authors declare that they have no competing interests.

<https://ejbc.kr>

Anatomy Versus Physiology: Is Breast Lymphatic Drainage to the Internal Thoracic (Internal Mammary) Lymphatic System Clinically Relevant?

Priscilla Machado ¹, **Ji-Bin Liu** ¹, **Laurence Needleman** ¹, **Christine Lee** ²,
Flemming Forsberg ¹

¹Department of Radiology, Thomas Jefferson University, Philadelphia, USA

²Department of Radiology, Mayo Clinic, Rochester, USA

ABSTRACT

Approximately 15%–25% of breast lymphatic drainage passes through the internal thoracic (internal mammary) lymphatic system, draining the inner quadrants of the breast. This study aimed to use lymphosonography to identify sentinel lymph nodes (SLNs) in the axillary and internal thoracic lymphatic systems in patients with breast cancer. Seventy-nine patients received subcutaneous ultrasound contrast agent injections around the tumor. Lymphosonography was used to identify SLNs. In 14 of the 79 patients (17.7%), the tumor was located in the inner quadrant of the breast. Lymphosonography identified 217 SLNs in 79 patients, averaging 2.7 SLNs per patient. The 217 identified SLNs in the 79 patients were located in the axillary lymphatic system; none were located in the internal thoracic (internal mammary) lymphatic system, although it was expected in two to four patients (i.e., 4–11 SLNs). These results implied that SLNs associated with breast cancer are predominantly located in the axillary lymphatic system.

Keywords: Breast Neoplasms; Contrast Media; Lymph Nodes; Lymphatic System; Ultrasonography

INTRODUCTION

Our group designed a study to use ultrasound (US) imaging to identify sentinel lymph nodes (SLNs) in patients with breast cancer who undergo surgical excision. The objective of this study was to compare standard of care methods for lymphatic mapping (i.e., blue dye and/or radioactive tracer) with lymphosonography, which uses contrast-enhanced US (CEUS) to track US contrast agents (UCAs) injected subcutaneously around the tumor area for lymphatic mapping.

The UCA used in this study was Sonazoid (GE Healthcare, Oslo, Norway), a reticuloendothelial-specific agent, which means that the UCA is captured by macrophages and stays in the SLNs, not moving forward to secondary and tertiary lymph nodes (LNs) [1-3]. This characteristic provides an important advantage for the lymphatic mapping and identification of SLN [1].

Author Contributions

Conceptualization: Machado P, Forsberg F;
Data curation: Machado P; Formal analysis:
Machado P, Forsberg F; Investigation:
Machado P, Liu JB, Needleman L, Forsberg F;
Methodology: Machado P, Liu JB, Needleman
L, Forsberg F; Writing - original draft: Machado
P, Liu JB, Needleman L, Lee C, Forsberg F;
Writing - review & editing: Machado P, Liu JB,
Needleman L, Lee C, Forsberg F.

METHODS

During the development of the study methodology, there were several discussions between the research team and clinical team to determine the most ethical way to address the clinical approach in the case of the research modality (i.e., lymphosonography) finding more and/or different SLNs than the standard of care, which was one of the objectives of our study. The final decision was that if lymphosonography revealed different SLNs located in the axillary region close to the standard axillary surgical excision, the clinical team would also extract those SLNs. There was also agreement that any SLNs found by lymphosonography located in the internal thoracic (internal mammary) lymphatic system would be observed and the findings were communicated to the clinical team, who would then determine the expansion of the radiation field to include the locations where the internal thoracic lymphatic system was located. Based on the literature, it was expected that 15%–25% of patients with tumors located in the inner quadrants of the breast were expected to have draining SLNs located in the internal thoracic (internal mammary) lymphatic system [4-8]. This study was approved by the IRB and FDA (NCT:02652923; IND:127,419). The 79 patients underwent US examination of the axillary lymphatic system and the internal thoracic lymphatic system to locate all SLNs, even for patients with tumors located in the outer quadrants of the breast. Of the 79 patients enrolled, 14 patients (17.7%) had tumors in the inner quadrant of the breast. Surprisingly, none of the patients had SLNs in the internal thoracic (internal mammary) lymphatic system.

This observation creates an interesting conundrum, in which there appears to be a difference between anatomical and physiological expectations of lymphatic drainage in the breast.

Breast lymphatic system

The SLN concept theorizes that in tumors with regional lymphatic metastatic potential, metastatic cells will spread through the lymphatic system, with the SLN, the first LN in the lymphatic chain (LC), being the first to receive metastatic cells [9-13]. Therefore, if the SLN contains metastatic cells, the remaining LNs are considered potentially positive for metastatic disease; the same is true for benign SLNs and the remaining LNs [9,11,12]. Determining regional LN involvement is used to guide treatment selection and remains the most powerful predictor of recurrence and survival in breast cancer patients [1,14-19].

The lymphatic drainage of the breast moves 75%–85% of the drainage through the axillary LNs, with an average of 20–30 LNs in the axillary region [4-7]. The axillary LNs are divided for surgical purposes into six groups: axillary vein, external mammary, scapular, central, infraclavicular, and interpectoral (Rotter nodes) groups, in which the groups are named according to their relationship to the pectoralis minor muscle [6]. The remaining 15%–25% of the breast lymphatic drainage passes through the lymphatic system along the perforating branches of the internal mammary artery and enters the parasternal group (internal thoracic [internal mammary] LNs), draining the inner quadrants of the breast [6]. The internal thoracic (internal mammary) LNs are usually small, approximately 3.0 mm, with 3–5 LNs found on either side of the sternum. These LNs drain not only the inner quadrants of the breast but also the anterior chest wall, anterior portion of the diaphragm, upper portion of the rectus sheath and muscle, and superior portion of the liver [4]. Based on the lymphatic drainage system described above, the internal thoracic (internal mammary) system is expected to be part of the lymphatic system to drain the inner quadrants of the breast. However, this was not the case in the present clinical study.

RESULTS

Pre-clinical studies of the lymphosonography technique performed by our group using a Sinclair swine model with naturally occurring melanoma tumors showed that the UCAs used as lymphatic tracers in lymphosonography remain restricted to SLNs that do not progress in the lymphatic system to secondary and tertiary LNs [2,3,20,21]. The study from which the data discussed here were acquired represents the translation of our group into a clinical trial evaluating lymphosonography in patients with breast cancer scheduled to undergo surgical excision [22,23]. Subcutaneous UCA injection was performed around the tumor area to precisely identify the lymphatic system that drains the tumor.

A total of 86 patients scheduled for breast cancer surgery with SLN excision were enrolled, and 79 completed this study between March 2017 and January 2022. Written informed consent was obtained from all enrolled patients. Among the 79 patients, 47 patients had tumors located in the right breast (59.5%), and 32 had tumors located in the left breast (40.5%). The mean tumor size at the time of diagnosis was 1.8 cm (range, 0.3–9.7 cm). Most of the patients had tumors located in the upper outer quadrant (n = 57; 72.2%), 8 had tumors located in the lower outer quadrant (10.1%), 12 had tumors located in the upper inner quadrant (15.2%), and 2 had tumors located in the lower inner quadrant (2.5%). Therefore, in 65 of the 79 patients (82.3%), the tumor was located in the outer quadrant of the breast, and in 14 of the 79 patients (17.7%), the tumor was located in the inner quadrant of the breast. Therefore, for the 14 patients with tumors located in the inner quadrants of the breast, we expected that 2–4 patients would have SLNs in the internal thoracic (internal mammary) lymphatic system. The demographics, tumor location, and tumor type of the patients are summarized in **Table 1**.

Table 1. Demographics, tumor location, and tumor type of the patients

Subjects	Values (n = 79)
Sex	
Female	79 (100)
Age (yr), mean (range)	61 (27–84)
Side	
Right	47 (59.5)
Left	32 (40.5)
Location	
Upper outer quadrant	57 (72.2)
Lower outer quadrant	8 (10.1)
Upper inner quadrant	12 (15.2)
Lower inner quadrant	2 (2.5)
Tumor size (cm), mean (range)	1.8 (0.3–9.7)
Tumor type	
Invasive ductal carcinoma	62 (78.5)
Ductal carcinoma in situ	5 (6.3)
Invasive lobular carcinoma	11 (13.9)
Papillary carcinoma	1 (1.3)
Stage: tumor (T)	
T1	67 (84.9)
T2	8 (10.1)
T3	2 (2.5)
T4	2 (2.5)
Stage: node (N)	
N0	61 (77.3)
N1	14 (17.7)
N2	2 (2.5)
N3	2 (2.5)

Values are presented as number (%) unless otherwise indicated.

The US examination consisted of the B-mode of the tumor to determine its location and size. Subsequently, UCA Sonazoid (GE Healthcare), a reticuloendothelial-specific agent (1-3), was injected subcutaneously around the tumor area at the 12, 3, 6, and 9 o'clock positions (0.25 mL per position for a total of 1 mL). After injections, the site was massaged for 5 min to accelerate the uptake of UCA into the lymphatic system. CEUS was then performed (i.e., lymphosonography) to identify the number, location, and course of the LCs and SLNs using Cadence Pulse Sequencing (CPS; Siemens Healthineers, Mountain View, USA) on an S3000 HELX scanner (Siemens Healthineers) with a high-frequency, broad-bandwidth (4–9 MHz) linear array probe (9L4). Imaging parameters, i.e., focal zone, scanning depth, and time-gain compensation, were adjusted individually to optimize the visualization of the target region (SLN or LC). No compounding or other image-processing techniques were applied. Sagittal and transverse still images and digital clips were acquired during the US examination. A radiologist (PM) with more than 12 years of experience in CEUS performed the US examinations.

Lymphosonography identified 217 SLNs in 79 patients, averaging 2.7 SLNs per patient. The location and size measurements of all identified SLNs were recorded, and US images were acquired for all SLNs. **Figure 1** shows an example of dual-image CEUS and B-mode of an SLN. The 217 SLNs identified in the 79 patients were located in the axillary lymphatic system; none of the SLNs identified in this study were in the internal thoracic (internal mammary) lymphatic system.

The focus of the study was on the identification of SLNs that were connected with the tumor area, and the detection of microbubbles in any type of CEUS enhancement inside the SLN was used to determine it as an SLN connected with the tumor area without attempting to characterize the SLN morphology using CEUS enhancement patterns.

The main limitation of this study is the small number of patients with tumors located in the inner quadrants of the breast (14/79) and that the excision of LNs located in the internal thoracic (internal mammary) lymphatic system is not part of the standard of care, with the use of an extended radiotherapy window being the current treatment when there is suspicious LN involvement of the internal thoracic (internal mammary) lymphatic system.

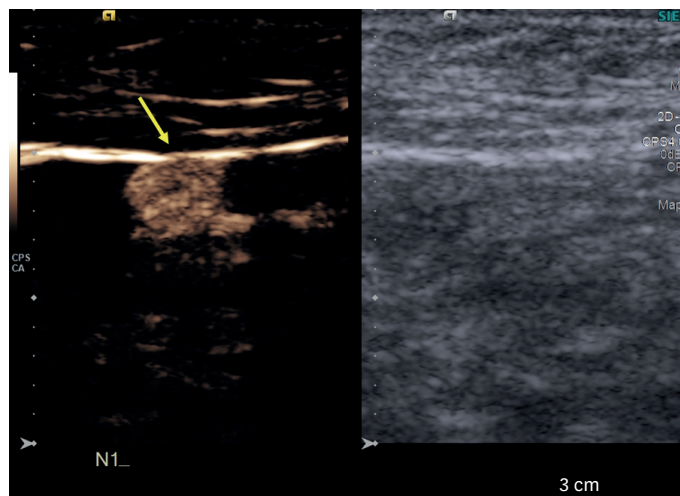


Figure 1. Example of a study case. The patient is a 53-year-old female diagnosed with an invasive lobular carcinoma located in the right breast at the 12 o'clock position, measuring 1.2 cm. Dual-image contrast-enhanced ultrasound and B-mode of the sentinel lymph node (arrow).

The results of this study indicated that SLNs associated with breast cancer are located in the axillary lymphatic system. This suggests that LNs in the internal thoracic (internal mammary) lymphatic system are part of the secondary and tertiary lymphatic systems.

DISCUSSION

Although the literature [4-8] states that patients with tumors located in the inner quadrants of the breast would have SLNs located in the internal thoracic (internal mammary) lymphatic system, our study using lymphosonography to identify SLNs showed that none of the SLNs were located in the internal thoracic (internal mammary) lymphatic system. These results suggest that the internal thoracic (internal mammary) lymphatic system may not be a primary lymphatic drainage system, especially since the UCA properties of being a reticuloendothelial-specific agent, meaning that the UCA is captured by macrophages and stays in the SLNs not moving forward to secondary and tertiary LNs, which appears to be the case with the internal thoracic (internal mammary) lymphatic system. This may have important clinical implications regarding the importance of the internal thoracic (internal mammary) lymphatic system in the breast lymphatic drainage system pathway. Multicenter studies with large sample sizes, including large numbers of inner breast cancers, are required to confirm these findings.

ACKNOWLEDGMENTS

Sonazoid was supplied by GE Healthcare, Oslo, Norway. The S3000 HELX scanner was provided by Siemens Healthineers, Mountain View, CA, USA.

REFERENCES

1. Machado P, Stanczak M, Liu JB, Moore JN, Eisenbrey JR, Needleman L, et al. Subdermal ultrasound contrast agent injection for sentinel lymph node identification: an analysis of safety and contrast agent dose in healthy volunteers. *J Ultrasound Med* 2018;37:1611-20.
[PUBMED](#) | [CROSSREF](#)
2. Goldberg BB, Merton DA, Liu JB, Murphy G, Forsberg F. Contrast-enhanced sonographic imaging of lymphatic channels and sentinel lymph nodes. *J Ultrasound Med* 2005;24:953-65.
[PUBMED](#) | [CROSSREF](#)
3. Goldberg BB, Merton DA, Liu JB, Forsberg F, Zhang K, Thakur M, et al. Contrast-enhanced ultrasound imaging of sentinel lymph nodes after peritumoral administration of Sonazoid in a melanoma tumor animal model. *J Ultrasound Med* 2011;30:441-53.
[PUBMED](#) | [CROSSREF](#)
4. Ellis H, Mahadevan V. Anatomy and physiology of the breast. *Surgery* 2013;31:11-4.
[CROSSREF](#)
5. Jesinger RA. Breast anatomy for the interventionalist. *Tech Vasc Interv Radiol* 2014;17:3-9.
[PUBMED](#) | [CROSSREF](#)
6. Pandya S, Moore RG. Breast development and anatomy. *Clin Obstet Gynecol* 2011;54:91-5.
[PUBMED](#) | [CROSSREF](#)
7. Bistoni G, Farhadi J. Anatomy and physiology of the breast. *Plastic and Reconstructive Surgery: Approaches and Techniques*. 2015;31:477-85.
[CROSSREF](#)
8. Dogan BE, Dryden MJ, Wei W, Fornage BD, Buchholz TA, Smith B, et al. Sonography and sonographically guided needle biopsy of internal mammary nodes in staging of patients with breast cancer. *AJR Am J Roentgenol* 2015;205:905-11.
[PUBMED](#) | [CROSSREF](#)

9. Wisner ER, Bloch SH. Use of ultrasound bubbles in lymph node imaging. In: Bulte JW, Modo MM, editors. *Nanoparticles in Biomedical Imaging*. New York: Springer; 2008. p.289-310.
10. Boughey JC, Suman VJ, Mittendorf EA, Ahrendt GM, Wilke LG, Taback B, et al. Factors affecting sentinel lymph node identification rate after neoadjuvant chemotherapy for breast cancer patients enrolled in ACOSOG Z1071 (Alliance). *Ann Surg* 2015;261:547-52.
[PUBMED](#) | [CROSSREF](#)
11. Emerson DK, Limmer KK, Hall DJ, Han SH, Eckelman WC, Kane CJ, et al. A receptor-targeted fluorescent radiopharmaceutical for multireporter sentinel lymph node imaging. *Radiology* 2012;265:186-93.
[PUBMED](#) | [CROSSREF](#)
12. Tokin CA, Cope FO, Metz WL, Blue MS, Potter BM, Abbruzzese BC, et al. The efficacy of Tilmanocept in sentinel lymph node mapping and identification in breast cancer patients: a comparative review and meta-analysis of the ^{99m}Tc-labeled nanocolloid human serum albumin standard of care. *Clin Exp Metastasis* 2012;29:681-6.
[PUBMED](#) | [CROSSREF](#)
13. Tan VK, Goh BK, Fook-Chong S, Khin LW, Wong WK, Yong WS. The feasibility and accuracy of sentinel lymph node biopsy in clinically node-negative patients after neoadjuvant chemotherapy for breast cancer—a systematic review and meta-analysis. *J Surg Oncol* 2011;104:97-103.
[PUBMED](#) | [CROSSREF](#)
14. Kim T, Giuliano AE, Lyman GH. Lymphatic mapping and sentinel lymph node biopsy in early-stage breast carcinoma: a metaanalysis. *Cancer* 2006;106:4-16.
[PUBMED](#) | [CROSSREF](#)
15. Nielsen Moody A, Bull J, Culpan AM, Munyombwe T, Sharma N, Whitaker M, et al. Preoperative sentinel lymph node identification, biopsy and localisation using contrast enhanced ultrasound (CEUS) in patients with breast cancer: a systematic review and meta-analysis. *Clin Radiol* 2017;72:959-71.
[PUBMED](#) | [CROSSREF](#)
16. Shimazu K, Miyake T, Tanei T, Naoi Y, Shimoda M, Kagara N, et al. Real-time visualization of lymphatic flow to sentinel lymph nodes by contrast-enhanced ultrasonography with sonazoid in patients with breast cancer. *Ultrasound Med Biol* 2019;45:2634-40.
[PUBMED](#) | [CROSSREF](#)
17. Liu YB, Xia M, Li YJ, Li S, Li H, Li YL. Contrast-enhanced ultrasound in locating axillary sentinel lymph nodes in patients with breast cancer: a prospective study. *Ultrasound Med Biol* 2021;47:1475-83.
[PUBMED](#) | [CROSSREF](#)
18. Deng H, Lei J, Jin L, Shi H. Diagnostic efficacy of sentinel lymph node in breast cancer under percutaneous contrast-enhanced ultrasound: an updated meta-analysis. *Thorac Cancer* 2021;12:2849-56.
[PUBMED](#) | [CROSSREF](#)
19. Lyman GH, Giuliano AE, Somerfield MR, Benson AB 3rd, Bodurka DC, Burstein HJ, et al. American Society of Clinical Oncology guideline recommendations for sentinel lymph node biopsy in early-stage breast cancer. *J Clin Oncol* 2005;23:7703-20.
[PUBMED](#) | [CROSSREF](#)
20. Goldberg BB, Merton DA, Liu JB, Thakur M, Murphy GF, Needleman L, et al. Sentinel lymph nodes in a swine model with melanoma: contrast-enhanced lymphatic US. *Radiology* 2004;230:727-34.
[PUBMED](#) | [CROSSREF](#)
21. Liu JB, Merton DA, Berger AC, Forsberg F, Witkiewicz A, Zhao H, et al. Contrast-enhanced sonography for detection of secondary lymph nodes in a melanoma tumor animal model. *J Ultrasound Med* 2014;33:939-47.
[PUBMED](#) | [CROSSREF](#)
22. Machado P, Liu JB, Needleman L, Lazar M, Willis AI, Brill K, et al. Sentinel lymph node identification in patients with breast cancer using lymphosonography. *Ultrasound Med Biol* 2023;49:616-25.
[PUBMED](#) | [CROSSREF](#)
23. Machado P, Liu JB, Needleman L, Lazar M, Willis AI, Brill K, et al. Sentinel lymph node identification in post neoadjuvant chemotherapy breast cancer patients undergoing surgical excision using lymphosonography. *J Ultrasound Med*. Epub 2023 Jan 2. <https://doi.org/10.1002/jum.16164>.
[PUBMED](#) | [CROSSREF](#)