

2-8-2013

Management of upper aerodigestive tract bleeding on extracorporeal membrane oxygenation.

Hitoshi Hirose, MD, PhD

Thomas Jefferson University, Hitoshi.Hirose@Jefferson.edu

[Let us know how access to this document benefits you](#)

Follow this and additional works at: <https://jdc.jefferson.edu/surgeryfp>Part of the [Surgery Commons](#)

Recommended Citation

Harrison MA, Baker AL, Roy S, Hirose H, Cavarocchi NC. Management of upper aerodigestive tract bleeding on extracorporeal membrane oxygenation. *Mechanical Circulatory Support* 2013;4:20333.

This Article is brought to you for free and open access by the Jefferson Digital Commons. The Jefferson Digital Commons is a service of Thomas Jefferson University's [Center for Teaching and Learning \(CTL\)](#). The Commons is a showcase for Jefferson books and journals, peer-reviewed scholarly publications, unique historical collections from the University archives, and teaching tools. The Jefferson Digital Commons allows researchers and interested readers anywhere in the world to learn about and keep up to date with Jefferson scholarship. This article has been accepted for inclusion in Department of Surgery Faculty Papers by an authorized administrator of the Jefferson Digital Commons. For more information, please contact: JeffersonDigitalCommons@jefferson.edu.

Management of upper aerodigestive tract bleeding on extracorporeal membrane oxygenation

Meredith A. Harrison¹, Adam L. Baker², Sudeep Roy²,
Hitoshi Hirose^{1*} and Nicholas C. Cavarocchi¹

¹Department of Surgery, Thomas Jefferson University, Philadelphia, PA, USA; ²Department of Otolaryngology, Thomas Jefferson University, Philadelphia, PA, USA

Received: 24 December 2012; Revised: 11 January 2013; Accepted: 17 January 2013; Published: 8 February 2013

Abstract

Introduction: Bleeding complications are often encountered on extracorporeal membrane oxygenation (ECMO). In a review of our own series, it was found that upper aerodigestive tract bleeding was common and that its management was often difficult. We propose an algorithm to help manage upper aerodigestive tract bleeding in the anticoagulated, ECMO patient.

Methods: A retrospective chart review was performed of the patients who underwent veno-venous or veno-arterial ECMO at our institution between July 2010 and July 2012. The patients that had upper aerodigestive tract bleeding that required an otolaryngology consultation were identified. They were further investigated to determine the location of bleed, and procedures were performed to control the bleeding.

Results: Among the 37 consecutive patients on ECMO, 11 (30%) had upper aerodigestive tract bleeding events. Of these 11, 7 (63.6%) were secondary to an iatrogenic incident, such as placing a nasogastric tube or transesophageal echo probe. All 11 patients were treated at bedside with conservative management and 3 were treated in the operating room. Four patients (36%) treated with conservative management required repeated procedures due to incomplete hemostasis, compared to no repeated procedure required once surgical intervention in the operating room was complete.

Conclusion: Approximately one-third of the ECMO patients developed upper aerodigestive tract bleeding. This bleeding should be controlled in a timely manner; otherwise it may result in massive transfusions. Delaying intervention or conservative management may not be effective. We recommend surgical intervention, if the initial conservative management failed and continued to bleed for more than 24–36 hours.

Keywords: ECMO; upper aerodigestive tract; bleeding; anticoagulation; management

Introduction

Bleeding complications on extracorporeal membrane oxygenation (ECMO) are often encountered and can be a difficult problem to handle since ECMO patients need to remain on anticoagulation to prevent the circuit from forming clots. One particular complication, frequently encountered at many centers, is upper aerodigestive tract bleeding, especially after manipulation or instrumentation. Presently there is not a standardized algorithm for management of this bleeding, which could affect the results for these patients, allowing for continued anticoagulation, decreased number of transfusions, and easier wean from ECMO. Here, we present a case report to illustrate the review of our series of upper aerodigestive bleeding in the ECMO patient and

attempt to develop a management algorithm to better treat the bleeding, anticoagulated ECMO patient.

Case report

A 66-year-old female was placed on veno-arterial ECMO (VA ECMO) for profound cardiogenic shock. On ECMO day 6, a bedside transesophageal echocardiography (TEE) probe was placed to evaluate heart function. Oropharyngeal and nasopharyngeal bleeding were noted immediately after the procedure. Packing of gauze into the nares did not stop bleeding. Twenty-six hours later, otolaryngology was consulted. The patient's nares were sprayed with oxymetolazone and were packed with Merocel (Beaver-Visitec International, Inc. Waltham, MA). The patient continued to bleed, her hemoglobin

count continued to drop, and she required multiple transfusions (Fig. 1). Otolaryngology (ear nose and throat, ENT service) continued to attempt conservative management, but the patient continued to bleed. At this time, the patient's partial thromboplastin time (PTT, normal range 25–35 seconds) was always in the range of 37 to 53 sec and there was no bleeding from any other source. Because the patient's oropharyngeal space was still welling with blood even after oropharyngeal packing, a decision was made to take the patient to the operating room. By the time this decision was made, the patient had received 32 units of packed red blood cells (PRBCs), 50 units of platelets, and 2 units of fresh frozen plasma. The otolaryngology team had seen the patient over 10 separate times prior to surgical intervention. The patient was unable to wean from ECMO because of uncertainty of airway protection secondary to oropharyngeal bleed. In the operating room, the patient was found to have a laceration to her adenoid pad close to the midline, which never would have been visualized at the bedside. The bleeding vessel was cauterized using a Bovie. The patient was successfully weaned from ECMO the following day and required no further blood transfusions after this point.

Methods

A retrospective chart review was performed for patients who underwent veno-arterial (VA) or veno-venous (VV) (veno-venous) ECMO in our institution from July 2010 to July 2011. Incidence of upper aerodigestive tract bleeding that required an otolaryngology consultation was recorded. All notes from the otolaryngology service were reviewed to determine location of bleed, chronological time line after instrumentation, and procedures performed to stop the bleeding. This study was approved by the local internal review board.

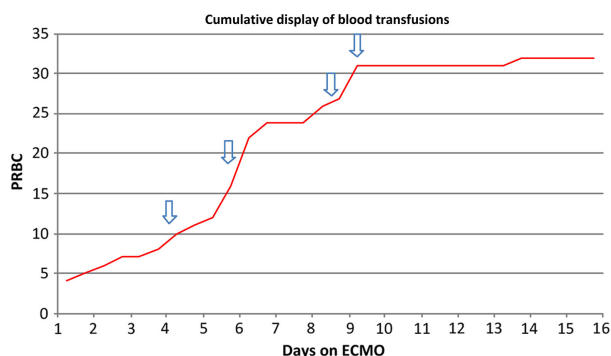


Fig. 1. Cumulative transfusion of packed red cell given for the presented case. Arrows demonstrate each otolaryngology intervention. The last arrow indicates the definitive surgical intervention in the operating room. PRBC: packed red blood cell.

Results

Our institution had 37 consecutive patients on ECMO from July 2010 to July 2012, of which 11 patients (30%) had upper aerodigestive tract bleeding events (Table 1). Among these 11 patients, 7 (63.6%) were secondary to an iatrogenic incident, such as placing a nasogastric tube, feeding tube, or transesophageal echo probe. Of the 11 patients, Seven (64%) were from the nose or nasopharynx, 4 were from the oropharynx (36%) and none from the trachea. All of the upper aerodigestive bleeding occurred within 12 hours of instrumentation and otolaryngology consultation was obtained within 12–18 hours. All patients were anticoagulated with intravenous heparin at the time of the upper aerodigestive tract bleeding, with an averaged PTT of 45 sec (range 28–72). Anticoagulation was initially held for 12 or 24 hours or lowered (subsequent bleed) during the upper aerodigestive tract bleeding. All patients underwent bedside ENT procedures, including oxymetolazone spray in 11 (100%) and Merocel packing in eight (73%). Repeated bleeding after initial otolaryngology procedure was observed in four patients (36%). Operative procedure was done in three patients (27%) and none of them re-bleed.

Discussion

We found that upper aerodigestive tract bleeding in ECMO patients is not uncommon. Lowering or holding anticoagulation did not solve the upper aerodigestive tract bleeding according to our findings. Thus, an algorithm should be made to follow when upper aerodigestive tract bleeding complications occur. In consultation with our otolaryngology department, management of these bleeds was often complicated by persistent bleeding. In the case presented, it is clear that conservative management was not enough to control the bleeding. The lesion was not visible until an operative intervention was performed.

It is often difficult to take ECMO patients to the operating room because of the hemodynamic monitoring and safety during the transportation. We developed an algorithm to assist in this upper aerodigestive tract bleeding management. If a patient develops upper aerodigestive tract bleeding, anticoagulation profiles should be reduced to 1.3–1.4 times the PTT, limited interventions should be performed, suctioning should be done with softer red rubber catheters rather than traditional nasotracheal suctioning devices, and conservative management should be initiated, including oxymetolazone and direct pressure via packing, and the otolaryngology service should be consulted. If conservative management fails to control the bleeding, nasopharyngolaryngoscopy should be done to locate the site of the bleed. A different procedure can be performed depending on the location of the bleed as shown below, as interpreted by Gifford and Orlandi (1) and Barnes, Spielmann and White (2).

Table 1. Bleeding/transfusion data associated with ENT evaluations

Patients	ENT evaluations/patient	Days until bleeding stopped	Transfusion totals
1	6	5 (once decannulated)	5 PRBCs; 2 FFP; 2 platelets
2	4	3	4 PRBCs; 1 platelets
3	12	Never stopped until LVAD placement	1 PRBC
4	6	7	1 PRBC; 2 platelets
5	2	1	None
6	1	1	None
7	1st consultation: 12 2nd consultation: 2	13 2	8 PRBCs; 8 platelets 3 cryoprecipitate
8	1	Expired	None
9	6	6	2 PRBCs
10	1st consultation: 2 2nd consultation: 3	1 2	2 PRBCs
11 (presented)	10	9	32 PRBCs; 2 FFP; 50 platelets

FFP: fresh frozen plasma, LVAD: left ventricular assist device, PRBC: pure red blood cell.

Nares

According to our data, we found that most patients had posterior nasopharyngeal sources for bleeding. Posterior bleeding is often challenging to identify, but it can be treated with packing. Bilateral bacitracin-coated polycellulose packs, which are placed between the inferior turbinate, septum, and posteriorly abutting the nasopharynx, will tamponade anterior, posterior, and nasopharyngeal sources of epistaxis. Packs should be changed within 72 hours to prevent the colonization of harmful bacteria. The patient should be placed on an antibiotic to cover streptococcus to prevent toxic shock syndrome. If bleeding persists, or begins to present as an oropharyngeal bleed, further packing may be placed. If bleeding continues to persist after 2–3 packs, further investigation with nasal endoscopy may be warranted. Occasionally, severe oropharyngeal hemorrhage may cause epistaxis, although seldom without hemorrhage from the mouth.

Mouth

It is not unusual for posterior nasal cavity or nasopharyngeal bleeding to present from the mouth without epistaxis. Thus, all oral bleeding must be approached by ruling out nasopharyngeal bleeding. The nasal passage is often used as a conduit for feeding, ventilation, and esophageal probes. We found that an uninstrumented spontaneous oropharyngeal bleed is less likely than an instrumented nasopharyngeal bleed presenting as oral hemorrhage. Thus, it is reasonable to pack a nose which has recently been instrumented even if there is only evidence of bleeding from the mouth. However, if bleeding from the mouth persists, or if oropharyngeal bleeding is highly suspicious, an oxymetolazone-saturated throat pack may be placed. This can be typically achieved with a paralyzed and sedated patient, using 1–2 Kling wraps

tied end-to-end, firmly packed in the direction toward the hypopharynx. Again, packs should be changed within 72 hours, and appropriate prophylactic antibiotic therapy should be initiated.

Endotracheal tube or trachea

Frequently, upper aerodigestive tract bleeding will present alone with secretions from either the endotracheal tube or in conjunction with nasal or oral hemorrhage. If occurring alone and suspicion for hemoptysis is low, evaluation with nasopharyngolaryngoscopy is warranted to identify the source of bleeding. Occasionally, injury to subsites within the hypopharynx, such as the piriform sinus, can occur with nasogastric tubes, and may solely present in this manner. Excessive hemorrhage from an upper aerodigestive source may present as bloody leakage around the cuff.

After thorough examination and conservative management, if bleeding persists, surgical intervention should be performed. The operating room allows for a controlled environment in which a thorough exam and appropriate interventions can be performed. Cauterization or ligation of a bleeding vessel may be necessary. Taking the patient to the operating room, sooner rather than later, can decrease the amount of transfusion and upper aerodigestive tract-specific bleeding-related morbidity, such as aspiration pneumonia. Increased transfusion requirements, increased sedation requirements, and decreased anticoagulation profiles can all be detrimental in the ECMO patient.

Conclusions

In the ECMO patient, the incidence of upper aerodigestive tract bleeding was as high as 30%. With such a high incidence, it is important to have an algorithm to follow to

treat these patients in a timely fashion. Delaying intervention with conservative management that is not successful can prove detrimental. Conservative management outlined in this article should be done by experienced personnel as a first line approach. However, if bleeding continues for more than 24–36 hours and the patient demonstrates continued blood transfusion requirements, surgical intervention may be necessary. Every patient should be approached on a case-by-case basis, but delaying repair of a laceration or cauterization of a bleeding vessel can increase morbidity in this patient population. Taking a patient to the operating room for a thorough evaluation and treatment should not be delayed.

Conflict of interest and funding

There is no conflict of interest in the present study for any of the authors.

References

1. Gifford TO, Orlandi RR. Epistaxis. *Otolaryngol Clin North Am* 2008; 41: 525–36.
 2. Barnes ML, Spielmann PM, White PS. Epistaxis: A contemporary evidence based approach. *Otolaryngol Clin North Am* 2012; 45: 1005–17.
-

*Hitoshi Hirose, MD, PhD.

Division of Cardiothoracic Surgery
Department of Surgery
Thomas Jefferson University
1025 Walnut Street, Room 605
Philadelphia, PA 19107, USA
Tel: +215-955-5654
Fax: +215-955-6010
Email: Hitoshi.Hirose@jefferson.edu