

8-1-2020

The Implications of Paraspinal Muscle Atrophy in Low Back Pain, Thoracolumbar Pathology, and Clinical Outcomes After Spine Surgery: A Review of the Literature.

Kevin He

Thomas Jefferson University

Jeffery Head

Thomas Jefferson University

Nikolaos Mouchtouris

Thomas Jefferson University

Kevin Hines and additional works at: <https://jdc.jefferson.edu/neurosurgeryfp>

 Thomas Jefferson University
Part of the [Neurology Commons](#), and the [Surgery Commons](#)

Phelan Shea
[Let us know how access to this document benefits you](#)
University of Maryland School of Medicine

Recommended Citation

See next page for additional authors.
He, Kevin; Head, Jeffery; Mouchtouris, Nikolaos; Hines, Kevin; Shea, Phelan; Schmidt, Richard; Hoelscher, Christian; Stricsek, Geoffrey; Harrop, James; and Sharan, Ashwini, "The Implications of Paraspinal Muscle Atrophy in Low Back Pain, Thoracolumbar Pathology, and Clinical Outcomes After Spine Surgery: A Review of the Literature." (2020). *Department of Neurosurgery Faculty Papers*. Paper 133.

<https://jdc.jefferson.edu/neurosurgeryfp/133>

This Article is brought to you for free and open access by the Jefferson Digital Commons. The Jefferson Digital Commons is a service of Thomas Jefferson University's [Center for Teaching and Learning \(CTL\)](#). The Commons is a showcase for Jefferson books and journals, peer-reviewed scholarly publications, unique historical collections from the University archives, and teaching tools. The Jefferson Digital Commons allows researchers and interested readers anywhere in the world to learn about and keep up to date with Jefferson scholarship. This article has been accepted for inclusion in Department of Neurosurgery Faculty Papers by an authorized administrator of the Jefferson Digital Commons. For more information, please contact: JeffersonDigitalCommons@jefferson.edu.

Authors

Kevin He, Jeffery Head, Nikolaos Mouchtouris, Kevin Hines, Phelan Shea, Richard Schmidt, Christian Hoelscher, Geoffrey Stricsek, James Harrop, and Ashwini Sharan

The Implications of Paraspinal Muscle Atrophy in Low Back Pain, Thoracolumbar Pathology, and Clinical Outcomes After Spine Surgery: A Review of the Literature

Kevin He, BS¹, Jeffery Head, BA¹ , Nikolaos Mouchtouris, MD¹ , Kevin Hines, MD¹ , Phelan Shea, MD², Richard Schmidt, MD¹, Christian Hoelscher, MD¹, Geoffrey Stricsek, MD¹, James Harrop, MD¹, and Ashwini Sharan, MD¹

Global Spine Journal
2020, Vol. 10(5) 657-666
© The Author(s) 2019
Article reuse guidelines:
sagepub.com/journals-permissions
DOI: 10.1177/2192568219879087
journals.sagepub.com/home/gsj



Abstract

Study Design: Literature review.

Objectives: Paraspinal muscle integrity is believed to play a critical role in low back pain (LBP) and numerous spinal deformity diseases and other pain pathologies. The influence of paraspinal muscle atrophy (PMA) on the clinical and radiographic success of spinal surgery has not been established. We aim to survey the literature in order to evaluate the impact of paraspinal muscle atrophy on low back pain, spine pathologies, and postoperative outcomes of spinal surgery.

Methods: A review of the literature was conducted using a total of 267 articles identified from a search of the PubMed database and additional resources. A full-text review was conducted of 180 articles, which were assessed based on criteria that included an objective assessment of PMA in addition to measuring its relationship to LBP, thoracolumbar pathology, or surgical outcomes.

Results: A total of 34 studies were included in this review. The literature on PMA illustrates an association between LBP and both decreased cross-sectional area and increased fatty infiltration of paraspinal musculature. Atrophy of the erector spinae and psoas muscles have been associated with spinal stenosis, isthmic spondylolisthesis, facet arthropathy, degenerative lumbar kyphosis. A number of studies have also demonstrated an association between PMA and worse postoperative outcomes.

Conclusions: PMA is linked to several spinal pathologies and some studies demonstrate an association with worse postoperative outcomes following spinal surgery. There is a need for further research to establish a relationship between preoperative paraspinal muscle integrity and postoperative success, with the potential for guiding surgical decision making.

Keywords

paraspinal muscle atrophy, low-back pain, systematic review, spine surgery, lumbar

Introduction

Paraspinal muscle integrity plays a critical role in the maintenance of global spinal alignment. Atrophy of the paraspinal muscles contributes to altered lumbar lordosis, thoracic kyphosis, and sacral-vertebral angle. While a few studies have demonstrated this association in adults without degenerative disease,^{1,2} more robust associations have been shown between the health of paraspinal muscles and the development of

¹ Thomas Jefferson University, Philadelphia, PA, USA

² University of Maryland School of Medicine, Baltimore, MD, USA

Corresponding Author:

Ashwini Sharan, Program Director, Residency in Neurological Surgery, Division Chief, Epilepsy and Neuromodulatory Neurosurgery, Thomas Jefferson University Hospital, 901 Walnut Street, 3rd Floor, Philadelphia, PA 19107, USA.

Email: ashwini.sharan@jefferson.edu



spinal deformities in pathological states, such as ankylosing spondylitis.³

Paraspinal muscle atrophy has been implicated in low back pain (LBP) as well as other thoracolumbar pathologies,⁴⁻⁸ including degenerative disc disease, lumbar spinal stenosis, and disc herniation, yet the evidence is less conclusive.⁴⁻¹¹ Furthermore, the impact of paraspinal muscle atrophy on postoperative outcomes has not been well studied. Most of the literature on the relationship between muscle atrophy and surgery has focused on the extent of atrophy between different surgical approaches as a primary endpoint. Few studies compare the degree of preoperative paraspinal cross-sectional area or fatty degeneration in relation to clinical outcomes assessed postoperatively.

Our primary objective is to determine the influence of paraspinal muscle atrophy on successful surgical outcomes in patients who received lumbar spinal surgery compared to patients with persistent low back pain, deformity, and pathology following lumbar spinal surgery. To achieve this objective, we conducted a review of the literature looking to elucidate the role of paraspinal muscle atrophy in spinal deformity, LBP, thoracolumbar pathology, persistent LBP after surgery, and failed back surgery. We highlight the current perception of the role of paraspinal muscle integrity in the success of spinal surgery in an effort to offer insight into avenues for improved surgical outcomes.

Methods

Literature Search and Inclusion Criteria

A review of the literature was performed in the PubMed Database on September 17, 2017 of all literature published after January 1, 2010. Briefly, we sought to identify studies of patients with LBP, thoracolumbar degenerative disease, or patients undergoing lumbar spine surgery that included an objective measure of paraspinal muscle atrophy and a comparison with disease-free controls or outcome-free controls. The search strategy included use of controlled vocabulary (MeSH terms) and key words including ((“Paraspinal Muscles”[MeSH Terms]) OR (intrinsic musc* of the back) OR (deep musc* of the back) OR (semispinalis) OR (rotatores) OR (multifidus) OR (erector spinae) OR (paraspinal) OR (paravertebral)) AND ((Atrophy[MeSH Terms]) OR (atroph*) OR (deteriorat*) OR (degenerat*)) AND ((evaluat*) OR (test) OR (assess*) OR (standard*) OR (assay*) OR (grade) OR (classify*) OR (quality) OR (morphology)). Articles were screened by 2 independent reviewers for the following inclusion criteria: pertaining to paraspinal muscle atrophy and LBP, thoracolumbar disease pathology, or lumbar spine surgery. Studies included randomized controlled trials, retrospective case-control studies, retrospective and prospective cohort studies, and meta-analyses. Exclusion criteria were the following: systematic reviews without meta-analysis, case reports, studies analyzing the cervical spine, and studies analyzing muscle-sparing surgical approaches, and studies analyzing paraspinal muscle atrophy without drawing a relation to LBP, thoracolumbar pathology, or postoperative outcomes.

A total of 267 articles were identified by the search and additional resources. Abstracts were sorted using the predefined inclusion criteria and classified as relevant to LBP, relevant to disease pathology, relevant to lumbar surgery, possibly relevant, or not relevant based on the exclusion criteria. A total of 87 articles were excluded in this manner (Figure 1). Full-text review of the remaining articles ($n = 180$) was done to determine if the studies contained an objective measure of paraspinal muscle atrophy (such as fatty degeneration or cross-sectional area) and if this measure was analyzed in the context of LBP, thoracolumbar degenerative disease, or lumbar spine surgery. This left 34 publications to be included for qualitative review.

Outcome Measures

Primary outcome measures included functional status as measured by Oswestry Disability Index (ODI) and visual analogue scale (VAS) for low-back and lower extremity pain. Other secondary outcomes measures included measures of spinal alignment, including pelvic tilt, sacral slope, sagittal balance, lumbar lordosis, thoracic kyphosis, and sagittal vertical axis.

Results

Study Selection

For the review of paraspinal muscle atrophy and its role in LBP, spinal pathology, and postoperative outcomes, 249 studies were identified through database searching and 18 studies were identified from references. Of these articles, 180 were deemed to be eligible for full-text review. Articles were assessed for inclusion of an analysis of the relationship between paraspinal muscle integrity and LBP, thoracolumbar pathology, or postoperative outcomes. A total of 146 articles were excluded. Reasons for exclusion included lack of an objective assessment of paraspinal muscle integrity, lack of an assessment of LBP or spinal pathology or postoperative outcomes, inclusion of cervical musculature, and so on. A total of 34 studies consisting of prospective cohorts, retrospective cohorts, cross-sectional, retrospective case-control and randomized controlled trials. The search flow diagram is shown in Figure 1.

Study Characteristics and Outcomes

The relevant characteristics of included studies are summarized in Tables 1 through 4. For the evaluation of the effect of paraspinal muscle atrophy on spinal alignment the primary outcomes were cross-sectional area and fatty infiltration of paraspinal muscles on magnetic resonance imaging (MRI). Secondary outcomes included thoracic kyphosis, lumbar lordosis, and sagittal vertical axis (Table 1). For the evaluation of the association between paraspinal muscle atrophy and both non-surgical LBP and postoperative LBP the primary outcomes were cross-sectional area and fatty infiltration on MRI and LBP by VAS (Tables 2 and 3). For the assessment of paraspinal muscle atrophy on postoperative LBP the primary outcomes

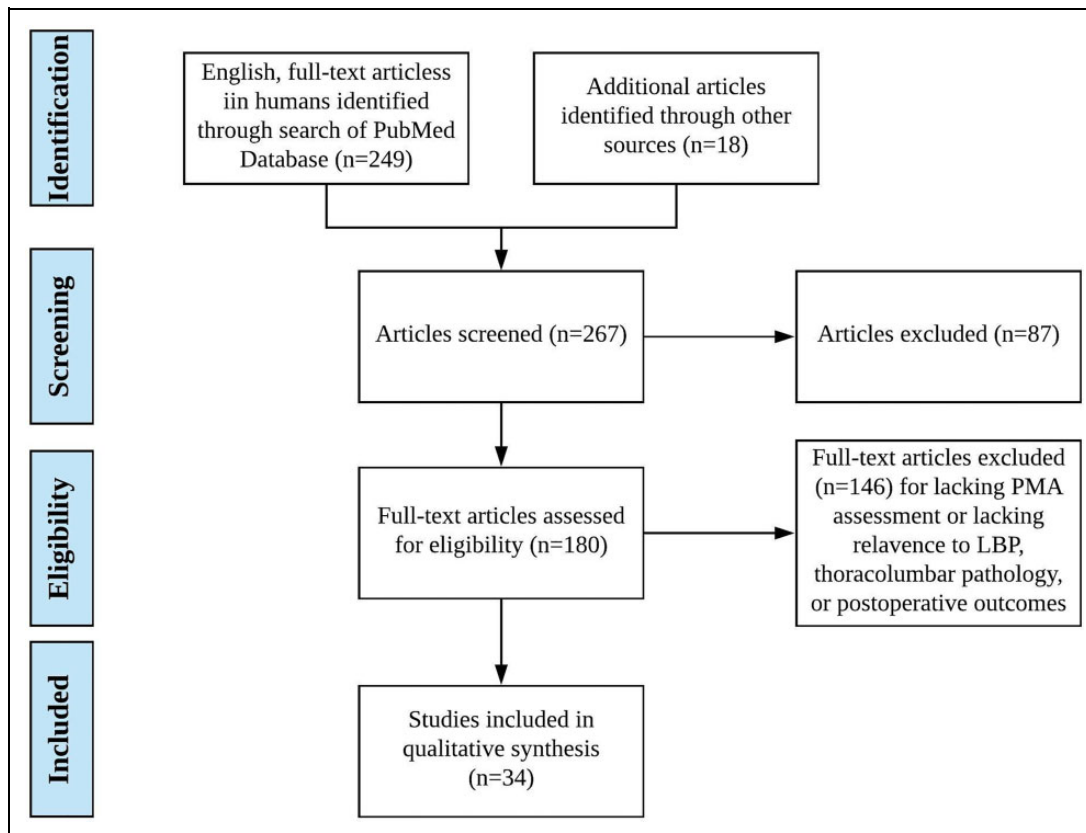


Figure 1. Flowchart illustrating approach to literature review and article selection.

Table 1. Studies Evaluating the Role of Paraspinal Muscle Atrophy in Maintaining Spinal Alignment in Patients Without Prior Spinal Surgery.

Paraspinal Muscle Atrophy in Spinal Alignment				
Authors	Year	Design	Conclusion	P
Masaki et al	2015	Cross sectional	Reduced thickness of erector spinae on ultrasound significantly determined increased thoracic kyphosis angle	<.01
Prasarn et al	2015	Retrospective cohort	Paraspinal muscle fatty degeneration on MRI was lower in patients with higher aerobic index	<.001
Jun et al	2016	Retrospective cohort	Fatty degeneration of paraspinal muscles on MRI was negatively correlated with lumbar lordosis and thoracic kyphosis and positively correlated with sagittal vertical axis	.000
Bok et al	2017	Retrospective cohort	Decreased cross-sectional area and increased fatty infiltration of paraspinal muscles on MRI were each significantly associated with increased lumbar lordosis and sacral slope on X-ray in control patients with chronic LBP	<.01

Abbreviations: LBP, low back pain; MRI, magnetic resonance imaging.

included ODI and VAS (Table 4). For the assessment of paraspinal muscle atrophy on failed back surgery, the primary outcomes included preoperative paraspinal cross-sectional area, fatty infiltration and postoperative spinal fusion (Table 4).

Discussion

The Role of Paraspinal Muscles in Maintaining Spinal Balance and Alignment

One of the goals of spine surgery is to adequately restore global spinal alignment, balance, and function of the spine. Numerous

spine alignment parameters have been well studied in asymptomatic adults^{9,10} and have been repeatedly implicated in the clinical outcomes of spine deformity and disease.^{11,12}

The integrity of the paraspinal muscles, which includes the multifidus, erector spinae, and psoas major muscles, plays a critical role in maintaining proper spinal balance and global alignment. A study of 36 middle-aged and elderly Japanese women demonstrated that reduced thickness of the erector spinae muscles measured on ultrasound was a significant determinant of increased thoracic kyphosis angle ($R^2 = 0.23$; $P < .01$) while decreased thickness of the psoas major was associated with increased sacral anterior inclination ($R^2 = 0.32$, $P < .01$).²

Table 2. Notable Studies Highlighting Relationships Between Low Back Pain and Reduced Cross-Sectional Area or Fatty Infiltration of Paraspinal Musculature.

Paraspinal Muscle Atrophy in Low Back Pain				
Authors	Year	Design	Conclusion	P
Wallwork et al	2009	Cross sectional	Patients with chronic LBP had smaller CSAs of the multifidus at L5 on ultrasound than pain-free controls	.001
Beneck et al	2012	Cross sectional	Patients with chronic unilateral LBP had smaller multifidus volumes at L5-S1 on MRI than pain-free controls	.026
Belavy et al	2011	Prospective cohort	After bed rest, patients experienced greater LBP on VAS with greater reductions in multifidus CSA at L4	.00027
Goubert et al	2017	Cross sectional	Individuals with continuous chronic LBP have greater fat CSA in the multifidus and erector spinae at L4 than those with noncontinuous chronic LBP	<.001, .007
Kjaer et al	2007	Cross sectional	Adults with severe fatty infiltration in the lumbar multifidus muscle had higher odds of ever experiencing LBP and of experiencing LBP in the past year compared to those with no fatty infiltration	OR 4.1, 95% CI [1.5-11.2]; OR 9.2, 95% CI [2.0-43.2]
Yanik et al	2013	Cross sectional	Greater muscle degeneration as assessed by signal intensity suppression rates and signal intensity indices was seen in patients with fatty infiltration and LBP compared with asymptomatic controls	<.001
Lakadamyali et al	2008	Case-control	Individuals with LBP had greater intrinsic muscle degeneration in lumbar paraspinals evaluated on STIR imaging compared with asymptomatic controls.	.0001

Abbreviations: CI, confidence interval; CSA, cross-sectional area; LBP, low back pain; MRI, magnetic resonance imaging; OR, odds ratio; STIR, short T1 inversion recovery; VAS, visual analogue scale.

In a study of 50 elderly patients with degenerative spine disease that did not undergo surgery, Jun et al¹ demonstrated that fatty degeneration of the erector spinae and multifidus was significantly correlated with decreased alignment of the spine. Fatty degeneration measured on MRI was negatively correlated with lumbar lordosis ($r = -0.505$, $P = .000$) and thoracic kyphosis ($r = -0.555$, $P = .000$) and positively correlated with sagittal vertical axis ($r = 0.488$, $P = .000$).¹ Furthermore, paraspinal fatty degeneration has been shown to significantly correlate with increased body fat percentage and worse physical fitness. In the same study, the patients with greater physical fitness were also shown to have on average a lower ODI score ($P = .075$).¹³

Bok et al³ took this association a step further and proposed that paraspinal muscle atrophy directly contributed to the disease process of spinal misalignment and imbalance in ankylosing spondylitis (AS). In their retrospective study of 51 AS patients with LBP but without deformity, paraspinal muscle atrophy was found to be evident in AS patients compared with age and spinopelvic alignment matched controls with chronic back pain.³ Decreased cross-sectional area and increased fatty infiltration were each significantly associated with increased lumbar lordosis ($r = 0.561$, $P < .01$; $r = 0.639$, $P < .01$), sacral slope ($r = 0.535$, $P < .01$; $r = 0.610$, $P < .01$), and decreased pelvic tilt ($r = -0.404$, $P < .01$; $r = -0.535$, $P < .01$). These associations persisted when adjusting for body mass index, physical workload, and leisure activity.³ The authors proposed that selective muscle degeneration of the paraspinal muscles causes dynamic imbalance between flexor and extensor groups,

which contributes to the development of kyphosis and further disuse atrophy of the paraspinal muscles.

The paraspinal musculature plays a critical role in maintaining normal alignment and balance of the spine (Table 1). The causal nature of this relationship has yet to be determined though and there is a paucity of evidence distinguishing between paraspinal muscle atrophy as a result of impaired spinal alignment versus paraspinal muscle atrophy as a primary disease process.³

The Role of Paraspinal Muscle Atrophy in Low Back Pain

Many studies have successfully demonstrated significant associations between decreased cross-sectional area of the multifidus and erector spinae muscles and increased LBP.⁴⁻⁸ Fatty infiltration on imaging and fat as an increased percentage of total cross-sectional area are two markers of muscle atrophy that have been demonstrated to play a role in the development of LBP.¹⁴⁻¹⁸ Additionally, side-to-side asymmetry of greater than 10% in the erector spinae was shown to be correlated with greater LBP.¹⁵ Despite these radiographic findings, the relationship between LBP and paraspinal muscle atrophy is not straightforward.

One study examined the relationship between paraspinal muscle atrophy and LBP in the context of bed rest, where 9 adult males were subjected to extended head-down-tilt bed rest and their pain was measured by VAS after bed rest.⁶ Greater LBP was strongly associated with increased loss of multifidus cross-sectional area at L4 ($9.5\% \pm 2.5\%$ greater reduction, $P =$

Table 3. Notable Studies Illustrating the Relationship Between Cross-Sectional Area, Fatty Infiltration, and Asymmetry of Paraspinal Muscles and the Presence of Spinal Disease.

Paraspinal Muscle Atrophy in Thoracolumbar Pathology				
Authors	Year	Design	Conclusion	P
Fortin et al	2017	Case control	Greater dysfunction in spinal stenosis as measured on ODI was associated with decreases in CSA ratios in the multifidus and psoas muscles at L5.	<.01, .03
Kang et al	2007	Cross sectional	Degenerative lumbar kyphosis was associated with smaller CSA-to-disc ratios in the psoas, erector spinae, and multifidus muscles at L4-L5 compared to individuals with chronic low back pain.	<.0001, .0002, <.0001
Sebro et al	2016	Cross sectional	Lower densities of the psoas, multifidus, and longissimus muscles on CT correlated with more severe degenerative disc disease and facet arthropathy.	<.0001
Thakar et al	2016	Case-control	Isthmic spondylolisthesis was associated with smaller CSA—vertebral body area in the multifidus, and greater CSA—vertebral body area in the erector spinae, with nonsignificant change in the psoas muscle.	.009, .002, .427
Hyun et al	2007	Case-control	Patients experiencing radiculopathy in the setting of a herniated disc had a greater prevalence of asymmetry in the multifidus at L4- L5 and L5-S1 compared to herniation in the absence of radiculopathy and non-herniated controls. The asymmetry was also more severe.	<.01
Shafaq et al	2012	Cross sectional	Patients with lumbar spinal stenosis and unilateral radiculopathy were found to have smaller CSA and greater fatty infiltration of the multifidus at L4-L5 and L5-S1 on the symptomatic side. There was greater fatty infiltration of the longissimus on the affected side at L5-S1 only. The CSA of the longissimus was not different between sides at L4-L5 and L5-S1.	CSA _m , .007, .001; FI _m , <.001, .001; FI _i , .200, 0.017; CSA _i , 0.090, .209
Ploumis et al	2011	Cross sectional	Patients with monosegmental disc degeneration experiencing unilateral back pain had smaller paravertebral muscle CSA on the symptomatic compared to asymptomatic side at all measured levels (one above and below the pathology) and muscles (psoas, multifidus, quadratus lumborum, longissimus, iliocostalis).	<.005
Battie et al	2012	Cross sectional	Patients with posterolateral lumbar disc herniation and unilateral radiculopathy possessed smaller functional-to-total multifidus CSA ratios below and at the level of the herniation. Fatty infiltration was greater on the side of the herniation at the level below. However, the total CSA was greater on the side of the herniation.	.007, .031, .014, .033

Abbreviations: CSA, cross-sectional area; CT, computed tomography; FI, fatty infiltration; ODI, Oswestry Disability Index.

.00027), but was not statistically significant at L5 (6.2% \pm 3.5% greater reduction, $P = .085$). Also, LBP was strongly correlated with increased posterior disc height in the lower lumbar spine due to decreased lordosis and increased intervertebral flexibility. This suggests that the LBP may have resulted from the increased onus on the paraspinal musculature to support the lower back complicated by disuse atrophy of the paraspinal muscles following bed rest. However, periodic exercise during the course of bedrest as a countermeasure to paraspinal muscle atrophy did not result in decreased reports of LBP or less deterioration of spinal morphology.¹⁹ These findings not only confirm that paraspinal muscle atrophy is associated with LBP but also suggest the deleterious effects of bed rest on surgical outcomes and postoperative LBP. Moreover, Goubert et al¹⁶ divided LBP into 3 categories: continuous chronic LBP (pain every day), noncontinuous chronic LBP (pain \geq 3-4 days per week), and recurrent LBP (\geq 2 episodes in the past year followed by no pain \geq 1 month).^{7,16} Interestingly, they showed

that fatty infiltration was highest in the continuous chronic LBP group.

Fatty infiltration and cross-sectional area are the mainstays of measuring muscle atrophy, and several studies have linked LBP to PMA using varied assessments of atrophy. Yanik et al²⁰ used chemical shift magnetic resonance imaging to more accurately detail fatty infiltration of the paraspinal muscles and revealed significantly more signal intensity changes, indicating more degeneration and atrophy in the LBP group, compared with asymptomatic control—even in the absence of fatty streaking in both groups. In a comparison of groups with fatty infiltration, the same results held true.²⁰ Lakadamyali et al²¹ used STIR (short T1 inversion recovery) imaging to determine the amount of edematous change in the paraspinal muscles. Even though it was not the most frequently seen form of paraspinal degeneration in the study, there was a significant difference in frequency of intrinsic spinal muscle degeneration between individuals with low

Table 4. Studies Analyzing the Relationship Between Preoperative Paraspinal Muscle Integrity and Postoperative Outcome, Including Persistent Low Back Pain, Failure of Fusion, Development of Adjacent Segment Disease, and Need for Reoperation.

Surgical Implications of Paraspinal Muscle Atrophy				
Authors	Year	Design	Conclusion	P
<i>Persistent low back pain after surgery</i>				
Betz et al	2017	Prospective cohort	Greater paraspinal muscle fat infiltration was associated with less clinical improvement on the SSM after surgical decompression at 12 months in patients with symptomatic lumbar spinal stenosis.	.04
Storheim et al	2017	Prospective cohort	Increased multifidus fat was associated with less improvement in ODI scores at 2 years in individuals with chronic back pain and degenerative disc disease who underwent total disc replacement.	<.001
Zotti et al	2017	Prospective cohort	Higher preoperative CSA is associated with more postoperative clinical improvement on COMI and ODI.	.006
Arts et al	2010	Randomized controlled trial	VAS did not significantly correlate with either postoperative to preoperative CSA ratio or multifidus fat infiltration in patients with lumbar herniation undergoing conventional microdiscectomy and tubular microdiscectomy	Spearman's correlation coefficient: -0.12, -0.23
<i>Failed back surgery</i>				
Betz et al	2017	Prospective cohort	Individuals with greater preoperative paraspinal muscle fat infiltration did not have significantly different failure rates than those with less degeneration after surgical decompression for symptomatic lumbar spinal stenosis.	.81
Choi et al	2017	Retrospective cohort	In patients undergoing L3-L4 PLIF with screw fixation, those who did not fuse at 56 weeks had significantly more PMA at the L2-L3 and L4-L5 levels.	.039, .015
Lee et al	2017	Retrospective cohort	There is a correlation between preoperative CSA of the lumbar paraspinals at multiple levels and improved static and multiple dynamic parameters obtained by fusion for patients undergoing correction of degenerative flat back.	Multiple significant values
Choi et al	2016	Retrospective cohort	In patients undergoing L4-L5 PLIF with stand-alone cage, those who did not fuse at 56 weeks had significantly more PMA at the L3-L4 and L4-L5 levels.	.048, .021
<i>Other postoperative complications</i>				
Kim et al	2016	Case-control	Patients with ASD were more likely to have greater preoperative fatty infiltration and decreased relative CSA after open midline PLIF with screw fixation.	.044, .003

Abbreviations: ASD, adjacent segment disease; COMI, Core Outcomes Measure Index; CSA, cross-sectional area; ODI, Oswestry Disability Index; PLIF, posterior lumbar interbody fusion; PMA, paraspinal muscle atrophy; SSM, Spinal Stenosis Measure; VAS, visual analogue scale.

back pain and their age- and ethnicity-matched controls ($P = .0001$).²¹

Despite the strong association between low back pain and paraspinal musculature atrophy seen in the aforementioned studies (Table 2), a study by Kalichman et al²² on patients with LBP from the Framingham Heart study who underwent computed tomography (CT) imaging to assess for aortic calcification had contradictory findings. They found that there was no association between LBP and paraspinal muscle density when adjusted for body mass index, age, and sex. Only spinal stenosis was significantly associated with LBP (odds ratio [OR] 3.45, 95% CI 1.12-10.68).²² Using CT instead of MRI is a major limitation of this study that needs to be taken into consideration when interpreting their findings.

The Role of Paraspinal Muscle Atrophy in Thoracolumbar Pathology

There is limited literature assessing paraspinal muscle atrophy with regard to thoracolumbar pathology. Kalichman et al⁸ suggest an association between paraspinal muscle atrophy and spondylolisthesis, facet joint osteoarthropathy, and disc space

narrowing. A study composed of patients with moderate ($ODI < 42$) and severe ($ODI \geq 42$) lumbar spinal stenosis found significant decreases in multifidus functional cross-sectional area to total cross-sectional area ratios (superior L5: 0.46 to 0.37, $P = .02$; inferior L5: 0.44 to 0.34, $P < .01$) and reductions in psoas cross-sectional area to vertebral endplate cross-sectional ratios (inferior L5: 0.80 to 0.61, $P = .03$) in more severe disease.²³ Degenerative lumbar kyphosis was associated with reduced cross-sectional area to disc ratios even relative to patients with chronic LBP (psoas: 0.79 ± 0.22 , 0.98 ± 0.23 , $P < .0001$; erector spinae: 1.36 ± 0.49 , 1.71 ± 0.46 , $P = .0002$; multifidus: 0.55 ± 0.21 , 0.86 ± 0.30 , $P < 0.0001$) via MRI evaluation of the paraspinal muscles,²⁴ whereas CT suggested a correlation between reduced density and presence of degenerative disc disease ($r_{\text{psoas}} = -0.60$, $r_{\text{multifidus}} = -0.61$, $r_{\text{longissimus}} = -0.67$; $P < .0001$) and facet joint arthropathy ($r_{\text{psoas}} = -0.59$, $r_{\text{multifidus}} = -0.61$, $r_{\text{longissimus}} = -0.68$; $P < .0001$).²⁵ Decreased multifidus cross-sectional area relative to vertebral body area was noted in a group of 120 individuals with isthmic spondylolisthesis when compared with normal controls (0.42 ± 0.09 , 0.46 ± 0.14 , $P = .009$).²⁶

The remaining studies implicating paraspinal muscle atrophy in thoracolumbar pathology development address

asymmetry between right- and left-sided paraspinal muscle groups rather than average area. In another group of patients with lumbar spinal stenosis, more asymmetric paraspinal muscle atrophy was noted in individuals with degenerative lumbar scoliosis than in those without.²⁷ Asymmetry appears to be associated with posterolateral disc herniation at the lower lumbar and upper sacral levels as well as with degenerative disc disease and radiculopathy.²⁸⁻³⁰ However, those with greater extents of atrophy did not have longer durations of symptoms in degenerative disc disease.²⁸ Hyun et al²⁹ compared patients with radiculopathy to patients with asymptomatic disc herniation and found that asymmetric atrophy of the multifidus muscle was more commonly seen in the patients with radiculopathy ($P < .01$).

While PMA has been associated with ipsilateral LBP and radiculopathy, a study by Ploumis et al³⁰ found no correlation with duration and the severity of pain as measured by ODI and VAS. Interestingly, a study of 120 patients with surgically managed isthmic spondylolisthesis in which an association was found between the pathology and multifidus atrophy did not illustrate a similar association between multifidus atrophy and disc degeneration or facet arthropathy,²⁶ nor did it note significant reductions in psoas cross-sectional area to vertebral body area ratios (0.61 ± 0.19 , 0.63 ± 0.20 , $P = .427$) in isthmic spondylolisthesis versus controls. In fact, the erector spinae cross-sectional area to vertebral body area ratio was increased (0.99 ± 0.26 , 0.89 ± 0.24 , $P = .002$) in the isthmic spondylolisthesis group, suggesting compensatory hypertrophy.

As with the studies on LBP, the links between paraspinal muscle atrophy and the forms of thoracolumbar pathology discussed above are associative. There is some evidence linking reduced cross-sectional area to these diseases (Table 3). There are no standardized methods of assessing muscular pathology in this context. As the preponderance of investigations have studied the relationship between paraspinal muscle atrophy and LBP, there is room for more investigation into the impact of paraspinal muscle atrophy on thoracolumbar pathologies.

The Impact of Paraspinal Muscle Atrophy on Persistent Low Back Pain After Surgery

Less paraspinal muscle atrophy has also been shown to result in better clinical outcomes after surgery for lumbar spine stenosis (Table 4). A recent study by Zotti et al³¹ concluded that preoperative lumbar multifidus cross-sectional area evaluated on MRI is a better predictor of clinical outcome on the Core Outcomes Measure Index and ODI than the Kader classification (Table 5),³² which scored the muscles based on fatty degeneration. Higher cross-sectional area was associated with greater improvement in ODI score, and individuals were more likely to have greater than 40% improvement on the Core Outcomes Measure Index and ODI if they had a higher cross-sectional area (68% of individuals in the large cross-sectional area group vs 32%, $P = .006$). Preoperatively, the fatty appearance of the multifidus based on the Kader classification did not significantly predict pain indices

Table 5. Kader Classification System.^a

Degree of Atrophy	Percentage of Muscle Bulk Replaced by Fat and Fibrous Tissue
Mild	<10
Moderate	<50
Severe	>50

^aAs defined in the methods of Kader et al (2000).³² Changes in the multifidus muscle on fast-spin echo T2-weighted lumbar spine magnetic resonance imaging in axial and sagittal views were assessed.

Table 6. Goutallier Classification System.^a

Grade	Quantity of Intramuscular Fat
0	none
1	fatty streaks
2	present but less than muscle
3	equal to muscle
4	greater than muscle

^aAs defined in the methods of Goutallier et al (1994).³⁴ The classification system was originally proposed in a study of rotator cuff ruptures using computed tomography imaging. It was recently evaluated as a qualitative measure of lumbar paraspinal muscle using T1-weighted axial magnetic resonance imaging by Tamai et al (2018).³⁵

postoperatively, though it trended toward significance.³¹ In spite of this lack of predictive value, Betz et al³³ describe greater symptom improvement based on the Spinal Stenosis Measure (SSM) in the setting of less paraspinal muscle atrophy as defined by Goutallier's classification (Table 6).³⁴ A Goutallier score of 2 or more, consistent with greater paraspinal degeneration, resulted in less clinically meaningful symptom improvement in the SSM score from baseline to 12 months after surgical decompression compared with a Goutallier score of 1 or less (3.2 to 2.3 [0.9], 3.2 to 2.1 [1.1], $P = .04$; Table 4).³³ Logistic regression models additionally found that the odds of experiencing a clinically significant difference in SSM were lower with greater degrees of degeneration (OR = 0.47, 95% CI 0.25-0.88, $P = .02$). The follow-up periods in these studies were 2 years and 1 year, respectively; greater follow-up may be necessary to accurately assess the impact of preoperative muscle integrity on long-term outcomes.

Pain is not consistently associated with poorer paraspinal integrity in the context of disc pathology. VAS did not significantly correlate with postoperative to preoperative cross-sectional area ratio in patients with lumbar herniation undergoing conventional microdiscectomy and tubular microdiscectomy (Spearman's correlation coefficient = -0.12).³⁶ It additionally did not correlate with multifidus fatty infiltration in the lumbar herniation cases (Spearman's correlation coefficient = -0.23). There were, however, significantly lower ODI scores (16.8 ± 14.2 vs 42.6 ± 20.3 , $P < .001$) at 2-year follow-up in individuals undergoing total disc replacement who had no change in multifidus muscle fat

compared to those with increased multifidus muscle fat in 1 or 2 levels.³⁷

The Relationship Between Paraspinal Muscle Atrophy and Failed Back Surgery

Paraspinal muscle strength and integrity have also been implicated in the development of spinal deformity as a complication of surgery (Table 4). In a study of 60 patients with degenerative lumbar scoliosis treated with fusion, decreased cross-sectional area of the multifidus was moderately correlated to postoperative global misalignment measured as a composite of thoracic kyphosis, lumbar lordosis, and pelvic incidence ($r = -0.37$).³⁸

While Betz et al³³ demonstrated some contribution of low preoperative paraspinal fat content to reduction in postoperative symptom severity, there were nonsignificant reductions in reintervention rates with poorer paraspinal integrity. Data from a prospective multicenter cohort study were analyzed to include 205 patients with symptomatic lumbar spinal stenosis who received treatment with either epidural steroid infiltration or conventional decompression surgery. In the epidural steroid infiltration group, patients with a Goutallier score of 1 or less were more likely to require reintervention compared to those with scores of 2 or greater (71% vs 47%, $P = .22$). However, this relationship did not reach significance, and the primary intervention was nonsurgical, hence these findings are not reflective of postoperative outcomes. Those who underwent surgical decompression did not have notable differences in failure rates with different degrees of degeneration (13% vs 11%, $P = .81$). On the other hand, the only 2 studies on fusion available found results supportive of the predictive value of PMA. In patients undergoing posterior lumbar interbody fusions (PLIFs), smaller cross-sectional area was associated with poorer fusion rates in both screw fixation and stand-alone cage.^{39,40} For those undergoing screw fixation, increased preoperative paraspinal muscle atrophy also correlated with slower fusion times (for L3-L4 fusion, erector spinae and multifidus CSAs, $r_{L4-L5} = -0.401$, $P = .042$; for L4-L5 fusion, $r_{L3-L4} = -0.373$, $P = .025$; $r_{L4-L5} = -0.402$, $P = .048$) with fusion status determined at 56-week follow-up.³⁹ The results did not reach significance at all levels of muscle atrophy that were included in the study. In the L3-L4 group, the patients who did not fuse at 56 weeks were older (mean age 52.9 vs 60.1 years, $P = .009$) and had significantly more erector spinae and multifidus atrophy at L2-L3 (4150.1 ± 539.3 vs 3842.1 ± 515.4 , $P = .039$) and L4-L5 (4312.5 ± 515.8 vs 3957.2 ± 449.8 , $P = .015$) compared with those who did fuse, and the negative correlation found between time to fusion and erector spinae and multifidus atrophy only applied to the L4-L5 level ($r = -0.401$, $P = .042$).³⁹ In the L4-L5 group, similar findings applied to the L4-L5 and L5-S1 muscle levels with regard to fusion failure and the L3-L4 and L4-L5 muscle levels with regard to slow fusions.³⁹ Only L4-L5 was examined in the context of stand-alone PLIF cages, and atrophy at the levels L3-L4 (4391.7 ± 613.9 vs 3910.1 ± 479.0 , $P = .048$) and L4-L5 (3984.3 ± 500.1 vs 3501.5 ± 489.3 , $P = .021$) were

associated with higher failure rates.⁴⁰ An additional study reported a correlation between preoperative cross-sectional area of the lumbar paraspinals and improved static and dynamic parameters obtained by fusion for correction of degenerative flat back.⁴¹

Furthermore, paraspinal muscle atrophy has also been shown to affect adjacent segment degeneration (ASD). Kim et al⁴² studied 50 patients with radiographic ASD taken from a pool of patients who had previously undergone open midline PLIF with screw fixation. Preoperative measurements of the cross-sectional area of paraspinals were divided by the L4-L5 vertebral disc cross-sectional area to yield a relative cross-sectional (rCSA) to control for patient-to-patient variation. Fat composition was measured by classifying lean paraspinal muscle, fat, and bone into respective MRI grayscale ranges and calculating pixels within those ranges to provide accurate areas.⁴³ They matched the ASD group with 50 patients controlled for age, sex, fusion level and found that the ASD group had significantly lower preoperative paraspinal rCSA and cross-sectional area and more fatty, facet, and disc degeneration than controls. The latter 2 measurements were made in the proximal or distal adjacent segments to those that developed ASD. Preoperative fatty degeneration (OR 1.080, 95% CI 1.002-1.163, $P = .044$) and rCSA (OR 0.083, 95% CI 0.016-0.420, $P = .003$) were both predictors of postoperative ASD, alongside facet joint and disc degeneration.⁴²

Limitations

There are a few limitations that need to be considered when reviewing our findings. First, there is an inherent concern for selection and reporting bias in conducting a review of the literature. Furthermore, most studies we identified were retrospective cohort or case-control studies with moderate inherent bias. There is paucity of data available on the contribution of paraspinal muscle atrophy to low back pain, thoracolumbar pathology, and postoperative outcomes. Only 34 studies from the past 10 years ultimately qualified for inclusion in our review. An additional limitation is the lack of a standardized measurement for paraspinal muscle atrophy and the heterogeneous and subjective scales used to measure paraspinal muscle degeneration. The designs are spread across a wide range of cross-sectional, case control, and cohort studies that do not standardize measurements of cross-sectional area and fatty degeneration. For example, the study by Zotti et al³¹ mentioned measurement of the vertebral body and psoas muscle but did not further describe how this standardized the measurement. After being applied to preoperative imaging, the scores for fatty degeneration used in the studies by Storheim et al³⁷ and Betz et al³³ were not standardized within patients. The ratio of paraspinal fat to fat of another muscle group within the same individual may have been a more appropriate measure, as individual patients may have differing baseline levels of fat or cross-sectional area, making it difficult to draw conclusions from averaged, unstandardized measurements.

Conclusion

The literature on paraspinal muscle atrophy illustrates an association between LBP and both decreased cross-sectional area and increased fat, especially in the multifidus and erector spinae. Edematous changes and signal intensity changes indicated compromised paraspinal musculature. Atrophy of the erector spinae muscles and the psoas have been associated with spinal stenosis, isthmic spondylolisthesis, facet arthropathy, degenerative lumbar kyphosis. More important, there are a number of studies demonstrating an association between paraspinal muscle atrophy and worse postoperative outcomes, yet there is still a paucity of standardized preoperative assessment of paraspinal muscle atrophy as well as guidelines on preoperative optimization and surgical timing. There is thus a pressing need for better studies on the prognostic value of paraspinal muscle atrophy for postoperative outcomes in an effort to assist the treating surgeon's decision making and operative planning.

Declaration of Conflicting Interests

The author(s) declared no potential conflicts of interest with respect to the research, authorship, and/or publication of this article.

Funding

The author(s) received no financial support for the research, authorship, and/or publication of this article.

ORCID iD

Jeffery Head, BA  <https://orcid.org/0000-0001-8077-4409>
 Nikolaos Mouchtouris, MD  <https://orcid.org/0000-0001-9495-9391>
 Kevin Hines, MD  <https://orcid.org/0000-0003-1700-174X>

References

1. Jun HS, Kim JH, Ahn JH, et al. The effect of lumbar spinal muscle on spinal sagittal alignment: evaluating muscle quantity and quality. *Neurosurgery*. 2016;79:847-855. doi:10.1227/NEU.0000000000001269
2. Masaki M, Ikezoe T, Fukumoto Y, et al. Association of sagittal spinal alignment with thickness and echo intensity of lumbar back muscles in middle-aged and elderly women. *Arch Gerontol Geriatr*. 2015;61:197-201. doi:10.1016/j.archger.2015.05.010
3. Bok DH, Kim J, Kim TH. Comparison of MRI-defined back muscles volume between patients with ankylosing spondylitis and control patients with chronic back pain: age and spinopelvic alignment matched study. *Eur Spine J*. 2017;26:528-537. doi:10.1007/s00586-016-4889-2
4. Wallwork TL, Stanton WR, Freke M, Hides JA. The effect of chronic low back pain on size and contraction of the lumbar multifidus muscle. *Man Ther*. 2009;14:496-500. doi:10.1016/j.math.2008.09.006
5. Beneck GJ, Kulig K. Multifidus atrophy is localized and bilateral in active persons with chronic unilateral low back pain. *Arch Phys Med Rehabil*. 2012;93:300-306. doi:10.1016/j.apmr.2011.09.017
6. Belavy DL, Armbrecht G, Richardson CA, Felsenberg D, Hides JA. Muscle atrophy and changes in spinal morphology: is the lumbar spine vulnerable after prolonged bed-rest? *Spine (Phila Pa 1976)*. 2011;36:137-145. doi:10.1097/BRS.0b013e3181cc93e8
7. Cooper RG, St Clair Forbes W, Jayson MI. Radiographic demonstration of paraspinal muscle wasting in patients with chronic low back pain. *Br J Rheumatol*. 1992;31:389-394.
8. Kalichman L, Carmeli E, Been E. The association between imaging parameters of the paraspinal muscles, spinal degeneration, and low back pain. *Biomed Res Int*. 2017;2017:2562957. doi:10.1155/2017/2562957
9. Cho Y. Evaluation of global sagittal balance in Koreans adults. *J Korean Neurosurg Soc*. 2017;60:560-566. doi:10.3340/jkns.2016.1212.002
10. Asai Y, Tsutsui S, Oka H, et al. Sagittal spino-pelvic alignment in adults: the Wakayama spine study. *PLoS One*. 2017;12:e0178697. doi:10.1371/journal.pone.0178697
11. McDowell MM, Tempel ZJ, Gandhoke GS, et al. Evolution of sagittal imbalance following corrective surgery for sagittal plane deformity. *Neurosurgery*. 2017;81:129-134. doi:10.1093/neuros/nyx145
12. Terran J, Schwab F, Shaffrey CI, et al; International Spine Study Group. The SRS-Schwab adult spinal deformity classification: assessment and clinical correlations based on a prospective operative and nonoperative cohort. *Neurosurgery*. 2013;73:559-568. doi:10.1227/NEU.0000000000000012
13. Prasarn ML, Kostantinos V, Coyne E, Wright J, Rechtine GR. Does lumbar paraspinal muscle fatty degeneration correlate with aerobic index and Oswestry Disability Index? *Surg Neurol Int*. 2015;6(suppl 4):S240-S243. doi:10.4103/2152-7806.156606
14. Pezolato A, de Vasconcelos EE, Defino HLA, Nogueira-Barbosa MH. Fat infiltration in the lumbar multifidus and erector spinae muscles in subjects with sway-back posture. *Eur Spine J*. 2012;21:2158-2164. doi:10.1007/s00586-012-2286-z
15. Fortin M, Yuan Y, Battie MC. Factors associated with paraspinal muscle asymmetry in size and composition in a general population sample of men. *Phys Ther*. 2013;93:1540-1550. doi:10.2522/ptj.20130051
16. Goubert D, De Pauw R, Meeus M, et al. Lumbar muscle structure and function in chronic versus recurrent low back pain: a cross-sectional study. *Spine J*. 2017;17:1285-1296. doi:10.1016/j.spinee.2017.04.025
17. Teichtahl AJ, Urquhart DM, Wang Y, et al. Lumbar disc degeneration is associated with modic change and high paraspinal fat content—a 3.0T magnetic resonance imaging study. *BMC Musculoskelet Disord*. 2016;17:439. doi:10.1186/s12891-016-1297-z
18. Kjaer P, Bendix T, Sorensen JS, Korsholm L, Leboeuf-Yde C. Are MRI-defined fat infiltrations in the multifidus muscles associated with low back pain? *BMC Med*. 2007;5:2. doi:10.1186/1741-7015-5-2
19. Belavy DL, Armbrecht G, Gast U, Richardson CA, Hides JA, Felsenberg D. Countermeasures against lumbar spine deconditioning in prolonged bed rest: resistive exercise with and without whole body vibration. *J Appl Physiol (1985)*. 2010;109:1801-1811. doi:10.1152/jappphysiol.00707.2010
20. Yanik B, Keyik B, Conkbayir I. Fatty degeneration of multifidus muscle in patients with chronic low back pain and in asymptomatic volunteers: quantification with chemical shift magnetic

- resonance imaging. *Skeletal Radiol.* 2013;42:771-778. doi:10.1007/s00256-012-1545-8
21. Lakadamyali H, Tarhan NC, Ergun T, Cakir B, Agildere AM. STIR sequence for depiction of degenerative changes in posterior stabilizing elements in patients with lower back pain. *AJR Am J Roentgenol.* 2008;191:973-979. doi:10.2214/AJR.07.2829
 22. Kalichman L, Kim DH, Li L, Guermazi A, Hunter DJ. Computed tomography-evaluated features of spinal degeneration: prevalence, intercorrelation, and association with self-reported low back pain. *Spine J.* 2010;10:200-208. doi:10.1016/j.spinee.2009.10.018
 23. Fortin M, Lazary A, Varga PP, Battie MC. Association between paraspinal muscle morphology, clinical symptoms and functional status in patients with lumbar spinal stenosis. *Eur Spine J.* 2017;26:2543-2551. doi:10.1007/s00586-017-5228-y
 24. Kang CH, Shin MJ, Kim SM, Lee SH, Lee CS. MRI of paraspinal muscles in lumbar degenerative kyphosis patients and control patients with chronic low back pain. *Clin Radiol.* 2007;62:479-486. doi:10.1016/j.crad.2006.12.002
 25. Sebro R, O'Brien L, Torriani M, Bredella MA. Assessment of trunk muscle density using CT and its association with degenerative disc and facet joint disease of the lumbar spine. *Skeletal Radiol.* 2016;45:1221-1226. doi:10.1007/s00256-016-2405-8
 26. Thakar S, Sivaraju L, Aryan S, Mohan D, Kiran NAS, Hegde AS. Lumbar paraspinal muscle morphometry and its correlations with demographic and radiological factors in adult isthmic spondylolisthesis: a retrospective review of 120 surgically managed cases. *J Neurosurg Spine.* 2016;24:679-685. doi:10.3171/2015.9.SPINE15705
 27. Shafaq N, Suzuki A, Matsumura A, et al. Asymmetric degeneration of paravertebral muscles in patients with degenerative lumbar scoliosis. *Spine (Phila Pa 1976).* 2012;37:1398-1406. doi:10.1097/BRS.0b013e31824c767e
 28. Ploumis A, Michailidis N, Christodoulou P, Kalaitzoglou I, Gouvas G, Beris A. Ipsilateral atrophy of paraspinal and psoas muscle in unilateral back pain patients with monosegmental degenerative disc disease. *Br J Radiol.* 2011;84:709-713. doi:10.1259/bjr/58136533
 29. Hyun JK, Lee JY, Lee SJ, Jeon JY. Asymmetric atrophy of multifidus muscle in patients with unilateral lumbosacral radiculopathy. *Spine (Phila Pa 1976).* 2007;32:E598-E602. doi:10.1097/BRS.0b013e318155837b
 30. Battie MC, Niemelainen R, Gibbons LE, Dhillon S. Is level- and side-specific multifidus asymmetry a marker for lumbar disc pathology? *Spine J.* 2012;12:932-939. doi:10.1016/j.spinee.2012.08.020
 31. Zotti MGT, Boas FV, Clifton T, Piche M, Yoon WW, Freeman BJC. Does pre-operative magnetic resonance imaging of the lumbar multifidus muscle predict clinical outcomes following lumbar spinal decompression for symptomatic spinal stenosis? *Eur Spine J.* 2017;26:2589-2597. doi:10.1007/s00586-017-4986-x
 32. Kader DF, Wardlaw D, Smith FW. Correlation between the MRI changes in the lumbar multifidus muscles and leg pain. *Clin Radiol.* 2000;55:145-149. doi:10.1053/crad.1999.0340
 33. Betz M, Burgstaller JM, Held U, et al; LSOS Study Group. Influence of paravertebral muscle quality on treatment efficacy of epidural steroid infiltration or surgical decompression in lumbar spinal stenosis—analysis of the Lumbar Spinal Outcome Study (LSOS) Data: a Swiss Prospective Multicenter Cohort Study. *Spine (Phila Pa 1976).* 2017;42:1792-1798. doi:10.1097/BRS.0000000000002233
 34. Goutallier D, Postel JM, Bernageau J, Lavau L, Voisin MC. Fatty muscle degeneration in cuff ruptures. Pre- and postoperative evaluation by CT scan. *Clin Orthop Relat Res.* 1994;(304):78-83.
 35. Tamai K, Chen J, Stone M, et al. The evaluation of lumbar paraspinal muscle quantity and quality using the Goutallier classification and lumbar indentation value. *Eur Spine J.* 2018;27(5):1005-1012. doi:10.1007/s00586-018-5485-4
 36. Arts M, Brand R, van der Kallen B, Lycklama à Nijeholt G, Peul W. Does minimally invasive lumbar disc surgery result in less muscle injury than conventional surgery? A randomized controlled trial. *Eur Spine J.* 2011;20:51-57. doi:10.1007/s00586-010-1482-y
 37. Storheim K, Berg L, Hellum C, et al; Norwegian Spine Study Group. Fat in the lumbar multifidus muscles—predictive value and change following disc prosthesis surgery and multidisciplinary rehabilitation in patients with chronic low back pain and degenerative disc: 2-year follow-up of a randomized trial. *BMC Musculoskelet Disord.* 2017;18:145. doi:10.1186/s12891-017-1505-5
 38. Yagi M, Hosogane N, Watanabe K, Asazuma T, Matsumoto M; Keio Spine Research Group. The paravertebral muscle and psoas for the maintenance of global spinal alignment in patient with degenerative lumbar scoliosis. *Spine J.* 2016;16:451-458. doi:10.1016/j.spinee.2015.07.001
 39. Choi MK, Kim SB, Park CK, Malla HP, Kim SM. Cross-sectional area of the lumbar spine trunk muscle and posterior lumbar interbody fusion rate: a retrospective study. *Clin Spine Surg.* 2017;30:E798-E803. doi:10.1097/BSD.0000000000000424
 40. Choi MK, Kim SB, Park BJ, Park CK, Kim SM. Do trunk muscles affect the lumbar interbody fusion rate? Correlation of trunk muscle cross sectional area and fusion rates after posterior lumbar interbody fusion using stand-alone cage. *J Korean Neurosurg Soc.* 2016;59:276-281. doi:10.3340/jkns.2016.59.3.276
 41. Lee JH, Lee SH. Does lumbar paraspinal muscles improve after corrective fusion surgery in degenerative flat back? *Indian J Orthop.* 2017;51:147-154. doi:10.4103/0019-5413.201713
 42. Kim JY, Ryu DS, Paik HK, et al. Paraspinal muscle, facet joint, and disc problems: risk factors for adjacent segment degeneration after lumbar fusion. *Spine J.* 2016;16:867-875. doi:10.1016/j.spinee.2016.03.010
 43. Ranson CA, Burnett AF, Kerslake R, Batt ME, O'Sullivan PB. An investigation into the use of MR imaging to determine the functional cross sectional area of lumbar paraspinal muscles. *Eur Spine J.* 2006;15:764-773. doi:10.1007/s00586-005-0909-3