

9-5-2022

Recurrent Giant Cell Myocarditis After Heart Transplant: A Case Report

Eitan S. Frankel

Alexander G. Hajduczuk

Indranee N. Rajapreyar

Yevgeniy Brailovsky

Follow this and additional works at: <https://jdc.jefferson.edu/cardiologyfp>



Part of the [Cardiology Commons](#), and the [Surgery Commons](#)

[Let us know how access to this document benefits you](#)

This Article is brought to you for free and open access by the Jefferson Digital Commons. The Jefferson Digital Commons is a service of Thomas Jefferson University's [Center for Teaching and Learning \(CTL\)](#). The Commons is a showcase for Jefferson books and journals, peer-reviewed scholarly publications, unique historical collections from the University archives, and teaching tools. The Jefferson Digital Commons allows researchers and interested readers anywhere in the world to learn about and keep up to date with Jefferson scholarship. This article has been accepted for inclusion in Division of Cardiology Faculty Papers by an authorized administrator of the Jefferson Digital Commons. For more information, please contact: JeffersonDigitalCommons@jefferson.edu.

Recurrent giant cell myocarditis after heart transplant: a case report

Eitan S. Frankel, Alexander G. Hajduczuk *, Indranee N. Rajapreyar, and Yevgeniy Brailovsky

Division of Cardiology, Jefferson Heart Institute, Sidney Kimmel School of Medicine, Thomas Jefferson University Hospital, 925 Chestnut Street, Suite 200, Philadelphia, PA 19107, USA

Received 21 January 2022; first decision 11 March 2022; accepted 30 August 2022; online publish-ahead-of-print 5 September 2022

Background

Giant cell myocarditis (GCM) is a rare but well-known cause of fulminant myocarditis. Despite optimal medical therapy, many patients progress to orthotopic heart transplant (OHT). We present a case of recurrent GCM following OHT, including complex considerations in patient management and infectious sequelae.

Case summary

A 33-year-old previously healthy male presented with 2 months of worsening shortness of breath. Transthoracic echocardiogram (TTE) demonstrated a left ventricular ejection fraction of 30–35%. After ruling out an ischaemic aetiology, he was discharged on guideline-directed medical therapy and later presented with productive cough, worsening dyspnoea on exertion, and diarrhoea. He was found to have elevated troponins and N-terminal pro-brain natriuretic peptide, lactic acidosis, progression of severe bi-ventricular dysfunction on TTE and right heart catheterization, and low cardiac index (1.0 L/min/m²) requiring inotropes. He then required left ventricular assist device as a bridge to OHT. Pathology of the apical core diagnosed GCM as the cause of his fulminant heart failure. He eventually underwent heart transplantation, which was complicated by recurrent GCM. Treatment required intensification of his immunosuppressive regimen, which led to multiple infectious sequelae including norovirus, Shiga-like toxin producing *Escherichia coli*, and disseminated nocardia of the lung and brain. As of the most recent follow-up, the patient is currently clinically stable.

Discussion

Although recurrent GCM after OHT has been reported in the literature, the prognosis is not well understood and there are no clear guidelines regarding management. This case summarizes clinical considerations, treatment strategies, and adverse effects of recurrent GCM treatment.

Keywords

Giant cell myocarditis • Heart transplant • Case report • Immunosuppression • Left ventricular assist device • Recurrent infection

ESC curriculum

6.2 Heart failure with reduced ejection fraction • 6.5 Cardiomyopathy • 6.1 Symptoms and signs of heart failure • 6.4 Acute heart failure • 6.7 Right heart dysfunction

Learning points

- Recurrent giant cell myocarditis (GCM) post-orthotopic heart transplant (OHT) necessitates intensification of immunosuppressive therapy, usually with pulse dose methylprednisolone and a prolonged steroid taper.
- Intensification of immunosuppression to treat GCM post-OHT carries significant risks of infection and malignancy.
- Reported cases of recurrent GCM has increased with increasing rates of heart transplant, but the optimal treatment regimen requires further study.

* Corresponding author. Tel: +1 (215) 955-5050, Fax: +1 (215) 503-0052, Email: alexander.hajduczuk@jefferson.edu

Handling Editor: Marta Cvijic

Peer-reviewers: Emilia D'Elia; Giulia Elena Mandoli; Maria Concetta Pastore

Compliance Editor: Omar Abdelfattah

Supplementary Material Editor: Ameenathul Mazaya Fawzy

© The Author(s) 2022. Published by Oxford University Press on behalf of the European Society of Cardiology.

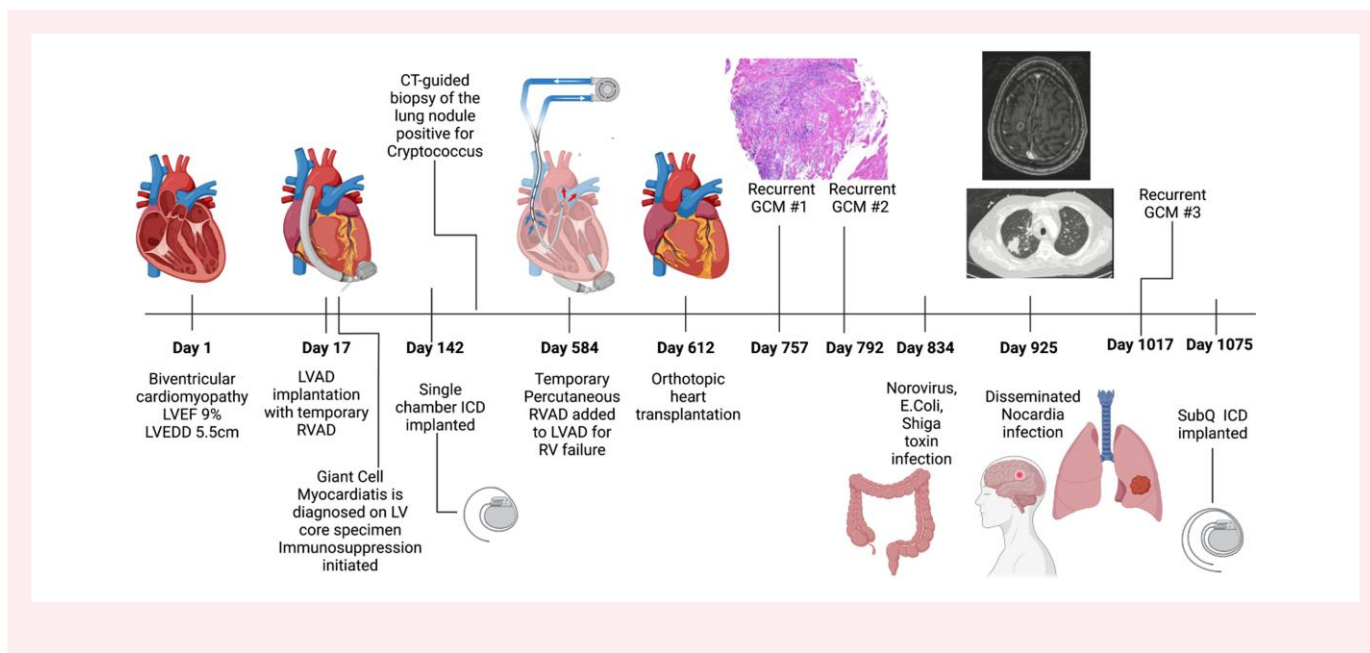
This is an Open Access article distributed under the terms of the Creative Commons Attribution-NonCommercial License (<https://creativecommons.org/licenses/by-nc/4.0/>), which permits non-commercial re-use, distribution, and reproduction in any medium, provided the original work is properly cited. For commercial re-use, please contact journals.permissions@oup.com

Introduction

Giant cell myocarditis (GCM) is a rare but well-known cause of fulminant myocarditis. Without treatment, the median survival is 5.5 months.¹ Combination immunosuppressive therapy has led to improvements in survival and has become the standard treatment.^{2,3} Despite optimal medical therapy, many patients progress to orthotopic heart transplant (OHT). This case demonstrates many dilemmas that clinicians face in treating recurrent GCM, including complex diagnostic and therapeutic considerations, infectious complications, and lack of clear management guidelines.

While OHT offers the best chance of cure, there is still a risk of recurrence. In one registry, 9/34 (26%) of patients transplanted for GCM recurred at an average of 3 years post-transplant.¹ In another multicenter registry, 9/38 (24%) patients had a recurrence of GCM after transplant.⁴ Unlike the initial GCM presentation, which often progresses irrespective of therapy, recurrent GCM after OHT seems to have a different disease progression, and optimal management strategy is unclear. As seen in this case, recurrent GCM post-OHT may be discovered in asymptomatic patients during a routine endomyocardial biopsy (EMB) without overt heart failure or graft dysfunction. These patients tend to respond well to intensification of immunosuppression and repeat biopsies frequently demonstrate resolution of GCM. These patients are, however, at greater risk of subsequent infection due to their immunocompromised state.

Timeline



Case presentation

A 33-year-old male previously presented to another institution with 2 months of worsening shortness of breath. Echocardiogram demonstrated a left ventricular ejection fraction (LVEF) of 30–35%. Left heart catheterization revealed normal coronary anatomy and right heart catheterization showed reduced cardiac output. Cardiac magnetic resonance imaging (MRI) was non-diagnostic due to patient's inability to hold his breath. He was previously discharged on guideline-directed medical therapy without a clear aetiology to explain his

cardiomyopathy. He now presents with a productive cough, worsening dyspnoea on exertion, and diarrhoea.

The patient had no known past medical history. He emigrated from Honduras to the USA 15 years ago. He had no history of tobacco, drug, or alcohol use, and no known tuberculosis exposures, history of rheumatic fever, or family history of cardiovascular disease. Physical exam was notable for elevated jugular venous pulse, an S3 heart sound, rales on lung auscultation, abdominal tenderness, and bilateral lower extremity oedema.

Laboratory testing was notable for high sensitivity troponin T 216 ng/L (ref <19), NTproBNP 8403 pg/mL (ref <125), aspartate transaminase 56 IU/L, alanine transaminase 112 IU/L, and lactate 3.3 mmol/L. Additional workup included drug screening, iron studies, human immunodeficiency virus testing, hepatitis testing, Trypanosoma Cruzi antibodies, stool studies, quantiferon, antinuclear antibody, thiamine, selenium, and carnitine, which were all negative.

Echocardiography showed mild left ventricular enlargement (left ventricular internal diameter end diastole 5.5 cm), severely reduced LV systolic function with global hypokinesis (LVEF 9%), severely reduced right ventricular (RV) function, biatrial dilation, and severe tricuspid regurgitation with estimated pulmonary artery (PA) systolic pressure of 43 mmHg. Right heart catheterization revealed right atrium 18 mmHg, right ventricle 35/18 mmHg, PA 35/25 (mean 28) mmHg, pulmonary capillary wedge pressure 23 mmHg. Cardiac output 1.8 L/min, cardiac index 1 L/min/m², pulmonary vascular resistance 2.78 Woods units, and systemic vascular resistance 1798 Dynes.

Differential diagnosis for aetiology of nonischaemic cardiomyopathy in this patient included infectious cardiomyopathy (i.e. Chagas or viral myocarditis), genetic cardiomyopathy, and toxic cardiomyopathy.

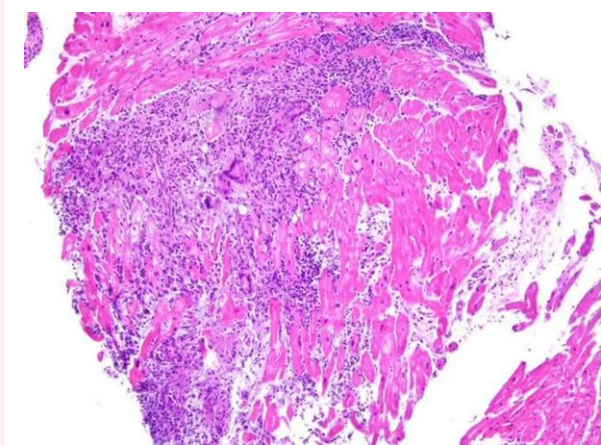


Figure 1 Pathology sample from apical core demonstrating giant cell myocarditis.

Despite immunosuppressive therapy, with tacrolimus and prednisone, the patient developed worsening RV failure manifested by low flow alarms and ventricular arrhythmias (VAs). Eighteen months after LVAD implantation, he developed RV failure requiring placement of a temporary RVAD and expedited transplant evaluation. His transplant listing was further complicated by an incidental lung nodule on computerized tomography (CT), which was positive for cryptococcus, requiring treatment with fluconazole. After 6 weeks of cryptococcus treatment followed by repeat CT imaging showing stable disease, he underwent OHT with basiliximab induction and was initiated on maintenance immunosuppression with tacrolimus, mycophenolate, and prednisone. Pathology of the explanted heart confirmed GCM with prominent myocardial fibrosis and intracardiac and PA thrombi.

Post-discharge, surveillance EMB 6 weeks after transplant demonstrated recurrent GCM (Figures 2). The patient had mild LV dysfunction but no other evidence of graft failure. After discussion with a multidisciplinary team including cardiothoracic surgery, cardiology, infectious disease, and pharmacy, he was treated with pulse dose steroids and increased dosing of maintenance immunosuppression (tacrolimus, mycophenolate, and prednisone). Repeat EMB 1 week after treatment did not show evidence of GCM. The patient continued to undergo surveillance EMB and was treated for 2R rejection 10 weeks after transplant with prednisone 100 mg for 3 days. Five months after the initial positive biopsy, he had recurrent GCM (Figures 2). He was treated with pulse dose steroids with the addition of anti-thymocyte globulin (ATG) with a cumulative dose of 4 mg/kg given over 8 days. He continued a three-drug immunosuppression regimen of tacrolimus (goal trough 10–15), mycophenolate (1500 mg twice a day), and prednisone (slow taper).

With the intensification of immunosuppression, the patient developed significant infectious sequelae. He developed several courses of diarrhoea (Enteraggregative *Escherichia coli*, norovirus, and Shiga-like toxin producing *E. coli*) and subsequently presented with decreased oral intake, weakness, and paroxysmal nocturnal dyspnoea. Computerized tomography of the chest demonstrated a cavitary right upper lobe lesion (Figure 3A), and MRI of the brain showed a contrast-enhancing lesion concerning for abscesses (Figure 4). Transbronchial needle aspiration of a lymph node demonstrated baciliform structures with positive acid fast bacilli stain and cultures confirmed *Nocardia Asiatica* (Figure 3B). A multidisciplinary consensus involving neurosurgery and infectious disease was to manage

Table 1. Post-OHT Biopsy Results

<i>Biopsy</i>	<i>ACR</i>
1 week	0
2 week	0
3 week	1R
4 week	0
6 week	0*
8 week	1R
10 week	2R
11 week	0
13 week	1R
16 week	0
24 week	0**
28 week	0
32 week	0
36 week	1R
46 week	***
* <i>First recurrence GCM</i>	
** <i>Second recurrence GCM</i>	
*** <i>Third recurrence GCM</i>	

Figure 2 Endomyocardial biopsy results (rejection classification, giant cell myocarditis).

disseminated nocardia with prolonged antibiotics, decreased immunosuppression (prednisone and mycophenolate), and interval surveillance with imaging.

While the patient was being treated for *Nocardia* infection, surveillance EMB demonstrated a third recurrence of GCM (Figures 2). Given significant infectious sequelae, high-dose prednisone was avoided and sirolimus was added to tacrolimus, mycophenolate, and prednisone.

This patient is doing well and followed in heart transplantation clinic with close attention to cardiac allograft function and further infectious complications. In particular, he is undergoing frequent clinical examinations, echocardiograms, laboratory monitoring of cardiac injury, biopsies, and monitoring of infectious complications.

Discussion

We present a case of severe GCM necessitating durable LVAD support as a bridge to heart transplantation, complicated by recurrent GCM and infectious sequelae of intensification of immunosuppression.

Initial diagnosis of GCM should be suspected in patients presenting with acute cardiogenic shock and incessant VA, however, clinical presentation can vary and maintaining high clinical suspicion is imperative. Interestingly, in our patient, diagnosis of GCM was established only at the time of LVAD implantation on pathological examination of LV core. Management of GCM is challenging and patients often progress despite intense immunosuppressive therapy requiring rapid escalation of mechanical circulatory support and heart transplantation.⁵

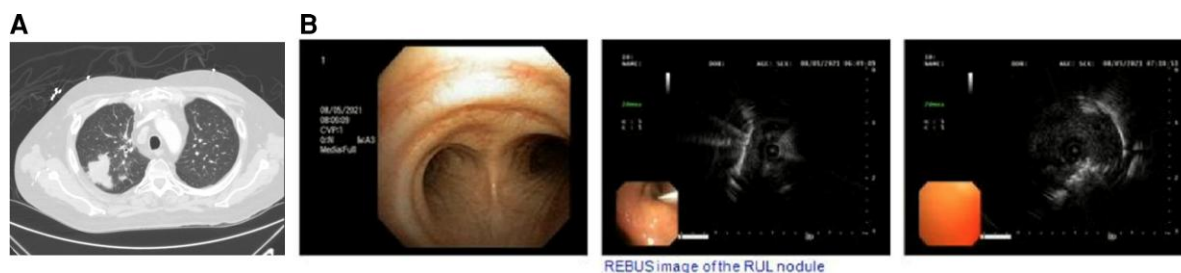


Figure 3 Computerized tomography chest demonstrating RUL nodule visualized by computerized tomography chest (A) and endobronchial ultrasound (B).

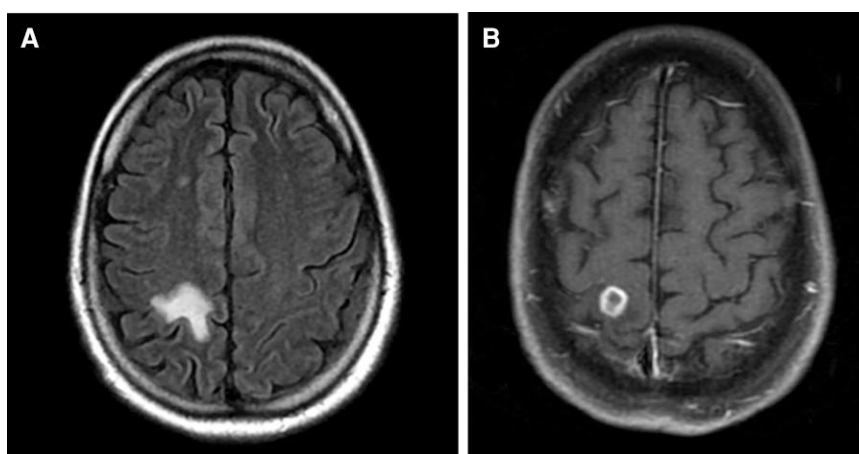


Figure 4 Magnetic resonance imaging of the brain demonstrating a contrast-enhancing lesion in the right parietal lobe, with (A) and without (B) vasogenic edema.

Recurrence of GCM after OHT is relatively common, but natural history and optimal therapy are less well understood. Although it is thought that recurrent GCM in a transplanted heart necessitates intensification of immunosuppressive therapy, it must be counterbalanced by increased risk of infection and malignancy. Most patients are initially treated with pulse dose methylprednisolone and a prolonged steroid taper. If GCM does not resolve or recurs, more aggressive immunosuppression with ATG can be utilized. There are also case reports using sirolimus, rituximab, and alemtuzumab.^{6–8} While sirolimus was attempted in our patient, it is important to note that no treatment for recurrent GCM has been studied prospectively.

Intensification of immunosuppression to treat GCM post-OHT carries significant risks of infection as occurred in our patient. Given multiple recurrences, our patient received several courses of pulse steroids (IV methylprednisolone), intensification of his immunosuppressive regimen (tacrolimus, mycophenolate, prednisone, and sirolimus), and ATG. This led to severe infectious complications including cryptococcus, Enterococci, *Enterobacteriaceae*, *Enterotoxigenic E. coli*, norovirus, and disseminated *Nocardia* that required antibiotic treatment and modification of immunosuppression. It is vital that modifications to immunosuppression are made by a multidisciplinary team including members from cardiothoracic surgery, advanced heart failure, infectious disease, and pharmacy.

As the number of patients who have been transplanted for GCM grows, so too does the number of reported cases of recurrent GCM. When GCM was initially described, it was a rare entity without good treatment options. Multicenter registries helped define the disease and randomized trials helped develop treatment paradigms.^{1,2,4} While there are case reports suggesting possible treatment strategies for recurrent GCM after an OHT, future studies are needed to develop a more standardized treatment algorithm.

Other treatment consideration in patients with GCM is VAs. There is increased propensity for VAs associated with GCM in native heart, but incidence of VA post-OHT is not well known. Given multiple recurrences of GCM post-OHT in our patient we conducted a multidisciplinary discussion with electrophysiology and heart failure specialists and decision was to implant subcutaneous ICD for primary prevention.

Conclusions

Recurrent GCM after OHT is not uncommon. Unlike GCM in a native heart, prognosis of recurrent GCM after OHT is not well understood. Given that OHT presents the best treatment option for GCM, it should not be withheld for fear of recurrence. Further research is needed to identify the optimal treatment regimen for recurrent GCM and better

understand the risks associated with the intensification of immunosuppression.

Lead author biography



Dr Frankel is a second year Cardiology Fellow at Thomas Jefferson University Hospital where he is the Louis R. Dinon Chief Fellow. He completed his residency training at Thomas Jefferson University Hospital and medical school at the University of Illinois College of Medicine. He is interested in pursuing a career in electrophysiology and is interested in the complex rhythms found among patients with cardiomyopathies.

Supplementary material

Supplementary material is available at *European Heart Journal – Case Reports* online.

Acknowledgments

We would like to thank Arwa M Omary, PharmD, Mahek Shah, MD, Indranee Rajapreyar, MD, Rene Alvarez, MD, Jesus E Rame, MD, Jennifer M Clifford, MD, Howard T Massey, MD, and Eugene Storozynsky, MD, PhD, along with the house staff, nurses, transplant team members, respiratory therapists, and physical therapists for their discussions and care related to this complex patient.

Slide sets: A fully edited slide set detailing this case and suitable for local presentation is available online as Supplementary data.

Consent: The authors confirm that consent for submission and publication of this case report including images and associated text has been obtained from the patient in line with COPE guidance.

Conflict of interest: The authors of this publication certify that they have no affiliations with or involvement with any organization with any financial interest in the subject matter discussed.

Funding

No grants, contracts, or other forms of financial support funded this research.

References

1. Cooper LT, Berry GJ, Shabetai R. Idiopathic giant-cell myocarditis—natural history and treatment. *N Engl J Med* 1997;**336**:1860–1866.
2. Cooper LT, Hare JM, Tazelaar HD, Edwards WD, Starling RC, Deng MC, Menon S, et al. Usefulness of immunosuppression for giant cell myocarditis. *Am J Cardiol* 2008;**102**:1535–1539.
3. Bang V, Ganatra S, Shah SP, Dani SS, Neilan TG, Thaveniranathan P, et al. Management of patients with giant cell myocarditis. *J Am Coll Cardiol* 2021;**77**:1122–1134.
4. Scott RL, Ratliff NB, Starling RC, Young JB. Recurrence of giant cell myocarditis in cardiac allograft. *J Heart Lung Transplant* 2001;**20**:375–380.
5. Brailovsky Y, Masoumi A, Bijou R, Oliveros E, Sayer G, Takeda K, Uriel N. Fulminant giant cell myocarditis requiring bridge with mechanical circulatory support to heart transplantation. *JACC Case Rep* 2022;**4**:265–270.
6. Patel AD, Lowes B, Chamsi-Pasha MA, Radio SJ, Hyden M, Zolty R. Sirolimus for recurrent giant cell myocarditis after heart transplantation: a unique therapeutic strategy. *Am J Ther* 2019;**26**:600–603.
7. Toscano G, Tartaro P, Fedrigo M, Angelini A, Marcolongo R. Rituximab in recurrent idiopathic giant cell myocarditis after heart transplantation: a potential therapeutic approach. *Transpl Int* 2014;**27**:e38–42.
8. Evans JD, Pettit SJ, Goddard M, Lewis C, Parameshwar JK. Alemtuzumab as a novel treatment for refractory giant cell myocarditis after heart transplantation. *J Heart Lung Transplant* 2016;**35**:256–258.