

2-1-2021

White paper on ophthalmic imaging for choroidal nevus identification and transformation into Melanoma

Carol Shields

Ocular Oncology Service, Wills Eye Hospital, Thomas Jefferson University, Philadelphia, PA, USA

Sara E. Lally

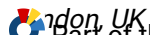Ocular Oncology Service, Wills Eye Hospital, Thomas Jefferson University, Philadelphia, PA, USA

Lauren Dalvin

Department of Ophthalmology, Mayo Clinic, Rochester, MN, USA

Mandeep Sagoo

Ocular Oncology Service, Moorfields Eye Hospital and NIHR Biomedical Research Centre for Ophthalmology and Moorfields Eye Hospital and University College London Institute of Ophthalmology, London, UK
<https://jdc.jefferson.edu/willsfp/>
Part of the [Ophthalmology Commons](#)



Let us know how access to this document benefits you

Marco Pellegrini
Eye Clinic, Department of Biomedical and Clinical Science "Luigi Sacco", Luigi Sacco Hospital, University of Milan, Milan, Italy

Recommended Citation

Shields, Carol; Lally, Sara E.; Dalvin, Lauren; Sagoo, Mandeep; Pellegrini, Marco; Kaliki, Swathi; Gunduz, Ahmet Kaan; Furuta, Minoru; Mruthyunjaya, Prithvi; Fung, Adrian T.; Duker, Jay S.; Selig, Sara M.; Yaghy, Antonio; Ferenczy, Sandor R.; Eydelman, Malvina B.; and Blumenkranz, Mark S., "White paper on ophthalmic imaging for choroidal nevus identification and transformation into Melanoma" (2021). *Wills Eye Hospital Papers*. Paper 122.
<https://jdc.jefferson.edu/willsfp/122>

This Article is brought to you for free and open access by the Jefferson Digital Commons. The Jefferson Digital Commons is a service of Thomas Jefferson University's [Center for Teaching and Learning \(CTL\)](#). The Commons is a showcase for Jefferson books and journals, peer-reviewed scholarly publications, unique historical collections from the University archives, and teaching tools. The Jefferson Digital Commons allows researchers and interested readers anywhere in the world to learn about and keep up to date with Jefferson scholarship. This article has been accepted for inclusion in Wills Eye Hospital Papers by an authorized administrator of the Jefferson Digital Commons. For more information, please contact: JeffersonDigitalCommons@jefferson.edu.

Authors

Carol Shields, Sara E. Lally, Lauren Dalvin, Mandeep Sagoo, Marco Pellegrini, Swathi Kaliki, Ahmet Kaan Gündüz, Minoru Furuta, Prithvi Mruthyunjaya, Adrian T. Fung, Jay S. Duker, Sara M. Selig, Antonio Yaghy, Sandor R. Ferenczy, Malvina B. Eydelman, and Mark S. Blumenkranz

White Paper on Ophthalmic Imaging for Choroidal Nevus Identification and Transformation into Melanoma

Carol L. Shields¹, Sara E. Lally¹, Lauren A. Dalvin², Mandeep S. Sagoo³, Marco Pellegrini⁴, Swathi Kaliki⁵, Ahmet Kaan Gündüz⁶, Minoru Furuta⁷, Prithvi Mruthyunjaya⁸, Adrian T. Fung⁹, Jay S. Duker¹⁰, Sara M. Selig¹¹, Antonio Yaghy¹, Sandor R. Ferenczy¹, Malvina B. Eydelman¹², and Mark S. Blumenkranz¹³

¹ Ocular Oncology Service, Wills Eye Hospital, Thomas Jefferson University, Philadelphia, PA, USA

² Department of Ophthalmology, Mayo Clinic, Rochester, MN, USA

³ Ocular Oncology Service, Moorfields Eye Hospital and NIHR Biomedical Research Centre for Ophthalmology at Moorfields Eye Hospital and University College London Institute of Ophthalmology, London, UK

⁴ Eye Clinic, Department of Biomedical and Clinical Science "Luigi Sacco", Luigi Sacco Hospital, University of Milan, Milan, Italy

⁵ The Operation Eyesight Universal Institute for Eye Cancer, LV Prasad Eye Institute, Hyderabad, India

⁶ Department of Ophthalmology, Ankara University School of Medicine, Ankara, Turkey

⁷ Department of Ophthalmology, Fukushima Medical University, Fukushima, Japan and Department of Ophthalmology, Yachiyo Medical Center, Tokyo Women's Medical University, Tokyo, Japan

⁸ Ocular Oncology Service, Department of Ophthalmology, Byers Eye Institute, Stanford University, Palo Alto, CA, USA

⁹ Westmead and Central Clinical Schools, Discipline of Clinical Ophthalmology and Eye Health, University of Sydney, Australia and Department of Ophthalmology, Faculty of Medicine, Health and Human Sciences, Macquarie University, Sydney, Australia

¹⁰ New England Eye Center, Tufts Medical Center, Tufts University School of Medicine, Boston, MA, USA

¹¹ Melanoma Research Foundation, Washington, DC, USA

¹² Office of Ophthalmic, Anesthesia, Respiratory, Ear, Nose and Throat (ENT), and Dental Devices, Food & Drug Administration (FDA), Washington, DC

¹³ Department of Ophthalmology, Ophthalmology Innovation Program, Byers Eye Institute, Stanford University, Palo Alto, CA, USA

Correspondence: Carol L. Shields, Ocular Oncology Service, Suite 1440, Wills Eye Hospital, 840 Walnut Street, Philadelphia, PA 19107, USA. e-mail: carolshields@gmail.com

Received: October 5, 2020

Accepted: January 3, 2021

Published: February 17, 2021

Keywords: artificial intelligence; multimodal imaging; choroid; nevus; melanoma

Citation: Shields CL, Lally SE, Dalvin LA, Sagoo MS, Pellegrini M, Kaliki S, Gündüz AK, Furuta M, Mruthyunjaya P, Fung AT, Duker JS, Selig SM, Yaghy A, Ferenczy SR, Eydelman MB, Blumenkranz MS. White paper on ophthalmic imaging for choroidal nevus identification and transformation into melanoma. *Trans Vis Sci Tech.* 2021;10(2):24, <https://doi.org/10.1167/tvst.10.2.24>

Purpose: To discuss the evolution of noninvasive diagnostic methods in the identification of choroidal nevus and determination of risk factors for malignant transformation as well as introduce the novel role that artificial intelligence (AI) can play in the diagnostic process.

Methods: White paper.

Results: Longstanding diagnostic methods to stratify benign choroidal nevus from choroidal melanoma and to further determine the risk for nevus transformation into melanoma have been dependent on recognition of key clinical features by ophthalmic examination. These risk factors have been derived from multiple large cohort research studies over the past several decades and have garnered widespread use throughout the world. More recent publications have applied ocular diagnostic testing (fundus photography, ultrasound examination, autofluorescence, and optical coherence tomography) to identify risk factors for the malignant transformation of choroidal nevus based on multimodal imaging features. The widespread usage of ophthalmic imaging systems to identify and follow choroidal nevus, in conjunction with the characterization of malignant transformation risk factors via diagnostic imaging, presents a novel path to apply AI.

Conclusions: AI applied to existing ophthalmic imaging systems could be used for both identification of choroidal nevus and as a tool to aid in earlier detection of transformation to malignant melanoma.

Translational Relevance: Advances in AI models applied to ophthalmic imaging systems have the potential to improve patient care, because earlier detection and treatment of melanoma has been proven to improve long-term clinical outcomes.

Introduction

Choroidal nevus is the most common primary intraocular tumor.¹ Based on several studies, the overall prevalence of choroidal nevus in the adult population ranges from 5% to 25%.²⁻⁷ Choroidal nevus is often found incidentally on routine ophthalmic funduscopic examination. This lesion typically occurs as a well-circumscribed pigmented or nonpigmented lesion, residing deep to the retina within the choroid and measuring <2 mm in thickness and <5 mm in diameter. This lesion carries two important risks, including vision loss, particularly if the mass is subfoveal; more important, a benign nevus can transform into malignant melanoma, with the potential for melanoma-related metastasis and death.

Similar to a cutaneous nevus, a choroidal nevus can slowly change over time and such change might not necessarily be a harbinger of malignant transformation. In 2008, Shields et al.⁸ evaluated 3422 eyes with choroidal nevus and found that the following parameters change over time, including number of nevi per eye, nevus thickness, and nevus-related overlying drusen. In addition, choroidal nevus can slowly and minimally enlarge over time and still maintain benign behavior. Mashayekhi et al.⁹ documented that 31% of choroidal nevi demonstrate slight enlargement over 7 to 10 years without clinical evidence of transformation into melanoma and this is more often noted in younger compared to older patients.

Choroidal nevus can be divided into low risk and high risk for future growth into melanoma based on clinical features. Low risk clinical features include overlying drusen or retinal pigment epithelial (RPE) alterations, both implying a long-standing mass with overlying chronic degeneration (Fig. 1). In 1995, an early study showed high-risk clinical features to include thickness of >2 mm, the presence of overlying subretinal Fluid, presence of Symptoms, presence of overlying Orange pigment, and tumor location near the optic disc Margin, which can be remembered by the mnemonic “*To Find Small Ocular Melanoma*” (TFSOM) (Fig. 2).¹⁰ In 2000, various combinations of high-risk features were evaluated, with the greatest risk for transformation into melanoma at 63%, found with the combination of three features, including a thickness of >2 mm, the presence of subretinal fluid, and a tumor margin near the optic disc.¹¹ A later follow-up study of >2500 choroidal nevi continued to refine the high risk clinical factors for transformation into melanoma including greater Thickness, subretinal Fluid, Symptoms, Orange pigment, Margin near disc, and additionally with three new features: Ultrasound

Hollowness, absence of Halo and absence of Drusen, creating a new mnemonic “*To Find Small Ocular Melanoma - Using Helpful Hints Daily*” (TFSOM - UHHD). A combination of any three factors posed a mean risk of >50% for transformation.¹²

Singh et al.¹³ calculated the rate for transformation of choroidal nevus into melanoma in the United States population at 1 in 8845, but with the assumption that all choroidal melanoma arises from a preexisting nevus, which might not be the case. Kivelä and Eskelin¹⁴ calculated that the lifetime risk for transformation of nevus to melanoma by age 80 years of age approached 1%. Therefore, the over-riding goal is to detect choroidal nevus and follow periodically (semianually or annually) for evidence of risk factors for transformation or for documentation of growth into melanoma, both necessitating intervention with eradication of the lesion. If the pigmented lesion is choroidal melanoma at the time of detection, identification of the tumor at a tiny or small stage would be ideal as increasing size increases the risk for metastasis (Fig. 3). Shields et al.¹⁵ reviewed 8033 cases of uveal melanoma and noted that each millimeter of increasing thickness added a 5% risk for melanoma metastasis at 10 years (Fig. 4). For example, a melanoma measuring 0 to 1 mm thickness demonstrated approximately 5% rate of metastasis, those measuring 4 to 5 mm thickness showed approximately 25% rate, and those of ≥10 mm showed a >50% rate of metastasis.¹⁵ Clinical recognition and detection of small melanoma is key to prevention of metastasis and death. There is no known cure for metastasis.

What Have We Learned from Cutaneous Melanoma?

The word melanoma causes one to think of skin (cutaneous) melanoma. Approximately 90% to 95% of all melanomas are found in the skin. Cutaneous melanoma is well-publicized and is increasing in frequency, mostly owing to overexposure to solar radiation. Cutaneous melanoma also has the potential to lead to metastasis and death. Cutaneous melanoma generally arises on sun-exposed areas of the body, with ultraviolet radiation exposure being the main risk factor for development.¹⁶⁻¹⁹ Lesser known, the eye (uvea [iris, ciliary body, and choroid]) is the second most frequent location of malignant melanoma in the body, representing about 5% of all melanomas. Although cutaneous and uveal melanoma are two distinct diseases and one does not lead to the other, both occur most often in patients with fair skin

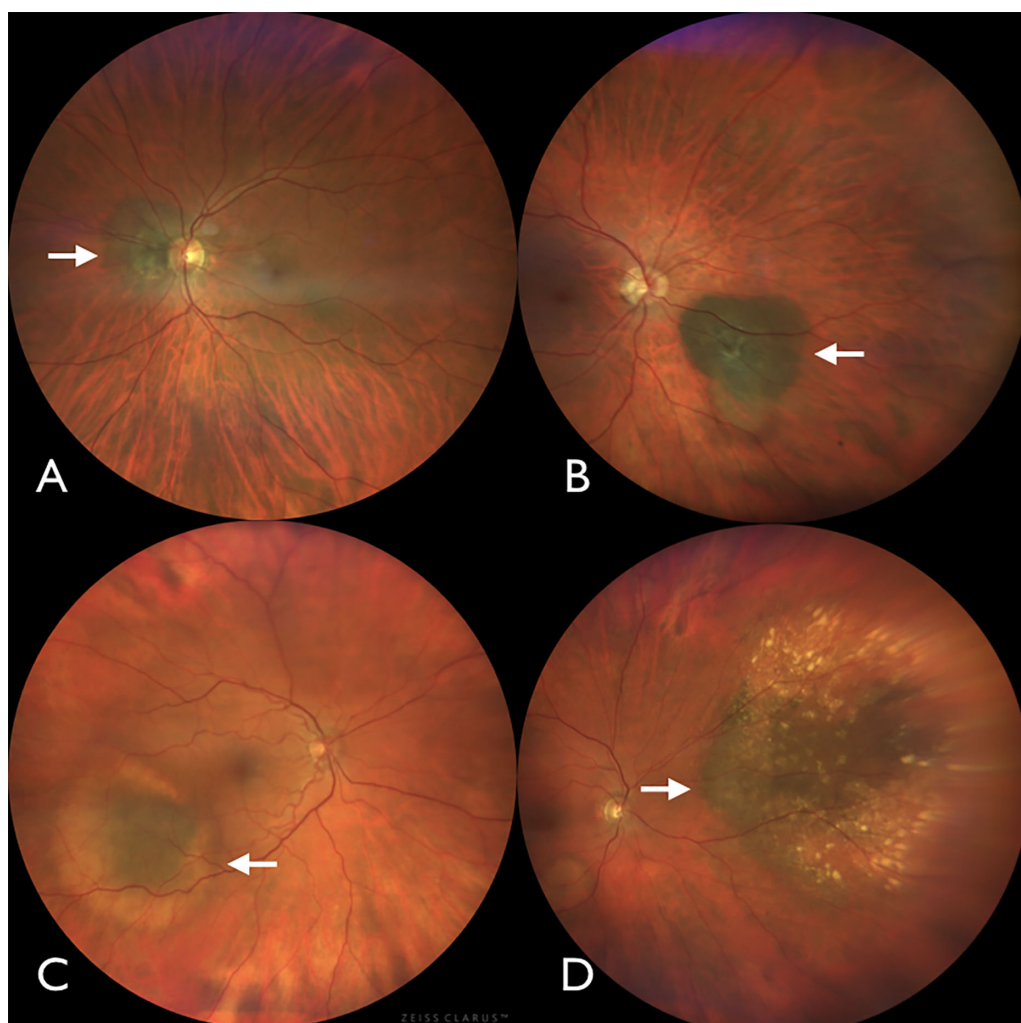


Figure 1. Spectrum of benign choroidal nevus. (A) Choroidal nevus (arrow) near the optic disc with overlying RPE atrophy. (B) Choroidal nevus (arrow) nasal to the optic disc with overlying and dependent RPE atrophy. (C) Choroidal nevus (arrow) inferotemporal to the macula with surrounding yellow halo. (D) Large choroidal nevus (arrow) nasal to the optic disc with overlying yellow drusen.

complexion and blue or green eyes. Uveal melanoma has not clearly been found to be related to sunlight exposure, but similar to cutaneous melanoma, uveal melanoma can arise from a preexisting nevus or de novo.¹⁶ For both diseases, early detection is key for survival.

In 2004, Lindholm et al.¹⁷ documented that early cutaneous melanoma (<1 mm in thickness) had a 5-year survival of rate of 94% and this decreased to 49% in those with a thickness of >4 mm. Major advances in the dermatology (skin) literature have helped in early detection of cutaneous melanoma. The mnemonic ABCDE (Asymmetry, Border irregularity, Color, Diameter >6 mm, Evolving size, shape, or color) simplified the key features of early cutaneous melanoma and helped physicians and nonphysicians diagnose suspicious lesions before they grew.¹⁸ Skin self-examination has helped to

improve the early detection of cutaneous melanoma.¹⁹ Further advances with the use of instruments like dermoscopy, a handheld device that allows magnified, high-resolution visualization of the skin, has also improved detection.²⁰ Automated computer-assisted differentiation has provided 95% sensitivity and 70% specificity.²⁰

Malignant melanoma of the eye occurs in the uveal tissue, which encompasses the iris, ciliary body, and choroid. This tract is a specialized vascularized tissue that manifests pigmented melanocytes, the source of nevus and melanoma. Uveal melanoma, similar to cutaneous melanoma, can metastasize to distant parts of the body and lead to death.²¹ Current treatments for uveal melanoma include enucleation (removal of the eye), different forms of radiotherapy, local resection of the tumor, thermal laser, and novel therapies, still in development, using nanoparticles.²²

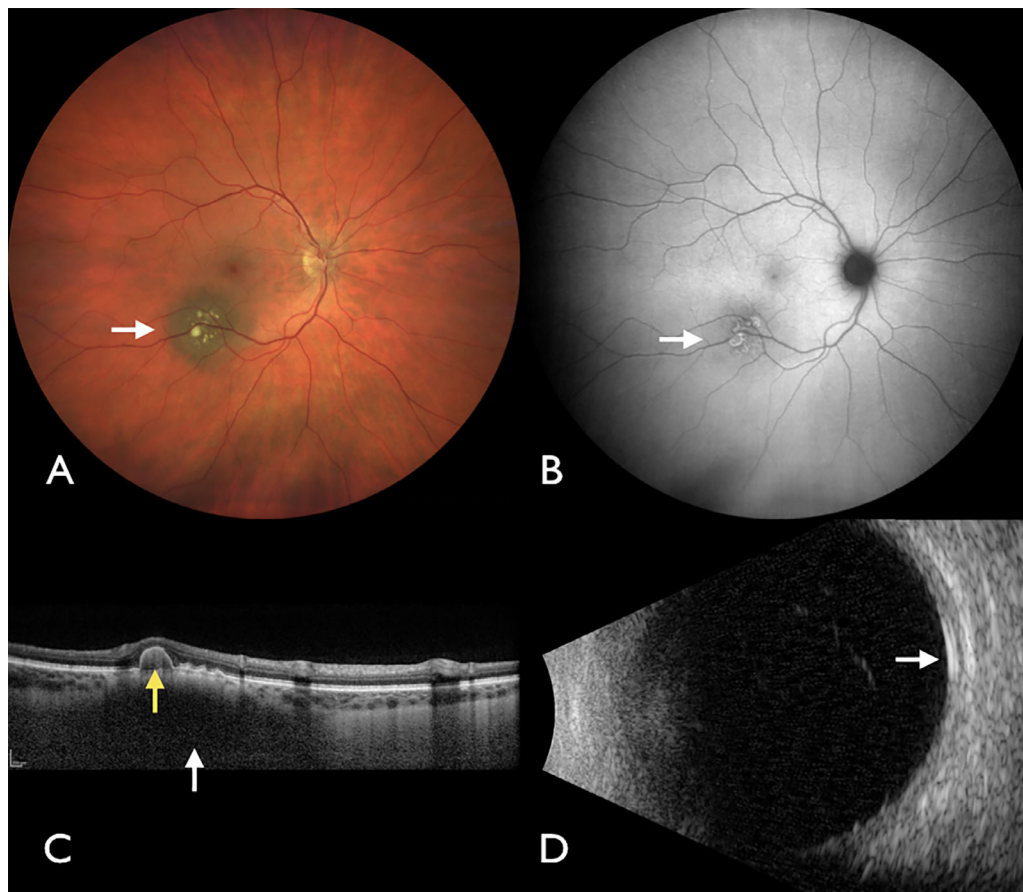


Figure 2. Multimodal imaging of benign choroidal nevus. (A) Choroidal nevus (arrow) with overlying yellow drusen. (B) Autofluorescence demonstrating the ring-shaped, minimally bright signal (arrow) of drusen. (C) OCT showing dark nevus with low signal (white arrow) and overlying pigment epithelial detachment (yellow arrow). (D) Ultrasound examination showing flat nevus (arrow) with <2 mm thickness.

Clinical Significance

Uveal melanoma most often arises in the choroid and often from a preexisting choroidal nevus. This nevus may be clinically apparent at an earlier age prior to malignant transformation, allowing for the possibility of early detection and intervention based upon risk factors associated with the nevus. The natural occurrence of a nevus in the eye is far more common than melanoma.^{2,3}

In the past, before multimodal ophthalmic imaging was available, diagnostic risk factors were based on subjective clinical observations alone.^{10–12} These factors were refined over decades of research to more accurately identify melanoma at an earlier stage in transformation, with the goal of diagnosing and treating melanoma at the smallest possible size.¹² More recently, high-resolution multimodal ophthalmic imaging has become available and has been studied for identification of objective risk factors

for nevus transformation into melanoma.^{22–24} These objective imaging factors hold the same goal as subjective clinical risk factors, but with the added benefit of reproducibility and availability with documentation and seem to be more reliable as findings are measurable.

Ophthalmic diagnostic imaging generally allows for direct photographic imaging of extraocular and intraocular surfaces, including all boundaries of choroidal nevus and melanoma, as well as cross-sectional imaging of the mass via ultrasound examination and optical coherence tomography (OCT), the former approaching 150 microns of resolution in tissue and the latter with high resolution down to 10 microns. Imaging of the RPE is available with autofluorescence, a technique using light wave filters to detect lipofuscin within the RPE and represented with bright signal (overabundance of lipofuscin, found with small melanoma) or dark signal (underabundance of lipofuscin, found with chronic nevus damage to the RPE) (Figs. 2 and 4). Direct imaging of

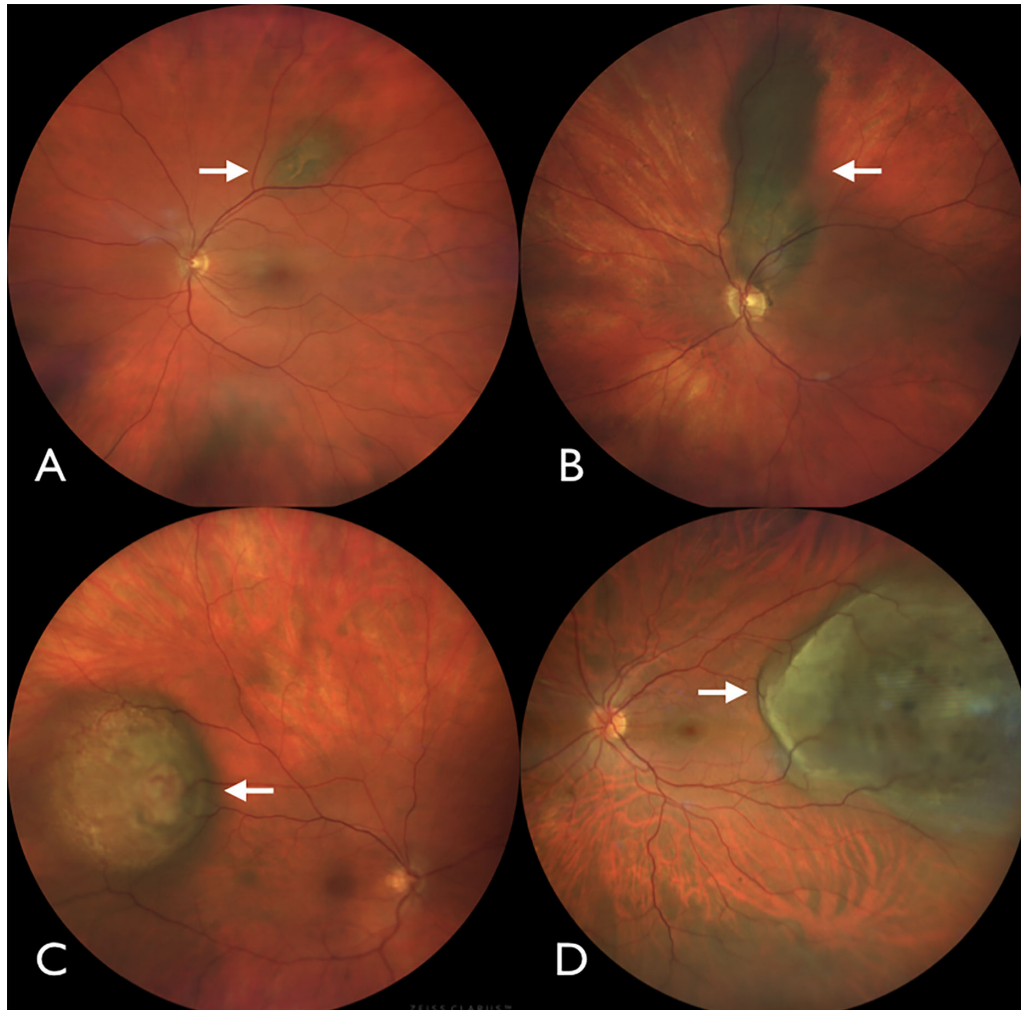


Figure 3. Spectrum of malignant choroidal melanoma. (A) Small choroidal melanoma (arrow) with overlying orange pigment. (B) Elongated choroidal melanoma (arrow) with overlying orange pigment on the inferior aspect. (C) Dome-shaped choroidal melanoma (arrow) with central elevated nodule. (D) Large choroidal melanoma (arrow) with overlying subretinal fluid.

ocular blood flow is also possible by intravenous injection of contrast agents, fluorescein angiography, and indocyanine green angiography. Fluorescein angiography can detect modifications in the internal and external blood-retinal barriers, which may help in differentiating large choroidal nevi from small choroidal melanomas. In contrast, indocyanine green angiography is mainly used to study intratumoral vascularization and can be beneficial in the differentiation between small amelanotic choroidal tumors, including choroidal nevi, choroidal melanoma, choroidal hemangiomas, and small isolated metastatic tumors. Noninvasive flow detection is possible with OCT angiography, using only light stimulated OCT images and applying a decorrelation algorithm to detect flow changes and with ultrasound examination using Doppler color flow mapping. Although OCT angiography can detect modifications of the superficial and deep capillary plexus of the

retina, its use in the differential diagnosis between choroidal nevus and melanoma is currently limited.²³

Several imaging modalities, including ultrasound examination, autofluorescence, and OCT, were combined to evaluate a series of 3806 choroid nevi.^{24,25} Using multimodal ophthalmic imaging, objective risk factors for nevus transformation into melanoma have been identified including Thickness >2 mm (ultrasound examination), Subretinal Fluid (OCT), Symptoms (Snellen visual acuity loss to $\leq 20/50$), Orange pigment (autofluorescence), Melanoma acoustic hollowness (ultrasound examination), and tumor Diameter >5 mm (fundus photography) (Figs. 2 and 4).^{24,25} Based on these recent findings, the mnemonic for choroidal nevus transformation to melanoma was updated to “*To Find Small Ocular Melanoma Doing IMaging*” to reflect the importance of integrating objective imaging modalities into the clinical

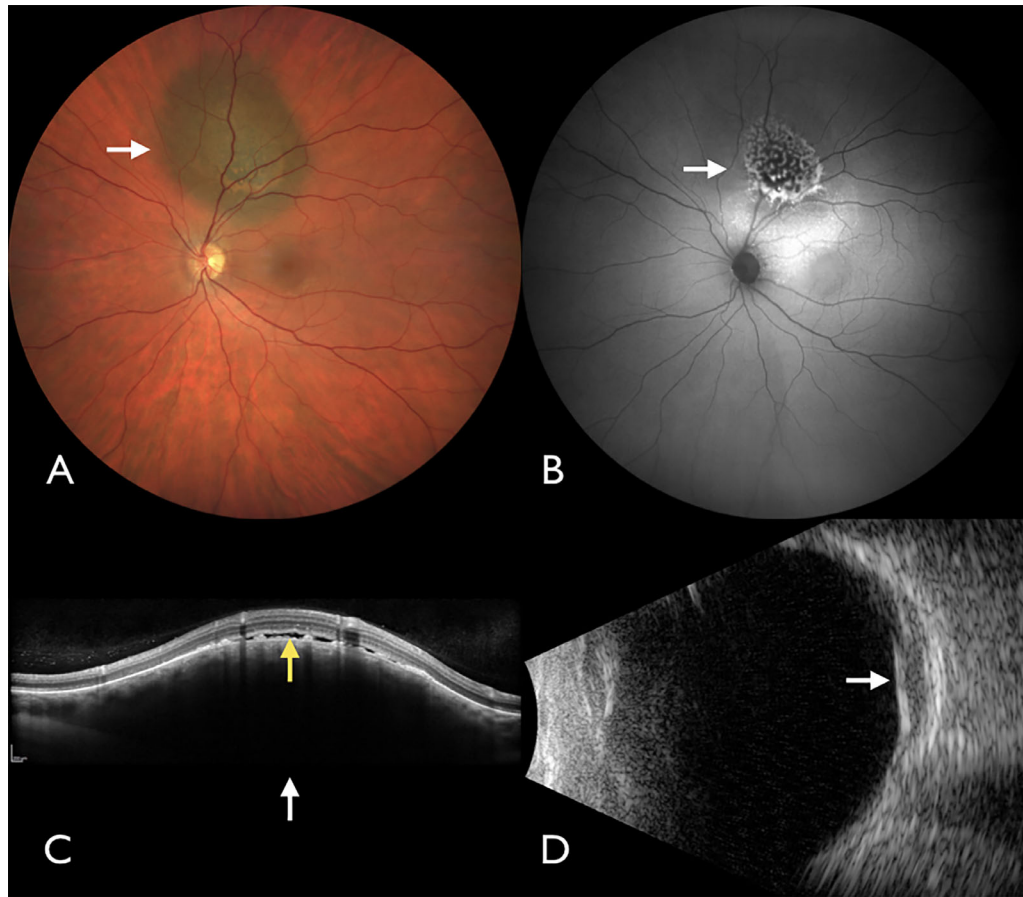


Figure 4. Multimodal imaging of malignant choroidal melanoma. (A) Choroidal melanoma (arrow) with overlying orange pigment. (B) Autofluorescence demonstrating the intense bright signal (arrow) of orange pigment. (C) OCT showing dark melanoma with low signal (white arrow) and overlying subretinal fluid (yellow arrow). (D) Ultrasound examination showing elevated melanoma (arrow) with acoustic hollowness, thickness > 2 mm, and shallow subretinal fluid.

assessment of these tumors. As with clinical risk factors, the mean 5-year rate for nevus growth to melanoma increases as more multimodal imaging features are positive, because any two factors promotes a mean 22% risk, three factors show 34% risk, and four factors promote >50% risk for transformation.^{24,25}

Potential for Artificial Intelligence (AI) Applications

The long-standing use of clinically identified risk factors in differentiating choroidal nevus from melanoma^{10,12,26} and the more recent extensive use of ophthalmic diagnostic imaging to both identify and monitor choroidal nevus and melanoma^{22,24–27} provide substantial data to begin to identify potential applications of AI.

AI is an interdisciplinary field of research developed out of the postulation by McCarthy et al. in the invitation to the Dartmouth Artificial Intelligence Conference in 1956 that “every aspect of learning or any other feature of intelligence can in principle be so precisely described that a machine can be made to simulate it.”²⁸

Machine learning (ML) is a conceptual approach to computational analysis that developed out of the field of AI. ML is an AI technique that can be used to design and train software algorithms to learn from and act on.²⁹ ML uses computer algorithms to generalize from datasets and continue to perform accurately on future data sets without further programming. The algorithms used can differ in approach, based on the data sets and the application. They can be supervised, where the algorithm is trained on human-labeled data, or unsupervised, where the algorithm is trained on unlabeled data and will search for patterns by

itself,³⁰ as well as numerous other methods of learning and model creation. Supervised learning and models tend to be excellent *classifiers* of disease type (e.g., nevus vs. no nevus) and disease stage (e.g., low-risk vs. high-risk nevus).³⁰ For instance, a supervised ML model can be trained with a dataset consisting of labeled fundus photographs of choroidal nevi and photographs of the normal fundus. The trained model, through supervised learning, may eventually be able to identify a nevus in a fundus photograph, with a sufficiently high level of accuracy, that is sensitivity and specificity. For the model to achieve high levels of accuracy, a large dataset of fundus photographs of choroidal nevi is required so that the model can identify any choroidal nevus regardless of shape, size (small vs. large), location (macular vs. extramacular), degree of pigmentation (pigmented vs. nonpigmented), as well as nevus associated with a variety of clinical features (subretinal fluid, orange pigment, overlying drusen, overlying RPE atrophy, RPE hyperplasia, or RPE fibrosis). Another supervised ML model can be trained with a separate dataset of fundus photographs of choroidal nevi labeled as low risk or high risk based on high-risk clinical features identified on fundus examination (presence of overlying subretinal fluid, presence of overlying orange pigment, diameter of >5 mm).

Deep learning is a highly specialized artificial neural network subtype of ML that consists of layers of algorithms forming complex neural networks inspired by the ones constituting the human brain.³⁰ This allows deep learning algorithms to self-iterate with the goal of improved performance and accuracy the more data they explore, a major advantage over classic ML algorithms that eventually reach a plateau.³⁰ Because of convolutional layers and the overall architectural structure of deep learning systems, this technology allows models to not only be excellent classifiers of disease but also excellent feature extractors.³⁰

In theory, an unsupervised deep learning model can be trained with unlabeled photographs of the normal fundus as well as photographs of various choroidal nevi with a range of risk factors for malignant transformation. A deep learning algorithm's process of progressive, layered data extraction allows the model to infer qualities from the input fundus photographs and cluster them based on computational features and then further identify patterns within those features and, perhaps, learn not only to identify a nevus, but also to classify it based on risk of malignant transformation. In this regard, deep learning algorithms hold the potential to find novel or unexpected computational features that might predict nevus at risk for malignant transformation.

Of note, true color fundus photographs are often chosen as initial training data for the ML models. With the advent of wide-field digital true color fundus cameras, a single photograph is enough in most cases to capture a choroidal nevus with its associated clinical features in contrast to the other ophthalmic imaging modalities such as OCT and OCT angiography where often a series of cuts are needed to capture the entire lesion. This allows for easier labeling of the data as well as faster training of the ML model. In addition, training of future ML models can be expanded to include pseudocolor fundus photographs as this carries the potential of providing AI assistance where clinical expertise might be needed the most, such as in optometry offices where pseudocolor fundus photograph cameras are often used for patient screening.

Recently, the US Food and Drug Administration (FDA) has cleared or approved several digital health technologies. In April 2018, the FDA authorized the first stand-alone diagnostic system, the Diabetic Retinopathy Detection Device (IDx-DR), designed to automatically detect the presence of more-than-mild diabetic retinopathy.³¹

There are also FDA-cleared systems for use in breast cancer detection including QuantX,³² for computer-aided imaging diagnosis detection granted in July 2017 and MammoScreen,³³ a radiologic computer-assisted software for lesions suspicious for cancer, cleared by FDA in March 2020. Recently, the FDA granted the "breakthrough" designation to 3Derm Spot³⁴ for the evaluation of skin images to autonomously detect cutaneous melanoma, squamous cell carcinoma and basal cell carcinoma. A full list of devices authorized for marketing including 510(k) "premarket notification" and "de novo" are available in the FDA searchable medical device database.³⁵ The FDA's Center for Devices and Radiological Health embraces development of digital health technologies which, include AI, ML, deep learning, and other types of software systems, known as Software as a Medical Device. Implementing the Center for Devices and Radiological Health's latest policies for digital health technologies will facilitate innovation in Software as a Medical Device for diagnosis of choroidal nevus and prediction of risk for malignant transformation.

Despite the potential of AI models in the diagnosis of choroidal nevus and prediction of risk for malignant transformation, there remains a number of challenges that should be considered, including the homogeneity of the training dataset, the potential of deep learning models to be black boxes, and the use of two-dimensional images that lack stereoscopic qualities.³⁶ Using fundus photographs taken with a specific digital fundus camera with a preset width of field, image

magnification, and resolution, and from patients of similar race could add bias to the results, precluding their generalizability and the use of the model in different clinical settings.³⁰ A technical challenge of reliance solely on fundus photographs arises from their two-dimensional nature. Without stereo fundus photographs or focus differential data, the aspect of thickness is greatly diminished. This is an important imaging feature, which was found to be a significant predictor for malignant transformation throughout all previous studies by Shields et al.^{10–12,24,25} However, AI might detect other features that could serve as a surrogate for thickness. Finally, considering the longstanding clinical diagnostic process, the potential that AI and deep learning can base risk of malignant transformation on nonspecific computational features³⁶ might raise questions among clinicians that will necessitate resolution before full acceptance of the models. Although challenges will need to be addressed, the potential benefits of AI and ML is substantial, especially with continued development of neural networks, more refined models and higher confidence in the results.³⁷

Conclusions

The concept of AI-based screening of ophthalmic imaging for both the presence of choroidal nevus and the factors that suggest potential transformation into melanoma would greatly enhance the detection and early treatment of melanoma within the eye. Guided by the understanding that, based on melanoma size at the time of treatment, smaller melanoma (earlier detection) portends a better life prognosis, this early detection has the potential to save lives.^{14,38,39}

Acknowledgments

Support provided by the Eye Tumor Research Foundation, Philadelphia, PA (CLS, SEL, SRF). The funders had no role in the design and conduct of the study, in the collection, analysis, and interpretation of the data, or in the preparation, review or approval of the manuscript. Carol Shields, MD, has had full access to all the data in the study and takes responsibility for the integrity of the data and the accuracy of the data analysis. No conflicting relationship exists for any author.

Disclosure: **C.L. Shields**, None; **S.E. Lally**, None; **L.A. Dalvin**, None; **M.S. Sagoo**, None; **M. Pellegrini**, None; **S. Kaliki**, None; **A.K. Gündüz**, None; **M. Furuta**,

None; **P. Mruthyunjaya**, None; **A.T. Fung**, None; **J.S. Duker**, None; **S.M. Selig**, None; **A. Yaghy**, None; **S.R. Ferenczy**, None; **M.B. Eydelman**, None; **M.S. Blumenkranz**, None

From the Collaborative Community on Ophthalmic Imaging (CCOI).

References

1. Shields JA, Shields CL. Choroidal nevus. In: *Intraocular Tumors. An Atlas and Textbook*. 3rd edition. Philadelphia, PA: Lippincott Wolters Kluwers; 2016;69–80.
2. Qui M, Shields CL. Choroidal nevus in the United States adult population: racial disparities and associated factors in the National Health and Nutrition Examination Survey. *Ophthalmology*. 2015;122:2071–2083.
3. Sumich P, Mitchell P, Wang JJ. Choroidal nevi in a white population: the Blue Mountains Eye Study. *Arch Ophthalmol*. 1998;116:645–650.
4. Jonas JB, You QS, Xu L, et al. Choroidal nevi in adult Chinese. *Ophthalmology*. 2008;115:1102.
5. Ng CH, Wang JJ, Mitchell P, et al. Prevalence and characteristics of choroidal nevi in an Asian vs. white population. *Arch Ophthalmol*. 2009;127:314–319.
6. Greenstein MB, Myers CE, Meuer SM, et al. Prevalence and characteristics of choroidal nevi: the multiethnic study of atherosclerosis. *Ophthalmology*. 2011;118:2468–2473.
7. Nangia V, Jones JB, Agarwal S, et al. Choroidal nevi in adult Indians: the Central India Eye and Medical Study. *Br J Ophthalmol*. 2012;96:1443–1444.
8. Shields CL, Furuta M, Mashayekhi A, et al. Clinical spectrum of choroidal nevi based on age at presentation in 3422 consecutive eyes. *Ophthalmology*. 2008;115:546–552.
9. Mashayekhi A, Siu S, Shields CL, Shields JA. Slow enlargement of choroidal nevi: a long-term follow-up study. *Ophthalmology*. 2011;118:382–388.
10. Shields CL, Shields JA, Kiratli H, et al. Risk factors for growth and metastasis of small choroidal melanocytic lesions. *Ophthalmology*. 1995;102:1351–1361.
11. Shields CL, Cater J, Shields JA, et al. Combination of clinical factors predictive of growth of small

- choroidal melanocytic tumors. *Arch Ophthalmol*. 2000;118:360–364.
12. Shields CL, Furuta M, Berman EL, et al. Choroidal nevus transformation into melanoma: analysis of 2514 consecutive cases. *Arch Ophthalmol*. 2009;127:981–987.
 13. Singh AD, Kalyani P, Topham A. Estimating the risk of malignant transformation of a choroidal nevus. *Ophthalmology*. 2005;112:1784–1789.
 14. Kivelä T, Eskelin S. Transformation of nevus to melanoma. *Ophthalmology*. 2006;113:887–888.e1.
 15. Shields CL, Furuta M, Thangappan A, et al. Metastasis of uveal melanoma millimeter-by-millimeter in 8033 consecutive eyes. *Arch Ophthalmol*. 2009;127:989–998.
 16. Pampena R, Kyrgidis A, Lallas A, et al. A meta-analysis of nevus-associated melanoma: prevalence and practical implications. *J Am Acad Dermatol*. 2017;77:938–945.
 17. Lindholm C, Andersson R, Dufmats M, et al. Invasive cutaneous malignant melanoma in Sweden, 1990–1999. A prospective, population-based study of survival and prognostic factors. *Cancer*. 2004;101:2067–2078.
 18. Rigel DS, Friedman RJ, Kopf AW, Polsky D. ABCDE—an evolving concept in the early detection of melanoma. *Arch Dermatol*. 2005;141:1032–1034.
 19. Weinstock MA. Progress and prospects on melanoma: the way forward for early detection and reduced mortality. *Clin Cancer Res*. 2006;12:2297s–1300s.
 20. Elbaum M, Kopf AW, Rabinovitz HS, et al. Automatic differentiation of melanoma from melanocytic nevi with multispectral digital dermoscopy: a feasibility study. *J Am Acad Dermatol*. 2001;44:207–218.
 21. Diener-West M, Hawkins BS, Markowitz JA, Schachat AP. A review of mortality from choroidal melanoma. II. A meta-analysis of 5-year mortality rates following enucleation, 1966 through 1988. *Arch Ophthalmol*. 1992;110:245–250.
 22. Shields CL, Lim LAS, Dalvin LA, Shields JA. Small choroidal melanoma: detection with multimodal imaging and management with plaque radiotherapy or AU-011 nanoparticle therapy. *Curr Opin Ophthalmol*. 2019;30:206–214.
 23. Welch RJ, Newman JH, Honig SE, et al. Choroidal amelanotic tumours: clinical differentiation of benign from malignant lesions in 5586 cases. *Br J Ophthalmol*. 2020;104:194–201.
 24. Shields CL, Dalvin LA, Ancona-Lezama D, et al. Choroidal nevus imaging features in 3,806 cases and risk factors for transformation into melanoma in 2,355 cases: the 2020 Taylor R. Smith and Victor T. Curtin Lecture. *Retina*. 2019;39:1840–1851.
 25. Shields CL, Dalvin LA, Yu MD, et al. Choroidal nevus transformation into melanoma per millimeter increment in thickness using multimodal imaging in 2355 cases: the 2019 Wendell L. Hughes Lecture. *Retina*. 2019;39:1852–1860.
 26. Augsburger JJ, Schroeder RP, Territo C, et al. Clinical parameters predictive of enlargement of melanocytic choroidal lesions. *Br J Ophthalmol*. 1989;73:911–917.
 27. Dalvin LA, Shields CL, Ancona-Lezama DA, et al. Combination of multimodal imaging features predictive of choroidal nevus transformation into melanoma. *Br J Ophthalmol*. 2019;103:1441–1447.
 28. McCarthy J, Minsky M, Rochester N, Shannon CE. A proposal for the Dartmouth Summer Research Project on Artificial Intelligence, August 31, 1955. *AI Magazine*. 2006;27:12–14.
 29. US Food and Drug Administration. Artificial intelligence and machine learning in software as a medical device. Available at: <https://www.fda.gov/medical-devices/software-medical-device-samd/artificial-intelligence-and-machine-learning-software-medical-device>. Accessed May 20, 2020.
 30. Schmidt-Erfurth U, Sadeghipour A, Gerendas BS, et al. Artificial intelligence in retina. *Prog Retin Eye Res*. 2018;67:1–29.
 31. US Food and Drug Administration. Device classification under Section 513(f)(2)(De Novo). Available at: <https://www.accessdata.fda.gov/scripts/cdrh/cfdocs/cfpmn/denovo.cfm?ID=DEN180001>. [IDx-DR] Accessed May 20, 2020.
 32. US Food and Drug Administration. Evaluation of automatic class III designation for QuantX. Decision summary. Available at: https://www.accessdata.fda.gov/cdrh_docs/reviews/DEN170022.pdf. [QuantX] Accessed May 20, 2020.
 33. US Food and Drug Administration. Radiological computer assisted detection/diagnosis software for lesions suspicious for cancer. Available at: <https://fda.report/PMN/K192854>. [MammoScreen] Accessed May 20, 2020.
 34. Whooley, S. 3Derm lands FDA breakthrough device designations for autonomous skin cancer AI. Available at: <https://www.massdevice.com/3derm-lands-fda-breakthrough-device-designations-for-autonomous-skin-cancer-ai/>. [3Derm Spot] Accessed May 20, 2020.

35. US Food and Drug Administration. Medical devices databases. Available at: <https://www.fda.gov/medical-devices/device-advice-comprehensive-regulatory-assistance/medical-device-databases>. Accessed May 20, 2020.
36. Poplin R, Varadarajan AV, Blumer K, et al. Prediction of cardiovascular risk factors from retinal fundus photographs via deep learning. *Nat Biomed Eng*. 2018;2:158–164.
37. Ting DSW, Pasquale LR, Peng L, et al. Artificial intelligence and deep learning in ophthalmology. *Br J Ophthalmol*. 2019;103:167–175.
38. Shields CL, Say EAT, Hasanreisoglu M, et al. Cytogenetic abnormalities in uveal melanoma based on tumor features and size in 1059 patients: the 2016 W. Richard Green Lecture. *Ophthalmology*. 2017;124:609–618.
39. Shields CL, Pefkianaki M, Mashayekhi A, et al. Cytogenetic results of choroidal nevus growth into melanoma in 55 consecutive cases. *Saudi J Ophthalmol*. 2018;32:28–32.