

1-15-2019

## Koebner phenomenon: pemphigus vulgaris following Mohs micrographic surgery.

Georgette Hattier  
*Thomas Jefferson University*

Sarah Beggs  
*Thomas Jefferson University*

Joya Sahu  
*Thomas Jefferson University*

Joshua Trufant  
*Thomas Jefferson University*

Elizabeth Jones  
Follow this and additional works at: <https://jdc.jefferson.edu/dcbfp>  
*Thomas Jefferson University*

 Part of the [Dermatology Commons](#)

[Let us know how access to this document benefits you](#)

### Recommended Citation

Hattier, Georgette; Beggs, Sarah; Sahu, Joya; Trufant, Joshua; and Jones, Elizabeth, "Koebner phenomenon: pemphigus vulgaris following Mohs micrographic surgery." (2019). *Department of Dermatology and Cutaneous Biology Faculty Papers*. Paper 109.

<https://jdc.jefferson.edu/dcbfp/109>

This Article is brought to you for free and open access by the Jefferson Digital Commons. The Jefferson Digital Commons is a service of Thomas Jefferson University's [Center for Teaching and Learning \(CTL\)](#). The Commons is a showcase for Jefferson books and journals, peer-reviewed scholarly publications, unique historical collections from the University archives, and teaching tools. The Jefferson Digital Commons allows researchers and interested readers anywhere in the world to learn about and keep up to date with Jefferson scholarship. This article has been accepted for inclusion in Department of Dermatology and Cutaneous Biology Faculty Papers by an authorized administrator of the Jefferson Digital Commons. For more information, please contact: [JeffersonDigitalCommons@jefferson.edu](mailto:JeffersonDigitalCommons@jefferson.edu).

# UC Davis

## Dermatology Online Journal

### Title

Koebner phenomenon: pemphigus vulgaris following Mohs micrographic surgery

### Permalink

<https://escholarship.org/uc/item/64b6k3wr>

### Journal

Dermatology Online Journal, 25(1)

### Authors

Hattier, Georgette  
Beggs, Sarah  
Sahu, Joya  
[et al.](#)

### Publication Date

2019

### License

[CC BY-NC-ND 4.0](#)

Peer reviewed

# Koebner phenomenon: pemphigus vulgaris following Mohs micrographic surgery

Georgette Hattier<sup>1</sup> BA, Sarah Beggs<sup>2</sup> MD, Joya Sahu<sup>2</sup> MD, Joshua Trufant<sup>2</sup> MD, Elizabeth Jones<sup>2</sup> MD

Affiliations: <sup>1</sup>Sidney Kimmel Medical College, Thomas Jefferson University, Philadelphia, Pennsylvania, USA, <sup>2</sup>The Thomas Jefferson University, Department of Dermatology, Philadelphia, Pennsylvania, USA

Corresponding Author: Elizabeth Jones MD, 833 Chestnut Street, Suite 740, Philadelphia, PA, Tel: 215-955-6680, Email: [Elizabeth.jones@jefferson.edu](mailto:Elizabeth.jones@jefferson.edu)

## Abstract

Koebnerization of pemphigus vulgaris (PV) is an infrequently reported reaction. We present a 65-year-old man with Koebnerized pemphigus vulgaris after Mohs microscopic surgery for a basal cell carcinoma. We present this case to heighten awareness of the phenomenon in the dermatological community.

**Keywords:** Koebnerization, pemphigus vulgaris, Mohs micrographic surgery

## Introduction

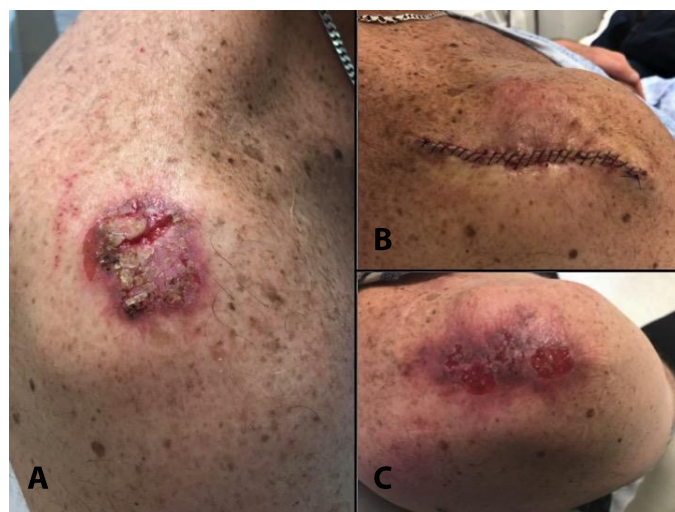Pemphigus vulgaris (PV) is a mucocutaneous blistering disease most often caused by IgG autoantibodies to desmogleins 1 and 3. These autoantibodies disrupt keratinocyte adhesion and cause epidermal acantholysis and blister formation. Rare reports have noted Koebnerization of PV after physical trauma such as radiation, burns, and surgery [1-3]. Only one report of PV and two reports of pemphigus foliaceus (PF) induced by Mohs micrographic surgery (MMS) for squamous cell carcinomas have been published [2-4]. Herein, we present a patient with PV Koebnerization, initially developing after a bicycling accident and exacerbated by later MMS for a basal cell carcinoma (BCC), which arose within the same site.

## Case Synopsis

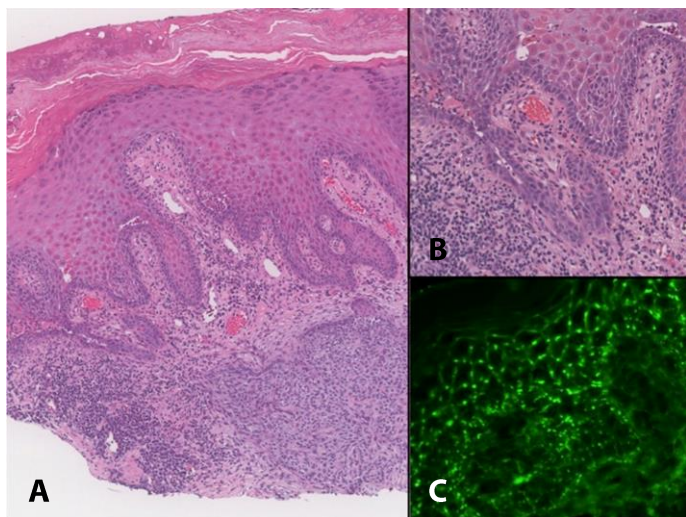
A 65-year-old man presented with a tender non-healing wound on the right shoulder. The wound was present for over five years following a bicycling

injury. Physical examination revealed a 5×3.5cm pink, eroded, friable, and crusted plaque on the right shoulder (**Figure 1A**). A shave biopsy of the right shoulder showed aggregations of abnormal follicular germinative cells consistent with a BCC. Acantholysis and dyskeratosis reminiscent of PV were subtle but incidentally noted in the specimen (**Figure 2 A, B**).

Mohs microscopic surgery performed two weeks later again demonstrated suprabasal acantholysis on frozen sectioning with residual BCC. Mohs microscopic surgery was completed in two stages followed by a linear closure (**Figure 1B**). Sutures were removed two weeks later without incident.



**Figure 1.** **A)** Right shoulder at time of initial presentation showing a pink pearly, ulcerated plaque with thick crust. **B)** Right shoulder after treatment with Mohs micrographic surgery for basal cell carcinoma. **C)** Right shoulder six weeks after the procedure showing an ulcerated, erythematous to violaceous plaque.



**Figure 2.** Initial biopsy with hematoxylin and eosin stain showing peripherally palisaded basaloid cells consistent with a basal cell carcinoma with coexistent acantholysis and dyskeratosis reminiscent of pemphigus vulgaris. **A)** 40 $\times$ , **B)** 100 $\times$ . **C)** Direct immunofluorescence revealed granular deposition in a network-like pattern of IgG within the lower epidermis, 100 $\times$ .

Six weeks later the patient presented with concerns of a non-healing surgical site. Physical examination revealed a deep red plaque with areas of erosions and flaccid bullae formation (**Figure 1C**). Hematoxylin and eosin stain confirmed the diagnosis of PV, showing suprabasal acantholysis forming a tombstoning appearance with blister formation. Direct immunofluorescence revealed granular deposition of IgG and C3 in a network-like pattern within the lower epidermis (**Figure 2C**). Desmoglein 3 antibodies were positive (151U/mL), consistent with mucosal-dominant PV. Upon further investigation, the patient disclosed a longstanding history of mucosal discomfort that he attributed to poor hygiene owing to pain with brushing his teeth.

The patient was initially given clobetasol ointment along with intralesional triamcinolone for the lesion on the shoulder and triamcinolone paste for the oral lesions. After three months of topical therapies, the right shoulder healed into an erythematous atrophic plaque; however, erosions remained on his mandibular and maxillary gingivae. The patient received two rituximab infusions two weeks apart. He has since been able to brush his teeth and gums daily and reported no new cutaneous or oral lesions.

## Case Discussion

The Koebner phenomenon is the appearance of dermatosis following skin trauma. Koebnerization is frequently seen in patients with preexisting dermatoses such as psoriasis, lichen planus, or vitiligo, but has been rarely reported in PV [1, 3]. Koebnerization of PV has been proposed to be related to an increased susceptibility of a traumatized epidermis to pemphigus autoantibodies in a genetically predisposed patient [1]. Epitope spreading has also been hypothesized, in which traumatized epithelium induces pemphigus antigens or exposes new epitopes leading to antibody formation and subsequent PV elsewhere [1-3, 5]. In the above patient who only had desmoglein 3 autoantibodies, it is possible that trauma from the bicycling accident and MMS incited a cutaneous exacerbation of pemphigus. The more superficial desmoglein 1 in the epidermis could no longer compensate for desmoglein 3 autoantibodies affecting the deeper epidermis.

Daneshpazhooh et al. published a review of thirty-six cases of PV incited by trauma, thirteen of which were of new-onset. Most of these cases followed major surgeries (abdominal, orthopedic, and chest surgeries) and dental procedures. Two cases were associated with cutaneous procedures, one following a cyst excision and the other after shave removal and cauterization of nevi. The time between trauma and PV development within the lesions were 15 weeks for patients without a known history of PV and 4.7 weeks for patients with a history of PV, consistent with the time line seen in our patient. All patients without a previous history of PV ultimately developed mucosal or cutaneous PV lesions elsewhere [1].

Squamous cell carcinomas develop variable expression of desmogleins 1 and 3, a possible triggering factor in the one PV and two PF previously reported cases induced by MMS [2-4]. Another case describes PV misdiagnosed as an acantholytic squamous cell carcinoma with the patient unnecessarily undergoing six stages of MMS [6]. Our patient had a clearly differentiated basal cell carcinoma that extended into the dermis. To our

knowledge, this is the first reported case of Koebnerized PV after MMS for BCC.

## References

1. Daneshpazhooh M, Fatehnejad M, Rahbar Z, Balighi K, Ghandi N, Ghiasi M, Abedini R, Lajevardi V, Chams-Davatchi C. Trauma-induced pemphigus: a case series of 36 patients. *J Dtsch Dermatol Ges*. 2016;14(2):166-71. [PMID: 26819113].
2. Rotunda AM, Bhupathy A, Dye R, Soriano TT. Pemphigus foliaceus masquerading as postoperative wound infection: report of a case and review of the koebner and related phenomenon following surgical procedures. *Dermatol Surg*. 2005;31(2):226-231. [PMID: 15762220].
3. Duick MG, Zaks B, Moy RL, Kaplan RP. Mohs micrographic surgery-induced pemphigus. *Dermatol Surg*. 2001;27(10):894-897. [PMID: 11722529].
4. Tolkachjov SN, Frith M, Cooper LD, Harmon CB. Pemphigus foliaceus demonstrating pathergy after Mohs micrographic surgery. *Dermatol Surg*. 2018;44(10):1352-1353. [PMID: 29293109].
5. Lehmann PV, Forsthuber T, Miller A, Sercarz EE. Spreading of T-cell autoimmunity to cryptic determinants of an autoantigen. *Nature*. 1992;358(6382):155-157. [PMID: 1377368].
6. Howard JC, Russell KJ, Vickers JL, Weiss E. Acantholysis: worth a second look? *Dermatol Surg*. 2014;40(11):1268-70. [PMID: 25322161].

## Conclusion

We present this case to heighten awareness of the phenomenon in the dermatological community.