

4-1-2017

# Misplaced Cervical Screws Requiring Reoperation.

Jeremy C. Peterson  
*University of Kansas Medical Center*

Paul M. Arnold  
*University of Kansas Medical Center*

Zachary A. Smith  
*Northwestern University*

Wellington K. Hsu  
*Northwestern University*

Michael G. Fehlings  
*Toronto Western Hospital*

*See next page for additional authors*

## [Let us know how access to this document benefits you](#)

Follow this and additional works at: [https://jdc.jefferson.edu/rothman\\_institute](https://jdc.jefferson.edu/rothman_institute)

 Part of the [Orthopedics Commons](#), and the [Surgery Commons](#)

### Recommended Citation

Peterson, Jeremy C.; Arnold, Paul M.; Smith, Zachary A.; Hsu, Wellington K.; Fehlings, Michael G.; Hart, Robert A.; Hilibrand, Alan S.; Nassr, Ahmad; Rahman, Ra'Kerry K.; Tannoury, Chadi A.; Tannoury, Tony; Mroz, Thomas E.; Currier, Bradford L.; De Giacomo, Anthony F.; Fogelson, Jeremy L.; Jobse, Bruce C.; Massicotte, Eric M.; and Riew, K. Daniel, "Misplaced Cervical Screws Requiring Reoperation." (2017). *Rothman Institute*. Paper 87.  
[https://jdc.jefferson.edu/rothman\\_institute/87](https://jdc.jefferson.edu/rothman_institute/87)

---

**Authors**

Jeremy C. Peterson, Paul M. Arnold, Zachary A. Smith, Wellington K. Hsu, Michael G. Fehlings, Robert A. Hart, Alan S. Hilibrand, Ahmad Nassr, Ra'Kerry K. Rahman, Chadi A. Tannoury, Tony Tannoury, Thomas E. Mroz, Bradford L. Currier, Anthony F. De Giacomo, Jeremy L. Fogelson, Bruce C. Jobse, Eric M. Massicotte, and K. Daniel Riew

# Misplaced Cervical Screws Requiring Reoperation

Global Spine Journal  
2017, Vol. 7(1S) 46S-52S  
© The Author(s) 2017  
Reprints and permission:  
sagepub.com/journalsPermissions.nav  
DOI: 10.1177/2192568216687527  
journals.sagepub.com/home/gsj



Jeremy C. Peterson, MD<sup>1</sup>, Paul M. Arnold, MD, FACS<sup>1</sup>,  
Zachary A. Smith, MD<sup>2</sup>, Wellington K. Hsu, MD<sup>2</sup>,  
Michael G. Fehlings, MD, PhD<sup>3</sup>, Robert A. Hart, MD<sup>4</sup>,  
Alan S. Hilibrand, MD<sup>5</sup>, Ahmad Nassr, MD<sup>6</sup>, Ra'Kerry K. Rahman, MD<sup>7,8</sup>,  
Chadi A. Tannoury, MD<sup>9</sup>, Tony Tannoury, MD<sup>9</sup>, Thomas E. Mroz, MD<sup>10</sup>,  
Bradford L. Currier, MD<sup>6</sup>, Anthony F. De Giacomo, MD<sup>11</sup>,  
Jeremy L. Fogelson, MD<sup>6</sup>, Bruce C. Jobse, BA<sup>9</sup>,  
Eric M. Massicotte, MD, MSc, FRCSC<sup>3,12</sup>, and K. Daniel Riew, MD<sup>13,14</sup>

## Abstract

**Study Design:** A multicenter, retrospective case series.

**Objective:** In the past several years, screw fixation of the cervical spine has become commonplace. For the most part, this is a safe, low-risk procedure. While rare, screw backout or misplaced screws can lead to morbidity and increased costs. We report our experiences with this uncommon complication.

**Methods:** A multicenter, retrospective case series was undertaken at 23 institutions in the United States. Patients were included who underwent cervical spine surgery from January 1, 2005, to December 31, 2011, and had misplacement of screws requiring reoperation. Institutional review board approval was obtained at all participating institutions, and detailed records were sent to a central data center.

**Results:** A total of 12903 patients met the inclusion criteria and were analyzed. There were 11 instances of screw backout requiring reoperation, for an incidence of 0.085%. There were 7 posterior procedures. Importantly, there were no changes in the health-related quality-of-life metrics due to this complication. There were no new neurologic deficits; a patient most often presented with pain, and misplacement was diagnosed on plain X-ray or computed tomography scan. The most common location for screw backout was C6 (36%).

**Conclusions:** This study represents the largest series to tabulate the incidence of misplacement of screws following cervical spine surgery, which led to revision procedures. The data suggest this is a rare event, despite the widespread use of cervical fixation. Patients suffering this complication can require revision, but do not usually suffer neurologic sequelae. These patients have increased cost of care. Meticulous technique and thorough knowledge of the relevant anatomy are the best means of preventing this complication.

## Keywords

cervical spine, fusion, instrumentation, complication, misplaced screw, screw backout

<sup>1</sup> University of Kansas Medical Center, Kansas City, KS, USA

<sup>2</sup> Northwestern University, Chicago, IL, USA

<sup>3</sup> Toronto Western Hospital, Toronto, Ontario, Canada

<sup>4</sup> Oregon Health & Science University, Portland, OR, USA

<sup>5</sup> Jefferson Medical College, The Rothman Institute, Philadelphia, PA, USA

<sup>6</sup> Mayo Clinic, Rochester, MN, USA

<sup>7</sup> Springfield Clinic, LLP, Springfield, IL, USA

<sup>8</sup> Southern Illinois University, Springfield, IL, USA

<sup>9</sup> Boston University Medical Center, Boston, MA, USA

<sup>10</sup> Cleveland Clinic, Cleveland, OH, USA

<sup>11</sup> Boston University, Boston, MA, USA

<sup>12</sup> University of Toronto, Toronto, Ontario, Canada

<sup>13</sup> Columbia University, New York, NY, USA

<sup>14</sup> New York-Presbyterian/The Allen Hospital, New York, NY, USA

## Corresponding Author:

Paul M. Arnold, Kansas University Medical Center, 3901 Rainbow Blvd,  
MS 3021, Kansas City, KS 66160, USA.  
Email: parnold@kumc.edu



This article is distributed under the terms of the Creative Commons Attribution-NonCommercial-NoDerivs 4.0 License (<http://www.creativecommons.org/licenses/by-nc-nd/4.0/>) which permits non-commercial use, reproduction and distribution of the work as published without adaptation or alteration, without further permission provided the original work is attributed as specified on the SAGE and Open Access pages (<https://us.sagepub.com/en-us/nam/open-access-at-sage>).

## Introduction

Techniques for instrumented fixation and fusion of the cervical spine have rapidly advanced in the past 30 years. These techniques have helped surgeons adequately manage complex trauma, tumor, and degenerative pathologies. For the most part, these are safe, low-risk procedures. Hadra in 1890 described the use of wiring and graft techniques to perform the first spinal fusion procedures.<sup>1,2</sup> These techniques were standard until the start of modern cervical spinal fusion with Roy-Camille in the 1970s.<sup>1,3</sup> Since this time there have been improvements in technique and implants, which have made the procedures safer, thus leading to increased adoption of instrumented cervical fusion.

Within the United States, approximately 150 000 cervical fusion procedures are performed each year.<sup>4</sup> Around 90% of cervical fusions are anterior with 10% being posterior.<sup>4</sup> The use of plate and screw instrumentation for anterior cervical fusion has become a mainstay, so much so that in 2010 the American Medical Association combined 2 Current Procedural Terminology codes into a comprehensive code. The indications for cervical fusion are well established, based on an abundance of studies showing clinical and biomechanical efficacy.<sup>5-10</sup>

Despite these studies there is a paucity of literature detailing the complications associated with cervical spinal fusion. Most studies are retrospective in design, contain a small numbers of patients, report single-institution data, relate to a single indication, or contain information with outdated procedures.<sup>9,11-29</sup> The overall complication rate for cervical fusion procedures is low, and these earlier studies may not reliably provide data on less common complications.

While rare, screw backout or misplaced screws can lead to morbidity, the need for revision surgery, and increased costs. Previous studies report a low incidence of this particular event. We report our experiences with this uncommon but potentially harmful complication.

## Methods

We have conducted a retrospective multicenter case series study involving 21 high-volume surgical centers from the AOSpine North America Clinical Research Network, selected for their excellence in spine care and clinical research infrastructure and experience. Medical records for 17 625 patients who underwent cervical spine surgery (levels from C2 to C7) between January 1, 2005, and December 31, 2011, inclusive, were reviewed to identify occurrence of 21 predefined treatment complications. The complications included reintubation requiring evacuation, esophageal perforation, epidural hematoma, C5 palsy, recurrent laryngeal nerve palsy, superior laryngeal nerve palsy, hypoglossal or glossopharyngeal nerve palsy, dural tear, brachial plexopathy, blindness, graft extrusion, misplaced screws requiring reoperation, anterior cervical infection, carotid artery injury or cerebrovascular accident, vertebral artery injuries, Horner's syndrome, thoracic duct injury, tetraplegia, intraoperative death, revision of arthroplasty and, pseudomeningocele.

Trained research staff at each site abstracted the data from medical records, surgical charts, radiology imaging, narratives, and other source documents for the patients who experienced one or more of the complications from the list. Data were transcribed into study-specific paper case report forms. Copies of case report forms were transferred to the AOSpine North America Clinical Research Network Methodological Core for processing, cleaning, and data entry.

Descriptive statistics were provided for baseline patient characteristics. Paired *t* test was used to analyze changes in clinical outcomes at follow-up compared to preoperative status. A total of 12 903 cervical procedures qualified for screening for the complication of misplaced screw requiring reoperation.

## Results

A total of 12 903 patients met the inclusion criteria and were analyzed. There were 11 instances of misplaced screws requiring reoperation, for an incidence of 0.085%, translating to a rate of 8.5 per 10 000 cervical spine surgeries (Table 1). A total of 8887 cases screened were specifically only anterior procedures making the incidence 3/8887 (0.034%). The remaining cases screened could be posterior or posterior/anterior combined procedures. We do not have enough information on the remaining cases to make a determination of the incidence of misplacement of posterior screws requiring reoperation, but suspect it would a higher rate. The average age of the patients was 53 years, and there were 4 female patients. No patients had evidence of osteoporosis at the time of surgery. Three of the patients were current smokers, and 5 patients had previously smoked. Myelopathy and radiculopathy were the most common reasons for initial operation, 6/11 (55%) and 5/11 (45%), respectively, with 1 patient having both symptoms. The average hospital length of stay was 9.25 days. There were 4 anterior and 7 posterior procedures. Importantly, there were no changes in the health-related quality-of-life metrics due to this complication. There were no new neurologic deficits; patients most often presented with pain, and screw backout was diagnosed on postoperative plain X-ray or computed tomography scan. Five of 11 (45%) and 3/11 (27%) patients were diagnosed within the original hospital admission or postoperative clinic follow-up, respectively, while we were unable to obtain these data on 3 cases. Two patients with anterior screw backout had swallowing problems, which resolved with reoperation. The most common location for screw backout was C6, 4/11 (36%); 2 patients had screw backout at C2. Patient 4 had aggressive removal of an osteophyte complex and an anterior cervical screw penetrated into the central canal (Figure 1A and B). The patient had symptoms of right-sided proximal upper extremity weakness, which resolved with removal and revision of the C5 penetrating screw (Figure 1C).

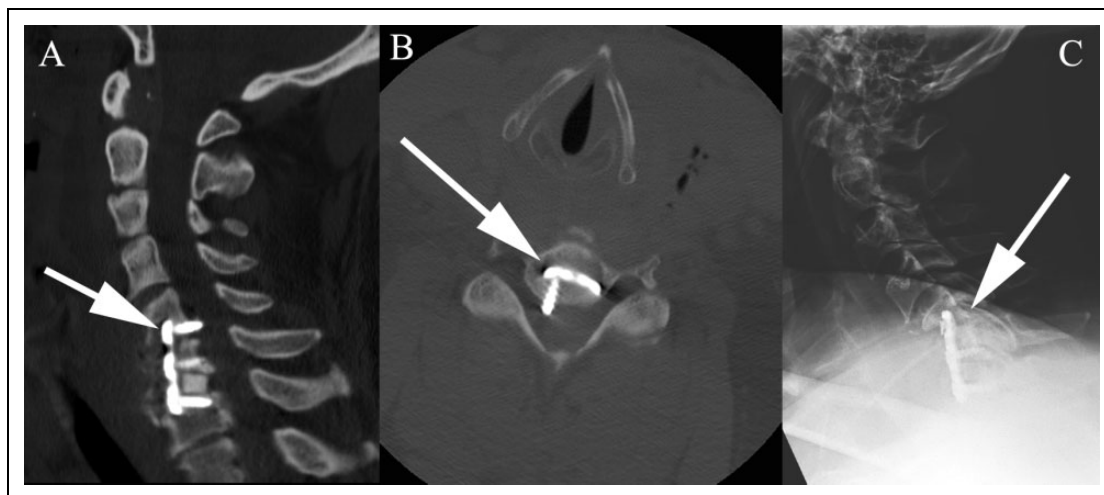
## Discussion

Due to the risk and complexity associated with cervical spinal surgery, current techniques and approaches did not become

**Table 1.** Case Information.

	Age (Years)	Tobacco Status at Surgery	Approach	Instrumented Levels	Discectomy Levels	Laminectomy Levels	Level of Screw Misplacement	Principal Diagnosis	Time From Surgery to Symptoms (Days)	Correction
1	46	Previous	Posterior	C5, C6, C7		N/A	C3, C4, C5, C6, C7, T1, T2	Fracture	17	C3-T2 segmental instrumentation
2	47	Current	Anterior	C5, C6, C7	C5-6, C6-7		C5	Radiculopathy, cervical stenosis	1	Removed C5 screw
3	63	Never	Posterior	C3, C4, C5, C6, C7, T1, T2		C3, C4, C5, C6	C2	Myelopathy	1	Removed right C2 screw
4	51	Previous	Posterior	N/A		C7, T1	C2, C6	Myelopathy	1	Replacement of left C2 and C6 screws
5	43	Never	Anterior	C3, C4	C3-4		C3	Myelopathy	2	Revision of left C3 screw
6	39	Previous	Posterior	C6, C7		N/A	C6	Radiculopathy, nonunion of C5-6	0	Removal of C5-C6 instrumentation then wire fixation
7	62	Previous	Posterior	C3, C4, C5, C6, C7, T1		C3, C4, C5, C6, C7	T1	Myelopathy	3	Left T1 screw repositioned
8	63	Never	Posterior	C2, C3, C4, C5, C6, C7		C3, C4, C5, C6	C7	DDD, myelopathy, radiculopathy, kyphosis	0	Screw revision
9	51	Current	Anterior	C6, C7	C6-7		C6	Radiculopathy	17	Removal of loose C6 screw
10	67	Previous	Posterior	N/A		C3, C4, C5, C6, C7	C3, C4	Myelopathy, fracture	N/A	Posterior fixation C2 to T1; anterior fusion C2 to C7
11	49	Current	Posterior	N/A		N/A	C5	Radiculopathy, nonunion C5-6-7	8	Removed left C5; lateral mass screw

Abbreviation: DDD, degenerative disc disease.



**Figure 1.** (A) Sagittal computed tomography scan with arrow demonstrating misplaced right C5 screw. (B) Axial computed tomography scan with arrow demonstrating misplaced right C5 screw. (C) Postoperative lateral cervical spine X-ray demonstrating removal of misplaced C5 screw.

popular until the mid-20th century. The initial procedures mainly included posterior decompression and posterior wiring for stabilization. Anterior approaches developed from surgery for head and neck pathology separate from spinal disease. Advances in imaging, operative microscopes, and instrumentation have allowed cervical spinal surgery to progress to the current state.

Since 1891 when the first cervical fusion procedure was performed there have been sequential advances described by many authors to develop the early fixation techniques.<sup>1-3,30-43</sup>

Several biomechanical animal and cadaver studies have been performed during the rapid advancement in cervical spinal instrumentation over the past 30 years. Posterior instrumented fusion studies have consistently proven the stiffness of the constructs to be equal to or greater than that of an intact spine.<sup>6,8,9,30,44-47</sup> The most common failure in these studies was screw pullout at a predictable amount of force.<sup>46</sup> Anterior plating studies have strongly guided the development of each type of system and have shown continued improvement in the efficacy of constructs.<sup>44,45,47</sup>

### Incidence of Complications

The advancements and improvements in cervical spinal instrumentation would be expected to decrease the rate of hardware-related complications. The overall complication rate of cervical spinal surgery is estimated to be 0.2% to 17.8%.<sup>4,17,27,48</sup> After 30 days, the most common complication is related to instrumentation dislodgement, breakage, or both, and occurs in 2% to 25% of cases of spinal fusion procedures.<sup>27</sup> Reoperation rate for instrumented spinal fusions is reported between 2% and 25%, with the majority related to pseudoarthrosis.<sup>27</sup>

There have been few studies looking at the complications related to instrumented cervical fusion. The majority of information is based on case reports, retrospective reviews, and small series of patients. There are few recent articles addressing

the rate of screw backout or misplacement requiring reoperation, and many older studies include the use of unrestricted devices that permitted screw backout.

Fehlings et al prospectively collected 302 cervical spondylotic myelopathy patients and found a perioperative complication rate of 15.6%, with 11.6% minor and 7.0% major perioperative risk.<sup>17</sup> Three patients had instrumentation malposition/migration for a rate of 1% in the perioperative period. The risk of delayed complications was 4.4%. Three patients had instrumentation/graft migration or instrumentation failure, making the risk of delayed hardware complications 1.1%. Not all patients in this small study received spinal instrumentation.<sup>17</sup>

Shapiro et al<sup>27</sup> reported on 299 consecutive spinal instrumentation cases. Of 195 anterior cervical plating procedures, 5 (2.6%) required reoperation for hardware failure.<sup>27</sup> Some of these failures were due to trauma around the time of surgery. Cole et al used the MarketScan Database and identified 13 662 patients who underwent anterior or posterior cervical fusion for degenerative disc disease.<sup>48</sup> The rate of any complication excluding dysphagia was 12.3% and 17.8% for anterior and posterior approaches, respectively. There is, however, no specific mention of the reason for reoperation in the study.<sup>48</sup>

In 2011, Katonis et al<sup>9</sup> reported on 1662 consecutively placed lateral mass screws. Screw pullout occurred in 3 (1.3%) patients, but they did not mention if these patients required reoperation or if the system was a screw-plate or polyaxial screw-rod implant system. The report also mentioned 11 (0.6%) screws had a suboptimal trajectory but no patient required reoperation for removal or replacement of hardware.<sup>9</sup> Al Barbarawi et al<sup>49</sup> had 2 screw pullout cases out of 430 lateral mass screw-rod fixation cases. Two (4.0%) cases were found to have screw pullout in the study by Kim et al using Yoon's method.<sup>50</sup>

Kasimatis et al included 74 patients from 1990 to 2005 who underwent anterior cervical treatment of cervical spine trauma

in their study looking at complications. Screw backout was reported in 4 (5.4%) cases, all of which were unrestricted back-out plates. Seven cases (9.5%) had “less-than-ideal” positioning of the construct with only one case requiring reoperation because of a malpositioned screw being completely in the intervertebral space.<sup>23</sup> Veeravagu et al looked at the MarketScan Database from 2006 and 2010 and found in 28 777 patients a reoperation rate of 9.13% and 10.7% for single-level and multi-level anterior cervical fusion, respectively.<sup>51</sup> Unfortunately, their data did not include data about the rate of reoperation related specifically to hardware failure. Shapiro et al found no screw pullout when using locking screw fixation in 246 consecutive anterior cervical fusion cases.<sup>52</sup>

Several reports exist in the literature of screw pullout resulting in dysphagia and sometimes erosion into the gastrointestinal tract.<sup>53-55</sup> They continue to document the incidence of screw pullout related to misplacement to be uncommon, but can result in complications with serious morbidity and increased costs.

Frequently screw pullout is related to malpositioned placement at the time of implantation. There are few studies that look directly at this relation. Coe et al performed a systematic review of lateral mass screw fixation, and implant removal was defined as a surgical procedure to correct malpositioned screws, screw breakout, or loosening. Reoperation as defined was necessary for 27 (1.2%) of 2185 screws placed in 294 patients across 5 studies.<sup>10,56-60</sup>

The limitations of the study pertain largely to it being retrospective in nature. Limited information was available to determine the number of patients with screw misplacement that did not require reoperation. There was also insufficient information within the screening population to determine the number of screws placed for comparison. The screening population was divided into anterior only and posterior or anterior/posterior combined groups. This does not allow for calculation of the incidence of posterior misplacement requiring revision, and it can only be speculated that this number would be much higher than the rate for anterior alone procedures.

## Conclusions

This study represents the largest series to analyze and tabulate the incidence of screw backout or misplacement requiring reoperation following cervical spine surgery. The data suggest this is a very rare adverse event, despite the widespread use of cervical fixation. Due to the methodology of this study, there is a potential for underestimation of screw misplacement requiring reoperation within this series of patients. This potential for underreporting is more likely to occur in the case of posterior cervical fusion as this could not be calculated based on this study. The data therefore represents a lower limit for the incidence of screw misplacement requiring reoperation. Patients suffering this complication require hardware revision, but do not usually suffer neurologic sequelae. These patients have extended hospital stays, which add to the cost of care.

Meticulous technique and thorough knowledge of the relevant anatomy are the best means of preventing this complication.

## Authors' Note

This study was ethically approved by the institutional ethics committees at all participating sites.

## Declaration of Conflicting Interests

The author(s) declared the following potential conflicts of interest with respect to the research, authorship, and/or publication of this article: Jeremy C. Peterson reports grants from AOSpine North America during the conduct of the study; Wellington K. Hsu reports grants from AOSpine North America during the conduct of the study, personal fees from Medtronic, personal fees from Stryker, personal fees from Bacterin, personal fees from Graftys, personal fees from Ceramtec, personal fees from Relievant, personal fees from Bioventus, personal fees from Globus, personal fees from SpineSmith, outside the submitted work; Michael G. Fehlings reports grants from AOSpine North America during the conduct of the study; Robert A. Hart reports grants from AOSpine North America during the conduct of the study, other from CSRS, other from ISSLS, other from ISSG Exec Board, personal fees from Depuy Synthes, personal fees from Globus, personal fees from Medtronic, other from Evans, Craven & Lackie, other from Benson, Bertoldo, Baker, & Carter, personal fees from Seaspine, personal fees from Depuy Synthes, other from Spine Connect, personal fees from Depuy Synthes, outside the submitted work; Alan S. Hilibrand reports grants from AOSpine North America during the conduct of the study, other from Amedica, Vertiflex, Benvenue, Lifespine, Paradigm Spine, PSD, Spinal Ventures, outside the submitted work, and in addition, Dr. Hilibrand has a patent Aesculap, Amedica, Biomet, Stryker, Alphatec, with royalties paid; Tony Tannoury reports grants from AOSpine North America during the conduct of the study; Thomas E. Mroz reports other from AO Spine during the conduct of the study, personal fees from Stryker, personal fees from Ceramtec, other from Pearl Diver, outside the submitted work; Bradford L. Currier reports grants from AOSpine North America during the conduct of the study, personal fees from DePuy Spine, personal fees from Stryker Spine, personal fees from Zimmer Spine, other from Zimmer Spine, other from Tenex, other from Spinology, other from LSRS, other from AOSNA, outside the submitted work; Jeremy L. Fogelson reports grants from AOSpine North America during the conduct of the study and Previous Consultant for one day to Depuy-Synthes March 2014; Bruce C. Jobse reports grants from AOSpine North America during the conduct of the study; Eric M. Massicotte reports grants from AOSpine North America during the conduct of the study, grants from Medtronic, Depuy-Synthes Spine Canada, personal fees from Watermark Consulting, grants from AOSpine North America, nonfinancial support from AOSpine North America, outside the submitted work; and K. Daniel Riew reports personal fees from AOSpine International, other from Global Spine Journal, other from Spine Journal, other from Neurosurgery, personal fees from Multiple Entities for defense, plaintiff, grants from AOSpine, grants from Cerapedics, grants from Medtronic, personal fees from AOSpine, personal fees from NASS, personal fees from Biomet, personal fees from Medtronic, nonfinancial support from Broadwater, outside the submitted work; Paul M. Arnold reports grants from AOSpine North America during the conduct of the study; other from Z-Plasty, other from Medtronic Sofamore Danek, other from Stryker Spine, other from FzioMed, other from AOSpine North America, other from Life Spine, other from Integra Life, other from Spine Wave, other from MIEMS, other from

Cerapedics, other from AOSpine North America, outside the submitted work; Zachary A. Smith reports grants from AOSpine North America during the conduct of the study; Ahmad Nassr reports grants from AOSpine North America during the conduct of the study; Ra'Kerry K. Rahman reports grants from AOSpine North America during the conduct of the study; in addition, Dr. Rahman has a patent Deformity System & Pedicle Screws pending. Chadi A. Tannoury reports grants from AOSpine North America during the conduct of the study; Anthony F. De Giacomo Dr. De Giacomo reports grants from AOSpine North America during the conduct of the study.

## Funding

The author(s) disclosed receipt of the following financial support for the research, authorship, and/or publication of this article: This study was sponsored by AOSpine North America Inc, a 501(c)3 nonprofit corporation.

## References

- Denaro V, Di Martino A. Cervical spine surgery: an historical perspective. *Clin Orthop Relat Res.* 2011;469:639-648.
- Hadra B. Wiring the spinous processes in fracture and Pott's disease. *Trans Am Orthop Assoc.* 1891;4:206-210.
- Roy-Camille R, Saillant G. Surgery of the cervical spine. 3. Complex fractures of the lower cervical spine. Tetraplegia [in French]. *Nouv Presse Med.* 1972;1:2707-2709.
- Fineberg SJ, Ahmadinia K, Oglesby M, Patel AA, Singh K. Hospital outcomes and complications of anterior and posterior cervical fusion with bone morphogenetic protein. *Spine (Phila Pa 1976).* 2013;38:1304-1309.
- Abumi K, Shono Y, Ito M, Taneichi H, Kotani Y, Kaneda K. Complications of pedicle screw fixation in reconstructive surgery of the cervical spine. *Spine (Phila Pa 1976).* 2000;25:962-969.
- Brodke DS, Anderson PA, Newell DW, Grady MS, Chapman JR. Comparison of anterior and posterior approaches in cervical spinal cord injuries. *J Spinal Disord Tech.* 2003;16:229-235.
- Deen HG, Birch BD, Wharen RE, Reimer R. Lateral mass screw-rod fixation of the cervical spine: a prospective clinical series with 1-year follow-up. *Spine J.* 2003;3:489-495.
- Jones EL, Heller JG, Silcox DH, Hutton WC. Cervical pedicle screws versus lateral mass screws. Anatomic feasibility and biomechanical comparison. *Spine (Phila Pa 1976).* 1997;22:977-982.
- Katonis P, Papadakis SA, Galanakos S, et al. Lateral mass screw complications: analysis of 1662 screws. *J Spinal Disord Tech.* 2011;24:415-420.
- Pateder DB, Carbone JJ. Lateral mass screw fixation for cervical spine trauma: associated complications and efficacy in maintaining alignment. *Spine J.* 2006;6:40-43.
- Bapat MR, Chaudhary K, Sharma A, Laheri V. Surgical approach to cervical spondylotic myelopathy on the basis of radiological patterns of compression: prospective analysis of 129 cases. *Eur Spine J.* 2008;17:1651-1663.
- Bilbao G, Duarte M, Aurrecochea JJ, et al. Surgical results and complications in a series of 71 consecutive cervical spondylotic corpectomies. *Acta Neurochir (Wien).* 2010;152:1155-1163.
- Boakye M, Patil CG, Santarelli J, Ho C, Tian W, Lad SP. Cervical spondylotic myelopathy: complications and outcomes after spinal fusion. *Neurosurgery.* 2008;62:455-461.
- Casha S, Engelbrecht HA, DuPlessis SJ, Hurlbert RJ. Suspended laminoplasty for wide posterior cervical decompression and intradural access: results, advantages, and complications. *J Neurosurg Spine.* 2004;1:80-86.
- Edwards CC 2nd, Heller JG, Murakami H. Corpectomy versus laminoplasty for multilevel cervical myelopathy: an independent matched-cohort analysis. *Spine (Phila Pa 1976).* 2002;27:1168-1175.
- Edwards CC 2nd, Heller JG, Silcox DH 3rd. T-Saw laminoplasty for the management of cervical spondylotic myelopathy: clinical and radiographic outcome. *Spine (Phila Pa 1976).* 2000;25:1788-1794.
- Fehlings MG, Smith JS, Kopjar B, et al. Perioperative and delayed complications associated with the surgical treatment of cervical spondylotic myelopathy based on 302 patients from the AOSpine North America Cervical Spondylotic Myelopathy Study. *J Neurosurg Spine.* 2012;16:425-432.
- Hashimoto M, Mochizuki M, Aiba A, et al. C5 palsy following anterior decompression and spinal fusion for cervical degenerative diseases. *Euro Spine J.* 2010;19:1702-1710.
- Heller JG, Edwards CC 2nd, Murakami H, Rodts GE. Laminoplasty versus laminectomy and fusion for multilevel cervical myelopathy: an independent matched cohort analysis. *Spine (Phila Pa 1976).* 2001;26:1330-1336.
- Ikenaga M, Shikata J, Tanaka C. Radiculopathy of C-5 after anterior decompression for cervical myelopathy. *J Neurosurg Spine.* 2005;3:210-217.
- Imagama S, Matsuyama Y, Yukawa Y, et al. C5 palsy after cervical laminoplasty: a multicentre study. *J Bone Joint Surg Br.* 2010;92:393-400.
- Kaminsky SB, Clark CR, Traynelis VC. Operative treatment of cervical spondylotic myelopathy and radiculopathy. A comparison of laminectomy and laminoplasty at five year average follow-up. *Iowa Orthop J.* 2004;24:95-105.
- Kasimatis GB, Panagiotopoulos E, Gliatis J, Tyllianakis M, Zouboulis P, Lambiris E. Complications of anterior surgery in cervical spine trauma: an overview. *Clin Neurol Neurosurg.* 2009;111:18-27.
- Kristof RA, Kiefer T, Thudium M, et al. Comparison of ventral corpectomy and plate-screw-instrumented fusion with dorsal laminectomy and rod-screw-instrumented fusion for treatment of at least two vertebral-level spondylotic cervical myelopathy. *Eur Spine J.* 2009;18:1951-1956.
- Naderi S, Alberstone CD, Rupp FW, Benzel EC, Baldwin NG. Cervical spondylotic myelopathy treated with corpectomy: technique and results in 44 patients. *Neurosurg Focus.* 1996;1(6):e5.
- Nagashima H, Dokai T, Hashiguchi H, et al. Clinical features and surgical outcomes of cervical spondylotic myelopathy in patients aged 80 years or older: a multi-center retrospective study. *Eur Spine J.* 2011;20:240-246.
- Shapiro SA, Snyder W. Spinal instrumentation with a low complication rate. *Surg Neurol.* 1997;48:566-574.
- Woods BI, Hohl J, Lee J, Donaldson W 3rd, Kang J. Laminoplasty versus laminectomy and fusion for multilevel cervical



- spondylotic myelopathy. *Clin Orthop Relat Res.* 2011;469:688-695.
29. Yang HS, Chen DY, Lu XH, et al. Choice of surgical approach for ossification of the posterior longitudinal ligament in combination with cervical disc hernia. *Eur Spine J.* 2010;19:494-501.
  30. Omeis I, DeMattia JA, Hillard VH, Murali R, Das K. History of instrumentation for stabilization of the subaxial cervical spine. *Neurosurg Focus.* 2004;16(1):E10.
  31. An HS, Coppes MA. Posterior cervical fixation for fracture and degenerative disc disease. *Clin Orthop Relat Res.* 1997;(335):101-111.
  32. Anderson PA, Henley MB, Grady MS, Montesano PX, Winn HR. Posterior cervical arthrodesis with AO reconstruction plates and bone graft. *Spine (Phila Pa 1976).* 1991;16(3 suppl):S72-S79.
  33. Jeanneret B. Posterior rod system of the cervical spine: a new implant allowing optimal screw insertion. *Eur Spine J.* 1996;5:350-356
  34. Xu R, Haman SP, Ebraheim NA, Yeasting RA. The anatomic relation of lateral mass screws to the spinal nerves. A comparison of the Magerl, Anderson, and An techniques. *Spine (Phila Pa 1976).* 1999;24:2057-2061.
  35. Fielding JW. The status of arthrodesis of the cervical spine. *J Bone Joint Surg Am.* 1988;70:1571-1574.
  36. Abumi K, Itoh H, Taneichi H, Kaneda K. Transpedicular screw fixation for traumatic lesions of the middle and lower cervical spine: description of the techniques and preliminary report. *J Spinal Disord.* 1994;7:19-28.
  37. Bailey RW, Badgley CE. Stabilization of the cervical spine by anterior fusion. *J Bone Joint Surg Am.* 1960;42:565-594.
  38. Robinson RA, Smith GW. Anterolateral cervical disc removal and interbody fusion for cervical disc syndrome. *Bull Johns Hopkins Hosp.* 1955;96:223-224.
  39. Cloward RB. The anterior approach for removal of ruptured cervical disks. *J Neurosurg.* 1958;15:602-617.
  40. Orozco Delclos R, Llovet Tapias J. Osteosintesis en las fracturas de raquis cervical. Nota de tecnica. *Rev Ortop Traumatol.* 1970;14:285-288.
  41. Caspar W, Barbier DD, Klara PM. Anterior cervical fusion and Caspar plate stabilization for cervical trauma. *Neurosurgery.* 1989;25:491-502.
  42. McCullen GM, Garfin SR. Spine update: cervical spine internal fixation using screw and screw-plate constructs. *Spine (Phila Pa 1976).* 2000;25:643-652.
  43. White AA 3rd, Panjabi MM. Biomechanical considerations in the surgical management of cervical spondylotic myelopathy. *Spine (Phila Pa 1976).* 1988;13:856-860.
  44. Kalf R, Ulrich C, Claes L, Wilke HJ, Grote W. Comparative experimental biomechanical study of different types of stabilization methods of the lower cervical spine. *Neurosurg Rev.* 1992;15:259-264.
  45. Lambiris E, Kasimatis GB, Tyllianakis M, Zouboulis P, Panagiotopoulos E. Treatment of unstable lower cervical spine injuries by anterior instrumented fusion alone. *J Spinal Disord Tech.* 2008;21:500-507.
  46. Smith ME, Cibischino M, Langrana NA, Lee CK, Parsons JR. A biomechanical study of a cervical spine stabilization device: Roy-Camille plates. *Spine (Phila Pa 1976).* 1997;22:38-43.
  47. Ulrich C, Worsdorfer O, Claes L, Magerl F. Comparative study of the stability of anterior and posterior cervical spine fixation procedures. *Arch Orthop Trauma Surg.* 1987;106:226-231.
  48. Cole T, Veeravagu A, Zhang M, Azad TD, Desai A, Ratliff JK. Anterior versus posterior approach for multilevel degenerative cervical disease: a retrospective propensity score-matched study of the MarketScan Database. *Spine (Phila Pa 1976).* 2015;40:1033-1038.
  49. Al Barbarawi MM, Allouh MZ. Cervical lateral mass screw-rod fixation: surgical experience with 2500 consecutive screws, an analytical review, and long-term outcomes. *Br J Neurosurg.* 2015;29:699-704.
  50. Kim Do Y, Kim JY, Yoon SH, Park HC, Park CO. Radiological efficacy of cervical lateral mass screw insertion and rod fixation by modified Magerl's method (Yoon's method) with minimum 2 years of follow-up. *Korean J Spine.* 2012;9:137-141.
  51. Veeravagu A, Cole T, Jiang B, Ratliff JK. Revision rates and complication incidence in single- and multilevel anterior cervical discectomy and fusion procedures: an administrative database study. *Spine J.* 2014;14:1125-1131.
  52. Shapiro S, Connolly P, Donaldson J, Abel T. Cadaveric fibula, locking plate, and allogeneic bone matrix for anterior cervical fusions after cervical discectomy for radiculopathy or myelopathy. *J Neurosurg.* 2001;95(1 suppl):43-50.
  53. Azadarmaki R, Soliman AM. Progressive dysphagia in a patient with a history of cervical spine fusion. *JAMA Otolaryngol Head Neck Surg.* 2014;140:675-676.
  54. Fountas KN, Kapsalaki EZ, Machinis T, Robinson JS. Extrusion of a screw into the gastrointestinal tract after anterior cervical spine plating. *J Spinal Disord Tech.* 2006;19:199-203.
  55. Wojtowicz P, Szafarowski T, Migacz E, Krzeski A. Recurrent laryngeal edema imitating angioedema caused by dislocated screw after anterior spine surgery. *Case Rep Otolaryngol.* 2015;2015:749463.
  56. Al Barbarawi MM, Audat ZA, Obeidat MM, et al. Decompressive cervical laminectomy and lateral mass screw-rod arthrodesis. Surgical analysis and outcome. *Scoliosis.* 2011;6:10.
  57. Coe JD, Vaccaro AR, Dailey AT, et al. Lateral mass screw fixation in the cervical spine: a systematic literature review. *J Bone Joint Surg Am.* 2013;95:2136-2143.
  58. Heller JG, Silcox DH 3rd, Sutterlin CE 3rd. Complications of posterior cervical plating. *Spine (Phila Pa 1976).* 1995;20:2442-2448.
  59. Stevens QE, Majd ME, Kattner KA, Jones CL, Holt RT. Use of spinous processes to determine the optimal trajectory for placement of lateral mass screws: technical note. *J Spinal Disord Tech.* 2009;22:347-352.
  60. Wellman BJ, Follett KA, Traynelis VC. Complications of posterior articular mass plate fixation of the subaxial cervical spine in 43 consecutive patients. *Spine (Phila Pa 1976).* 1998;23:193-200.