

12-1-2022

Myocardial Infarction With Nonobstructive Coronary Arteries in New-onset Inflammatory Bowel Disease

Benjamin B. Claxton
Thomas Jefferson University

George Sun
Thomas Jefferson University

Ritu Nahar
Thomas Jefferson University

Christopher Henry
Thomas Jefferson University

Follow this and additional works at: https://jdc.jefferson.edu/gastro_hepfp

 Part of the [Gastroenterology Commons](#)

[Let us know how access to this document benefits you](#)

Recommended Citation

Claxton, Benjamin B.; Sun, George; Nahar, Ritu; and Henry, Christopher, "Myocardial Infarction With Nonobstructive Coronary Arteries in New-onset Inflammatory Bowel Disease" (2022). *Division of Gastroenterology and Hepatology Faculty Papers*. Paper 86.
https://jdc.jefferson.edu/gastro_hepfp/86

This Article is brought to you for free and open access by the Jefferson Digital Commons. The Jefferson Digital Commons is a service of Thomas Jefferson University's [Center for Teaching and Learning \(CTL\)](#). The Commons is a showcase for Jefferson books and journals, peer-reviewed scholarly publications, unique historical collections from the University archives, and teaching tools. The Jefferson Digital Commons allows researchers and interested readers anywhere in the world to learn about and keep up to date with Jefferson scholarship. This article has been accepted for inclusion in Division of Gastroenterology and Hepatology Faculty Papers by an authorized administrator of the Jefferson Digital Commons. For more information, please contact: JeffersonDigitalCommons@jefferson.edu.

Myocardial Infarction With Nonobstructive Coronary Arteries in New-onset Inflammatory Bowel Disease

Benjamin B. Claxton, MD MPH,*^{id} George Sun, BS,* Ritu Nahar, MD,* and Christopher Henry, MD*

*Division of Gastroenterology & Hepatology, Department of Medicine, Thomas Jefferson University Hospitals, Philadelphia, PA, USA
Address correspondence to: Benjamin B. Claxton, MD, MPH, 1025 Walnut St. Suite 805, Philadelphia, PA 19107, USA (BClaxtonMD@gmail.com).

Inflammatory bowel disease (IBD) is a systemic pro-inflammatory condition with rare cardiovascular extraintestinal manifestations. Increasing evidence links gut inflammation and cardiovascular pathology, with myopericarditis encompassing approximately 70% of cases.^{1–3} Myocardial infarction with nonobstructive coronary arteries (MINOCA) has not been described in this population.⁴

A 36-year-old man with a history of gastroesophageal reflux disease and hypertension presented with a 10-day history of fever, hematochezia, and abdominal pain. Negative history included no travel, suspect foods, or drug use. Family history was negative for IBD or cardiac disease. Exam was unremarkable except for mild abdominal tenderness in bilateral lower quadrants. Labs revealed elevated white blood cell count, C-reactive protein, and erythrocyte sedimentation rate. Admission troponin and electrocardiogram (ECG) were normal.

Computed tomography (CT) abdomen and pelvis revealed diffuse bowel wall thickening and associated mesenteric inflammation of the entire colon. A stool infectious panel was negative. Sigmoidoscopy demonstrated diffuse continuous ulceration, friability, and granularity up to the splenic flexure (Figure 1A). Colon biopsies demonstrated diffuse, markedly active colitis. Although pathology had no evidence of chronicity, given a negative workup for infection or ischemia, no offending medications, no response to antibiotics, a characteristic endoscopic appearance, and a worsening clinical course that ultimately responded only to steroids, it was determined to be a diagnosis of early and new-onset ulcerative colitis.

On day 4 of steroids, the patient noted severe chest pain. Electrocardiogram revealed new ST elevations (Figure 1B). High-sensitivity troponin was newly elevated to 1218 ng/L. Transthoracic echocardiogram (TTE) while having chest pain was normal and without wall motion abnormalities. A CT angiogram (CTA) chest revealed no aortic dissection. A CTA of the coronary arteries showed no calcifications or wall motion abnormalities. Two days after his chest pain, he underwent cardiac magnetic resonance imaging (MRI). Imaging revealed transmural enhancement of the left ventricular apex with associated akinesia—signs associated with infarct (Figure 1C). Notably, there was no sign of myocarditis. With new concern

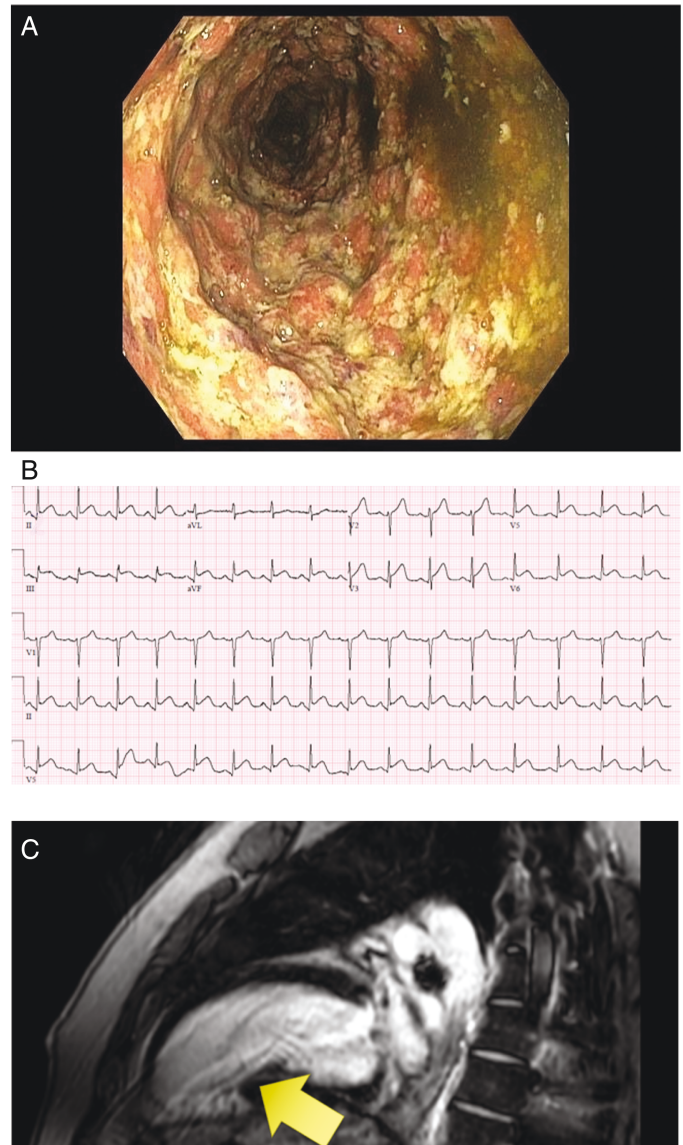


Figure 1. A, Colon with ulceration, friability, and granularity. B, ECG with anterolateral, inferior 1–2mm ST segment elevation. C, Cardiac MR with transmural enhancement of the LV.

for MINOCA, the patient was treated for acute myocardial infarction.

This case highlights a rare cardiac manifestation of IBD, unrelated to medication. Initial workup including ECG, TTE, and CTA were all without infarct territory or wall motion abnormalities. Computed tomography angiogram of the coronary arteries has a high negative predictive value for obstructive coronary artery disease.⁵ Therefore, MINOCA is the most accurate diagnosis. Given the sparsity of literature regarding MINOCA, further investigation is needed to delineate the incidence of MINOCA and nonpharmacologic-associated cardiac events in IBD.

Conflicts of Interest

The authors have no disclosures or conflicts of interest to declare.

References

1. Patel RS, Rohit Reddy S, Llukmani A, et al. Cardiovascular manifestations in inflammatory bowel disease: a systematic review of the pathogenesis and management of pericarditis. *Cureus*. 2021;13(3):e14010.
2. Singh S, Singh H, Loftus EV, Pardi DS. Risk of cerebrovascular accidents and ischemic heart disease in patients with inflammatory bowel disease: a systematic review and meta-analysis. *Clin Gastroenterol Hepatol*. 2014;12(3):382-93.e1: quiz e22.
3. Filimon AM, Negreanu L, Doca M, et al. Cardiovascular involvement in inflammatory bowel disease: dangerous liaisons. *World J Gastroenterol*. 2015;21(33):9688-9692.
4. Caio G, Lungaro L, Caputo F, et al. Recurrent myocarditis in a patient with active ulcerative colitis: a case report and review of the literature. *BMJ Open Gastroenterol*. 2021;8:e000587. doi:10.1136/bmjgast-2020-000587.
5. Roberts WT, Bax JJ, Davies LC. Cardiac CT and CT coronary angiography: technology and application. *Heart*. 2008;94(6):781-792.