

10-1-2017

## An investigation of human beta-defensins and cathelicidin expression in patients with pterygium.

Remzi Karadag

*Thomas Jefferson University; Istanbul Medeniyet University School of Medicine*

Nurettin Bayram

*Ipekyolu Government Hospital*

Serpil Oguztuzun

*Kirikkale University School of Medicine*

Huseyin Bayramlar

*Istanbul Medeniyet University School of Medicine*

Busra Bozer

*Hitit University*

Follow this and additional works at: <https://jdc.jefferson.edu/willsfp>

 Part of the [Jefferson Digital Commons](#)

**Let us know how access to this document benefits you**

### Recommended Citation

Karadag, Remzi; Bayram, Nurettin; Oguztuzun, Serpil; Bayramlar, Huseyin; Bozer, Busra; Simsek, Gulcin; and Rapuano, Christopher J, "An investigation of human beta-defensins and cathelicidin expression in patients with pterygium." (2017). *Wills Eye Hospital Papers*. Paper 77.  
<https://jdc.jefferson.edu/willsfp/77>

This Article is brought to you for free and open access by the Jefferson Digital Commons. The Jefferson Digital Commons is a service of Thomas Jefferson University's [Center for Teaching and Learning \(CTL\)](#). The Commons is a showcase for Jefferson books and journals, peer-reviewed scholarly publications, unique historical collections from the University archives, and teaching tools. The Jefferson Digital Commons allows researchers and interested readers anywhere in the world to learn about and keep up to date with Jefferson scholarship. This article has been accepted for inclusion in Wills Eye Hospital Papers by an authorized administrator of the Jefferson Digital Commons. For more information, please contact: [JeffersonDigitalCommons@jefferson.edu](mailto:JeffersonDigitalCommons@jefferson.edu).

---

**Authors**

Remzi Karadag, Nurettin Bayram, Serpil Oguztuzun, Huseyin Bayramlar, Busra Bozer, Gulcin Simsek, and Christopher J Rapuano

# An investigation of human beta-defensins and cathelicidin expression in patients with pterygium

## *Uma investigação da expressão de beta-defensinas humanas e de catelicidina em pacientes com pterígio*

REMZI KARADAG<sup>1,2</sup>, NURETTIN BAYRAM<sup>3</sup>, SERPIL OGUZTUZUN<sup>4</sup>, HUSEYIN BAYRAMLAR<sup>1</sup>, BUSRA BOZER<sup>5</sup>, GULCIN SIMSEK<sup>6</sup>, CHRISTOPHER J. RAPUANO<sup>2</sup>

### ABSTRACT

**Purpose:** To investigate human beta-defensins (HBDs) and cathelicidin LL-37 (LL-37) expressions in patients with pterygium.

**Methods:** In this retrospective consecutive case series, 26 pterygium specimens and 15 normal conjunctival specimens of 15 control subjects were investigated. Expressions of HBD-1, HBD-2, HBD-3, and LL-37 were assessed using immunohistochemical staining. A brown color in the cytoplasm and/or nuclei of epithelial cells indicated positive staining for HBDs and LL-37. For each antibody, the intensity of the reaction (negative [-], weak [1+], moderate [2+], or strong [3+]) was determined to describe the immunoreactions.

**Results:** The median age was 52 years in both groups. There were no significant differences in age and sex between the groups ( $p=0.583$ ,  $p=0.355$ , respectively). Of the 26 pterygium specimens, 15 (57.7%) (14 weak, 1 moderate staining) showed HBD-2 expression, which was not observed in any of the control specimens. One (3.8%) pterygium and one (6.7%) control specimen demonstrated weak staining for HBD-3. HBD-2 expression was significantly higher in the pterygium specimens than in the controls ( $p=0.002$ ). None of the tissue specimens had positive staining for HBD-1 or LL-37 in either group (both;  $p=1.00$ ).

**Conclusions:** HBD-2 expression was higher in pterygium specimens than in the controls. HBD-2 expression that might be stimulated by inflammatory cytokines may be related to inflammation and fibrovascular proliferation and may play a role in pterygium pathogenesis.

**Keywords:** Cathelicidins; Beta-defensins; Immunohistochemical; Inflammation; Pterygium/pathology

### RESUMO

**Objetivo:** Investigar as expressões beta defensinas humanas (HBD) e catelicidina em pacientes com pterígio.

**Métodos:** Nesta série de casos retrospectivos consecutivos, 26 espécimes de pterígio e 15 espécimes conjuntivais normais de 15 indivíduos controle foram investigados. As expressões de HBD-1, HBD-2, HBD-3 e catelicidina (LL-37) foram avaliadas por coloração imuno-histoquímica. Uma cor castanha no citoplasma ou nos núcleos de células epiteliais foi definida como coloração positiva para HBDs e LL-37. Para cada anticorpo foi determinada a intensidade da reação (negativo [-], fraco [1+], moderado [2+] ou forte [3+]) para descrever as imunoreações.

**Resultados:** A idade média foi de 52 anos em ambos os grupos. Não houve diferença significativa entre os grupos em termos de idade e sexo ( $p=0,583$ ,  $p=0,355$ , respectivamente). Das 26 amostras de pterígio, 15 (57,7%) (14 fracas e 1 moderada) demonstraram a expressão de HBD-2 enquanto não foi encontrada em nenhum dos espécimes de controle. Um dos pterígios (3,8%) e um dos espécimes de controle (6,7%) demonstraram fraca coloração para HBD-3. A expressão de HBD-2 foi significativamente maior nos espécimes de pterígio do que nos controles ( $p=0,002$ ). Nenhum dos espécimes de tecido apresentou coloração positiva para HBD-1 ou LL-37 em ambos os grupos (ambos  $p=1,00$ ).

**Conclusão:** Encontramos aumento da expressão de HBD-2 em espécimes de pterígio em relação aos controles. A expressão de HBD-2 que pode ser estimulada por citocinas inflamatórias pode estar relacionada com inflamação e proliferação fibrovascular e pode desempenhar um papel na patogênese do pterígio.

**Descritores:** Catelicidinas; Beta defensinas; Imunohistoquímica; Inflamação; Pterígio/pathologia

### INTRODUCTION

Pterygia develop from the growth of fibrovascular tissue of bulbar conjunctiva into the interpalpebral area of the cornea. Although the pathogenesis is not completely understood, oxidative stress, immunogenic mechanisms, anti-apoptosis, extracellular matrix remodeling, angiogenesis, viral infections, and genetic factors are considered to be contributing factors. Epidemiological studies have shown that chronic ultraviolet exposure has a major role in pterygium pathogenesis<sup>(1)</sup>. Ultimately, chronic inflammation due to some or all of the above factors probably causes fibrovascular proliferation. Cytokines, growth factors, stem cell factors, and pro-angiogenic factors may all have a role in inflammation and fibrovascular proliferation of pathogenesis of pterygium<sup>(1)</sup>. It has been shown that the expression

of human alpha-defensin, which is an antimicrobial peptide (AMP), is increased in the tears of patients with pterygia because of fibrovascular proliferation or associated inflammation<sup>(2)</sup>. In addition, it has been reported that some AMPs may be stimulated by proinflammatory cytokines, such as interleukin (IL)-1 alpha, IL-1 beta, and tumor necrosis factor-alpha<sup>(3,4)</sup>.

AMPs provide one of the defense mechanisms that are part of the innate immune response against exogenous pathogens. AMPs are divided into two major groups: defensins and cathelicidins. Human defensins are also divided into two groups: alpha and beta<sup>(5)</sup>. Human beta-defensins (HBD) have four subgroups (1 to 4) and are primarily expressed in epithelial tissues. However, HBD-1 and -2 are also present in immune cells, such as monocytes, macrophages, and

Submitted for publication: February 1, 2017

Accepted for publication: March 19, 2017

<sup>1</sup> Department of Ophthalmology, Istanbul Medeniyet University School of Medicine, Goztepe, Istanbul, Turkey.

<sup>2</sup> Cornea Service, Wills Eye Hospital, Sidney Kimmel Medical College at Thomas Jefferson University, Philadelphia, PA, USA.

<sup>3</sup> Department of Ophthalmology, Ipekyolu Government Hospital, Van, Turkey.

<sup>4</sup> Department of Biology, Kirikkale University School of Medicine, Kirikkale, Turkey.

<sup>5</sup> Scientific Technical Research and Application Center, Hitit University, Corum, Turkey.

<sup>6</sup> Department of Pathology, Keçioren Research and Training Hospital, Ankara, Turkey.

**Funding:** No specific financial support was available for this study.

**Disclosure of potential conflicts of interest:** None of the authors have any potential conflict of interest to disclose.

**Corresponding author:** Remzi Karadag, Department of Ophthalmology, Istanbul Medeniyet University School of Medicine, Goztepe-Istanbul, Turkey - E-mail: drkrkaradag@yahoo.com

**Approved by the following research ethics committee:** Istanbul Medeniyet University (#01/2011)..

dendritic cells<sup>(6)</sup>. It has been shown that the expressions of HBD-2 and -3 are stimulated by some cytokines<sup>(3-7)</sup>. Although HBD-1 and -3 have been found in healthy corneal and conjunctival epithelial cells, HBD-2 expression has not been found or is present only at very low levels in normal cells. On the other hand, HBD-2 expression has been found to be increased in inflammatory cells related to dry-eye syndrome<sup>(3,4)</sup>. Cathelicidins are the second group of AMPs. In humans the group is represented only by cathelicidin LL-37 (LL-37), a molecule that is expressed in corneal and conjunctival epithelial cells<sup>(8,9)</sup>. This peptide has also been found to be expressed after corneal epithelial trauma and in response to some bacterial infections<sup>(10,11)</sup>.

In previous studies, increased human alpha-defensin has been found in the tears of patients with pterygia<sup>(2)</sup>, and increased expression of HBD-2 has been found in conjunctival impression cytological specimens of patients with dry-eye syndrome<sup>(3)</sup>. To our knowledge, this is the first report of AMP expression in pterygium specimens in the literature. In this study, our aim was to investigate the expression of HBDs and cathelicidin in pterygium specimens, and whether their presence correlated with disease severity.

## METHODS

### INCLUSION CRITERIA AND DATA COLLECTION

The multicenter study protocol was carried out in accordance with the Helsinki Declaration as revised in 2013 and was approved by the local ethics committee. Written informed consent was obtained from each subject before surgery. The unused tissue specimens from our previous study, entitled "GST levels in patients with pterygium"<sup>(12)</sup>, were included in the study. Written informed consent allowing their tissue to be used for investigational testing was obtained from each subject before surgery in the previous study<sup>(12)</sup>.

### PATIENT DETAILS AND SPECIMENS

Twenty-six pterygium specimens and 15 control specimens of otherwise healthy patients who were undergoing cataract or strabismus surgery were included in the study. A detailed ophthalmic examination was performed for each patient, and pterygia were graded as follows: grade 1, a pterygium that did not prevent the visibility of episcleral vessels and had only mild inflammatory clinical signs; grade 2, episcleral vessels that could be partly seen and presence of moderate inflammatory signs; grade 3, a relatively thick pterygium that completely prevented the visibility of episcleral vessels and had severe inflammatory signs. Excised pterygium tissue and 1 x 2-mm specimens of conjunctival tissue from the control eyes were sent to the Pathology Department for immunohistochemical staining. Unused specimens from the previous study were prepared again by the staff of the Pathology Department for immunohistochemical staining.

### IMMUNOHISTOCHEMICAL STAINING TECHNIQUE

Biopsies were fixed immediately in 10% buffered formalin and embedded in paraffin blocks. Sections were cut 4- $\mu$ m thick, and one section was stained with hematoxylin and eosin to assess the tissue morphology and tumor score. For immunohistochemistry, endogenous peroxidase activity was blocked by incubating the sections in 1% hydrogen peroxide (v/v) in methanol for 10 minutes at room temperature (RT). The sections were subsequently washed in distilled water for 5 minutes, and antigen retrieval using 0.01M citrate buffer (pH 6.0) in a domestic pressure cooker was performed for 3 minutes. The sections were transferred in 0.05M Tris-HCl (pH 7.6) containing 0.15M sodium chloride Tris-buffered saline (TBS). After washing with water, the sections were incubated at RT for 10 minutes with super block (SHP125) (ScyTek Laboratories, Logan, UT, USA) to block nonspecific background staining. The sections were then covered with the

primary antibodies diluted 1:300 for anti-HBD-3, 1:400 for anti-HBD-2, 1:350 for anti-HBD-1, and 1:50 for anti-LL-37 in TBS at 4°C overnight. Anti-HBD-1 (PA1450) was obtained from Boster Bio., Pleasanton, CA, United States., anti-HBD-2 (sc-59494) was from Santa Cruz Inc., Santa Cruz, CA, USA, USA; anti-HBD-3 (NB200-117) was from Novus Biologicals Inc., Littleton, CO, USA; and LL-37 (sc-166770) was from Santa Cruz Biotechnology Inc., Santa Cruz, CA, USA, USA).

After washing in TBS for 15 minutes, the sections were incubated at RT in biotinylated link antibody (SHP125) (ScyTek Laboratories). Then, treatment was followed with Streptavidin/HRP complex (SHP125) (ScyTek Laboratories). Diaminobenzidine was used to visualize peroxidase activity in the tissues. Nuclei were lightly counterstained with hematoxylin, and then the sections were dehydrated and mounted. Both positive and negative controls were included in each run. The positive controls consisted of sections of spleen tissues for LL-37, skin tissues for HBD-3, kidney tissues for HBD-1, and colon-bladder tissues for HBD-2. TBS was used in place of the primary antibody for negative controls.

## HISTOPATHOLOGICAL EVALUATION

Light microscopy of immunohistochemically stained sections was performed by a pathologist and a biologist who had no knowledge of the patients' clinical information. Distribution, localization, and characteristics of the immunostaining were recorded. Brown color in the cytoplasm and/or nuclei of epithelial cells of the epidermis' basal layer were considered as positive staining. Scoring was also performed by two observers unaware of the patient data. Scoring differences between the observers were resolved by consensus. For each antibody, the intensity of the reaction (negative [-], weak [1+], moderate [2+], or strong [3+]) was determined to describe the immunoreactions.

## STATISTICAL ANALYSIS

Statistical analyses were performed by using the SPSS software version 16 (SPSS Inc., Chicago, IL, USA). Descriptive statistical methods (mean, standard deviation, median, frequency, ratio, minimum, maximum), the Mann-Whitney U test and chi-square test were used in the evaluation of this study's data. The Wilcoxon signed rank test was used for unequally distributed data in group comparisons. The Spearman correlation test was used for evaluating the data between groups. P values <0.05 were accepted as indicating statistical significance.

## RESULTS

### BASELINE CHARACTERISTICS

This study included 26 primary pterygium tissue specimens (11 males, 15 females) and 15 control (9 males, 6 females) subjects' specimens. The pterygium group involved 16 grade 2 and 10 grade 3 pterygium tissue specimens. The median age was 52 years (range, 34-68 years) and 52 years (range, 29-64 years) in the pterygium group and control group, respectively. There were no significant differences in age and sex between groups ( $p=0.583$ ,  $p=0.355$  respectively) (Table 1).

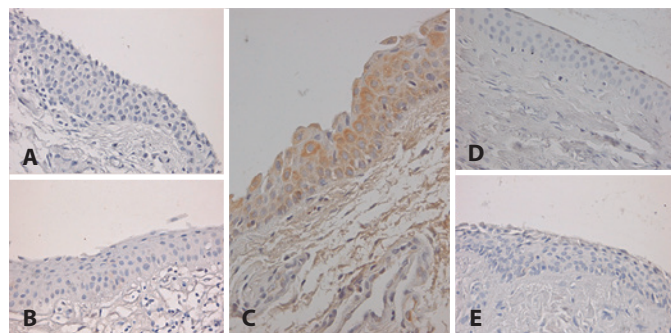
### IMMUNOHISTOCHEMICAL STAINING RESULTS

HBD-1, HBD-2, HBD-3, and LL-37 levels in both groups are shown in table 1. HBD-2 levels were statistically significantly higher in the pterygium group than in the control group ( $p=0.002$ ) (Figure 1). No significant differences in HBD-1 levels ( $p=1.00$ ), HBD-3 levels ( $p=0.883$ ), and LL-37 levels ( $p=1.00$ ) were found between the pterygium group and control group (Table 1 and Figure 1).

There was no statistically significant correlation between the pterygium grade and HBD-2 level ( $r=0.090$ ,  $p=0.661$ ) (Table 2).

**Table 1. Demographic data and HBD and LL-37 levels in the study and control groups**

|                          |                         | Pterygium (n) | Control (n) | P value      |
|--------------------------|-------------------------|---------------|-------------|--------------|
| Age median (range) years |                         | 52 (34-68)    | 52 (29-64)  | 0.583        |
| Sex (F/M)                |                         | 11/15         | 9/6         | 0.355        |
| HBD-1                    | Negative (-)            | 26            | 15          | 1.000        |
|                          | Weak (1+) moderate (2+) |               |             |              |
|                          | Strong (3+)             |               |             |              |
| HBD-2                    | Negative (-)            | 11            | 15          | <b>0.002</b> |
|                          | Weak (1+) moderate (2+) | 15            |             |              |
|                          | Strong (3+)             |               |             |              |
| HBD-3                    | Negative (-)            | 25            | 14          | 0.883        |
|                          | Weak (1+) moderate (2+) | 1             | 1           |              |
|                          | Strong (3+)             |               |             |              |
| LL-37                    | negative (-)            | 26            | 15          | 1.000        |
|                          | weak (1+) moderate (2+) |               |             |              |
|                          | strong (3+)             |               |             |              |



**Figure 1.** The expressions of human beta-defensins (HBDs) and cathelicidin peptides in pterygium shown with immunohistochemical staining. A) Negative HBD-2 expression. B) Negative HBD-1 expression. C) 2 positive HBD-2 peptide expressions. D) Negative HBD-3 expression; and E) Negative LL-37 expression.

**Table 2. Immunohistochemical staining scores**

| Pterygium                   | Immunohistochemical staining score |    |    |    |
|-----------------------------|------------------------------------|----|----|----|
|                             | HBD-2 (n)                          |    |    |    |
|                             | -                                  | 1+ | 2+ | 3+ |
| Grade1                      | 0                                  | 0  | 0  | 0  |
| Grade 2                     | 7                                  | 9  | 0  | 0  |
| Grade 3                     | 4                                  | 5  | 1  | 0  |
| Correlation coefficient (r) | 0.090                              |    |    |    |
| P value                     | 0.661                              |    |    |    |

**DISCUSSION**

In this study, we determined if the AMPs of HBD-1, HBD-2, HBD-3, and LL-37 were associated with pterygium pathogenesis. We found a higher level of HBD-2 in pterygium specimens than in controls, but HBD-1, HBD-3, and LL-37 levels were similar between the groups.

AMPs serve as a member of the innate immune system on the ocular surface. These peptides are multifunctional and have nu-

merous properties, including proliferation, cytokine production, chemotaxis, mast cell stimulation, and histamine release in addition to antimicrobial effects<sup>(5)</sup>. Although HBD-1 was first extracted from human plasma, it is primarily present in epithelial tissues, such as airway epithelium, urogenital tissues, nasolacrimal ducts, and mammary glands. The expressions of HBD-2 and HBD-3 from various epithelial tissues appear to be stimulated by bacterial products and cytokines. We did not investigate HBD-4 expression<sup>(13)</sup> because it has only been reported to be expressed from testis and epididymis<sup>(4-8)</sup>. Corneal and conjunctival epithelial cells mainly express HBD-1 and HBD-3, whereas HBD-2 expression results from various stimulants. It has been found that HBD-2 expression from corneal epithelial cells was upregulated as a result of stimulation from bacterial lipopolysaccharides via tyrosine kinase and p38 mitogen-activated protein kinase activation<sup>(14)</sup>. It has also been shown that HBD-2 expression was upregulated from corneal<sup>(15)</sup> and conjunctival<sup>(16)</sup> epithelial cells from proinflammatory cytokines, such as IL-1 and tumor necrosis factor-alpha.

McDermott et al. showed HBD-2 levels to increase in a corneal epithelial wound healing model in an in vitro organ culture media<sup>(17)</sup>. In two studies on patients with dry-eye syndrome with an inflammatory component, HBD-2 upregulation was found in conjunctival impression cytological specimens<sup>(16,18)</sup>. The authors emphasized that HBD-2 upregulation might be due to the activity of proinflammatory cytokines<sup>(16)</sup>.

In the other subgroup of AMPs, cathelicidins, only LL-37 exists in humans and is expressed from corneal and conjunctival epithelial cells. This peptide expression is a response to corneal epithelial trauma and is found to be elevated in bacterial infections because of *Pseudomonas aeruginosa* and *Staphylococcus aureus*. In addition, it is the major component of neutrophil granules, as in some defensins, and may be stimulated by some cytokines<sup>(7,19,20,21)</sup>. Moreover, LL-37 has properties, such as chemotaxis, histamine release from mast cells, dendritic cell differentiation, and cytokine release, similar to those of defensins<sup>(7)</sup>.

In previous studies, HBD-1 and HBD-3 expressions were found mainly in the presence of infections, whereas HBD-2 and LL-37 have been shown to be expressed following injury and inflammation in addition to infection<sup>(3,4,7,13-21)</sup>. In our study, we did not find any differences in HBD-1, HBD-3, and LL-37 expressions between pterygium tissue and normal tissue, whereas HBD-2 expression was significantly higher in pterygium specimens. This finding suggests that HBD-2 may be associated with the inflammation involved in pterygium pathogenesis.

Zhou et al. found that human alpha-defensin 1 and 2 expressions were increased in tears of patients with pterygia. Those authors stated that the molecules might be related to inflammation or fibrovascular proliferation in pterygium<sup>(2)</sup>. In our study, we assessed beta-defensins and cathelicidin as opposed to alpha-defensin. Our study is the first to compare HBD and cathelicidin expressions in pterygium specimens with normal tissues.

We found high-level expression of HBD-2, an AMP, in specimens of pterygium. HBD-2 may have an important role in pterygium pathogenesis. Further studies are necessary to determine if HBD-2 causes the release of inflammatory cytokines or if inflammatory cytokines elicit HBD-2 expression.

**REFERENCES**

- Chui J, Di Girolamo N, Wakefield D, Coroneo MT. The pathogenesis of pterygium: current concepts and their therapeutic implications. *Ocul Surf.* 2008;6(1):24-43.
- Zhou L, Beuerman RW, Ang LP, Chan CM, Li SF, Chew FT, et al. Elevation of human alpha-defensins and S100 calcium-binding proteins A8 and A9 in tear fluid of patients with pterygium. *Invest Ophthalmol Vis Sci.* 2009;50(5):2077-86.
- Narayanan S, Miller WL, McDermott AM. Expression of human beta-defensins in conjunctival epithelium: relevance to dry eye disease. *Invest Ophthalmol Vis Sci.* 2003; 44(9):3795-801.

4. McDermott AM, Redfern RL, Zhang B, Pei Y, Huang L, Proske RJ. Defensin expression by the cornea: multiple signalling pathways mediate IL-1beta stimulation of hBD-2 expression by human corneal epithelial cells. *Invest Ophthalmol Vis Sci.* 2003;44:1859-65.
5. Dutta P, Das S. Mammalian Antimicrobial Peptides: Promising Therapeutic Targets Against Infection and Chronic Inflammation. *Curr Top Med Chem.* 2016;16(1):99-129.
6. Duits LA, Ravensbergen B, Rademaker McHiemstra PS, Nibbering PH. Expression of beta-defensin 1 and 2 mRNA by human monocytes, macrophages and dendritic cells. *Immunology.* 2002;106(4):517-25.
7. McDermott AM. Defensins and other antimicrobial peptides at the ocular surface. *Ocul Surf.* 2004;2(4):229-47.
8. McIntosh RS, Cade JE, Al-Abed M, Shanmuganathan V, Gupta R, Bhan A, et al. The spectrum of antimicrobial peptide expression at the ocular surface. *Invest Ophthalmol Vis Sci.* 2005;46(4):1379-85.
9. Gordon YJ, Huang LC, Romanowski EG, Yates KA, Proske RJ, McDermott AM. Human cathelicidin (LL-37), a multifunctional peptide, is expressed by ocular surface epithelia and has potent antibacterial and antiviral activity. *Curr Eye Res.* 2005;30(5):385-94.
10. Huang LC, Petkova TD, Reins RY, Proske RJ, McDermott AM. Multifunctional roles of human cathelicidin (LL-37) at the ocular surface. *Invest Ophthalmol Vis Sci.* 2006;47(6):2369-80.
11. Kumar A, Yin J, Zhang J, Yu FSX. Modulation of corneal epithelial innate immune response to *Pseudomonas* infection by flagellin pretreatment. *Invest Ophthalmol Vis Sci.* 2007;48(10):4664-70.
12. Karadag R, Bayram N, Oguztuzun S, Bozer B, Bayramlar H, Simsek GG, et al. Investigation of Glutathione S-Transferase Isoenzyme Protein Expression in Patients with Pterygium. *Cornea.* 2016;35(8):1089-92.
13. Suarez-Carmona M, Hubert P, Delvenne P, Herfs M. Defensins: "Simple" antimicrobial peptides or broad-spectrum molecules? *Cytokine Growth Factor Rev.* 2015;26(3):361-70.
14. McNamara NA, Van R, Tuchin OS, Fleiszig SM. Ocular surface epithelia express mRNA for human beta defensin-2. *Exp Eye Res.* 1999;69(5):483-90.
15. McDermott AM, Redfern RL, Zhang B, Pei Y, Huang L, Proske RJ. Defensin expression by the cornea: multiple signalling pathways mediate IL-1beta stimulation of hBD-2 expression by human corneal epithelial cells. *Invest Ophthalmol Vis Sci.* 2003;44(5):1859-65.
16. Narayanan S, Miller WL, McDermott AM. Expression of human beta-defensins in conjunctival epithelium: relevance to dry eye disease. *Invest Ophthalmol Vis Sci.* 2003;44(9):3795-801.
17. McDermott AM, Redfern RL, Zhang B. Human beta-defensin 2 is up-regulated during reepithelialization of the cornea. *Curr Eye Res.* 2001;22(1):64-7.
18. Kawasaki S, Kawamoto S, Yokoi N, Connon C, Minesaki Y, Kinoshita S, et al. Up-regulated gene expression in the conjunctival epithelium of patients with Sjögren's syndrome. *Exp Eye Res.* 2003;77(1):17-26.
19. Redfern RL, Reins RY, McDermott AM. Toll-like receptor activation modulates antimicrobial peptide expression by ocular surface cells. *Exp Eye Res.* 2011;92(3):209-20.
20. Shamsuddin N, Kumar A. TLR2 mediates the innate response of retinal Muller glia to *Staphylococcus aureus*. *J Immunol.* 2011;186(12):7089-97.
21. Evans DJ, Fleiszig SM. Why does the healthy cornea resist *Pseudomonas aeruginosa* infection? *Am J Ophthalmol.* 2013;155(6):961-70.

## XXI Congresso Brasileiro de Uveítes

8 a 10 de março de 2018

Aracaju - SE

**Informações:**

Site: [www.uveitesbrasil.com.br](http://www.uveitesbrasil.com.br)