

5-20-2019

Monitoring Progression of Ductal Carcinoma In Situ Using Photoacoustics and Contrast-Enhanced Ultrasound.

Ryan Margolis
Thomas Jefferson University

Corinne Wessner
Thomas Jefferson University

Maria Stanczak
Thomas Jefferson University

Ji-Bin Liu
Thomas Jefferson University

Jingzhi Li
Follow this and additional works at: <https://jdc.jefferson.edu/radiologyfp>
Thomas Jefferson University

 Part of the [Radiology Commons](#)

Let us know how access to this document benefits you

See next page for additional authors

Recommended Citation

Margolis, Ryan; Wessner, Corinne; Stanczak, Maria; Liu, Ji-Bin; Li, Jingzhi; Nam, Kibo; Forsberg, Flemming; and Eisenbrey, John R., "Monitoring Progression of Ductal Carcinoma In Situ Using Photoacoustics and Contrast-Enhanced Ultrasound." (2019). *Department of Radiology Faculty Papers*. Paper 61.

<https://jdc.jefferson.edu/radiologyfp/61>

This Article is brought to you for free and open access by the Jefferson Digital Commons. The Jefferson Digital Commons is a service of Thomas Jefferson University's [Center for Teaching and Learning \(CTL\)](#). The Commons is a showcase for Jefferson books and journals, peer-reviewed scholarly publications, unique historical collections from the University archives, and teaching tools. The Jefferson Digital Commons allows researchers and interested readers anywhere in the world to learn about and keep up to date with Jefferson scholarship. This article has been accepted for inclusion in Department of Radiology Faculty Papers by an authorized administrator of the Jefferson Digital Commons. For more information, please contact: JeffersonDigitalCommons@jefferson.edu.

Authors

Ryan Margolis, Corinne Wessner, Maria Stanczak, Ji-Bin Liu, Jingzhi Li, Kibo Nam, Flemming Forsberg, and John R. Eisenbrey

Monitoring Progression of Ductal Carcinoma In Situ Using Photoacoustics and Contrast-Enhanced Ultrasound



Ryan Margolis¹, Corinne Wessner, Maria Stanczak, Ji-Bin Liu, Jingzhi Li, Kibo Nam, Flemming Forsberg and John R. Eisenbrey

Department of Radiology, Thomas Jefferson University, Philadelphia, PA 19107, USA

Abstract

Breast cancer is the leading form of cancer in women, accounting for approximately 41,400 deaths in 2018. While a variety of risk factors have been identified, physical exercise has been linked to reducing both the risk and aggressiveness of breast cancer. Within breast cancer, ductal carcinoma in situ (DCIS) is a common finding. However, less than 25% of DCIS tumors actually progress into invasive breast cancer, resulting in overtreatment. This overtreatment is due to a lack of predictive precursors to assess aggressiveness and development of DCIS. We hypothesize that tissue oxygenation and perfusion measured by photoacoustic and contrast-enhanced ultrasound imaging, respectively, can predict DCIS aggressiveness. To test this, 20 FVB/NJ and 20 SV40Tag mice that genetically develop DCIS-like breast cancers were divided evenly into exercise and control groups and imaged over the course of 6 weeks. Tissue oxygenation was a predictive precursor to invasive breast cancer for FVB/NJ mice ($P = 0.015$) in the early stages of tumor development. Meanwhile, perfusion results were inconclusive ($P > 0.2$) as a marker for disease progression. Moreover, voluntary physical exercise resulted in lower weekly tumor growth and significantly improved median survival ($P = 0.014$).

Translational Oncology (2019) 12, 973–980

Introduction

Breast cancer is the most common form of cancer in women. In 2018, there will be an estimated 266,120 new cases of invasive breast cancers diagnosed in the United States [1]. This translates to 30% of all cancers in women. Additionally, 63,960 in situ lesions will be diagnosed in women [1–4]. Ductal carcinoma in situ (DCIS) is the most frequent form of in situ breast cancer, referring to a condition defined as the premalignant proliferation of cells within the breast ducts and accounting for 83% of newly diagnosed in situ cases [1].

Healthcare costs to treat breast cancer exceed \$16.5 billion dollars per year in the U.S. [2], with an average cost per patient of approximately \$62,000 following diagnosis [5]. The current paradigm for breast cancer treatments involves a combination of breast surgery with radiation and chemotherapy of the tumor, surrounding tissue, or entire breast. Breast cancer is commonly detected through mammography or manual palpation [1,2,6]. While mammography can identify tumors at an early stage, this imaging technique is severely limited in patients with dense breast tissue and has demonstrated suboptimal specificity [7]. To counteract the deficiencies of mammography, magnetic resonance imaging (MRI) or ultrasound are two viable options. MRI is used post-diagnosis as it has a sensitivity of over 94% [1,7]. However, the high cost and lower

specificity compared to mammography (90% vs. 95%) means MRI is not currently used as a screening technique [7,8]. Alternatively, ultrasound is noninvasive, providing real-time imaging modality and costs a fraction of an MRI. Ultrasound has been shown to detect cancers that mammography would have missed [9] and shows similar overall breast anatomy as well as tumor diagnosis as MRI [10].

There is an ongoing clinical need for a predictive precursor for breast cancer, in particular for the early-stage, high-risk DCIS form. Only 20 to 25% of all DCIS cases progress into invasive breast cancer, and studies suggest that an average of 55% of DCIS cases are

Address all correspondence to: John R. Eisenbrey, Department of Radiology, Thomas Jefferson University, Philadelphia, PA 19107, USA.

E-mail: john.eisenbrey@jefferson.edu

¹ 5323 Harry Hines Blvd, Dallas TX 75235: Department of Radiology, UT Southwestern, Dallas, TX 75235.

Received 24 April 2019; Accepted 28 April 2019

© 2019 The Authors. Published by Elsevier Inc. on behalf of Neoplasia Press, Inc. This is an open access article under the CC BY-NC-ND license (<http://creativecommons.org/licenses/by-nc-nd/4.0/>).

1936-5233/19

<https://doi.org/10.1016/j.tranon.2019.04.018>

overtreated [2,11]. Recent literature reviews have shown that despite this rate of overtreatment, there are currently no predictive biomarkers to determine the aggressiveness and development of DCIS [1,2,12]. While a variety of environmental and socioeconomic risk factors have been identified [1–3], studies have shown that physical exercise reduces the risk of breast cancer mortality by upwards of 45% by limiting aggressiveness, as well as reducing the risk of getting diagnosed with breast cancer by 14% [1,10,28]. These benefits may be attributed to an increase in tissue perfusion and overall oxygenation state, while also reducing inflammation.

In order to reduce overtreatment of DCIS, parameters to monitor tumor aggressiveness are needed. Ultrasound is well poised to fill this role. One emerging trend to characterize tumor growth and aggressiveness is to quantify tumor hypoxia. Hypoxia has been linked to advanced tumor progression and angiogenesis [13,14]. This can be achieved with photoacoustic (PA) imaging. In this modality, light (typically in the 600–900 nm wavelength range) is directed into the tissue from a tunable laser and absorbed by tissue chromophores [15,16]. The optical energy is rapidly absorbed and converted into heat, resulting in thermoelastic expansion. The rapid expansion produces a broadband pressure wave that propagates in every direction, generating acoustic signals that are detected by the ultrasound transducer. PA imaging enables the measurement of hemoglobin and blood oxygenation to characterize tumor growth. Hemoglobin exhibits several absorption bands and this spectrum changes when binding occurs [16,17]. Oxygenated and deoxygenated hemoglobin interact differently across the frequency spectrum. Therefore, by using two wavelengths, most commonly 750 and 850 nm, percent saturation in the blood can be calculated [16]. The oxygenation saturation of hemoglobin correlates with the metabolic state of lesions and is thus an important diagnostic parameter [16,17]. Recent studies by our research group have investigated the use of hemoglobin oxygenation as a breast cancer imaging parameter by comparing the measurements to angiogenic immunohistochemical markers [17], while others have studied PA imaging's ability to differentiate between benign and malignant tumors [19–21].

Moreover, tumor perfusion can be estimated by contrast enhanced ultrasound (CEUS) [18] for monitoring DCIS progression. This technique involves intravenously injecting small lipid or polymer stabilized gas-filled microbubbles typically smaller than 8 μm in diameter [22,23]. Differences in acoustic impedance between the gas and surrounding tissue produce up to 25 dB in signal enhancement [24,25]. This allows for better visualization of angiogenic tumor vasculature and quantification of perfusion as an indicator of tumor growth and progression. CEUS has been shown to help differentiate between benign and malignant tumors [26,27]. Additionally, CEUS has been used to monitor the effects of physical exercise, a modifiable risk factor for breast cancer [1,3,28].

Tissue oxygenation and perfusion may become markers to characterize tumor growth. Therefore, this study investigates these two parameters as potential biomarkers for DCIS progression using PA and CEUS imaging in a human breast cancer mouse model.

Materials and Methods

Mouse Model

All animal work was approved by Thomas Jefferson University's Institutional Animal Care and Use Committee. Twenty FVB/NJ and

20 Tg(C3–1-TAg)cJeg mice (Jackson Laboratories, Bar Harbor, ME, USA) were purchased at 9 weeks of age and evenly allocated into exercise and control subgroups (i.e., 10 mice/group), where the exercise group had access to a Fisher Scientific (Hampton, NH, USA) exercise wheel (Figure 1). The Tg(C3–1-TAg)cJeg mice have a SV40 Tag in which they are genetically predisposed to develop breast cancer in each mammary gland at 10–13 weeks [29]. The tumors appear similar to DCIS before progressing to invasive breast cancer at approximately 16 weeks of age. The FVB/NJ mice do not develop breast cancer.

Animal Preparation

Prior to imaging each week, Nair (Trenton, NJ, USA) was used to remove hair from the abdomen and leg region. Animals were imaged over the course of 6 weeks and weighed biweekly until reaching sacrifice criteria. During imaging days, mice were given anesthesia using a mixture of oxygen and 3% isoflurane via a nosecone. Mice were placed on a heating pad at 40 °C during imaging and were monitored for 30 minutes post-imaging.

Tumor Volume Measurements

Due to their ellipsoidal shape of the tumors, tumor volumes measurements were obtained weekly on imaging days using a 3D scan prior to PA and CEUS imaging with a the Vevo 2100 LAZR scanner (VisualSonics, Toronto, Canada) using a LZ–250 PA probe in B-mode at 100% power at a transmitting frequency of 21 MHz. Tumor volumes were monitored only for the SV40 Tag mouse line as the FVB/NJ mice do not develop any tumors.

Photoacoustic Imaging

PA imaging was performed using a LZ-250 PA probe (VisualSonics). The transducer was aligned along the right hind and leg region of the mouse, angling from the abdominal mammary gland down towards the inguinal mammary gland. Once the mouse was correctly aligned, the laser was fired at 100% power at wavelengths of 750 and 850 nm. PA images were acquired for all mice with a PA gain of 35 dB and a depth offset of 3 mm for 25 frames. Weekly changes were calculated with respect to the baseline values at the 9 weeks old time point for oxygenation measurements.

Contrast-Enhanced Imaging

Immediately following the acquisition of the PA images, CEUS was performed using a nonlinear contrast mode with the same LZ-250 probe. Each mouse received a retro-orbital bolus injection of 10 μL of a contrast agent through a 22 gauge blunt needle. The ultrasound contrast agents SIMB3–4 sized microbubbles (Advanced Microbubble Laboratories, Boulder, CO) or Vevo MicroMarker® Target-Ready Contrast Agent (VisualSonics, Toronto, Canada) were injected. Both contrast agents are specifically designed for high frequency ultrasound imaging and have identical size (3–4 μm) and concentrations (2.12×10^5 microbubbles/ μL). Amplitude modulated flash-replenishment CEUS images were collected at 18 MHz at 4% power (which corresponds to a mechanical index of 0.08) [18] with a gain of 20 dB and frame rate of 10 Hz. Two destruction bursts ($\text{MI} > 0.3$) were initiated 20 seconds apart to allow for complete reperfusion in the mammary gland after the microbubbles were destroyed from the burst. Changes in weekly values for perfusion measurements were measured with respect to the 10 weeks old time point due to poor contrast signal.

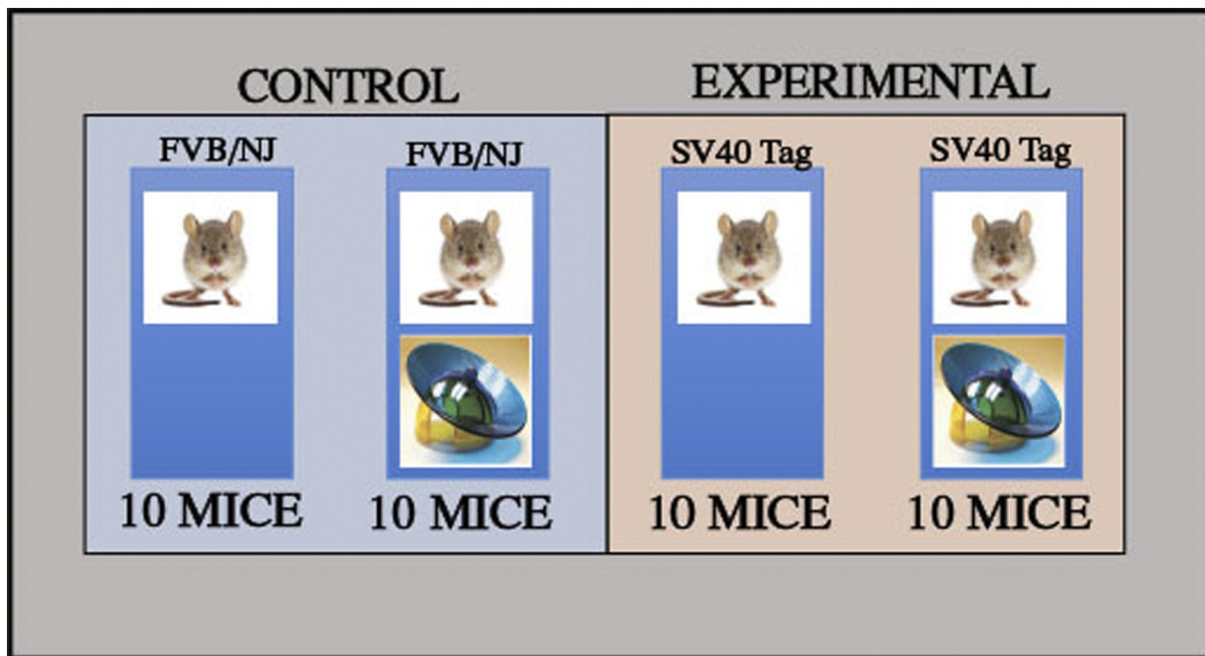


Figure 1. Experimental Design. Mouse model for study consisting of control and experimental subgroups within FVB/NJ and SV40 Tag mouse lines.

Statistical Analysis

All image analysis was performed offline using the Vevo CQ (VisualSonics, Toronto, Canada) software. For the PA images, regions of interest (ROIs) were manually outlined around the mammary gland by a user with 2 years of experience with Vevo CQ software and verified by a sonographer. (with 6 years of experience) The values for average tissue oxygenation (SO_2) were averaged across the 25 frames and was used for analysis. For CEUS images, ROIs were drawn around the skin layer, approximately 1–2 mm deep. Time intensity curves were created and values for wash-in rate (WIR) was calculated (as a measure of perfusion) after each destructive burst and averaged. Lastly, to measure the volumes of the tumors, ROIs were drawn around the tumor every 2–3 imaging slices and then extrapolated through the entire tumor to produce a 3D model of the mammary gland tumor for each mouse. Statistical differences between exercise and control groups were tested using repeated measures ANOVA. Lastly, Kaplan–Meier survival curves were generated to compare the effect of physical exercise. All tests were performed using a significance value of $\alpha \leq 0.05$. Analysis was performed using SPSS Statistics 25.0.0.0 (IMB, Richmond, VA, USA).

Results

One FVB/NJ and one SV40 Tag mouse died over the course of the 6 weeks of imaging and were excluded from analysis. Two contrast agents were needed for this study, due to shelf life issues of the microbubbles. Significant weight changes were observed between the exercise and control groups for both the FVB/NJ and SV40 Tag mice. For the FVB/NJ mice, weekly weight changes were lower for the exercise group than the control group ($3.30 \pm 2.46\%$ vs. $7.64 \pm 10.36\%$, $P = 0.012$). A similar result was obtained for the SV40 Tag mice between the exercise and control groups ($12.09 \pm 8.94\%$ vs. $13.62 \pm 10.14\%$, $P = 0.039$).

Tissue oxygenation and perfusion measurements were analyzed between the FVB/NJ and SV40 Tag mice, as well as among the exercise and control subgroups of each mouse line. Example images for each parameter are shown Figure 2. For tissue oxygenation measurements, there was no statistical difference found between the SV40 Tag and FVB mouse lines for either the exercise or control groups ($P = .2$; Figure 3). At 10 weeks of age, there was a statistical difference between the SV40 Tag and FVB/NJ mice in the control group ($P = 0.015$). Furthermore, there were no differences in WIR between exercise groups ($P = 0.9$) or control ($P = 0.2$), as shown in Figure 4. Due to the high variability in the SV40 measurements, single outliers were removed at the 11 and 14 weeks old time points, while two outliers were removed for at 12 and 13 weeks. In both the comparisons of exercise and control subgroups between each mouse line, there was a greater variation in the SV40 Tag measurements relative to the FVB/NJ measurements.

Additionally, there was no changes in tissue oxygenation between the exercise and control groups for the FVB mice ($5.16 \pm 23.68\%$ vs. $10.93 \pm 27.67\%$, $P = 0.5$). In comparing the exercise and control groups of the SV40 Tag mice, average weekly values were higher for the exercise group than the control group, although this was not statistically significant ($-6.51 \pm 26.17\%$ vs. $17.26 \pm 25.06\%$, $P = 0.037$). Similar to the results when comparing mouse line subgroups, there were no differences between subgroups in either the FVB/NJ mice or SV40 Tag mouse line for perfusion measurements ($P > 0.25$).

Although there was no statistical difference between the tumor volumes in the exercise and control groups, the exercise group exhibited slower tumor growth than compared to the control group at the early time points ($0.38 \pm 1.29 \text{ mm}^3$ vs. $0.88 \pm 1.28 \text{ mm}^3$, $P = 0.21$, Figure 5). Furthermore, the exercise mice survived an average of 3 weeks longer than those who had no exercise available (26 weeks vs. 23 weeks, $P = 0.014$; Figure 6). These differences were associated

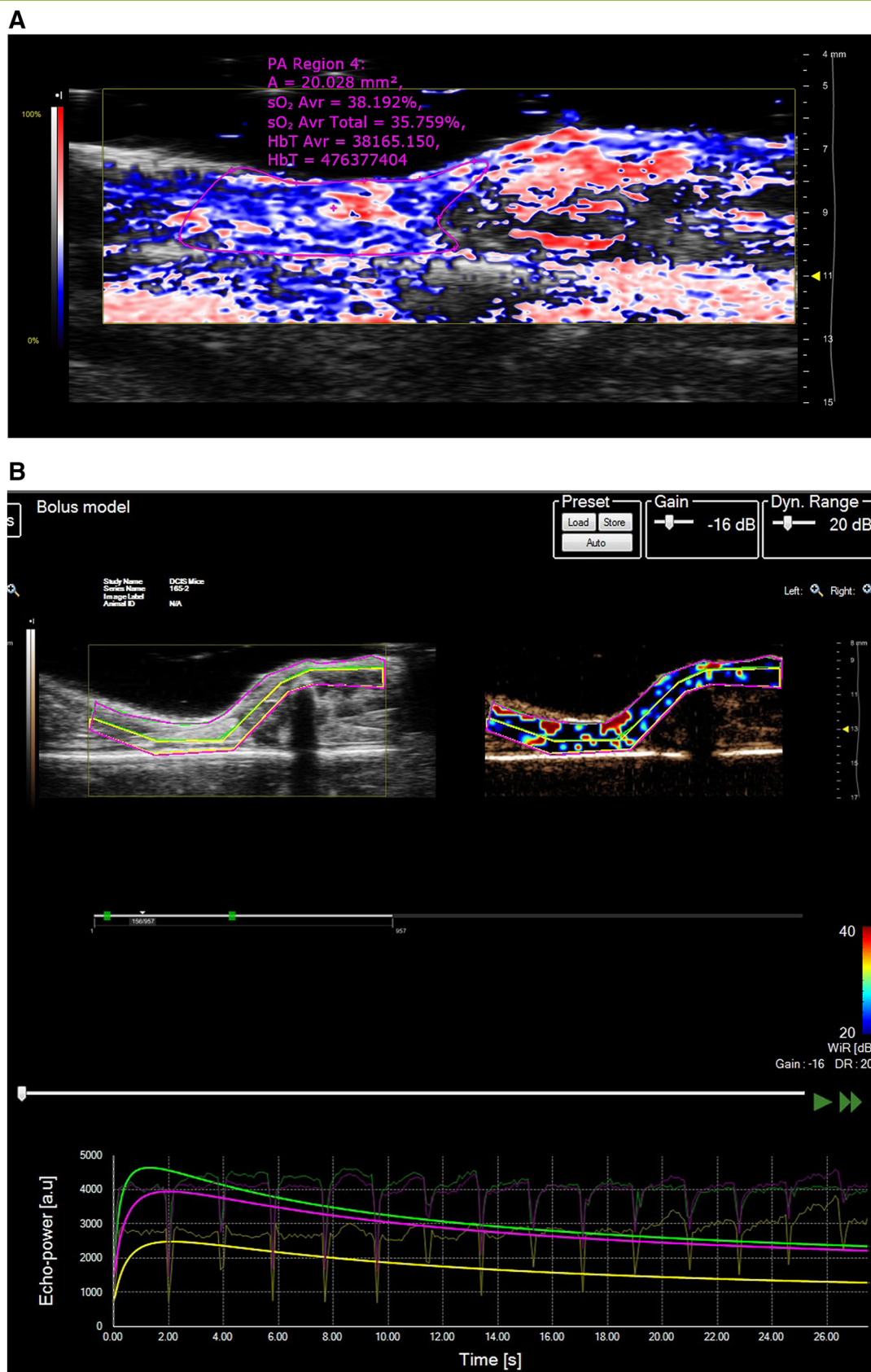


Figure 2. Example PA and CEUS images for FVB/NJ and SV40 Tag Mice. Example images for SV40 Tag of the PA (A) and perfusion (B) are shown, while example images for the FVB/NJ for PA and perfusion are shown in Panels C and D, respectively.

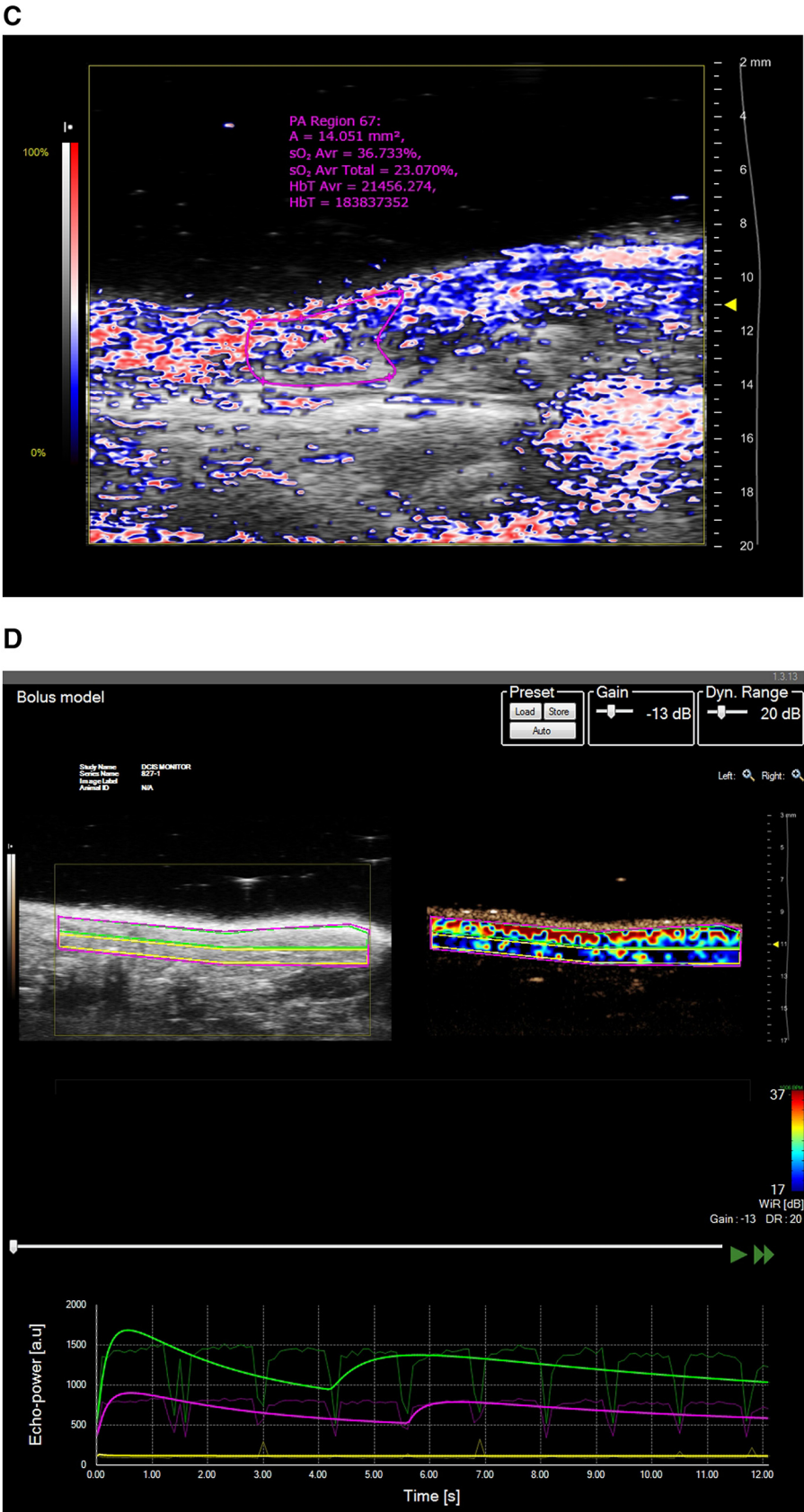


Figure 2. (Continued).

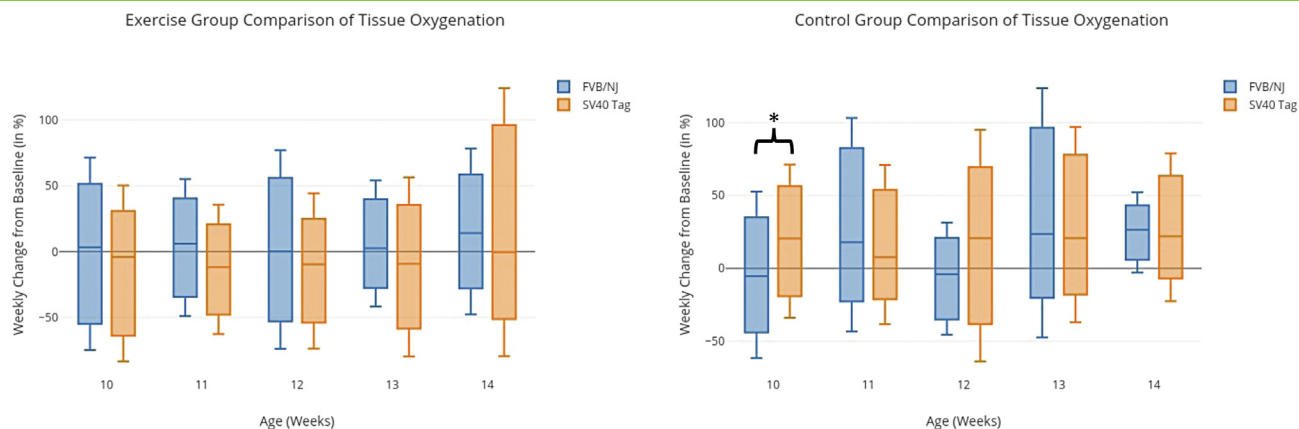


Figure 3. Comparison of Tissue Oxygenation Measurements. Tissue oxygenation comparison of subgroups between FVB/NJ mouse lines. The left graph displays differences between exercise groups, while the right shows differences among the control groups.

with both slower primary tumor growth and reduced secondary tumor formation in the axillary nodes.

Discussion

In the assessment of breast cancer, the transition from DCIS to invasive carcinoma is controversial. Current treatment options for DCIS can have serious long-lasting physical, psychological, and financial costs [4]. Understanding the underlying mechanism by which DCIS progresses is key to minimizing overtreatment. Tissue oxygenation and perfusion are two markers that have been used to monitor and detect angiogenesis [18,30], but to date have not been used to predict DCIS formation and progression. Additionally, studies have found that exercise helps reduce the risk of breast cancer occurrence, as well as reducing the risk of death post-diagnosis [1,10,28].

Tissue oxygenation showed the most promising results of the imaging parameters studied in this project. While there were no statistical differences between the exercise and control subgroups when comparing across the SV40 Tag or FVB/NJ mouse lines, due to a high level of variability (as shown in Figure 5), the control mice showed higher metastatic tumor growth in axillary nodes as well as overall tumor growth. Therefore, we can conclude that this as a precursor biomarker to invasive breast cancer. Moreover, there were differences in comparing between the exercise and control subgroups

within each mouse line. The statistical difference between the exercise and control groups of the SV40 Tag mice demonstrated that exercise group showed a more hypoxic environment, a sign of tumor growth. Hypoxia has been extensively studied and impacts angiogenesis, tumor progression, and immune tolerance [31,32].

CEUS has been extensively used to image angiogenesis [18,30], specifically the effect of physical exercise [33,34], as well as characterizing tumor growth [30]. Our results (cf., Figure 3) for tissue perfusion are consistent with findings previously obtained by Faustino-Rocha et al. [30] that exercise has no effect on perfusion as there were no differences between the FVB/NJ and SV40 Tag mice nor their subgroups ($P > .2$). There was a high degree of variability in these perfusion measurements, especially within the SV40 Tag mice. This could be due to several factors, such as limited circulation time (1–2 minutes), but is most likely due to the type of injections employed. Orbital eye injections required manual injections and a study was performed to evaluate the efficiency of manual versus controlled bolus tail-vein injections [35], which found that controlled injections improved reproducibility by a factor of 2 to 3 ($C = 18.6 \pm 8.0\%$ vs. $M = 46.7 \pm 19.2\%$, $P = 0.02$).

While tumor volume measurements were not statistically significant, they did showcase the effects of physical exercise on tumor growth. The average tumor size was lower in the exercise group than

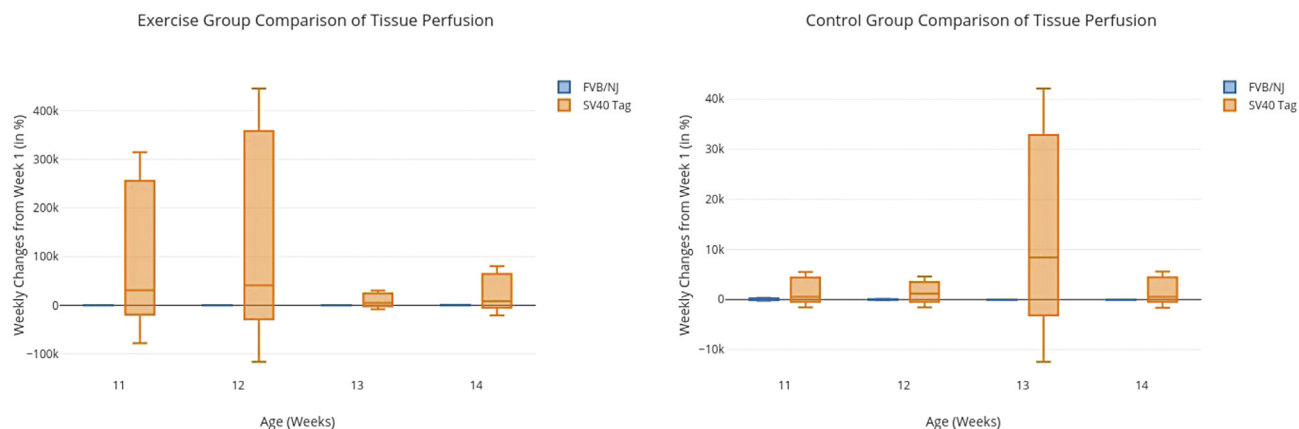


Figure 4. Comparison of Tissue Perfusion Measurements. Tissue perfusion comparison of subgroups between FVB/NJ mouse lines. The left graph displays differences between exercise groups, while the right shows differences among the control groups.

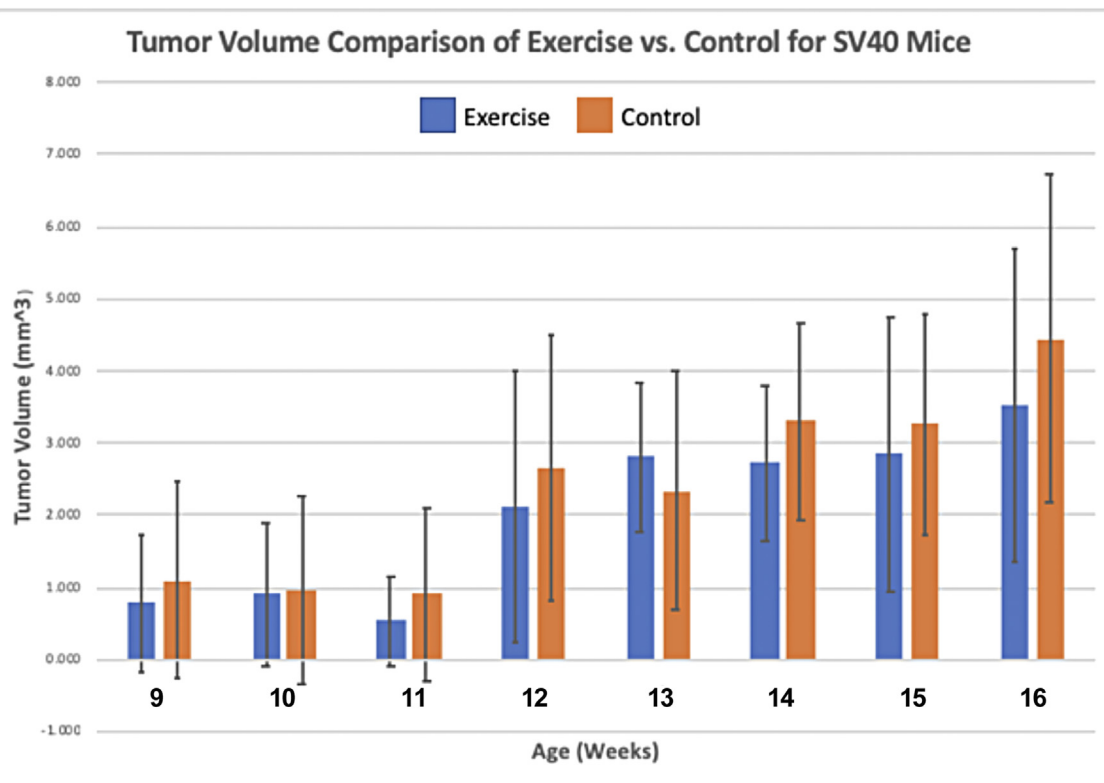


Figure 5. Comparison of Tumor Volume Growth in SV40 Mice Subgroups. Tumor growth comparison of exercise and control SV40 subgroups of mice from 9 to 16 weeks of age.

in the control group (Figure 5). Studies have shown that regular, moderate to vigorous physical exercise regularly can reduce the risk of breast cancer by 20 to 40% in postmenopausal women [1,28]. Additionally, this slower tumor growth lead to significantly increased longevity, as mice who exercised survived an average of 26 weeks, while the control group lived on average 23 weeks, which was statistically significant. This was attributed primarily to more frequent tumor metastases. These results also matched studies that stated exercise lowers the risk of death post diagnosis by 45% [11].

Our results have demonstrated that tissue oxygenation can be a predictive precursor for DCIS formation and progression to invasive carcinoma. These noninvasive tools can be readily translated to the clinic to potentially guide clinical management of DCIS. Addition-

ally, the role of physical exercise is evident on weight changes, slowed tumor growth, and improvement of median survival.

Acknowledgements

We gratefully acknowledge financial support from a Shaber Family Grant.

References

- [1] American Cancer Society (2017). Breast Cancer Facts & Figures 2017 – 2018. American Cancer Society, Inc: 1 – 9.
- [2] Vatovec CM, Erten MZ, Kolodinsky J, Brown P, Wood M, James T, and Sprague BL (2014). Ductal carcinoma in situ: a brief review of treatment variation and impacts on patients and society. *Crit Rev Eukaryot Gene Expr* **24**(4), 281–286.
- [3] Goncalves AK, Dantas Florencio GL, Maissonnete de Atayde Silva MJ, Cobucci RN, Giraldo PC, and Cote NM (2014). Effects of physical activity on breast cancer prevention: a systematic review. *J Phys Act Health* **11**, 445–454.
- [4] American Cancer Society (2017) (2017-2018). Cancer Facts and Figures. American Cancer Society, 1–11.
- [5] Blumen H, Fitch K, and Polkus V (2016). Comparison of Treatment Costs for Breast Cancer, by Tumor Stage and Type of Service. *American health & drug benefits* **9**(1), 23–32.
- [6] Vaidya Y, Vaidya P, and Vaidya T (2013). Ductal carcinoma in situ of the breast. *Indian J Surg* **77**(2), 141–146.
- [7] Warner E, Plewes DB, Shumak RS, Catzavelos GC, and Di Propsero LS, et al (2001). Comparison of breast magnetic resonance imaging, mammography, and ultrasound for surveillance of women at high risk for hereditary breast cancer. *J Clin Oncol* **19**(15), 3524–3531.
- [8] Saslow D, Boetes C, Burke W, Harms S, Leach MO, Lehman CD, Morris E, Pisano E, Schnall M, and Sener S, et al (2007). American Cancer Society Guidelines for Breast Screening with MRI as an Adjunct to Mammography. *CA Cancer J Clin* **57**, 75–89.

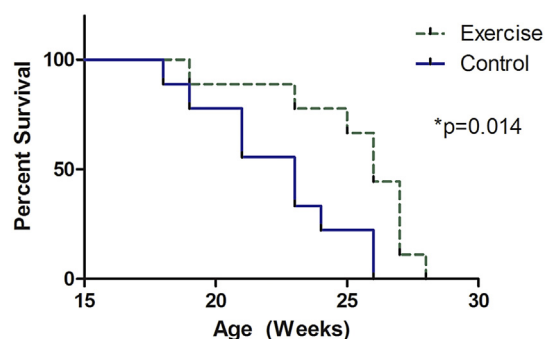


Figure 6. Survival Curve. Depicts the effect of physical exercise on survival.

- [9] Lee CH, Dershaw DD, Kopans D, Evans P, Monsees B, Monticciolo D, Brenner RJ, Bassett L, Berg W, and Feig S, et al (2010). Breast cancer screening with imaging: recommendations from the Society of Breast Imaging and the ACR on the use of mammography, breast MRI, breast ultrasound, and other technologies for the detection of clinically occult breast cancer. *Journal of American College of Radiology* 7(1), 18–27.
- [10] Ranger B, Littrup PJ, Duric N, Chandiwalla-Mody P, Li C, Schmidt S, and Lupinacci J (2012). Breast ultrasound tomography versus MRI for clinical display of anatomy and tumor rendering: preliminary results. *AJR Am J Roentgenol* 198 (1), 233–239.
- [11] van Luijt PA, Heijnsdijk EA, Fracheboud J, Overbeek LIH, Broeders MJM, Wessling J, den Heeten GJ, and de Koning HJ (2016). The distribution of ductal carcinoma in situ (DCIS) grade in 4232 women and its impact on overdiagnosis in breast cancer screening. *Breast Cancer Res* 18(47), 1–10.
- [12] Kopans Daniel B, Smith R, and Duffy SW (2011). Mammographic Screening and “Overdiagnosis”. *Radiology* 260(3), 616–620.
- [13] Muz B, de la Puente P, Azab F, and Azab AK (2015). The role of hypoxia in cancer progression, angiogenesis, metastasis, and resistance to therapy. *Hypoxia (Auckland, N.Z.)* 3, 83–92.
- [14] Harris AL (2002). Hypoxia — a key regulatory factor in tumour growth. *Nature Reviews Cancer* 2, 38–47.
- [15] Beard P (2011). Biomedical photoacoustic imaging. *Interface Focus* 1, 602–631.
- [16] Needles A, Heinmiller A, Sun J, Theodoropoulos C, Bates D, Hirson D, Yin M, and Foster FS (2013). Development and initial application of a fully integrated photoacoustic micro-ultrasound system. *IEEE Trans Ultrason Ferroelectr Freq Control* 60(5), 888–897.
- [17] Xu Minghua and Wang Lihong V (2006). Photoacoustic imaging in biomedicine. *Rev. Sci. Instrum.* 77, 041101–041122.
- [18] Eisenbrey JR, Merton DA, Marshall A, Lui J-B, Fox TB, Sridharan A, and Forsberg F (2014). Comparison of photoacoustically derived hemoglobin and oxygenation measurements with contrast-enhanced ultrasound estimated vascularity and immunohistochemical staining in a breast cancer model. *Ultrasonic Imaging* 37(1), 42–52.
- [19] Heijblom M, Piras D, van den Engh FM, van der Schaaf M, Klaase JM, Steenbergen W, and Manohar S (2016). The state of the art in breast imaging using the Twente Photoacoustic Mammoscope: results from 31 measurements on malignancies. *Eur Radiol* 26, 3874–3887.
- [20] Diot G, Metz S, Noske A, Liapis E, Schroeder B, Ovsepian SV, Meier R, Rummeny E, and Ntziachristos V (2017). Spectral signatures of human breast cancer by means of MSOT. *Clin Cancer Res* 23(22), 6912–6922.
- [21] Menezes GL, Pijnappel RM, Meeuwis C, Bisschops R, Veltman J, Lavin PT, van der Vijver MJ, and Mann RM (2018). Downgrading of breast masses suspicious for cancer by using optoacoustic breast imaging. *Radiology* 288(2), 1–11.
- [22] Dastgheyb SS and Eisenbrey JR (2014). Microbubble Applications in Biomedicine. *Handbook of Polymer Applications in Medicine and Medical Devices* (253–277). New York City, NY: Elsevier; 2014.
- [23] Eisenbrey JR, Burstein OM, Kambhampati R, Forsberg F, Liu J-B, and Wheatley MA (2010). Development and optimization of a doxorubicin loaded poly(lactic acid) contrast agent for ultrasound directed drug delivery. *Journal of Controlled Release* 143, 38–44.
- [24] Eisenbrey JR and Forsberg F (2010). Contrast-enhanced ultrasound for molecular imaging of angiogenesis. *Eur J Nucl Med Mol Imaging* 37(Suppl 1), S138–S146.
- [25] Greis C (2011). Quantitative evaluation of microvascular blood flow by contrast-enhanced ultrasound (CEUS). *Clinical Hemorheology and Microcirculation* 49(1-4), 137.
- [26] Zaho H, Xu R, Ouyang Q, Chen L, Dong B, and Huihua Y (2010). Contrast-enhanced ultrasound is helpful in the differentiation of malignant and benign breast lesions. *European Journal of Radiology* 73(2), 288–293.
- [27] Yuan Z, Quan J, Yunxiao Z, Jian C, Zhu H, and Liping G (2013). Diagnostic value of contrast-enhanced ultrasound parametric imaging in breast tumors. *J Breast Cancer* 16(2), 208–213.
- [28] Volaklis KA, Halle M, and Tokmakidis SP (2013). Exercise in the prevention and rehabilitation of breast cancer. *Wien Klin Wochenschr* 125, 297–301.
- [29] Jansen SA, Ileva LV, Riffle LA, Lu L, Anver M, and Kalen JD (2015). Ductal carcinoma in situ: magnetic resonance and ultrasound imaging in mouse models of breast cancer; 2015 .
- [30] Faustino-Rocha AI, Gama A, Oliveira PA, Vanderperren K, Saunders JH, Pires MJ, Ferreira R, and Ginja M (2017). A contrast-enhanced ultrasonographic study about the impact of long-term exercise training on mammary tumor vascularization. *J Ultrasound Med* 36, 2459–2466.
- [31] Chouaib S, Messai Y, Couve S, Escudier B, Hasmim M, and Noman MZ (2012). Hypoxia promotes tumor growth in linking angiogenesis to immune escape. *Frontiers in Immunology* 3(21), 1–10.
- [32] Vaupel P and Harrison L (2004). Tumor hypoxia: causative factors, compensatory mechanisms, and cellular response. *The Oncologist* 9(Suppl 5), 4–9.
- [33] Krix M, Krakowski-Roosen K, Kauczor H-U, Delorme S, and Weber M-A (2009). Real-time contrast-enhanced ultrasound for the assessment of perfusion dynamics in skeletal muscle. *Ultrasound in Med. & Biol.* 35(10), 1587–1595.
- [34] Sellei RM, Wachling A, Weber CD, Jeromin S, Zimmermann F, McCann PA, Hildebrand F, and Pape H-C (2014). Contrast enhanced ultrasound (CEUS) reliably detects critical perfusion in compartmental muscle: a model in healthy volunteers. *Eur J Trauma Emerg Surg* 40, 535–539.
- [35] Dizeux A, Payen T, Barrois G, Buffello DLG, and Bridal SL (2016). Reproducibility of contrast-enhanced ultrasound in mice with controlled injection. *Mol. Imaging Biol* 18, 651–658.