

10-2010

The Added Value of Molecular Testing in Small Pancreatic Cysts

Adam D. Toll, MD

Department of Pathology, Anatomy and Cell Biology, Thomas Jefferson University

Marluce Bibbo, MD

Department of Pathology, Anatomy and Cell Biology, Thomas Jefferson University

Follow this and additional works at: <https://jdc.jefferson.edu/pacbfp>

 Part of the [Medical Cell Biology Commons](#), and the [Pathology Commons](#)

[Let us know how access to this document benefits you](#)

Recommended Citation

Toll, MD, Adam D. and Bibbo, MD, Marluce, "The Added Value of Molecular Testing in Small Pancreatic Cysts" (2010). *Department of Pathology, Anatomy, and Cell Biology Faculty Papers*. Paper 58.

<https://jdc.jefferson.edu/pacbfp/58>

This Article is brought to you for free and open access by the Jefferson Digital Commons. The Jefferson Digital Commons is a service of Thomas Jefferson University's [Center for Teaching and Learning \(CTL\)](#). The Commons is a showcase for Jefferson books and journals, peer-reviewed scholarly publications, unique historical collections from the University archives, and teaching tools. The Jefferson Digital Commons allows researchers and interested readers anywhere in the world to learn about and keep up to date with Jefferson scholarship. This article has been accepted for inclusion in Department of Pathology, Anatomy, and Cell Biology Faculty Papers by an authorized administrator of the Jefferson Digital Commons. For more information, please contact: JeffersonDigitalCommons@jefferson.edu.

Background

Cystic lesions of the pancreas (CLP) represent a relatively common pathologic entity affecting at least 1% of medical patients and represent a spectrum of lesions from inflammatory pseudocysts to malignant neoplasms.^(1,2) A significant percentage of these cysts are found incidentally during imaging work-up for unrelated conditions and require appropriate diagnostic testing to characterize the nature of the CLP. A multi-disciplinary approach to characterize CLP is currently used involving cytology, imaging, and cyst fluid analysis. The most recent international guidelines recommend resection of pancreatic mucinous cysts >3 cm, or smaller cysts with positive cytology, mural nodules, or symptoms.⁽²⁾

Recent work utilized DNA analysis to characterize CLP as either mucinous or serous, and assess malignant potential.^(3,4) Focusing on *k-ras* gene point mutation, this group was able to detect mucinous differentiation (specificity 96%). Further, high amplitude *k-ras* mutations combined with allelic loss were 96% specific for malignancy. Correlation of *k-ras* mutation / allelic imbalances with CEA, however, showed poor agreement in the diagnosis of mucinous CLP.

Our aim is to determine the added benefit of molecular testing in diagnosing small (≤ 3 cm) pancreatic cysts.

Methods

63 pancreatic cysts ≤ 3 cm with fine-needle aspiration cytology, cyst fluid CEA levels, and molecular analysis (PathFinder TG; RedPath Integrated Pathology, Pittsburgh PA) were retrospectively obtained. The final study group was 60% male and 40% female. The average age was 69.2 years (range 18-91 years). The breakdown of CLP locations were: 24% head, 32% body, 13% uncinata, 12% tail, and 19% involving multiple areas. The indications for the procedure varied from symptomatic to incidentally discovered lesions. Diagnoses were classified as unsatisfactory, benign nonmucinous, benign mucinous, and suspicious/malignant. RedPath criteria for mucinous lesions included *k-ras*-2 gene point mutation, high DNA quantity (optical density ratio >10) / DNA quality, or loss of heterozygosity (LOH) in ≥ 2 genomic loci; criteria for malignancy included *k-ras*-2 gene mutation, high amplitude (>75%), or ≥ 2 genomic loci with LOH, high amplitude (>75%).

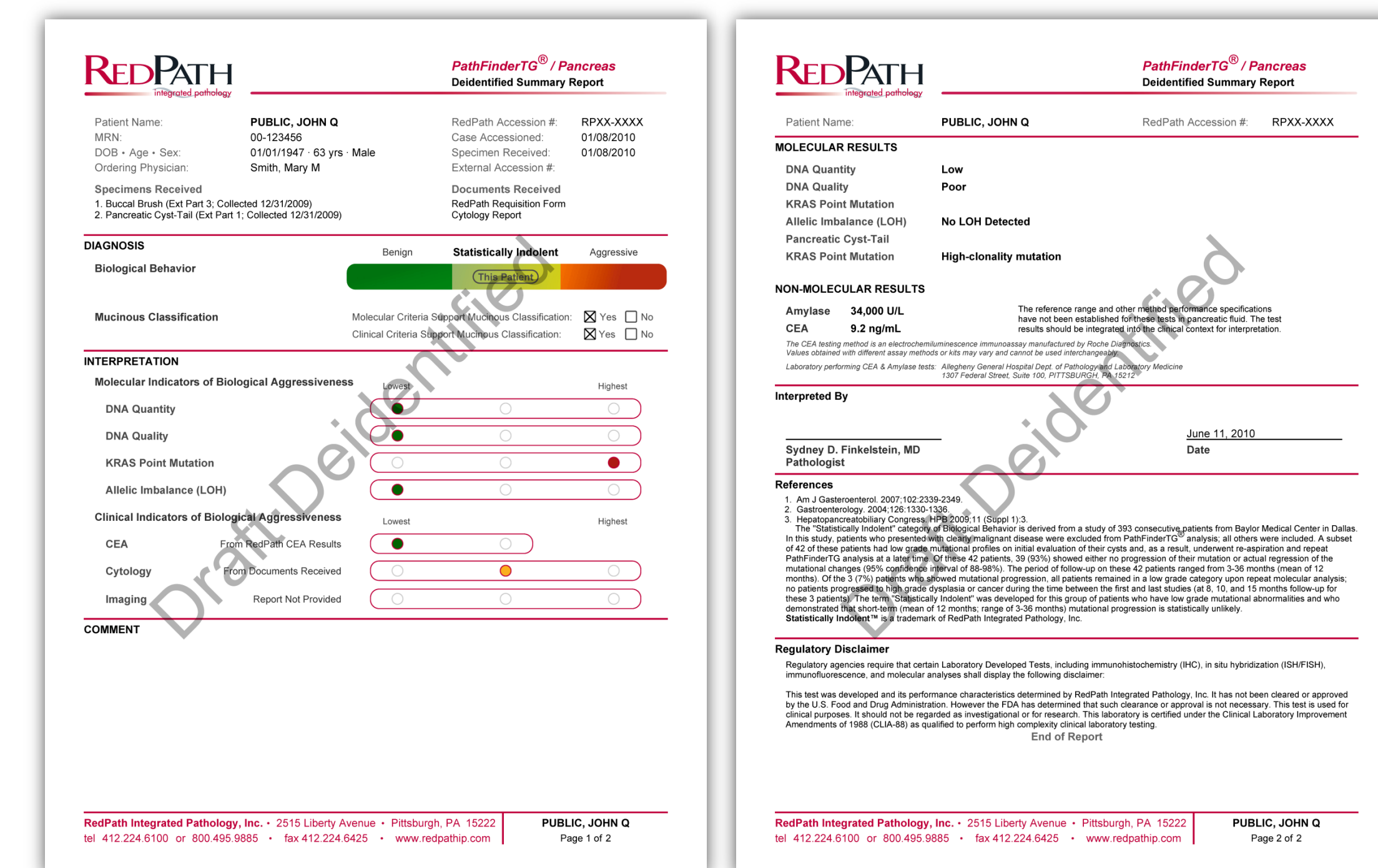


Figure 1: Sample RedPath report illustrating the genetic tests performed on pancreatic cysts. In this case the presence of a KRAS mutation in combination with low DNA quality/quantity, as well as no allelic loss, was diagnosed as an indolent mucinous lesion.

Results

Concordant diagnoses were seen in 56% (35/63) of cases. In 10 cases (16%), there was disagreement between cytology and molecular. Elevated CEA levels (>192 ng/ml) were seen in 25% of cases, each diagnosed as a mucinous lesion with molecular analysis. In 4 cases (6%) CEA was elevated when cytology was unsatisfactory, each diagnosed as benign mucinous cyst with molecular. Molecular testing provided a diagnosis in 20 cases (32%) when either cytology was unsatisfactory, or CEA not elevated (<192 ng/ml).

Table I: Ability to Render a Diagnosis

Diagnostic Test(s)	% of Cases with Diagnosis
Cytology	44 / 63 (70%)
Elevated CEA	16 / 63 (25%)
Molecular analysis	61 / 63 (97%)
Cytology unsatisfactory, Molecular diagnostic	17 / 63 (27%)
CEA not elevated, however Molecular diagnoses mucinous lesion	8 / 63 (13%)

Table II: Comparison of Mucinous and Nonmucinous Pancreatic Cysts by Molecular Diagnosis

	Nonmucinous / Benign	Mucinous / Neoplastic
K-ras mutation	0 / 63 (0%)	13 / 63 (21%) ¹
Allelic loss	4 / 63 (6%)	7 / 63 (11%)
K-ras mutation and allelic loss	0 / 63 (0%)	4 / 63 (6%) ²
CEA (ng/ml) median	6.1	403

¹ Two cases showed high amplitude (>75%) *K-ras* mutations at codon 12; 11 cases showed low amplitude (<75%) *K-ras* mutations at codon 12

² All cases showed low amplitude allelic loss (<75%); 2 cases showed allelic loss at 1 genomic loci, 1 case showed allelic loss at 2 genomic loci, and 1 case showed allelic loss at 3 genomic loci

Analysis of McNemar's test demonstrated a statistically significant benefit ($p=0.001$) with regard to the ability of molecular analysis to aid in providing a diagnosis when compared to cytology. This value was also significant when applying the criteria of elevated CEA to identify a mucinous CLP ($p=0.01$).

Conclusion

The results of our study demonstrate the addition of molecular analysis significantly increases the diagnostic yield of CLP ≤ 3 cm when used in conjunction with cytology and cyst fluid CEA levels.

Our results showed poor agreement between CEA and molecular analysis, consistent with previous work with regard to correlating these diagnostic modalities. This finding was previously attributed to the requirement for lining cells to secrete CEA, while molecular analysis depends on these same lining cells to acquire specific mutations.⁽⁵⁾

An example of the diagnostic sensitivity of molecular analysis is illustrated by a case in our study initially diagnosed as a benign mucinous lesion on cytology, while molecular analysis diagnosed malignancy. In view of the molecular findings, a repeat FNA was performed, and cytology now interpreted the lesion as suspicious for adenocarcinoma. A subsequent surgical resection revealed adenocarcinoma arising in association with an IPMN. In this case appropriate clinical management occurred as a direct result of molecular analysis.

In summary, we have presented data demonstrating molecular analysis adds to the diagnostic sensitivity of pancreatic FNA. This benefit becomes even more pronounced in scant specimens when cytology may be unsatisfactory and CEA unreliable.

References

- Brugge WR, Lauwers GY, Sahani D, Castillo CF, Warshaw AL. Cystic neoplasms of the pancreas. N Engl J Med 2004; 351:1218-1226.
- Khalid A, Brugge WR. ACG practice guidelines for the diagnosis and management of neoplastic pancreatic cysts. Am J Gastroenterol 2007; 102:2339-2349.
- Khalid A, Zahid M, Finkelstein SD, LeBlanc JK, Kaushik N, Ahmad N, Brugge WR, et al. Pancreatic cyst fluid DNA analysis in evaluating pancreatic cysts: a report of the PANDA study. Gastrointest Endosc 2009;69: 1095-1102.
- Khalid A, McGrath K, Zahid M, Wilson M, Brody D, Swalsky P, Moser J, et al. The role of pancreatic cyst fluid molecular analysis in predicting cyst pathology. Clin Gastroenterol Hepatol 2005; 3:967-973.
- Sawhney MS, Devarajan S, O'Farrell P, Cury MS, Kundu R, Vollmer CM, Brown A, et al. Comparison of carcinoembryonic antigen and molecular analysis in pancreatic cyst fluid. Gastrointest Endosc 2009; 69:1106-1110.