

7-1-2016

A Comparison Between Optical Coherence Tomography Angiography and Fluorescein Angiography for the Imaging of Type 1 Neovascularization.

Maiko Inoue

Vitreous Retina Macula Consultants of New York

Jesse J. Jung

Vitreous Retina Macula Consultants of New York

Chandrakumar Balaratnasingam

Vitreous Retina Macula Consultants of New York

Kunal K. Dansingani

Vitreous Retina Macula Consultants of New York

Follow this and additional works at: <https://jdc.jefferson.edu/willsfp>

 **Elona Dhrami-Gavazi**
Part of the [Ophthalmology Commons](#)
Vitreous Retina Macula Consultants of New York

[Let us know how access to this document benefits you](#)

See next page for additional authors

Recommended Citation

Inoue, Maiko; Jung, Jesse J.; Balaratnasingam, Chandrakumar; Dansingani, Kunal K.; Dhrami-Gavazi, Elona; Suzuki, Mihoko; de Carlo, Talisa E.; Shahlaee, Abtin; Klufas, Michael A.; El Maftouhi, Adil; Duker, Jay S.; Ho, Allen C.; Maftouhi, Maddalena Quaranta-El; Sarraf, David; and Freund, K. Bailey, "A Comparison Between Optical Coherence Tomography Angiography and Fluorescein Angiography for the Imaging of Type 1 Neovascularization." (2016). *Wills Eye Hospital Papers*. Paper 58.
<https://jdc.jefferson.edu/willsfp/58>

This Article is brought to you for free and open access by the Jefferson Digital Commons. The Jefferson Digital Commons is a service of Thomas Jefferson University's [Center for Teaching and Learning \(CTL\)](#). The Commons is a showcase for Jefferson books and journals, peer-reviewed scholarly publications, unique historical collections from the University archives, and teaching tools. The Jefferson Digital Commons allows researchers and interested readers anywhere in the world to learn about and keep up to date with Jefferson scholarship. This article has been accepted for inclusion in Wills Eye Hospital Papers by an authorized administrator of the Jefferson Digital Commons. For more information, please contact: JeffersonDigitalCommons@jefferson.edu.

Authors

Maiko Inoue, Jesse J. Jung, Chandrakumar Balaratnasingam, Kunal K. Dansingani, Elona Dhrami-Gavazi, Mihoko Suzuki, Talisa E. de Carlo, Abtin Shahlaee, Michael A. Klufas, Adil El Maftouhi, Jay S. Duker, Allen C. Ho, Maddalena Quaranta-El Maftouhi, David Sarraf, and K. Bailey Freund

A Comparison Between Optical Coherence Tomography Angiography and Fluorescein Angiography for the Imaging of Type 1 Neovascularization

Maiko Inoue,¹⁻³ Jesse J. Jung,^{1,2,4,5} Chandrakumar Balaratnasingam,^{1,2} Kunal K. Dansingani,^{1,2} Elona Dhrami-Gavazi,^{1,2,4} Mihoko Suzuki,^{1,2} Talisa E. de Carlo,^{6,7} Abtin Shahlaee,⁸ Michael A. Klufas,^{9,10} Adil El Maftouhi,¹¹ Jay S. Duker,⁶ Allen C. Ho,⁸ Maddalena Quaranta-El Maftouhi,¹¹ David Sarraf,^{9,10} and K. Bailey Freund^{1,2,12}; for the COFT-1 Study Group

¹Vitreous Retina Macula Consultants of New York, New York, New York, United States

²The LuEsther T. Mertz Retinal Research Center, Manhattan Eye, Ear and Throat Hospital, New York, New York, United States

³Yokohama City University Medical Center, Yokohama, Japan

⁴Edward S. Harkness Eye Institute, Columbia University College of Physicians and Surgeons, New York, New York, United States

⁵East Bay Retina Consultants, Inc., Oakland, California, United States

⁶New England Eye Center and Tufts Medical Center, Tufts University, Boston, Massachusetts, United States

⁷Department of Electrical Engineering and Computer Science, Research Laboratory of Electronics, Massachusetts Institute of Technology, Cambridge, Massachusetts, United States

⁸Mid Atlantic Retina, The Retina Service of Wills Eye Hospital, Thomas Jefferson University, Philadelphia, Pennsylvania, United States

⁹Department of Ophthalmology, David Geffen School of Medicine at UCLA, Los Angeles, California, United States

¹⁰Stein Eye Institute, Los Angeles, California, United States

¹¹Centre Ophtalmologique Rabelais, Lyon, France

¹²Department of Ophthalmology, New York University School of Medicine, New York, New York, United States

Correspondence: K. Bailey Freund, Vitreous Retina Macula Consultants of New York, 460 Park Avenue, 5th Floor, New York, NY 10022, USA; kbfnf@aol.com.

See the appendix for the members of the COFT-1 Study Group.

Submitted: December 14, 2015

Accepted: March 2, 2016

Citation: Inoue M, Jung JJ, Balaratnasingam C, et al. A comparison between optical coherence tomography angiography and fluorescein angiography for the imaging of type 1 neovascularization. *Invest Ophthalmol Vis Sci.* 2016;57:OCT314-OCT323. DOI:10.1167/iovs.15-18900

PURPOSE. To determine the sensitivity of the combination of optical coherence tomography angiography (OCTA) and structural optical coherence tomography (OCT) for detecting type 1 neovascularization (NV) and to determine significant factors that preclude visualization of type 1 NV using OCTA.

METHODS. Multicenter, retrospective cohort study of 115 eyes from 100 patients with type 1 NV. A retrospective review of fluorescein (FA), OCT, and OCTA imaging was performed on a consecutive series of eyes with type 1 NV from five institutions. Unmasked graders utilized FA and structural OCT data to determine the diagnosis of type 1 NV. Masked graders evaluated FA data alone, en face OCTA data alone and combined en face OCTA and structural OCT data to determine the presence of type 1 NV. Sensitivity analyses were performed using combined FA and OCT data as the reference standard.

RESULTS. A total of 105 eyes were diagnosed with type 1 NV using the reference. Of these, 90 (85.7%) could be detected using en face OCTA and structural OCT. The sensitivities of FA data alone and en face OCTA data alone for visualizing type 1 NV were the same (66.7%). Significant factors that precluded visualization of NV using en face OCTA included the height of pigment epithelial detachment, low signal strength, and treatment-naïve disease ($P < 0.05$, respectively).

CONCLUSIONS. En face OCTA and structural OCT showed better detection of type 1 NV than either FA alone or en face OCTA alone. Combining en face OCTA and structural OCT information may therefore be a useful way to noninvasively diagnose and monitor the treatment of type 1 NV.

Keywords: optical coherence tomography angiography, fluorescein angiography, neovascularization, image analysis, age-related macular degeneration

Choroidal neovascularization (CNV) is a vision-threatening complication of chorioretinal diseases.¹ Type 1 NV is the most common subtype of neovascular age-related macular degeneration (AMD) and is characterized by pathologic angiogenesis in the sub-retinal pigment epithelium (RPE) compartment.²⁻⁴ Other conditions that are commonly associated with type 1 NV include the pachychoroid-related spectrum⁵⁻⁷ of diseases including central serous chorioretinopathy (CSC),^{8,9} pachychoroid neovascularopathy (PNV),¹⁰ and polypoidal choroidal vasculopathy

lium (RPE) compartment.²⁻⁴ Other conditions that are commonly associated with type 1 NV include the pachychoroid-related spectrum⁵⁻⁷ of diseases including central serous chorioretinopathy (CSC),^{8,9} pachychoroid neovascularopathy (PNV),¹⁰ and polypoidal choroidal vasculopathy



(PCV).^{6,10} The prevalence of conditions associated with type 1 NV is projected to substantially increase over the next two decades,¹ and there remains an important need to improve the diagnostic and therapeutic outcomes related to these disorders.

The current standard for diagnosing NV relies upon the integration of fluorescein angiography (FA) and structural optical coherence tomography (OCT).^{11,12} Optical coherence tomography is a rapid, safe, and noncontact imaging modality that provides high-resolution anatomical information about retinal and choroidal structures.¹³ Fluorescein angiography, on the other hand, is an invasive, prolonged investigation that permits wide-field examination of the retina and provides information about vascular leakage, staining, and pooling.¹⁴ There are disadvantages of FA including the need for intravenous dye injection and the risk of nausea and vomiting, allergy and, rarely, anaphylaxis.¹⁵⁻¹⁷ For these reasons, frequent FA examinations are not commonly used to monitor the clinical course of neovascular diseases.

Optical coherence tomography angiography (OCTA) is a new technique that detects vascular structures using motion or flow characteristics. Optical coherence tomography angiography provides fast, noninvasive, depth-resolved vascular information and has been proposed by some investigators as a suitable replacement for FA. However, there are several patient and disease-related factors that are known to preclude reliable visualization of NV using OCTA¹⁸ and the utility of OCTA for managing NV remains unclear. The purpose of this report is to evaluate the sensitivity of en face OCTA alone and combined en face OCTA and structural OCT data for diagnosing type 1 NV. The sensitivity of these techniques is determined by comparison to the reference standard which includes FA combined with structural OCT data. The sensitivity of FA alone for detecting type 1 NV is also evaluated in this report. Results from an international, multicenter study are provided.

METHODS

Study Design

The comparison of OCTA to FA for the imaging of type 1 neovascularization (COFT-1) trial was an international, multicenter cohort study. This retrospective study design was approved by the institutional review boards at each participating center. It complied with the health insurance portability and accountability act of 1996 and followed the tenets of the Declaration of Helsinki.

Data Collection

We retrospectively reviewed the charts and imaging data of a consecutive series of eyes (both treatment naïve and treated) with type 1 NV secondary to AMD, CSC, PNV, and PCV. Polypoidal choroidal vasculopathy was diagnosed using a combination of imaging techniques including OCT, FA, and indocyanine green angiography. Pachychoroid neovascularopathy was defined as a form of type 1 NV occurring over areas of pachyvessels that exceeded the choroidal diameter seen in normal eyes.⁵ The diagnosis of each form of type 1 NV was performed at the individual institutions. All imaging studies were performed between August 1, 2014, and August 1, 2015, at one of five tertiary referral institutions, which involved four sites in the United States and one site in France. Only eyes that underwent OCTA using the spectral domain (SD)-OCT device (Optovue RTVue XR Avanti; Optovue, Inc., Fremont, CA, USA)

and concomitant FA and OCT imaging within 7 days were included. Eyes that received treatment with anti-vascular endothelial growth factor (VEGF) therapy or photodynamic therapy (PDT) between imaging studies were excluded.

Fluorescein angiography was performed with a commercial OCT device (Heidelberg Spectralis HRA + OCT; Heidelberg Engineering, Heidelberg, Germany). Spectral-domain OCT imaging (Heidelberg Spectralis HRA + OCT; Heidelberg Engineering or Cirrus high-definition OCT; Carl Zeiss Meditec, Dublin, CA, USA) including enhanced depth imaging OCT was performed on all eyes.

Patient demographic characteristics at the time of FA and OCTA imaging including age, sex, and previous treatments were recorded. The Snellen best-corrected visual acuity (BCVA) was also recorded and converted to logarithm of the minimum angle of resolution (logMAR) for statistical analysis.

Optical Coherence Tomography Angiography

The optical coherence tomography angiography system that was used in this study was the Optovue RTVue XR Avanti (Optovue, Inc.). This system utilizes an A-scan rate of 70,000 scans per second, a light source centered on 840 nm and a bandwidth of 45 nm to obtain split-spectrum amplitude-decorrelation angiography images. Each OCTA volume contains 304 × 304 A-scans with two consecutive B-scans captured at each fixed position before proceeding to the next sampling location.¹⁹ Angiography information displayed is the average of the decorrelation values when viewed perpendicularly through the thickness being evaluated.

To ensure consistent image selection, raw data (en face OCTA and structural OCT) obtained on the AngioVue from all five centers were sent to one institution. One of the unmasked investigators chose the best quality images of en face OCTA (3 × 3 mm) and structural OCT for analysis (Fig. 1). Automated segmentation was used to visualize neovascular tissue in the plane above Bruch's membrane. However, when automated techniques failed, the areas of segmentation were manually adjusted until the tissue of interest was visualized.

Unmasked Evaluation of Neovascularization

Figure 1 is a flowchart that illustrates the study design. Selection of suitable cases was initially undertaken at each of the five centers participating in this study. Fluorescein angiography and OCT information from the entire data set was then reviewed by two unmasked graders (MI, KD) to confirm type 1 NV. Fluorescein angiography information that was used to diagnose NV consisted of single frames from the early and late stages of the angiogram. Type 1 NV on FA was defined as "present" if there were any characteristic signs of CNV on FA including stippled hyperfluorescence and/or late hyperfluorescent leakage. Eyes determined to have type 2 (subretinal), type 3 (retinal angiomatous proliferation, intraretinal) and mixed NV were excluded from further analysis.

Additional features that were recorded from structural OCT scans included presence/absence of exudative change, maximum width of pigment epithelial detachment (PED), and maximum height of PED. Length of PED was measured using the caliper function or analysis tools in the Fiji distribution (Fiji is just ImageJ [http://imagej.nih.gov/ij/; provided in the public domain by the National Institutes of Health, Bethesda, MD, USA], http://fiji.sc).²⁰

En face OCTA images from eyes that were deemed to have type 1 NV on FA and OCT were then evaluated by unmasked graders. The ability to visualize NV on en face OCTA was graded in a binary fashion: present or absent. When type 1 NV was seen on en face OCTA images it was categorized into one

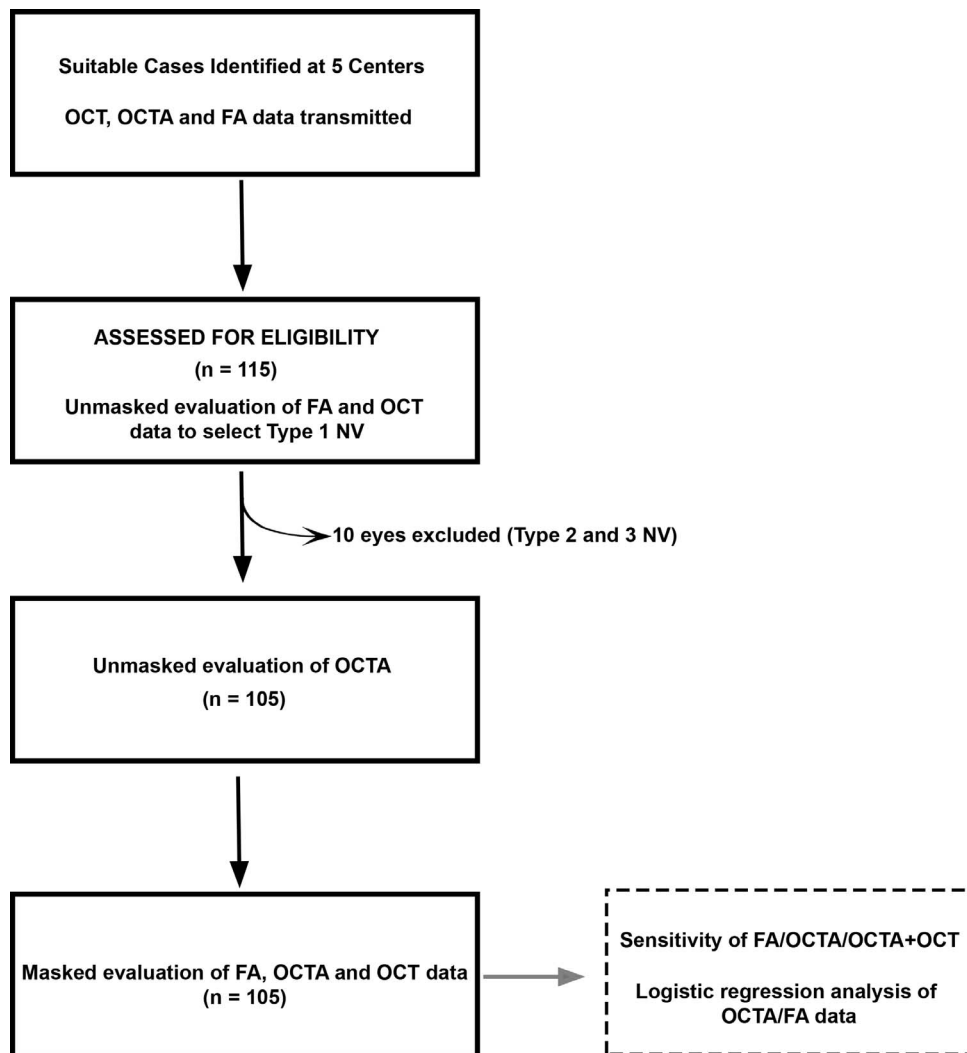


FIGURE 1. A flow chart to illustrate study design.

of 2 types: tangled pattern²¹ or filamentous pattern.²² Qualitative comparisons were made between FA and en face OCTA with respect to size and morphologic appearances of neovascular lesions. The appearance of NV as imaged by en face OCTA at sites of FA leakage or staining was also evaluated.

Masked Evaluation of Sensitivity of FA and OCTA

Two retina specialists who were blinded to the purpose and results of the study evaluated the FA alone, en face OCTA alone, and combined en face OCTA with structural OCT. The structural OCT B-scans from the same raw data acquired by the SD-OCTA were utilized to provide for uniform grading. Grading for NV was performed in a binary manner (1 = present, 0 = absent). Fluorescein angiography, en face OCTA, and combined en face OCTA with structural OCT were evaluated separately and additional patient information was not provided. When the evaluation was inconsistent, a third masked reader made the final arbitration. Sensitivity of FA alone, en face OCTA alone, and combined en face OCTA with structural OCT for diagnosing type 1 NV was determined by comparing it against the reference, the analysis of unmasked graders using combined structural OCT and FA information.

Statistical Analysis

Kruskal-Wallis 1-way ANOVA on ranks was used to compare demographic characteristics between AMD, CSC, PNV, and PCV groups. Scheffe multiple comparison test was used to compare the data within each group.

Logistic regression analysis was used to determine the influence of different variables including age, sex, cause of type 1 NV (AMD or pachychoroid-related diseases), treatment (treatment-naïve or treated), BCVA, presence/absence of exudative change, width and height of PED, signal strength of OCTA images, and the ability to visualize type 1 NV on FA or on en face OCTA.

Agreement between masked observers was assessed using the kappa statistic which was defined as follows: greater than 0.81 represents “excellent” agreement; 0.61–0.80 represents “good” agreement; 0.41–0.60 represents “moderate” agreement and less than 0.40 represents “poor” agreement.²³ The interobserver reproducibility of en face OCTA and FA was compared using Fisher’s exact test. Statistical analysis was performed using statistical software (SPSS software Version 21; SPSS, Inc., Chicago, IL, USA). A value of $P < 0.05$ was considered significant.

TABLE 1. Demographic and Clinical Characteristics of Eyes With Type 1 NV

Total eyes	105
Number of patients, <i>n</i> (%)	92
Male	54 (58.7)
Female	38 (41.3)
Age, mean \pm SD, year (range)	73.1 \pm 11.7 (44–95)
Side (right/left)	52/53
Mean logMAR BCVA (Snellen equivalent)	0.44 \pm 0.40 (20/55)
Origin of type 1 NV, <i>n</i> (%)	
Neovascular AMD (%)	59 (56.2)
CSC	22 (21.0)
PNV	2 (1.9)
PCV	22 (21.0)
Previous treatment, <i>n</i> (%)	
Anti-VEGF	43 (41.0)
Anti-VEGF + PDT	1 (1.0)
Anti-VEGF + PDT + laser photocoagulation	2 (1.9)
Laser photocoagulation	3 (2.8)
None	56 (53.3)
Mean signal strength of OCTA images	59.6 \pm 9.1
Appearance of NV on OCTA, <i>n</i> (%)	
Tangled vessel pattern	71 (67.6)
Filamentous pattern	5 (4.8)
Not detected	29 (27.6)

RESULTS

Patient Characteristics

A total of 115 eyes of 100 patients, which were sent as type 1 NV from 5 institutions, were evaluated by unmasked graders. Ten eyes were determined to have type 2 or type 3 NV and were excluded from the study resulting in a total of 105 eyes of 92 patients. Demographic and clinical characteristics of patients with type 1 NV are shown in Table 1. Mean patient age was 73.1 \pm 11.7 years (median, 73 years; range, 44–95 years). Forty-nine (46.7%) of the patients had received previous treatment with intravitreal anti-VEGF therapy, PDT, or laser photocoagulation. Mean logMAR BCVA was 0.44 (20/55 Snellen equivalent). Mean signal strength of OCTA images was 59.6 \pm 9.1.

Type 1 NV was due to AMD in 59 eyes (56.2%), CSC in 22 eyes (21.0%), PNV in 2 eyes (1.9%) and PCV in 22 eyes (21.0%). The demographic and lesion characteristics of each of the subgroups with type 1 NV are summarized in Table 2. Patient characteristics such as age, sex, and BCVA were significantly different between the four groups. Mean BCVA was better in the PCV group than the neovascular AMD group ($P = 0.021$), but there were no significant differences between other groups (all $P > 0.05$). Age was significantly higher in the neovascular

AMD group than in the CSC and PCV groups ($P < 0.001$ and $P = 0.001$, respectively).

Unmasked Evaluation of Neovascularization

A total of 71 of 105 eyes (67.6%) demonstrated a tangled pattern of NV with en face OCTA and five eyes (4.8%) showed a filamentous pattern of NV on en face OCTA (Figs. 2, 3). The boundaries of the areas of NV appeared clearly defined on en face OCTA images. Type 1 NV was not identified with en face OCTA in 29 eyes (27.6%) that were deemed to have type 1 NV by unmasked graders using the reference (Fig. 4). A tall PED ($>2000 \mu\text{m}$) as localized at the site of NV in 17 of these 29 eyes and a significant loss of signal intensity was observed beyond the outer margins of the RPE in these eyes (Fig. 4).

Of the 76 eyes that demonstrated type 1 NV with en face OCTA, 61 (80.3%), were localized within sites of fluorescein leakage/staining (Figs. 2, 3). In the remaining 15 eyes (19.7%), en face OCTA identified type 1 NV at sites where fluorescein leakage/staining was not observed (Fig. 5). There were no discernible differences in the structure and flow signatures of NV with en face OCTA between areas of fluorescein leakage and staining. The area of NV frequently appeared larger on FA compared to en face OCTA due to the occurrence of RPE window defects and fluorescein leakage/staining. In 39 cases (51.3%), a large or small dark ring was identified around the NV with OCTA (Fig. 6).

Masked Grading Outcomes and Sensitivity Analyses

A diagnosis of type 1 NV was confirmed using FA alone in 70 eyes, en face OCTA alone in 70 eyes and combined en face OCTA with structural OCT in 90 eyes by the masked readers. The sensitivity for the detection of type 1 NV using FA alone, en face OCTA alone and combined en face OCTA with structural OCT was therefore 66.7% (70/105), 66.7% (70/105), and 85.7%, (90/105) respectively, compared with the reference. Interobserver agreement was moderate with a kappa value of 0.454 (standard error ± 0.078 , $P < 0.001$) for FA alone, good with 0.686 (standard error ± 0.072 , $P < 0.001$) for en face OCTA alone and 0.660 (standard error ± 0.105 , $P < 0.001$) for combined en face OCTA and structural OCT data. The interobserver agreement for en face OCTA ($P = 0.026$) and combined en face OCTA with structural OCT ($P < 0.001$) was significantly greater than FA alone, respectively.

Factors Influencing Detection of Neovascularization

Logistic regression analysis of FA data acquired from masked readers showed that detection of type 1 NV correlated

TABLE 2. Comparison of Characteristics for Each Origin of Type 1 NV

	Neovascular AMD, <i>n</i> = 59	CSC, <i>n</i> = 22	PNV, <i>n</i> = 2	PCV, <i>n</i> = 22	<i>P</i> Value*
Patient	48	21	2	22	
Number of males/females	21/27	15/6	2/0	17/5	0.016
Age, years, mean \pm SD	79.7 \pm 8.7	62.2 \pm 11.7	73.0 \pm 2.8	68.8 \pm 7.2	<0.001
Baseline logMAR visual acuity, mean \pm SD	0.51 \pm 0.39	0.35 \pm 0.33	0.15 \pm 0.21	0.35 \pm 0.49	0.005
Previous treatment, +/-	23/36	9/13	1/1	16/6	0.054
Identified/unidentified of NV on OCTA	38/21	17/5	1/1	19/3	0.203
Mean signal strength of the OCTA image	57.9 \pm 8.6	62.1 \pm 11.4	62.0 \pm 11.3	61.5 \pm 7.1	0.127

To compare the characteristics for each, origin of type 1 NV was investigated using the Kruskal-Wallis test.

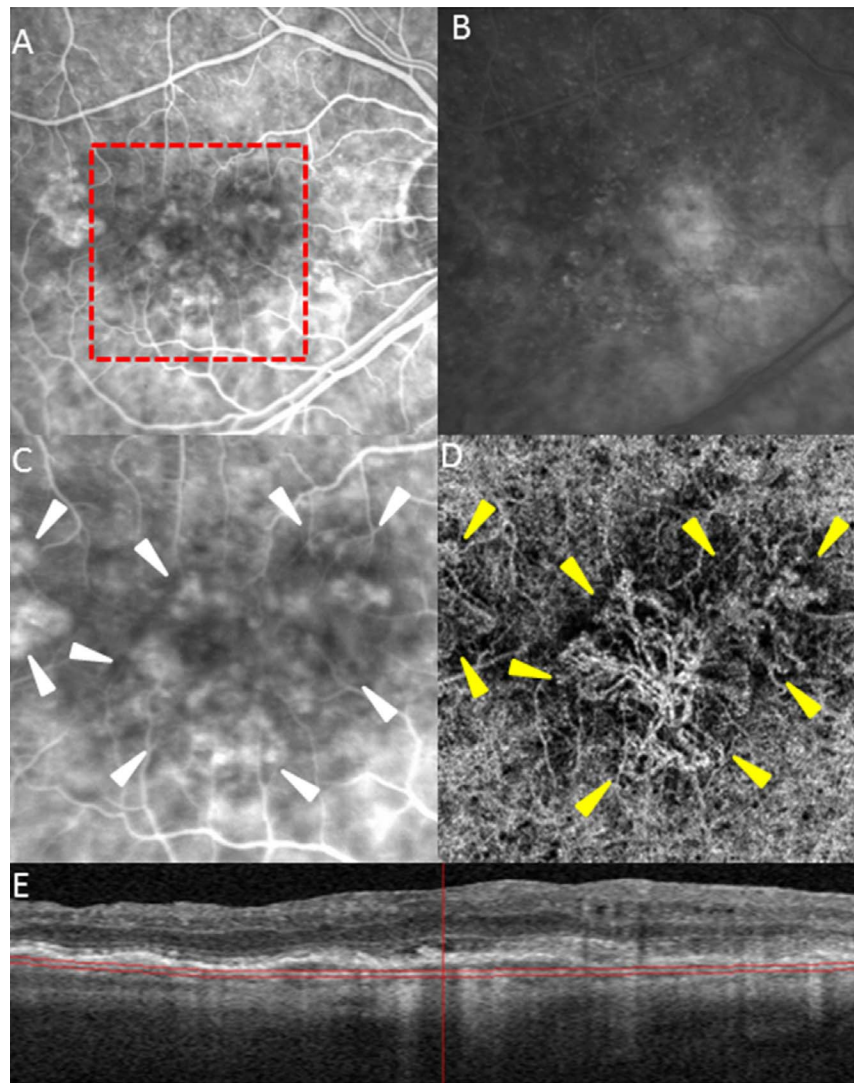


FIGURE 2. Tangled morphology of type 1 neovascularization as imaged with FA and en face OCTA in an eye with age-related macular degeneration. (A) Early-phase FA of the right eye shows several irregular areas of hyperfluorescence. (B) Late-phase FA shows areas of poorly defined leakage and staining. (C) Magnified view of early-phase FA shows poorly defined irregular borders of the lesion (*arrowheads*). (D) A tangled pattern within the neovascular lesion is seen on the corresponding OCTA. The localization of neovascularization on en face OCTA correlates with the hyperfluorescent area on FA (*yellow arrowheads*). (E) The structural OCT provides details about the plane of segmentation of the en face OCTA. A fibrovascular pigment epithelial detachment with subretinal hyperreflective exudation is seen.

significantly to the cause of type 1 NV ($P = 0.045$; Table 3). Type 1 NV was visualized more frequently in eyes with pachychoroid spectrum on FA. Analysis of the en face OCTA data showed that detection of type 1 NV significantly correlated to OCTA signal strength ($P = 0.034$); treatment history ($P = 0.006$); and PED height ($P = 0.018$). Type 1 NV was more frequently visualized in eyes with a higher signal strength, shallower PED, and a history of previous treatment. However, detection of type 1 NV on OCTA was not significantly correlated to the cause of the type 1 NV ($P = 0.789$).

DISCUSSION

The prevalence of AMD is projected to rise in the developed world in the next two decades, and, in some countries, the increase is predicted to be as high as 75% by 2040.¹ Refining our ability to visualize NV in AMD may be one way to reduce the clinical burden and visual morbidity associated with this disease. Integration of FA and OCT information is currently

considered the standard for diagnosing NV.^{11,12} However, the invasive nature and potential adverse effects of FA preclude its frequent use in the clinical setting. Other drawbacks of FA include its inability to estimate accurately the expanse of NV and differentiate leakage from staining or RPE window defects in some settings. A recent study suggested that the sensitivity and specificity of OCTA, with the use of corresponding structural OCT, for detecting type 1 and mixed (type 1 and 2) NV in CSC could be as high as 100%.²⁴ The purpose of this multicenter study was to define the sensitivity of OCTA for diagnosing type 1 NV in neovascular AMD, CSC, PNV, and PCV and to ascertain if it is an adequate replacement for the current standard (FA and OCT).

In this study, we found that the sensitivity for detecting type 1 NV using OCTA data combined with structural OCT information was 85.7%. In comparison, the sensitivity of en face OCTA alone and FA alone for detecting type 1 NV was the same (66.7%). The higher sensitivity for detection achieved by combining OCTA and structural OCT data suggests that it may

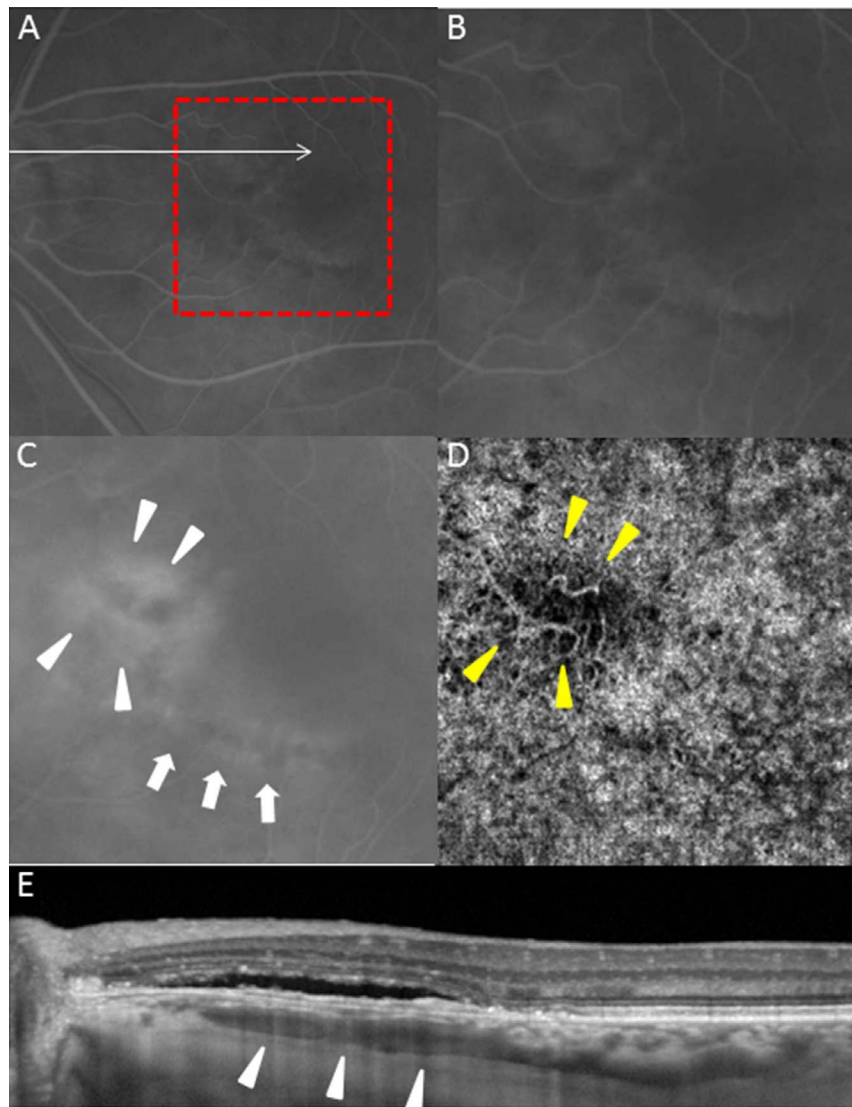


FIGURE 3. Filamentous morphology of type 1 neovascularization (NV) as imaged with FA and en face OCTA in an eye with central serous chorioretinopathy. (A) Early-phase FA of the left eye shows an area of faint hyperfluorescence inferior and nasal to the macula. (B) Magnified view of the early-phase FA. (C) Late-phase FA shows leakage (*arrowheads*). An inferior area of hyperfluorescence due to a window defect is also seen (*arrows*). (D) Corresponding en face OCTA demonstrates NV (*yellow arrowheads*) of filamentous morphology within the area of FA leakage. (E) Enhanced-depth imaging OCT shows a shallow irregular PED with overlying subretinal fluid at the site of NV and demonstrates underlying pachyvessels beneath the PED (*arrowheads*).

be a useful technique for the noninvasive, clinical diagnosis of type 1 NV. It may also potentially translate to a reduced need for FA in these settings.

Previous reports have suggested that FA and stereo color photographs are the best method for detecting new onset choroidal NV.²⁵ In the current study, the overall sensitivity of conventional FA alone for detecting NV was lower than expected, and this may be because stereoscopic FA and color photographs were not used. Over the past several years, stereoscopic photography has been performed less commonly due to the availability of digital imaging and the time-consuming nature of color and FA stereoscopic photography which limit their use in daily clinical practice.

In this study, the interobserver agreement for OCTA was greater than for FA suggesting a greater degree of reproducibility in the interpretation of OCTA images. This finding suggests that there may be more subjectivity with FA interpretation compared with OCTA.

An important finding in this study was that NV was not visualized using en face OCTA alone in 27.6% of eyes that were deemed to have type 1 NV by the reference. This finding is consistent with a previous study investigating type 1 NV in neovascular AMD.¹⁸ Logistic regression analysis identified three significant variables that influenced identification of type 1 NV, and these included the height of PEDs, the signal strength of the scan and a history of prior treatment for NV. The most frequent reason that NV was not detected using en face OCTA was the presence of a relatively tall PED at the site of NV. Pigment epithelium detachments have the capacity to attenuate the OCT signal and can preclude visualization of vascular structures beyond the RPE layer. Cataract, media opacities, poor fixation, and projection artifacts of retinal vessels on OCTA can compound this problem further and diminish the quality of OCTA images.²⁶ Interestingly, the detection rate of type 1 NV with en face OCTA was significantly greater in eyes with a history of treatment. This

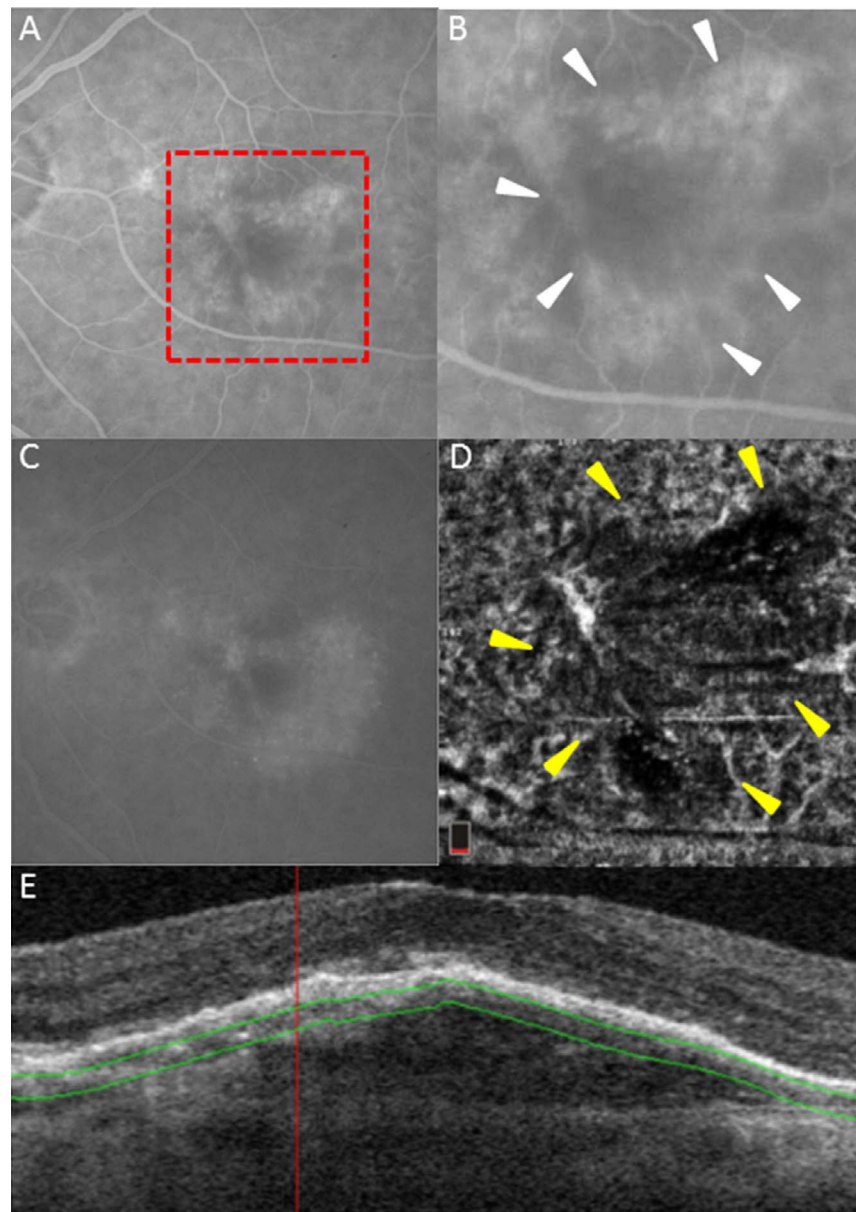


FIGURE 4. An example of en face OCTA failing to show neovascularization in an eye with AMD despite visualization by FA. **(A)** Early-phase FA shows an area of stippled hyperfluorescence with irregular borders. **(B)** A magnified view of the early-phase FA. Well-defined borders of the vascularized PED are seen (*arrowheads*). **(C)** Late-phase FA shows hyperfluorescent staining of a vascularized PED. **(D)** The corresponding en face OCTA demonstrates low signal and an absence of flow signature at the site of the PED (*yellow arrowheads*). **(E)** The structural OCT illustrates a tall PED and identifies the plane of en face OCTA segmentation.

finding is also consistent with a previous report which showed that maturation and abnormalization of neovascular vessels occurs following continuous anti-VEGF therapy.^{18,21} Chronic, multilayered fibrovascular PEDs likely contain more mature fibrovascular type 1 complexes and are more readily visualized by en face OCTA compared to treatment-naïve eyes.^{18,27}

Our study showed that the localization of NV with en face OCTA correlated with sites of leakage or staining on FA in most cases. Furthermore, in some eyes, type 1 NV was detected with en face OCTA in areas where it was not detected with FA. Although we cannot rule out the possibility of a false positive interpretation, this finding suggests that some type 1 lesions visible on en face OCTA could represent quiescent vessels that may not leak fluorescein dye. Currently, it remains unclear if

quiescent lesions seen on OCTA require anti-VEGF therapy and longitudinal studies will be required to define the natural course of these lesions. With regard to those lesions seen on OCTA that demonstrated leakage on FA, we were unable to identify any specific OCTA imaging biomarkers that seemed to correlate with the degree of leakage present in active NV seen on conventional FA. Therefore, OCTA still remains limited in its ability to identify leakage and activity of type 1 NV compared with conventional FA.

In this study, 51.3% of cases demonstrated a small or large dark ring around the type 1 NV on OCTA. Jia and colleagues²⁸ first described the association of a “halo” finding in some cases of CNV imaged with OCTA. They described that the halo seemed to be due to mechanical compression of the underlying choriocapillaris from the exudative changes leading

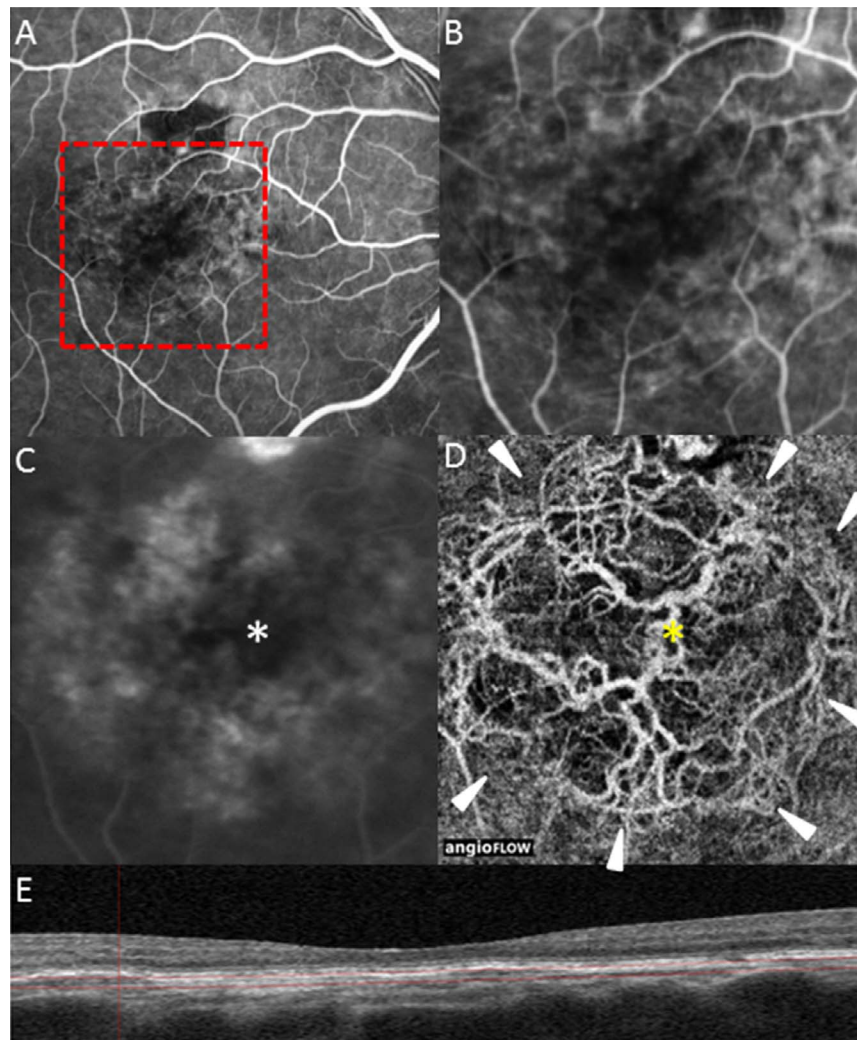


FIGURE 5. Comparison of FA and en face OCTA. (A) Early-phase FA image shows multiple areas of irregular hyperfluorescence. (B) Magnified view of the early-phase FA. (C) Late-phase FA shows multiple areas of hyperfluorescent staining. Note the absence of hyperfluorescence in the central macula (*asterisk*). (D) Corresponding en face OCTA shows NV with tangled morphology. Note that there are areas of NV clearly visualized on en face OCTA that are not detected on FA (*yellow asterisk*). The margins of the lesion also appear better defined on en face OCTA (*white arrow heads*). (E) The structural OCT provides details about the plane of segmentation of the en face OCTA. A shallow irregular PED is seen.

to alterations in normal blood flow in the choriocapillaris and darkening on OCTA imaging.²⁸ Previous histologic analysis by McLeod and colleagues²⁹ supported this hypothesis and demonstrated that choriocapillaris dropout was evident in the absence of RPE adjacent to active NV. In our study, we noted the dark halo in some eyes both with and without intraretinal and/or subretinal fluid visible on structural OCT. This observation suggests that there may be additional explanations for the halo including changes in imaging artifacts, including projection artifacts, occurring at the edges of elevated vascularized PEDs. Another possibility is lower flow rates occurring at the margins of certain neovascular lesions. It is possible that attenuation of flow at the edges of some lesions may be below the detection level currently utilized in some OCTA algorithms.

Limitations of this study include its retrospective nature and a lack of overall uniformity of case selection due to the participation of multiple institutions. The manual detection of type 1 NV on en face OCTA could be reader dependent. To minimize this confounding factor, we designed the study such

TABLE 3. Logistic Regression Analysis on FA and OCTA in Detecting NV

Variables	FA		OCTA	
	P Value	Odds Ratio	P Value	Odds Ratio
Age	0.227	1.032	0.750	1.010
Sex	0.087	2.340	0.723	1.216
Cause of type 1 NV (AMD or pachychoroid spectrum)	0.045	3.477	0.789	1.190
Treatment (treatment-naïve or treated)	0.423	1.455	0.006	4.851
logMAR visual acuity	0.152	2.638	0.819	0.863
Exudative changes on OCT	0.539	1.366	0.245	1.915
Width of PED	0.412	1.000	0.886	1.000
Height of PED	0.487	1.001	0.018	0.993
Signal strength of the OCTA image	-	-	0.034	1.070

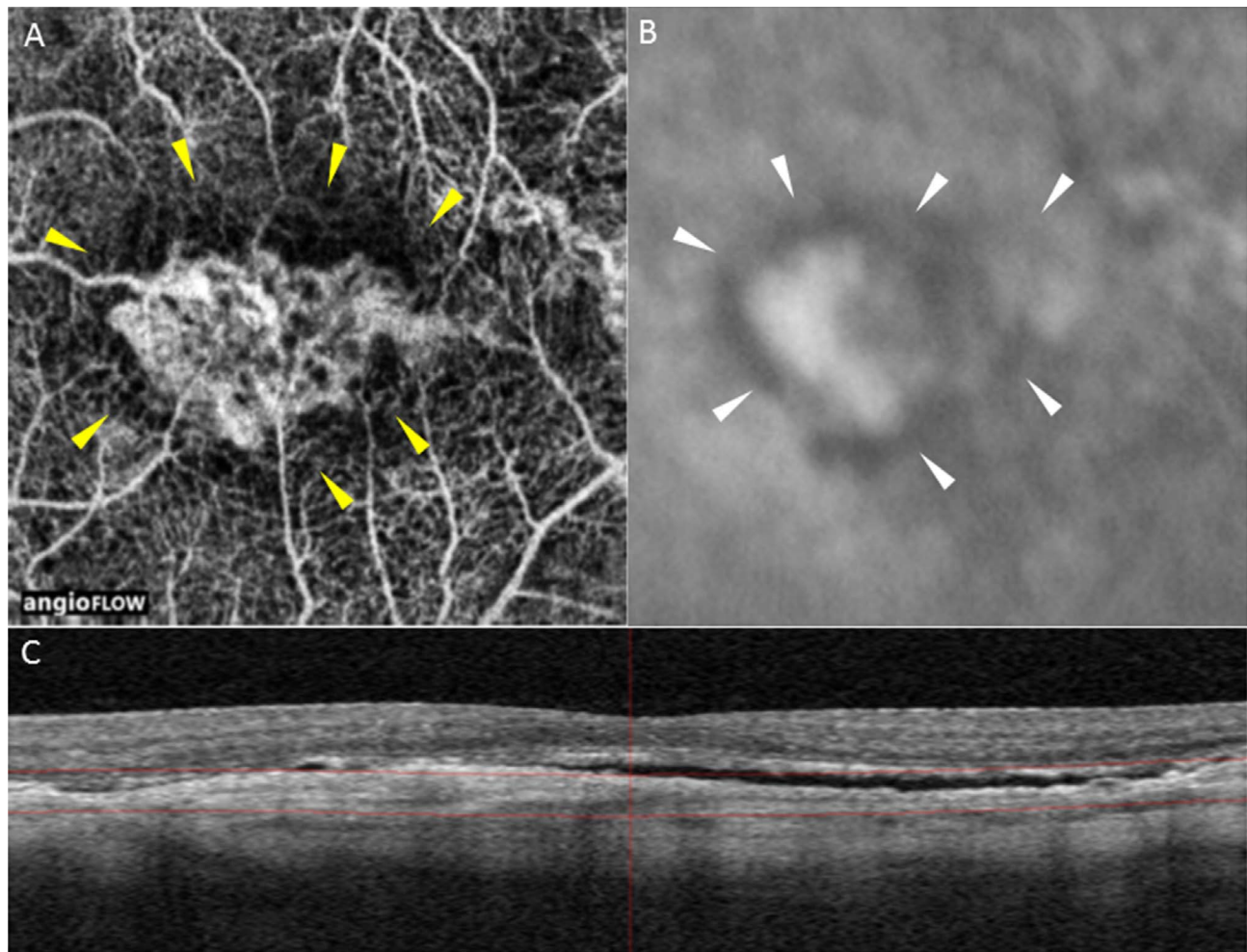


FIGURE 6. An example of a dark ring on en face OCTA and FA. (A) En face OCTA demonstrates tangled morphology of type 1 NV surrounded by the dark ring (yellow arrowheads). (B) Early-phase FA also shows a dark ring in the same position (white arrowheads). (C) The structural OCT illustrates a type 1 NV with subretinal fluid.

that the unmasked grader prepared the best images of type 1 NV as seen on OCTA for evaluation by masked graders. Furthermore, because we had already made the determination that all of the eyes had type 1 NV based upon the findings of FA and OCT, it was not possible to evaluate the specificity of OCTA in this study. Finally, it will be important to investigate the sensitivity of swept-source OCTA for detecting type 1 NV and to determine if it is different to SD-OCTA.

A strength of the study is the comparison of contemporaneous information acquired using FA, OCT, and OCTA from a relatively large cohort of subjects. The findings of this study suggest that en face OCTA and structural OCT does not replace the current standard (FA and OCT) in the diagnosis of type 1 NV. Rather, our findings demonstrate the effectiveness of OCTA as an adjunctive imaging modality that complements the information derived from FA. It is possible that noninvasive multimodal imaging, including the combination of en face OCTA and structural OCT will serve an important future role in the diagnosis and management of neovascular diseases involving the choroid. However, further longitudinal information will be required to clarify the role of OCTA in clinical practice and to determine if it is a suitable replacement for FA.

Acknowledgments

Supported by the LuEsther T. Mertz Retinal Research Center, Manhattan Eye, Ear and Throat Hospital (New York, NY, USA) and the Macula Foundation, Inc. (New York, NY, USA). The authors alone are responsible for the content and writing of the paper.

Disclosure: **M. Inoue**, None; **J.J. Jung**, Optos (C), Carl Zeiss Meditec (C); **C. Balaratnasingam**, None; **K.K. Dansingani**, None; **E. Dhrami-Gavazi**, None; **M. Suzuki**, None; **T.E. de Carlo**, None; **A. Shahlaee**, None; **M.A. Klufas**, None; **A.E. Maftouhi**, Optovue (F, I), EBC (F, I), Bayer (F, I); **J.S. Duker**, Carl Zeiss Meditec (C), Optovue (C), Alcon/Novartis (C), CoDa Therapeutics (C), Thrombogenics (C), Allergan (C), Lumenis (C), Santen (C), Hemera Biosciences (C), EyeNetra Inc. (C), Ophthotech (C), Eleven Biotherapeutics (S); **A.C. Ho**, Alcon/Novartis (C), Thrombogenics (C), Allergan (C), Janssen/J&J (C), Genentech (C), Regeneron (C), Second Sight (C); **M.Q. Maftouhi**, EBC (C), Alcon/Novartis (C), Bayer (C), Allergan (C); **D. Sarraf**, Genentech (F), Regeneron (F); **K.B. Freund**, Optovue (I), Genentech (I), Optos (I), REGENXBIO (I), ThromboGenics (I), Ohr Pharmaceutical (I), Heidelberg Engineering (I)

References

1. Wong WL, Su X, Li X, et al. Global prevalence of age-related macular degeneration and disease burden projection for 2020

- and 2040: a systematic review and meta-analysis. *Lancet Glob Health*. 2014;2:e106-e116.
2. Freund KB, Yannuzzi LA, Sorenson JA. Age-related macular degeneration and choroidal neovascularization. *Am J Ophthalmol*. 1993;115:786-791.
 3. Gass JD. Biomicroscopic and histopathologic considerations regarding the feasibility of surgical excision of subfoveal neovascular membranes. *Am J Ophthalmol*. 1994;118:258-298.
 4. Grossniklaus HE, Gass JDM. Clinicopathologic correlations of surgically excised type 1 and type 2 submacular choroidal neovascular membranes. *Am J Ophthalmol*. 1998;126:59-69.
 5. Dansingani KK, Naysan J, Balaratnasingam C, Freund KB. En face imaging of pachychoroid spectrum disorders with swept-source optical coherence tomography. *Retina*. 2016;36:499-516.
 6. Balaratnasingam C, Lee WK, Hideki K, et al. Polypoidal choroidal vasculopathy: a distinct disease or manifestation of many? *Retina*. 2016;36:1-8.
 7. Dansingani KK, Balaratnasingam C, Klufas MA, Sarraf D, Freund KB. Optical coherence tomography angiography of shallow irregular pigment epithelial detachments in pachychoroid spectrum disease. *Am J Ophthalmol*. 2015;160:1243-1254.e2.
 8. Warrow DJ, Hoang QV, Freund KB. Pachychoroid pigment epitheliopathy. *Retina*. 2013;33:1659-1672.
 9. Fung AT, Yannuzzi LA, Freund KB. Type 1 (sub-retinal pigment epithelial) neovascularization in central serous chorioretinopathy masquerading as neovascular age-related macular degeneration. *Retina*. 2012;32:1829-1837.
 10. Pang CE, Freund KB. Pachychoroid neovascularopathy. *Retina*. 2015;35:1-9.
 11. Freund KB, Zweifel SA, Engelbert M. Do we need a new classification for choroidal neovascularization in age-related macular degeneration? *Retina*. 2010;30:1333-1349.
 12. Jung JJ, Chen CY, Mrejen S, et al. The incidence of neovascular subtypes in newly diagnosed neovascular age-related macular degeneration. *Am J Ophthalmol*. 2014;158:769-779.e2.
 13. Hee MR, Baumal CR, Puliafito CA, et al. Optical coherence tomography of age-related macular degeneration and choroidal neovascularization. *Ophthalmology*. 1996;103:1260-1270.
 14. Macular Photocoagulation Study Group. Subfoveal neovascular lesions in age-related macular degeneration. Guidelines for evaluation and treatment in the macular photocoagulation study. *Arch Ophthalmol*. 1991;109:1242-1257.
 15. Ellis PP, Schoenberger M, Rendi MA. Antihistamines as prophylaxis against side reactions to intravenous fluorescein. *Trans Am Ophthalmol Soc*. 1980;78:190-205.
 16. Kwiterovich KA, Maguire MG, Murphy RP, et al. Frequency of adverse systemic reactions after fluorescein angiography. Results of a prospective study. *Ophthalmology*. 1991;98:1139-1142.
 17. Heffner JE. Reactions to fluorescein. *JAMA*. 1980;243:2029-2030.
 18. Kuehlewein L, Bansal M, Lenis TL, et al. Optical coherence tomography angiography of type 1 neovascularization in age-related macular degeneration. *Am J Ophthalmol*. 2015;160:739-748.
 19. Spaide RF, Klancnik JM Jr, Cooney MJ. Retinal vascular layers imaged by fluorescein angiography and optical coherence tomography angiography. *JAMA Ophthalmol*. 2015;133:45-50.
 20. Schindelin J, Arganda-Carreras I, Frise E, et al. Fiji: an open-source platform for biological-image analysis. *Nat Methods*. 2012;9:676-682.
 21. Spaide RF. Optical coherence tomography angiography signs of vascular abnormalization with antiangiogenic therapy for choroidal neovascularization. *Am J Ophthalmol*. 2015;160:6-16.
 22. de Carlo TE, Bonini Filho MA, Chin AT, et al. Spectral-domain optical coherence tomography angiography of choroidal neovascularization. *Ophthalmology*. 2015;122:1228-1238.
 23. Cohen J. Weighted kappa: nominal scale agreement with provision for scaled disagreement or partial credit. *Psychol Bull*. 1968;70:213-220.
 24. Bonini Filho MA, de Carlo TE, Ferrara D, et al. Association of choroidal neovascularization and central serous chorioretinopathy with optical coherence tomography angiography. *JAMA Ophthalmol*. 2015;133:899-906.
 25. Do DV, Gower EW, Cassard SD, et al. Detection of new-onset choroidal neovascularization using optical coherence tomography: the AMD DOC Study. *Ophthalmology*. 2012;119:771-778.
 26. Spaide RF, Fujimoto JG, Waheed NK. Image artifacts in optical coherence tomography angiography. *Retina*. 2015;35:2163-2180.
 27. Rahimy E, Freund KB, Larsen M, et al. Multilayered pigment epithelial detachment in neovascular age-related macular degeneration. *Retina*. 2014;34:1289-1295.
 28. Jia Y, Bailey ST, Wilson DJ, et al. Quantitative optical coherence tomography angiography of choroidal neovascularization in age-related macular degeneration. *Ophthalmology*. 2014;121:1435-1444.
 29. McLeod DS, Grebe R, Bhutto I, et al. Relationship between RPE and choriocapillaris in age-related macular degeneration. *Invest Ophthalmol Vis Sci*. 2009;50:4982-4991.

APPENDIX A

COFT-1 Study Group

Maiko Inoue, MD
 Jesse J. Jung, MD
 Chandrakumar Balaratnasingam, MD, PhD
 Kunal K. Dansingani, MA, FRCOphth
 Elona Dhrami-Gavazi, MD
 Mihoko Suzuki, MD
 Talisa E. de Carlo, BA
 Abtin Shahlaee, MD
 Michael A. Klufas, MD
 Adil-El Maftouhi, OD
 Jay S. Duker, MD
 Allen C. Ho, MD
 Maddalena Quaranta-El Maftouhi, MD
 David Sarraf, MD
 K. Bailey Freund, MD