

## Case Report

# Organophosphate retinopathy

Hang Pham<sup>1</sup>, Michelle D. Lingao<sup>2</sup>, Anuradha Ganesh<sup>3</sup>, Jenina E. Capasso<sup>4</sup>, Rosanne Keep<sup>5</sup>,  
Karthikeyan A. Sadagopan<sup>6</sup>, Alex V. Levin<sup>1,4</sup>

<sup>1</sup>Sidney Kimmel Medical College, Thomas Jefferson University, <sup>4</sup>Department of Pediatric Ophthalmology and Ocular Genetics, Wills Eye Hospital, Philadelphia, <sup>5</sup>Quest Diagnostics, Horsham, PA, USA, <sup>2</sup>Department of Pediatric Ophthalmology and Asian Eye Institute, Makati, Philippines, <sup>3</sup>Department of Ophthalmology, Sultan Qaboos University Hospital, Muscat, Oman, <sup>6</sup>Department of Pediatric Ophthalmology and Ocular Genetics, CMER (Shenzhen) Dennis Lam Eye Hospital, Shenzhen, China

Organophosphates have rarely been reported to cause various ocular sequelae including retinal degeneration. Retinal manifestations have been rarely reported and poorly characterized. We describe a case of a 76-year-old man with vision loss beginning in his 20s due to acute on chronic exposure to dimethoate, an organophosphate. He

presented with bilateral geographic macular atrophy and midperipheral pigmentary clumping which we characterized by dilated fundoscopic examination, optical coherence tomography, and fundus autofluorescence.

**Keywords:** Organophosphate, pesticide, retinopathy

## Introduction

Organophosphates are a commonly used class of pesticides worldwide. All organophosphate pesticides share a common mechanism of action: Competitive inhibition of acetylcholinesterase (AChE) de-acetylation of the neurotransmitter acetylcholine. Human exposure causes acute and subacute toxicity in many organ systems including the eyes. In the 1960–1970s, residents and workers of the agricultural Saku Region of Japan, who were exposed to high levels of organophosphate pesticides experienced a high incidence of visual defects (Saku disease), including blurring of vision, myopia, astigmatism, eye movement disorders, pupillary dysfunction, retinal degeneration, optic disc edema, and optic nerve atrophy. In the United States, organophosphate usage has declined by 45% since 1980.<sup>[1]</sup> Reports of organophosphate's ocular toxicity in humans are otherwise infrequent.

### Correspondence:

Dr. Alex V. Levin, Department of Pediatric Ophthalmology and Ocular Genetics, Suite 1210, Wills Eye Hospital, 840 Walnut Street, Philadelphia, PA 19107-5109, USA.  
E-mail: [alevin@willseye.org](mailto:alevin@willseye.org)

## Case Report

A 76-year-old man was referred to our ocular genetics clinic with long-standing visual impairment and suspicion of retinal dystrophy. During childhood, he worked on an olive farm in Italy where spraying with Rogor® (dimethoate) was routinely performed. At 18 years old, he consumed large quantities of figs that had been sprayed with Rogor, after which he developed blisters on his arm and ear. One month later, he noticed difficulty in playing the piano due to reduced visual acuity. His central vision continued to deteriorate.

Although his parents are reported to be nonconsanguineous, both sides of his family come from Casavellino, Italy, with a population of approximately 2000. He had a sister who had poor vision in her 60s and died in her 80s. He has a nephew who was diagnosed with age-related macular degeneration in one eye in his 50s. The proband has four children and 10 grandchildren, who have no ocular symptoms.

This is an open access article distributed under the terms of the Creative Commons Attribution-NonCommercial-ShareAlike 3.0 License, which allows others to remix, tweak, and build upon the work non-commercially, as long as the author is credited and the new creations are licensed under the identical terms.

**For reprints contact:** [reprints@medknow.com](mailto:reprints@medknow.com)

**Cite this article as:** Pham H, Lingao MD, Ganesh A, Capasso JE, Keep R, Sadagopan KA, Levin AV. Organophosphate retinopathy. *Oman J Ophthalmol* 2016;9:49-51.

Access this article online	
<b>Quick Response Code:</b> 	<b>Website:</b> <a href="http://www.ojonline.org">www.ojonline.org</a>
	<b>DOI:</b> 10.4103/0974-620X.176101

Ocular examination showed best-corrected visual acuity of 20/630 right eye and counted fingers at three feet left eye. Refractive error was plano + 1.50 axis 90 right eye and - 1.00 sphere left eye. Pupils were round and reactive to light with no afferent or paradoxical pupillary defect. Anterior segment examination was normal except mild nuclear sclerosis right eye and pseudophakia left eye. Intraocular pressures were normal. Dilated examination showed optic nerve pallor, retinal arteriolar attenuation, and a large area of geographic macular atrophy with pigmentary clumping and atrophic patches extending into the peripapillary area [Figure 1]. There were midperipheral retinal pigmentary clumping and several subretinal deposits in both eyes. In the areas of geographic loss, the underlying choroid was still present but somewhat sclerosed.

Fundus autofluorescence imaging shows geographic patchy hypoautofluorescence [Figure 2]. Immediately adjacent to these areas, there is hyperfluorescence but no discrete lipofuscin deposits. Optical coherence tomography shows thickening of the anterior choroid, basement membrane, retinal pigmented epithelium (RPE) complex with some subretinal deposition, and bilateral macular thinning [Figure 3]. Intravenous fluorescein angiography shows a large area of macular atrophy as well as some peripheral mottling of the RPE [Figure 4]. There is no silent choroid or flecks.

Full-field electroretinography, performed according to the standards of the International Society for Clinical Electrophysiology and Vision, revealed isoelectric responses to all stimuli in both eyes, except the combined flash which elicited a delayed (right eye only) and very diminished a-wave and a diminished b-wave with normal implicit time in both eyes.<sup>[2]</sup> Multifocal electroretinogram and visual fields could not be conducted.

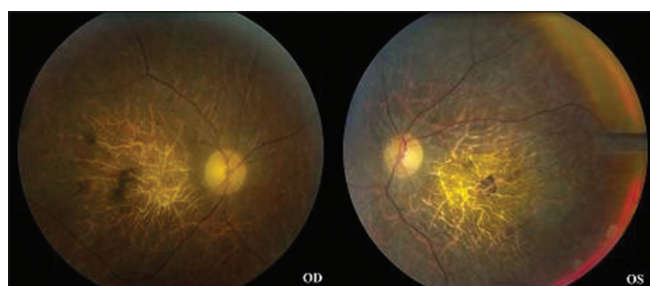
Audiometry showed loss of sensitivity to high frequencies with fair word recognition bilaterally indicating mild to moderate sensorineural hearing loss. These findings are consistent with presbycusis [Figure 5]. Vestibular testing could not be conducted.

An autosomal recessive retinitis pigmentosa targeted mutation panel (Asper Biotech, Tartu, Estonia) revealed one previously reported heterozygous mutation in *USH2A* (c. 1663C > G).<sup>[3,4]</sup> Full sequencing of the *USH2A* gene was performed (Casey Eye Institute Molecular Diagnostic Laboratory, Portland, Oregon, USA) which identified one novel variant (c. 10189A > G) that is predicted to be benign (score of 0.001 by Polymorphism Phenotyping v2). The family was not interested in pursuing segregation analysis.

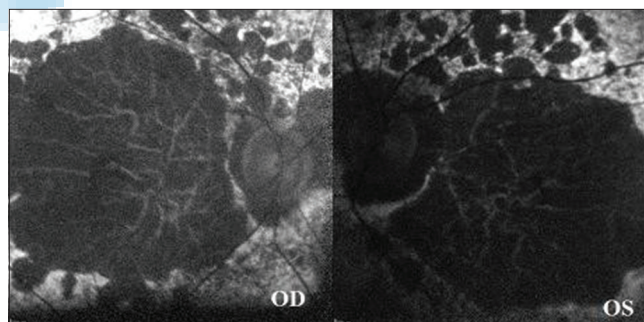
## Discussion

Retinopathy has been previously suggested to be associated with organophosphate exposure. Kirrane *et al.* found an elevated risk (odds ratio = 1.9, 95% confidence interval = 1.2–3.1) of retinal degeneration in wives of farmers who were pesticide applicators.<sup>[5]</sup> Inhibition of AchE resulting in lower levels of acetylcholine may interfere with retinal neurotransmission.<sup>[6]</sup> Alternatively, organophosphates may generate free radicals leading to oxidative stress in retinal neurons.<sup>[7]</sup>

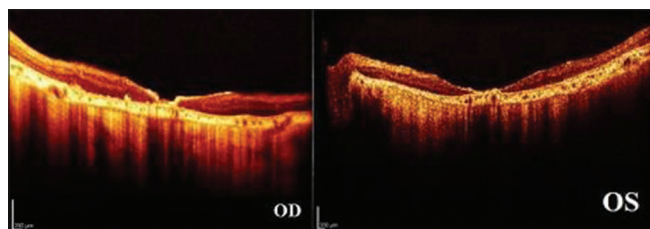
Our patient experienced bilateral retinal degeneration characterized primarily by a geographic maculopathy, which we believe is due to chronic and acute exposure to dimethoate. There is only one published paper, to our knowledge, describing the appearance of organophosphate retinopathy. Fundus examination in 79 workers, who had been engaged in fenthion spraying for at least 1 year, showed



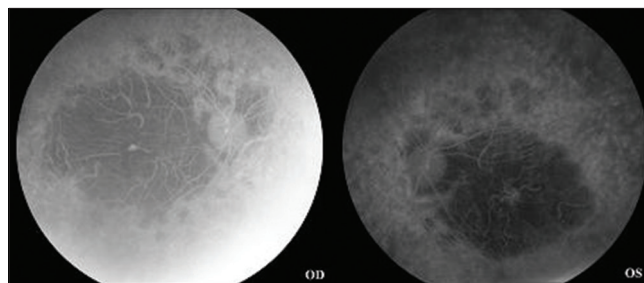
**Figure 1:** Fundus photography shows optic nerve pallor, retinal blood vessel attenuation, and macular geographic atrophy extending to the peripapillary region with pigmentary clumping



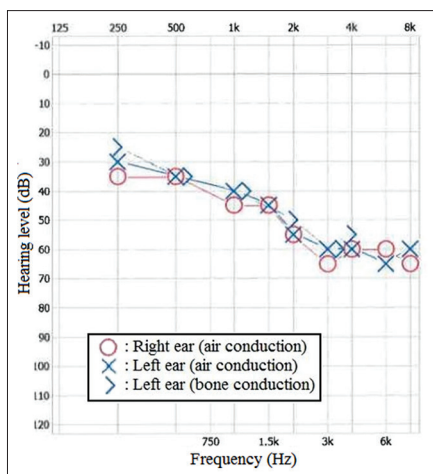
**Figure 2:** Fundus autofluorescence shows geographic and patchy hypoautofluorescence also involving the peripapillary area



**Figure 3:** Optical coherence tomography shows bilateral macular thinning and disruption of the photoreceptor-retinal pigmented epithelium complex with subretinal deposition



**Figure 4:** Intravenous fluorescein angiography shows a large area of macular atrophy and peripheral mottling of the retinal pigmented epithelium in both eyes



**Figure 5:** Audiogram demonstrates a downward slope indicating loss of sensitivity at high frequencies associated with presbycusis

macular changes in 15 (19%), which included perifoveal pigmentation irregularity and areas of hypopigmentation measuring 1/8–1/3 disc diameter. Fluorescein angiography was done in three patients with macular changes and revealed an area of hyperfluorescence suggesting pigment epithelium defect.<sup>[8]</sup> Our patient's macular atrophy is more geographic and extensive. He also had pigmentary changes in the periphery not described by Misra *et al.*

We also considered the possibility that our patient had a retinal dystrophy unrelated to organophosphate exposure. A panel of 19 genes revealed only one heterozygous mutation in *USH2A* (c. 1663C > G) that is associated with Usher syndrome type II. Previous reports have identified compound heterozygous *USH2A* mutations that are associated with Usher syndrome type II. In these studies, the affected members display hearing impairment and signs of retinitis pigmentosa including bone-spicule hyperpigmentation, attenuated retinal vessels, and optic nerve pallor.<sup>[9]</sup> Our patient's retinal phenotype and audiology pattern are not consistent with this form of Usher syndrome. When heterozygous, the c. 1663C > G mutation found in our patient has not, to our knowledge, been reported to cause Usher syndrome; although compound heterozygous mutation of c. 1663C > G has been associated with nonsyndromic retinitis pigmentosa.<sup>[10]</sup> Perhaps, the presence of the c. 1663C > G mutation makes our patient's retina more susceptible to organophosphate toxicity.

Organophosphate exposure may lead to significant visual impairment resulting in decreased quality of life. Our case illustrates the importance of exploring a history of organophosphate exposure in the differential diagnosis of what might otherwise be considered a retinal dystrophy.

### Financial support and sponsorship

Nil.

### Conflicts of interest

There are no conflicts of interest.

### References

1. Kiely T, Donaldson D, Grube A. Pesticide Industry Sales and Usage – 2000 and 2001 Market Estimates. Washington (DC): U.S. EPA; 2004. Available from: [http://www.epa.gov/opp00001/pestsales/01pestsales/market\\_estimates2001.pdf](http://www.epa.gov/opp00001/pestsales/01pestsales/market_estimates2001.pdf). [Last accessed on 2014 Oct 05].
2. Marmor MF, Fulton AB, Holder GE, Miyake Y, Brigell M, Bach M; International Society for Clinical Electrophysiology of Vision. ISCEV standard for full-field clinical electroretinography (2008 update). *Doc Ophthalmol* 2009;118:69-77.
3. Leroy BP, Aragon-Martin JA, Weston MD, Bessant DA, Willis C, Webster AR, *et al.* Spectrum of mutations in *USH2A* in British patients with Usher syndrome type II. *Exp Eye Res* 2001;72:503-9.
4. Garcia-Garcia G, Aparisi MJ, Jaijo T, Rodrigo R, Leon AM, Avila-Fernandez A, *et al.* Mutational screening of the *USH2A* gene in Spanish USH patients reveals 23 novel pathogenic mutations. *Orphanet J Rare Dis* 2011;6:65.
5. Kirrane EF, Hoppin JA, Kamel F, Umbach DM, Boyes WK, Deroos AJ, *et al.* Retinal degeneration and other eye disorders in wives of farmer pesticide applicators enrolled in the agricultural health study. *Am J Epidemiol* 2005;161:1020-9.
6. Hutchins JB, Hollyfield JG. Acetylcholine receptors in the human retina. *Invest Ophthalmol Vis Sci* 1985;26:1550-7.
7. Yu F, Wang Z, Ju B, Wang Y, Wang J, Bai D. Apoptotic effect of organophosphorus insecticide chlorpyrifos on mouse retina *in vivo* via oxidative stress and protection of combination of Vitamins C and E. *Exp Toxicol Pathol* 2008;59:415-23.
8. Misra UK, Nag D, Misra NK, Mehra MK, Ray PK. Some observations on the macula of pesticide workers. *Hum Toxicol* 1985;4:135-45.
9. Huang XF, Xiang P, Chen J, Xing DJ, Huang N, Min Q, *et al.* Targeted exome sequencing identified novel *USH2A* mutations in Usher syndrome families. *PLoS One* 2013;8:e63832.
10. Bernal S, Ayuso C, Antifio G, Gimenez A, Borrego S, Trujillo MJ, *et al.* Mutations in *USH2A* in Spanish patients with autosomal recessive retinitis pigmentosa: High prevalence and phenotypic variation. *J Med Genet* 2003;40:e8.