

1-1-2022

Isolated Splenic Infarction: An Initial Manifestation of Postoperative Atrial Fibrillation.

Chaitra Janga

Kimberley Okoyeze


Vincent Chan

Follow this and additional works at: <https://jdc.jefferson.edu/internalfp>

[Let us know how access to this document benefits you](#)

This Article is brought to you for free and open access by the Jefferson Digital Commons. The Jefferson Digital Commons is a service of Thomas Jefferson University's [Center for Teaching and Learning \(CTL\)](#). The Commons is a showcase for Jefferson books and journals, peer-reviewed scholarly publications, unique historical collections from the University archives, and teaching tools. The Jefferson Digital Commons allows researchers and interested readers anywhere in the world to learn about and keep up to date with Jefferson scholarship. This article has been accepted for inclusion in Division of Internal Medicine Faculty Papers & Presentations by an authorized administrator of the Jefferson Digital Commons. For more information, please contact: JeffersonDigitalCommons@jefferson.edu.

Isolated Splenic Infarction: An Initial Manifestation of Postoperative Atrial Fibrillation

Journal of Investigative Medicine High Impact Case Reports
Volume 10: 1–4
© 2022 American Federation for Medical Research
DOI: 10.1177/23247096221103384
journals.sagepub.com/home/hic


Chaitra Janga, MD¹, Kimberley Okoyeze, MD¹,
and Vincent Chan, MD²

Abstract

Splenic infarction is an uncommon cause of abdominal pain. In this article, we present a case of isolated splenic infarction presenting with severe abdominal pain, nausea, and with associated generalized weakness. Computed tomography (CT) abdomen and pelvis with contrast revealed multiple splenic infarctions of the entire lower pole with occlusion of the branch splenic arteries, while CT abdomen without contrast was unremarkable. Etiology was later revealed to be thromboembolism secondary to atrial fibrillation. It was managed with anticoagulation. To our knowledge, this is the second case of splenic infarction presenting as an initial manifestation of atrial fibrillation (AF), reported in the literature.

Keywords

hematology oncology, splenic infarction, atrial fibrillation, anticoagulation

Background

Splenic infarction (SI) is a rare condition that occurs due to reduced blood supply to the organ, leading to tissue ischemia and eventual necrosis. Despite being an uncommon phenomenon, the clinical burden on the patient population is significant with a mortality rate of 11% to 20%.^{1,2} The etiology of SI could be multifactorial; moreover, recent studies have shown an increase in newly diagnosed disease in patients being admitted with SI as the initial presentation.³ Splenic infarcts have been associated with many conditions and have been reported as postoperative complications, in association with thrombophilic syndromes, inflammatory bowel disease, myeloproliferative disorders, phospholipid syndrome, cardiac arrhythmia such as atrial fibrillation, and arteriosclerotic arterial disease.^{1,3-5} In this article, we discuss a case of isolated SI as an initial manifestation of atrial fibrillation (AF) in a postoperative patient.

Case Report

A 68-year-old female with a past medical history of colonic Crohn's disease with sigmoid strictures (previously on ustekinumab, status post colectomy with Hartman's pouch ileostomy, 3 weeks prior to presentation), hypertension, and hypothyroidism, presented to the emergency Department (ED) for persistent nausea, abdominal pain, high ostomy output, and generalized weakness.

Abdominal pain, in the mid-epigastric region, started 2 to 3 days after the procedure (colectomy with ileostomy) and was persistent with progressive worsening. She also reported decreased oral intake and reduced urine output. She had no changes to her medication, no new diet, activities, travel, recent injuries/trauma, or sick contacts. Patient was a former smoker, occasional drinker with 1 to 2 drinks per week, and denied drug use.

On physical exam, the patient was in mild distress. Vital signs showed blood pressure at 106/48, heart rate 86 bpm, afebrile at 36.8 C, respiratory rate 18 and oxygen saturation 99% on room air. Patient had regular heart rate and rhythm; no murmurs were auscultated; lungs were clear to auscultation bilaterally, no rales, wheezing or rhonchi were heard; abdominal examination was positive for generalized abdominal tenderness, without any palpable masses, guarding, rigidity, or rebound tenderness. The ostomy was patent, pink with an ileostomy bag filled with fluid and gas.

¹Department of Internal Medicine, Jefferson Health—Abington, PA, USA

²Department of Pulmonary and Critical Care, Thomas Jefferson University, Philadelphia, PA, USA

Received March 19, 2022. Revised April 24, 2022. Accepted May 8, 2022.

Corresponding Author:

Chaitra Janga, MD, Department of Internal Medicine, Jefferson Health—Abington, 1200 Old York Road, Abington, PA 19001-3720, USA.
Email: Chaitra.janga94@gmail.com



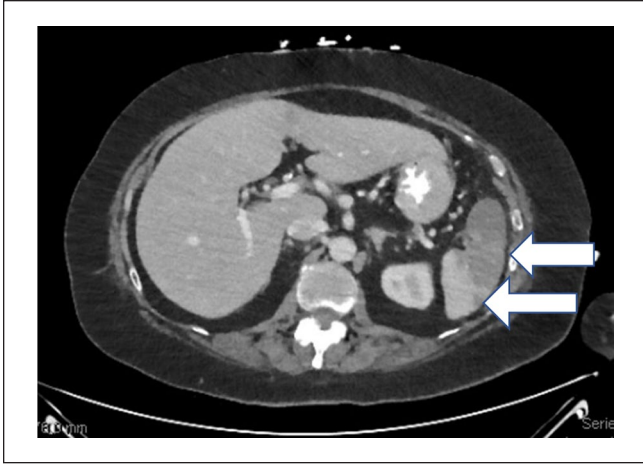

Figure 1. Axial contrast abdominal computed tomography demonstrating multiple areas of splenic infarction.

Her laboratory tests were significant for severely elevated creatinine of 9.56 (baseline Cr 0.56), hyponatremia with a sodium of 124 and metabolic acidosis with bicarbonate level of 9 (high anion gap and non-anion gap metabolic acidosis). Complete blood count was significant for thrombocytosis with a platelet count of 493. Venous blood gas showed a pH of 7.13, pCO₂ of 37, pO₂ of 43, bicarbonate of 12. Electrocardiography was normal, with regular rate and rhythm.

Initially, the abdominal pain was suspected secondary to post-surgical complication, and computed tomography (CT) abdomen pelvis without contrast was performed. This imaging was normal except for herniation of the mesenteric fat of the abdominal wall at the ileostomy site, and multiple gallstones without any evidence of gallbladder wall thickening or pericholecystic fluid. Despite starting the patient on pain medications, the abdominal discomfort persisted with gradual worsening, associated with an episode of vomiting. Therefore, imaging of abdomen was repeated with CT with contrast, which showed multiple splenic infarctions of the entire lower pole with occlusion of the branch splenic arteries (Figures 1 and 2). As the patient was hemodynamically stable, no surgical intervention was recommended. As cardio-embolic source is the major source of S I,¹⁻⁴ alone or associated with other conditions, we empirically started the patient on enoxaparin while she was being worked up. The patient's elevated creatinine was pre-renal in etiology (secondary to decreased intake and high ileostomy output). With repletion of intravenous fluids and avoiding nephrotoxins, acute kidney injury was resolved.

On further interaction, our patient did not have any previous history of cardiac disorders, arterial or venous thrombosis, hematologic disorders, and thrombotic disorders. She was never on any anti-coagulants in the past. The different etiologies to be considered include: thrombophilic syndromes, hematologic disorders, inflammatory bowel disease,

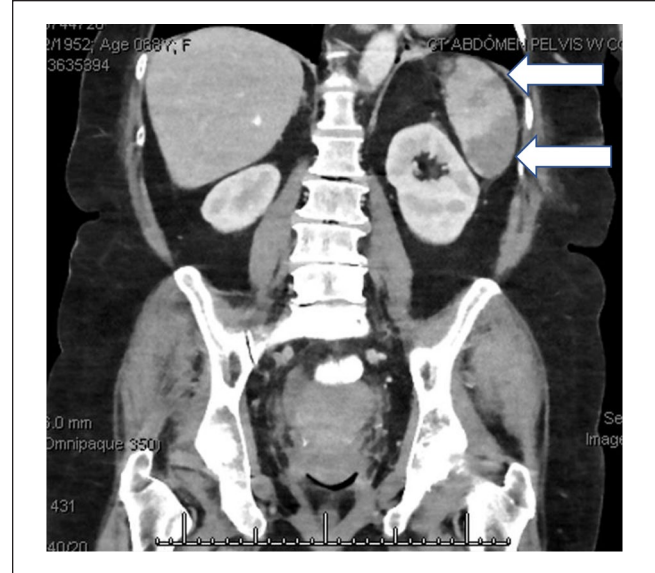


Figure 2. Coronal contrast abdominal computed tomography demonstrating multiple areas of splenic infarction.

myeloproliferative disorders, phospholipid syndrome, cardiac arrhythmia such as atrial fibrillation and arteriosclerotic arterial disease.

As recent studies have focused on the multi-factorial etiology for SI, we performed further diagnostic workup. Phospholipid antibodies and JAK2 mutation testing were negative. Echocardiogram revealed normal left ventricular ejection fraction (LVEF), without any evidence of vegetation or PFO. On telemetry, the patient had an episode of atrial fibrillation with subsequent reversion back to sinus rhythm in a day. The patient was, however, asymptomatic. Paroxysmal atrial fibrillation was determined to be the culprit of her splenic infarct, and the patient was discharged on apixaban and metoprolol. In addition, her CHA₂DS₂-VASc score was 3 (age 65-74 years, female, and hypertension history), necessitating the continuation of anticoagulation. At outpatient follow-up visit, the abdominal pain had subsided.

Discussion

Splenic infarction is a rare cause of abdominal pain. The incidence of SI is unclear as there is not much data surrounding it. It accounted for about 0.016% of admissions in an academic center over a period of 10 years.⁴ The common clinical presentation is pain in the LUQ and/or mid epigastrium. In about 10-33% of cases, no abdominal pain was reported in patients with SI.¹⁻⁴ Being an uncommon event with a variable clinical presentation, SI is under-diagnosed.⁴

Other clinical symptoms in patients with SI include fever, nausea, vomiting, flank pain, chest pain, and dyspnea.^{1,4} Lab findings that are seen in SI include WBC >12,000 and

elevated LDH.^{3,6} CT abdomen with contrast is the imaging modality of choice in identifying SI.⁷ Once the diagnosis of SI is established, investigating the underlying etiology is important as it helps in managing the patient and establishing the prognosis.² Moreover, SI could be the initial presentation in patients with underlying medical conditions, which would be diagnosed later. In a study by Lawrence et al, 21 out of 26 patients had initial presentation with SI and were subsequently diagnosed with medical conditions, like our case report.^{3,6,8}

The etiology underlying SI can potentially range from cardio-embolic to infectious causes, including vascular, hematological, and malignancy-related. Interestingly, more than one etiology could lead to SI: cardiac abnormalities including AF, mural thrombi of left ventricle, severe LV dysfunction and mitral valve disease (14.5%), endocarditis (12.2%), vascular disease (11.1%), others include JAK 2 mutations, APLAS, and solid tumors.^{1,3-5,9}

In our patient, postoperative splenic injury could be one of the reasons for SI, as evident from the previous literature.¹⁰ Additionally, AF is one of the other proposed mechanisms leading to SI, as the imaging in our patient showed multiple splenic infarcts along with evidence of paroxysmal AF on telemetry. This emphasizes that etiology of SI can be multifactorial, thus, it is important to look for other causes of SI, even in patients with an established etiology.¹⁴

Although the previous literature has shown high suspicion for AF in patients presenting with infarctions in multiple organs (splenic infarction, renal infarction, or mesenteric ischemia), our patient diagnosed with AF had isolated SI.¹¹ Hence, it is recommended to perform EKG, echocardiography, telemetry in all patients with SI to identify occult atrial fibrillation, endocarditis, or aortic disease as the source of emboli. Additionally, phospholipid antibodies and JAK2 mutation can also be considered as a part of thrombophilia workup.³ However, JAK2 mutations are reported in only about 50% to 55% of the cases of essential thrombocythemia. Therefore, further testing for MPL and CALR mutations is useful in ruling out myeloproliferative neoplasms in cases of negative JAK2 mutation.^{12,13}

Treatment primarily depends on the underlying cause when identified. Acute management includes pain control with analgesics, hydration, anti-emetics, and other supportive care. The role of anticoagulation in managing these patients is not clear and can be influenced by the underlying etiology. Starting the patients on anticoagulation is preferred if the cause for SI is cardioembolic, hypercoagulable, or malignancy related. In a recent study, anticoagulation has also improved long-term mortality in patients with SI.^{14,15} Surgery, which may include splenectomy, is considered as a last resort in management of SI, limited to cases with splenic abscess, splenic rupture, or hemodynamic instability.^{14,16} Ultrasound can be utilized to assess the resolution of SI, as well as to monitor complications secondary to SI.¹⁷

Conclusion

Our case highlights the importance of heightened suspicion for SI in patients presenting to the ED with vague abdominal complaints. Relevant work-up should be performed in cases with unknown, as well as known etiology, which could subsequently lead to establishing new or concomitant diagnoses. Acute splenic infarction can be the initial and only presentation of AF and should be considered even in the presence of a normal EKG on presentation.

Declaration of Conflicting Interests

The author(s) declared no potential conflicts of interest with respect to the research, authorship, and/or publication of this article.

Funding

The author(s) received no financial support for the research, authorship, and/or publication of this article.

Ethics Approval

Our institution does not require approval for reporting individual case reports.

Informed Consent

Verbal informed consent was obtained from the patient(S) for their anonymized information to be published in this article.

References

1. Brett AS, Azizzadeh N, Miller EM, Collins RJ, Seegars MB, Marcus MA. Assessment of clinical conditions associated with splenic infarction in adult patients. *JAMA Intern Med.* 2020;180:1125-1128. doi:10.1001/jamainternmed.2020.2168.
2. Yen CC, Wang CK, Chen SY, et al. Risk assessment and prognostic analysis of patients with splenic infarction in emergency department: a multicenter retrospective study. *Sci Rep.* 2021;11:21423. doi:10.1038/s41598-021-00897-0.
3. Wand O, Tayer-Shifman OE, Khoury S, Hershko AY. A practical approach to infarction of the spleen as a rare manifestation of multiple common diseases. *Ann Med.* 2018;50:494-500. doi:10.1080/07853890.2018.1492148.
4. Schattner A, Adi M, Kitroser E, Klepfish A. Acute splenic infarction at an academic general hospital over 10 years: presentation, etiology, and outcome. *Medicine (Baltimore).* 2015;94:e1363. doi:10.1097/md.0000000000001363.
5. Cox M, Li Z, Desai V, et al. Acute nontraumatic splenic infarctions at a tertiary-care center: causes and predisposing factors in 123 patients. *Emerg Radiol.* 2016;23:155-160. doi:10.1007/s10140-016-1376-3.
6. Lawrence YR, Pokroy R, Berlowitz D, Aharoni D, Hain D, Breuer GS. Splenic infarction: an update on William Osler's observations. *Isr Med Assoc J.* 2010;12:362-365.
7. Tonolini M, Bianco R. Nontraumatic splenic emergencies: cross-sectional imaging findings and triage. *Emerg Radiol.* 2013;20:323-332. doi:10.1007/s10140-013-1103-2.

8. Antopolsky M, Hiller N, Salameh S, Goldshtein B, Stalnikowicz R. Splenic infarction: 10 years of experience. *Am J Emerg Med.* 2009;27:262-265. doi:10.1016/j.ajem.2008.02.014.
9. Im JH, Chung M-H, Lee H-J, et al. Splenic infarction and infectious diseases in Korea. *BMC Infect Dis.* 2020;20:915. doi:10.1186/s12879-020-05645-9.
10. Gayer G, Galperin-Aizenberg M. Iatrogenic splenic injury in postoperative patients: a series of case reports. *Emerg Radiol.* 2008;15:109-113. doi:10.1007/s10140-007-0669-y.
11. Shen LL, Qi W, Duarte J, Nagar A, Merchant NB. Acute renal and splenic infarctions as the initial manifestations of atrial fibrillation. *Lancet.* 2019;393:1856. doi:10.1016/s0140-6736(19)30839-6.
12. Tefferi A, Barbui T. Polycythemia vera and essential thrombocythemia: 2021 update on diagnosis, risk-stratification and management. *Am J Hematol.* 2020;95:1599-1613. doi:10.1002/ajh.26008.
13. Xia D, Hasserjian RP. Molecular testing for JAK2, MPL, and CALR in myeloproliferative neoplasms. *Am J Hematol.* 2016;91:1277-1280. doi:10.1002/ajh.24578.
14. Chapman J, Helm TA, Kahwaji CI. Splenic infarcts. In: *StatPearls.* Treasure Island, FL: StatPearls Publishing; 2022.
15. Yen CC, Wang CK, Chaou CH, Chen SY, Lin JP, Ng CJ. Anticoagulant therapy is associated with decreased long-term mortality in splenic infarction patients: a multicenter study. *Front Med (Lausanne).* 2021;8:778198. doi:10.3389/fmed.2021.778198.
16. Pothula V, Saegusa E, Takekoshi D, Edson T, Ignacio R. Splenic syndrome: a rare indication for splenectomy. *Mil Med.* 2008;173:1233-1237. doi:10.7205/milmed.173.12.1233.
17. Goerg C, Schwerck WB. Splenic infarction: sonographic patterns, diagnosis, follow-up, and complications. *Radiology.* 1990;174:803-807. doi:10.1148/radiology.174.3.2406785.