

MoyaMoya Disease and Acute Inpatient Rehabilitation in a 17-month old Previously Healthy Male

Cassandra Coleman; Nicole Marcantuono, MD

Jefferson Department of Pediatric Physical Medicine and Rehabilitation

Case Diagnosis

17-month old male with newly diagnosed MoyaMoya after presenting with new onset seizures and right-sided weakness.

Case Description

MoyaMoya is a rare cerebrovascular condition predisposing patients to stroke in association with progressive stenosis of the intracranial internal carotid arteries and their proximal branches.

The patient presented initially after a fall with subsequent inability to bear weight on his right leg along with minimized use of his right arm. Patient was treated for a suspected tibial Salter-Harris II and nursemaid's elbow. He presented four days later to the ED with new onset seizures. CT of the brain showed loss of left frontal gray-white matter. MRI showed bilateral MoyaMoya and a saccular aneurysm at the left internal carotid bifurcation. Patient underwent bilateral encephaloarterial synangiosis procedure. Four days post-op, new left-sided deficits were noted and stat MRI showed new acute infarcts. Once medically stable, patient was transferred to acute inpatient rehabilitation.

MoyaMoya is associated with approximately 6% of childhood strokes. Females are affected twice as often as males and more common in those of Asian or African American descent. The highest rate of diagnosis is in the first decade (average age 5 years). Inherited gene defect associated with sickle cell disease, Down Syndrome, or a history of surgery for congenital heart disease. However, environmental factors precipitate clinical emergence in susceptible patients.

MoyaMoya is a progressive disease due to increased narrowing of arteries. Without surgery, 50-60% of individuals will experience gradual deterioration of cognitive function from recurring strokes. MoyaMoya should be suspected in any patient, particularly children, presenting with a stroke of unclear etiology. The standard diagnosis of MoyaMoya is cerebral angiography (Figure 1).

Discussion

This is the first presented case report on rehabilitation of MoyaMoya in patients under the age of two. Typically, stroke is the initial presentation of MoyaMoya and small strokes may be missed in patients who are preverbal, as was the case of our patient. Upon admission to inpatient rehabilitation, the patient's deficits included developmental regression of communication/language skills, oral stage dysphagia, weakness, and mobility deficits. After a 2.5 week stay with three hours of therapy per day, patient had demonstrated good progress with improvements in dysphagia, weakness, and mobility. He should improved strength in legs and was able to squat and ambulate independently with use of a gait belt for safety.

Treatment of choice is a bilateral pial synangiosis. Retrospective studies indicate 94.7% of patients had improved or stable neurologic status at follow-up compared to prior to surgery. More than 2/3 of pediatric patients are now leading normal, active adult lives with no noticeable neurological problems.

If neurologic impairment has resulted from stroke, rehabilitation with physical therapy, occupational therapy, and speech therapy should be used and can range from outpatient to full, comprehensive inpatient rehabilitation.

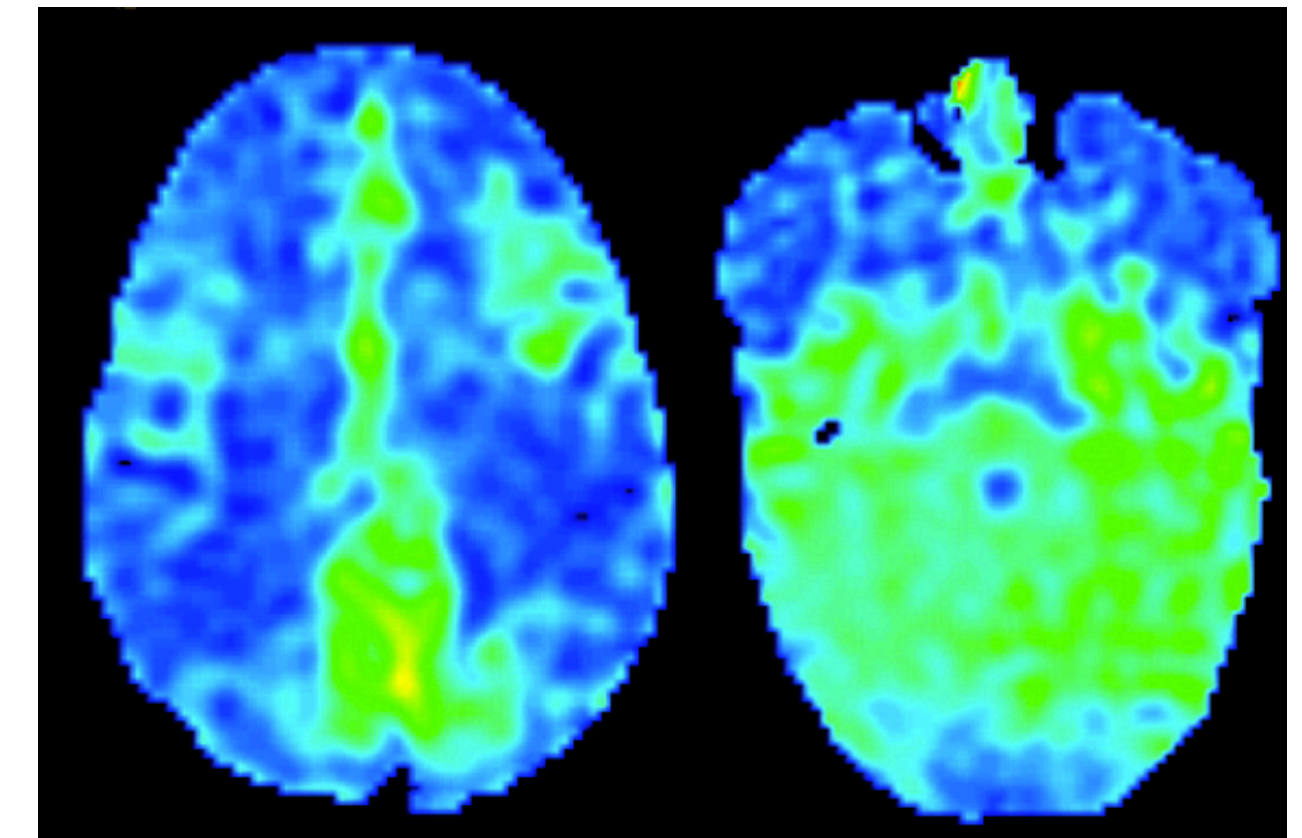


Figure 2. AAsl fMRI imaging of an 18-month-old boy with newly diagnosed MoyaMoya showing hypoperfusion bilaterally of the central regions of the cerebral hemispheres (shown in blue). For comparison, the cerebellum, in the right image, is a normal green hue.

Conclusion

Acute inpatient rehabilitation is both well-tolerated and effective for treating impairments in MoyaMoya patients less than two years of age.

Delay in diagnosis and revascularization surgery in patients with MoyaMoya could lead to a worse prognosis for the patient. Physicians practicing in the community who are unfamiliar with MoyaMoya should not hesitate to seek consultation with a stroke specialist.

References

- Nagaraja D, Verma A, Taly AB, et al. Cerebrovascular disease in children. *Acta Neurol Scand* 1994; 90(5): 251-5.
- Baba T, Houkin K, Kuroda S. Novel epidemiological features of MoyaMoya disease. *J Neurol Neurosurg Psychiatry*. 2007; 79(8): 900-4.
- Uchino K, Johnston SC, Becker KJ, et al. Moyamoya disease in Washington State and California. *Neurology*. 2005; 65(6): 956-8.
- Smith, E., & Scott, R. (n.d.). Moyamoya: Epidemiology, Presentation, And Diagnosis. *Neurosurgery Clinics of North America*, 543-551. Retrieved September 14, 2014, from http://www.mc.vanderbilt.edu/documents/singerlab/files/Moyamoya_Epidemiology_Presentation_and_Diagnosis.pdf
- Smith, E. (2011, January 1). Moyamoya Disease - Symptoms, Diagnosis and Treatment. Retrieved September 14, 2014, from <http://www.childrenshospital.org/health-topics/conditions/moyamoya-disease>

Table 1 Symptoms at presentation in 143 patients		
	Number of Patients With Symptom	% of Patients With Symptom
Stroke	97	67.8
TIA's (including drop attacks)	62	43.4
Seizures	9	6.3
Headache	9	6.3
Choreiform movements	6	4.2
Incidental	6	4.2
Intraventricular or intracerebral bleed	4	2.8

Table 1. Patients with MoyaMoya present with signs and symptoms of ischemic injury.

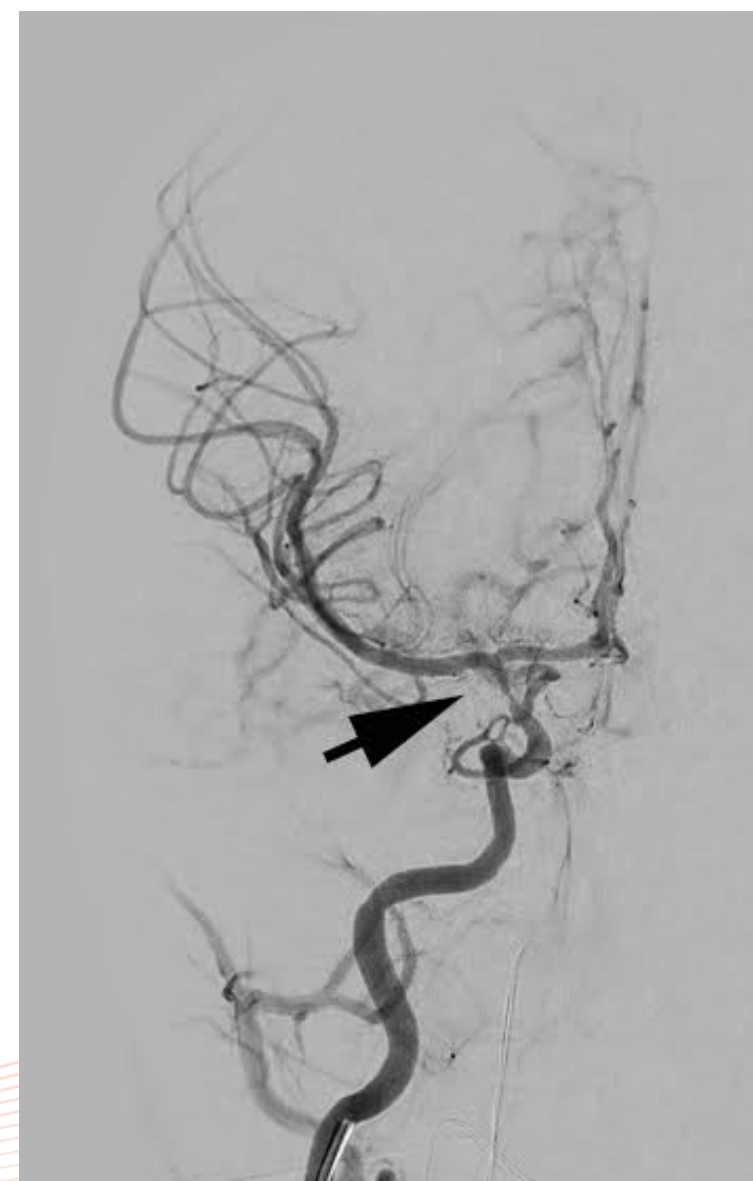

Figure 1. Angiogram showing the stenosis of the right internal artery (arrow) in 18-month old boy with a new diagnosis of MoyaMoya disease.