

2013

# Genodermatoses: Differential diagnosis of cutaneous elastin disorders: Cutis Laxa vs. pseudoxanthoma elasticum

Jouni Uitto

*Department of Dermatology and Cutaneous Biology, Jefferson Medical College, jouni.uitto@jefferson.edu*

## Let us know how access to this document benefits you

Follow this and additional works at: <https://jdc.jefferson.edu/dcbfp> Part of the [Dermatology Commons](#)

### Recommended Citation

Uitto, Jouni, "Genodermatoses: Differential diagnosis of cutaneous elastin disorders: Cutis Laxa vs. pseudoxanthoma elasticum" (2013). *Department of Dermatology and Cutaneous Biology Faculty Papers*. Paper 33.

<https://jdc.jefferson.edu/dcbfp/33>

This Article is brought to you for free and open access by the Jefferson Digital Commons. The Jefferson Digital Commons is a service of Thomas Jefferson University's [Center for Teaching and Learning \(CTL\)](#). The Commons is a showcase for Jefferson books and journals, peer-reviewed scholarly publications, unique historical collections from the University archives, and teaching tools. The Jefferson Digital Commons allows researchers and interested readers anywhere in the world to learn about and keep up to date with Jefferson scholarship. This article has been accepted for inclusion in Department of Dermatology and Cutaneous Biology Faculty Papers by an authorized administrator of the Jefferson Digital Commons. For more information, please contact: [JeffersonDigitalCommons@jefferson.edu](mailto:JeffersonDigitalCommons@jefferson.edu).

## Photodermatology

### Photodermatology Session Topics

*Dr Amra Osmancevic, Gothenburg, Sweden: An Update on Vitamin D.* A general review of the accumulating knowledge of vitamin D was given. Vitamin D insufficiency is common especially at higher latitudes. However, there is no consensus on the optimal level of serum calcidiol (25-hydroxyvitamin D) which is the best indicator of vitamin D status. Individual variation in vitamin D concentrations may be genetic in origin. A non-linear response between vitamin D intake and calcidiol concentration has also been observed. Calcidiol screening should be focused on subjects at high risk of vitamin D insufficiency, such as persons > 70 years of age, people with limited sun exposure, dark skin, fat malabsorption, and obesity. Solar UVB is the major source of vitamin D for most people, but photoprotection is necessary to prevent photodamage and skin cancer. About 30 min solar exposure at noon suffices for optimal vitamin D status.

*Photobiologist Riikka Pastila, Helsinki, Finland: Sunbeds: What's in There?* Riikka Pastila clarified the drawbacks of cosmetic sunbed UVA exposures which provide a tan, but offer minimal protection from subsequent UV exposures. The International Agency for Research on Cancer has classified artificial UV tanning devices as carcinogenic to humans on the basis of meta-analysis showing a 75% increased risk of melanoma when the first indoor tanning exposure occurred under the age of 35 years. Adolescence and early adulthood seem to be the most sensitive periods for UV drawbacks. Interestingly, frequent tanning behaviour exhibits signs of psychological and physiological dependence. The suggested mediator is beta-endorphin, cleaved together with melanocyte stimulating hormone from pro-opiomelanocortin, in keratinocytes. Many countries have forbidden, or aim to forbid, the sunbed use from the minors.

*Dr Tapio Rantanen, Tampere, Finland: Update on Skin Photoprotection.* Tapio Rantanen focused on photoprotection and for motivation, he showed figures of increasing incidence rates of melanoma from the Nordic Cancer Registries. Sunburn avoidance and photoprotection are the only ways of primary prevention. Rantanen recommended to observe the UV Index, limit time in the midday sun, wear protective clothing and sunglasses, use sunscreens liberally, re-apply every 2<sup>nd</sup> h, and keep babies out of the sun. A total of 27 filters are available in EU, but not all are widely used. New filters are assessed for chemical and physical properties, function, mode of action, toxicology, human data, and calculations for margin of safety. Safety concerns of sunscreens include radical formation, contact allergies, stability, systemic absorption, hormone-like activity, vitamin D aspects, environmental worries, and nanotechnology. The take-home messages were: Photoprotection is reasonable. Most sunscreens are effective, but many filters



From left: Meri Ala-Houhala, Leena Koulu, Riikka Pastila, Amra Osmancevic, Erna Snellman, Katja Vähävihi.

are not yet properly assessed. Nano-sized TiO<sub>2</sub> and ZnO do not penetrate stratum corneum. Human mind is the problem, photosensitive subjects want a tan. Sun holidays are sunburn holidays. Sunscreens are misused. Further campaigns to prevent sunburn are urgently needed.

ERNA SNELLMAN<sup>1</sup> AND LEENA KOULU<sup>2</sup>

<sup>1</sup>Tampere University and Tampere University Hospital, Tampere and <sup>2</sup>Turku University and Turku University Hospital, Turku, Finland

E-mail: [erna.snellman@uta.fi](mailto:erna.snellman@uta.fi), [leena.koulu@tyks.fi](mailto:leena.koulu@tyks.fi)

## Genodermatoses

### Plenary Lecture by Jouni Utto: Personalized Medicine for Heritable Skin Diseases

One of the emerging concepts of contemporary medicine revolves around personalized or individualized medicine. What makes this concept particularly topical at this juncture is the fact that we have an unprecedented capability to analyze an individual's genome by next generation sequencing, either entire genome analysis or a subset of it through whole exome sequencing.

Epidermolysis bullosa (EB) is a group of heritable blistering diseases in which spectacular progress has been made over the past two decades in identifying the underlying molecular defects, and it is now known to be caused by mutations in 18 distinct genes. Detailed knowledge of the specific mutations has provided molecular confirmation of the diagnosis and allowed subclassification of EB with prognostic implications. Identification of mutations can also have profound conse-

quences for genetic counseling, particularly in families where there is no previous history of a blistering disease.

Furthermore, identification of mutations in the candidate genes has formed basis for prenatal testing in families at risk for recurrence, which can be performed by chorionic villus sampling as early as the 10<sup>th</sup> week gestation. Recent work has also focused on development of non-invasive prenatal testing through analysis of the fetal DNA in the mother's serum. Fetal free DNA is readily detectable in mother's blood by polymerase chain reaction as early as the 5<sup>th</sup> week gestation, i.e., just at the time when a woman may know that she is pregnant. Thus, non-invasive prenatal diagnosis can provide information of the fetal genotype to the parents and healthcare providers earlier than currently available. The identification of specific mutations in families with EB has also formed the basis for pre-implantation genetic diagnosis which is done even before the pregnancy starts in the context of in vitro fertilization. This approach has already been applied to a limited number of cases with severe forms of EB.

Finally, identification of specific mutations in the candidate genes in different forms of EB has led to development of novel molecular therapies of regenerative medicine, including gene therapy and protein replacement approaches. Finally, allogeneic bone marrow transplantation for recessive dystrophic EB has been demonstrated to alleviate blistering tendency in a subset of patients. While the early results have warranted cautious optimism, the long-term outcome of this process is not yet known. Also, allogeneic bone marrow transplantation carries a significant risk of complications and death, indicating that a careful analysis of the risk/benefit ratio is in order. Nevertheless, one could predict that treatment of single gene disorders, such as EB, will be available soon.



**JOUNI UITTO**  
 Department of Dermatology and  
 Cutaneous Biology, Jefferson Medical  
 College, 233 S. 10<sup>th</sup> Street, Ste. 450,  
 Philadelphia, PA, USA  
 E-mail: jouni.uitto@jefferson.edu

### Congenital Ichthyosis and Other Disorder of Cornification – An Update

The rarest and most severe forms of ichthyosis mostly belong to the autosomal recessive congenital ichthyoses (ARCI). This heterogeneous group of diseases can be subdivided into 4 groups based on clinical features and prognosis (see Fig. 1). The aetiology of ARCI comprises more than 20 genes, all involved in skin barrier formation. Most of the newborns with massive hyperkeratinization (Harlequin foetus and collodion babies) will subsequently develop lamellar ichthyosis (LI) or ichthyosiform erythroderma (CIE). But some babies will show almost complete healing within 1 month, a phenotypic shift entitled

*pleomorphic ichthyosis* (or non-LI/non-CIE). Included in the latter subgroup of ARCI are 3 genetically distinct conditions: (i) self-improving congenital ichthyosis due to *ALOX12B*/*ALOXE3* and *TGM1* mutations; (ii) ichthyosis prematurity syndrome due to *SLC27A4* mutations, and (iii) bathing-suit ichthyosis due to temperature sensitive *TGM1* mutations, explaining why lamellar ichthyosis appears only on skin areas exposed to high ambient temperature, such as in utero and under tight clothing in a hot climate. When diagnosing ichthyosis in children and adults it is important not to miss this subgroup of ARCI with mild skin symptoms, because both medical advice (e.g., concerning anhidrosis and heat-intolerance) and genetic counselling will differ compared to other forms of more common ichthyosis. The most effective therapy for ichthyosis remains retinoids together with emollients, but the side effects of retinoids are still a problem and new, potent alternative remedies are needed.

A few other disorders of cornification were also discussed, especially in the light of recent progress in our understanding of their pathogenesis. Acral peeling skin syndrome (APSS) typically starts at the age of 3–6 months with superficial blisters on the toes and fingers. The aetiology is a deficiency of *TGM5*, encoding a transglutaminase essential for the adherence of stratum corneum to stratum granulosum, especially when acral skin is exposed to heat and friction. This recessive and fairly common condition is genetically distinct from generalised peeling skin syndrome due to *CDSN* mutations. A rarer type of recessive disorder of cornification is Mal de Maleda due to *SLURP-1* mutations; our recent investigations have established that the Gamborg-Nielsen type of keratoderma, typically found in northern Sweden, is a mild variant of Mal de Maleda. The more common, dominant form of keratoderma, type Bothnia, on the other hand, is due to mutations in an aquaporin gene, *AQP5*, which encodes a water-channel protein. Exactly how this kind of mutation causes a massive

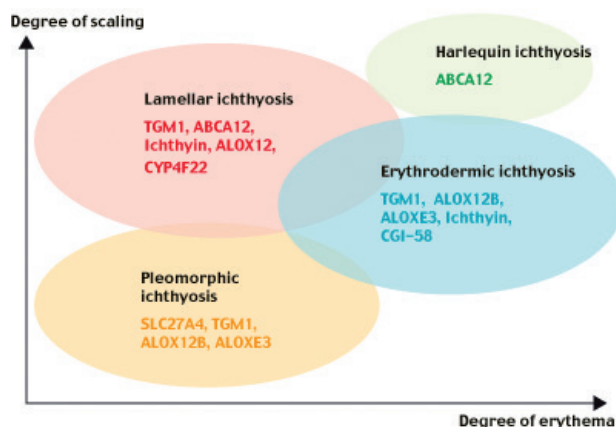


Fig. 1. Subgrouping of autosomal recessive ichthyosis based on the phenotypic appearance and genetic etiology. The area of the circles approximately reflect the relative prevalences of the subgroups. Adapted from A. Vahlquist, Acta Derm Venereol 2010.

thickening of the horny layer is still unknown. Hopefully, all this new knowledge will soon lead to new therapeutic ideas.



**ANDERS VAHLQUIST**  
*Department of Dermatology, University Hospital, SE-751 85 Uppsala, Sweden*  
*E-mail: anders.vahlquist@medsci.uu.se*

### What is New in Neurofibromatosis 1

Neurofibromatosis type 1 (NF1) is an autosomally dominantly inherited syndrome which has typical diagnostic findings on skin. Dermatologists can make the diagnosis based on café-au-lait macules, skinfold freckles and cutaneous neurofibroma tumours. In addition to being a dermatological disease, NF1 is a multiorgan syndrome with findings and symptoms from several organ systems. About 30% of the patients have a decreased bone mineral density or osteoporosis which leads to more than a 5-fold increased risk for bone fractures. Speech abnormalities and various craniofacial aberrations are also common, including the presence of mucosal neurofibromas in the mouth. Because of the multiorgan nature of the disease, NF1 patients require a multidisciplinary approach in healthcare.



**SIRKKU PELTONEN**  
*Department of Dermatology, Turku University Hospital, FI-20521 Turku, Finland*  
*E-mail: sipelto@utu.fi*

### Differential Diagnosis of Cutaneous Elastin Disorders: Cutis Laxa vs. Pseudoxanthoma Elasticum

Disorders of the elastic fibers with skin manifestations were reviewed. The prototype of such disorders is cutis laxa, a heterogeneous group of connective tissue disorders with the diagnostic hallmark of loose and sagging skin with loss of elasticity and recoil due to paucity of elastic fibers. The skin findings are often associated with extracutaneous manifestations, including pulmonary emphysema, inguinal and umbilical hernia, vascular abnormalities, and gastrointestinal and urinary track diverticula. The clinical heterogeneity of cutis laxa reflects the fact that mutations have been identified in a number of different genes, many of them involved in elastin fibrillogenesis, including those encoding elastin as well as fibulins 4 and 5.

Another elastin associated heritable disorder, pseudoxanthoma elasticum (PXE) manifests with yellowish papules coalescing into loose and inelastic skin, in association of characteristic ocular and vascular manifestations. The pathomechanisms of PXE include mineralization of elastic structures in the affected organs. PXE is caused by mutations in the *ABCC6* gene expressed primarily in the liver, suggesting that PXE is a metabolic disorder.

Recently, an interesting combination of clinical manifestations has been encountered consisting of loose and sagging skin suggestive of cutis laxa in association of PXE-like cutaneous findings. Instead of *ABCC6*, the mutant gene was shown to be *GGCX* which encodes an enzyme required for activation of matrix gla protein, an anti-mineralization factor. The distinction of cutis laxa vs. PXE in these patients can be made by histopathology of skin which demonstrates accumulation of pleomorphic elastic structures in mid dermis with profound mineralization, findings characteristic of PXE.

In summary, abnormalities in the elastic fibers can result in a spectrum of cutaneous manifestations, and accurate diagnosis by histopathologic examination is required in order to arrive at proper diagnosis and classification, with potential implications for treatment of these disorders.

**JOUNI UITTO**  
*Department of Dermatology and Cutaneous Biology, Jefferson Medical College, Philadelphia, PA, USA*  
*E-mail: jouni.uitto@jefferson.edu*

### Cowden's Syndrome (Multiple Hamartoma)

Cowden's syndrome (multiple hamartoma) is an autosomal dominant inherited disease due to mutations in *PTEN* located on chromosome 10q22-q23. The pathophysiology and symptoms of the disease were reviewed. A 64-year-old man was presented with multiple mucocutaneous facial papules (tricholemmomas), oral mucosal papillomatosis and acral and palmoplantar keratoses, together with thyroid adenoma, multiple intestinal polyposis and mental retardation. The skin tumours were removed by electro-surgery with partial success.



**BARBARA GASIOR-CHRZAN**  
*Department of Dermatology, University of Tromsø, NO-9012 Tromsø, Norway*  
*E-mail: barbara.gasior-chrzan@uit.no*