

5-1-2015

Frederic E. Mohs, M.D. (1910-2002): physician and innovator.

Nicholas A. Ross, B.A.
Thomas Jefferson University

Nazanin Saedi, MD
Laser Surgery and Cosmetic Dermatology Center

Charles J. Yeo, MD
Thomas Jefferson University

Scott W. Cowan, MD
Thomas Jefferson University

Follow this and additional works at: <https://jdc.jefferson.edu/gibbonsocietyprofiles>



Part of the [History of Science, Technology, and Medicine Commons](#), and the [Surgery Commons](#)

[Let us know how access to this document benefits you](#)

Recommended Citation

Ross, B.A., Nicholas A.; Saedi, MD, Nazanin; Yeo, MD, Charles J.; and Cowan, MD, Scott W., "Frederic E. Mohs, M.D. (1910-2002): physician and innovator." (2015). *Department of Surgery Gibbon Society Historical Profiles*. Paper 43.

<https://jdc.jefferson.edu/gibbonsocietyprofiles/43>

This Article is brought to you for free and open access by the Jefferson Digital Commons. The Jefferson Digital Commons is a service of Thomas Jefferson University's [Center for Teaching and Learning \(CTL\)](#). The Commons is a showcase for Jefferson books and journals, peer-reviewed scholarly publications, unique historical collections from the University archives, and teaching tools. The Jefferson Digital Commons allows researchers and interested readers anywhere in the world to learn about and keep up to date with Jefferson scholarship. This article has been accepted for inclusion in Department of Surgery Gibbon Society Historical Profiles by an authorized administrator of the Jefferson Digital Commons. For more information, please contact: JeffersonDigitalCommons@jefferson.edu.

Surgical History *Frederic E. Mohs, M.D. (1910—2002): Physician and Innovator*

NICHOLAS A. ROSS, B.A.,* NAZANIN SAEDI, M.D.,† CHARLES J. YEO, M.D.,‡ SCOTT COWAN, M.D.‡

From *Department of Dermatology & Cutaneous Biology; †Laser Surgery and Cosmetic Dermatology Center; and ‡Department of Surgery, Thomas Jefferson University, Philadelphia, Pennsylvania

Frederic “Fred” E. Mohs was an “honest and good man, a ferocious and courageous worker.”¹ Husband, father of three, prolific writer, and speaker, Dr. Mohs was a pioneer in many fields. His desire to do good was fueled by his enthusiasm for scientific advancement (Frederic E. Mohs Jr., personal communication, 2014). He is most remembered for Mohs Micrographic Surgery, formerly chemosurgery, which allows visualization and examination of all tissue margins achieving skin cancer cure rates of 98 to 99 per cent.^{2, 3}

Fred Mohs was born on March 1, 1910 in Burlington, Wisconsin. His father, Frederic Carl Mohs, was an accountant at a creamery in Milwaukee, Wisconsin. His mother, Grace Tilton, was a home-maker. They were a well-to-do family.¹ Fred had two siblings: Carl E. Mohs, his older brother, and Laura Ruth Mohs, his younger sister who unfortunately died from Spanish flu at a young age. In 1913, when Fred was three months old, his father died from tuberculosis. To support the family, Grace worked as a timekeeper at the local blanket factory. “Aunty,” a neighbor, cared for Fred during the day (Fig. 1). Daily, Fred was left home alone for the hours before supper because Aunty had to prepare food for her own family.⁴ He was a latchkey child. These lonely times likely impacted his character; yet, he was never the kind of person to feel sorry for himself.²

Around 1918, Grace moved the family to Madison, WI, so that Carl could attend college. Renting an apartment on Conklin Court near Lake Street, she used the rest of the money from the sale of their Burlington home to invest in a half-share of a boarding home.¹ The Great Depression, however, brought scarcity. Nevertheless, Grace was a hard worker, finding further employment as a practical nurse and waitress to supplement income from the boarding home. She also spent Sundays doing laundry for the boarders. The whole family worked hard. Fred earned money as a tender of boilers and delivery boy in the neighborhood.¹

Fred Mohs was a successful student and played on the Madison Central High School football team. Although a devoted team member, his true passion was radio. It was the biggest innovation to communication since the printing press and as revolutionary to its times as the Internet. Fred practiced with a “spark kit” because he did not have money for more advanced radio sets. With his friend Reginald Jackson, grandson to billionaire Reese Stevens, however, he built a radio operation in the loft of a barn. From there, Fred spent many nights raising short-wave responses from



FIG. 1. Grace Tilton, Frederic Mohs, and Auntie Burlington, 1914. Courtesy of Frederic E. Mohs, Jr.

Address correspondence and reprint requests to Scott W. Cowan, M.D., Department of Surgery, Thomas Jefferson University, 1025 Walnut Street, College Building, Suite 607, Philadelphia, Pennsylvania 19107. E-mail: Scott.Cowan@jefferson.edu.

countries abroad. It was there that he even heard the announcement of Charles Lindenberg's departure across the Atlantic, a young man that Fred had met through Carl Mohs during his studies at the University of Wisconsin. Radio quickly became more than a passion, as Fred prepared for a career in radio-engineering.¹

Mohs graduated high school in 1927 (Fig. 2), enrolling in the engineering program at the University of

Wisconsin. He supported himself financially as the Brittingham Research Assistant to Michael F. Guyer, the Chairman of the University's Department of Zoology. Among other tasks, he fed the laboratory animals at an hourly wage.^{4, 5} Noting Fred Mohs' diligence and devotion, Dr. Guyer taught Fred about the laboratory's mouse models investigating intraleisional anticancer agents. Fred was then trained for

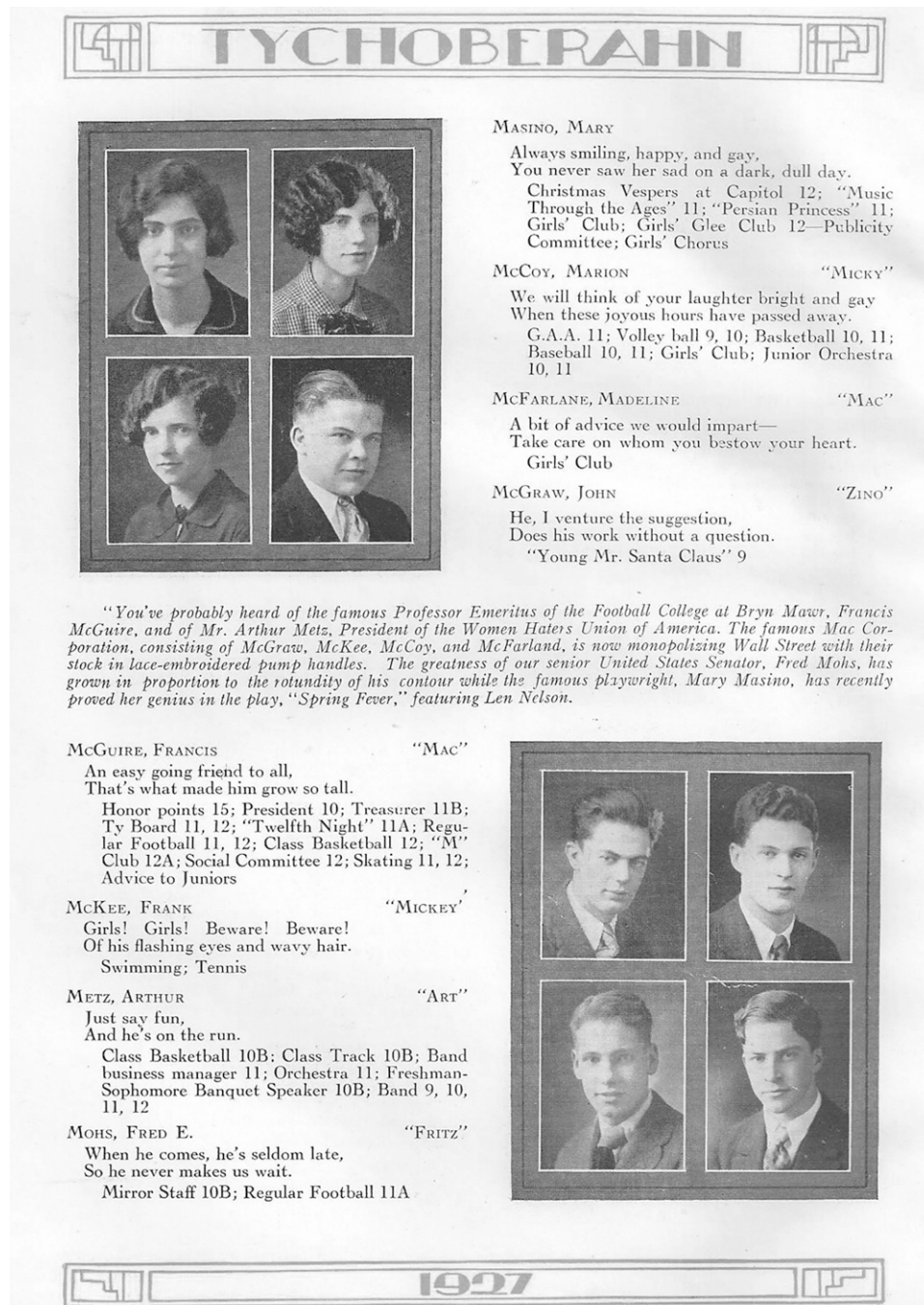


FIG. 2. Frederic E. Mohs, Senior Portrait (lowest right), Wisconsin Central High Tychoberahn, 1927. Courtesy of Nadine Goff, Central Historian.

more challenging roles including specimen injection, excision, and slide preparation. Around 1933, while preparing specimens for microscopic examination, Fred observed that tumors injected with zinc chloride 20 per cent showed necrosis without architectural disruption.^{2, 5} It was this discovery that later became central in the development of “Mohs fixative paste.”

In spite of being engrossed by his work, Fred remained disinterested in a biology degree and ignored Carl Mohs’ urgings that he switch majors to prepare for medical school.¹ Continued laboratory work, however, likely strengthened his subconscious enthusiasm. Fred went on to complete his bachelor’s degree in three years and applied to medical school. Still working in Dr. Guyer’s laboratory, Fred Mohs planned a new surgical technique representing a union of *in situ* tissue fixation, microscopic examination, and tumor mapping.⁴

Dr. Mohs completed medical school at the University of Wisconsin and trained as a general surgery resident in Portland, Oregon. He moved back to Wisconsin, with his wife, Mary Ellen, to begin work at the new McArdle Research Center. There, he experimented with the chemosurgery technique in animal models. The Wisconsin Alumni Research Foundation supported his research with a \$500 monthly check, delivered personally by Thomas E. Brittingham, Jr., and a state-of-the-art laboratory facility.^{1, 6, 7}

On June 30, 1936, Dr. Mohs performed his first human patient procedure. The case was a squamous cell carcinoma of the lower lip, a common lesion in this largely agricultural area.⁴ At that time, Dr. Mohs was 26 years old and working in a one-room suite at the Department of Dermatology of Wisconsin General Hospital. The room had a student-desk, freezing microtome, and staining setup. Slides were prepared by surgical pathologists and residents. If he required the assistance of a nurse, he borrowed one from the Emergency Department. Many of the early cases were conducted on obligate patients drawn from the Mendota Mental Health Hospital or Waupun State Penitentiary. Dr. Mohs saw this as an opportunity that nobody else would ever give these patients. These were different times in medicine.

The early process of what was to evolve into Mohs surgery is described below. Each lesion was prepared for excision with an application of acetic acid.⁸ Once keratin debris was scraped clear, a black fixative paste was applied. It was composed of 30 grams of stibnite (80 mesh sieve), 10 grams of powdered *Sanguinaria canadensis* root and 34.5 cubic centimeters of saturated zinc chloride solution in a base of clinker obtained from the university’s heating plant furnaces (Fig. 3).^{9, 10} Fixation spanned several hours to one day.¹² The carcinoma was removed layer by layer at

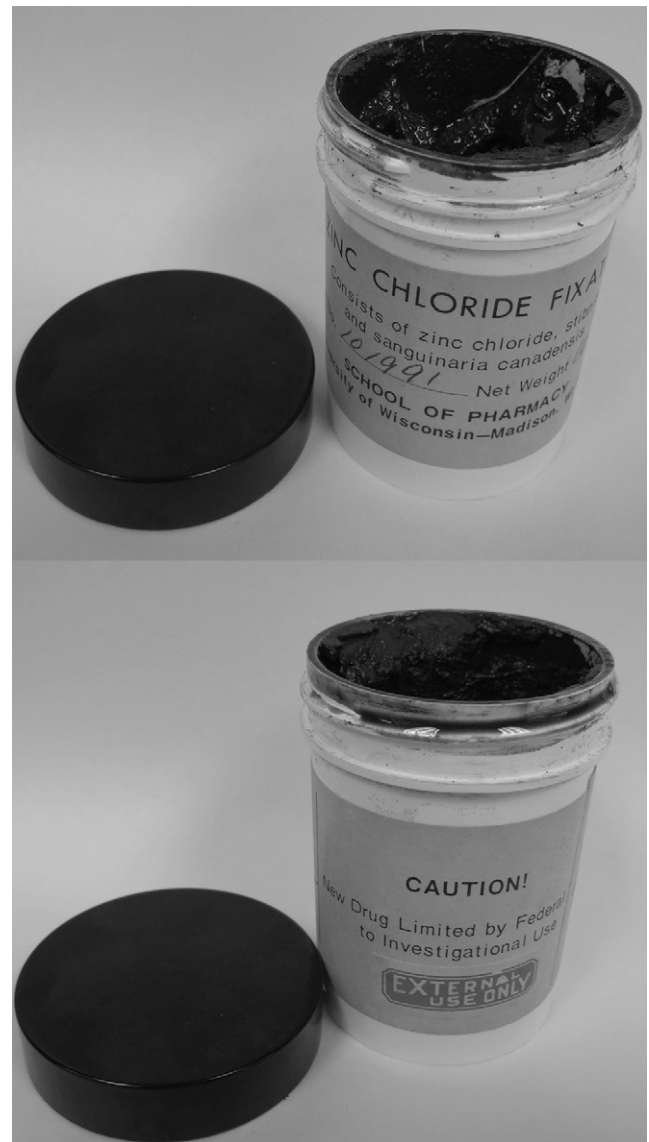

FIG. 3. Zinc chloride fixative paste, original specimen. Courtesy of Nicholas A. Ross.

daily intervals.² Specimens were oriented precisely for sectioning using dyes and cuts.¹² This allowed residual tumor, seen on microscopic examination, to be excised from the defect with maximal preservation of normal tissue.⁸ Closure was by secondary intention or guiding sutures.^{2, 10, 12} The process was arduous and painful for the patient.^{2, 13}

In 1940, Dr. Mohs expanded his practice. With the expansion came more patient cases and more pathology slides. Dr. Mohs prioritized timely, well-prepared specimens. Due to the surgical nature of his practice, his suite was moved to the Hospital’s Department of Surgery. Protestors and skeptics of the technique, however, outnumbered supporters. In fact, his technique did not receive much attention until the

Wisconsin State Journal interviewed Dr. Mohs about its prospects. The reporter later visited his laboratory with a photographer who took one of the famous pictures of Dr. Mohs at his microscope (Fig. 4). The newspaper headline read, "UW Man Reveals Cancer Killer," stirring much debate about his technique.¹⁵ Surgeons, accustomed to traditional excision methods, spoke out, labeling the procedure as "Black Magic" for the black fixative paste used. Proceedings to revoke Dr. Mohs' medical license were even initiated by the Dane County Medical Association. Purportedly, the uproar was silenced by the strong support from Dr. William Middleton, Dean of the University of Wisconsin Medical School, and Dr. Guyer.

Busier by the day, the clinic treated walk-in patients in the mornings and the larger, in-house cases during the afternoons. In 1953, Dr. Mohs excised a lower eyelid neoplasm without *in-situ* fixation, enabling rapid processing. The positive results led Dr. Mohs to employ the "fresh tissue" technique for other peri-orbital neoplasms. He presented his findings at the Chemosurgery College meeting, demonstrating cure in 66 cases of basal cell carcinoma and four cases of squamous cell carcinoma of the eyelid.¹⁵ In 1976, he published 5-year cure rates of 99.3 per cent in a series of 9351 basal cell carcinomas and 94.4 per cent in

a series of 3302 squamous cell carcinomas.¹⁶ Other reports popularized this technique, recapitulating the technique's efficacy.^{17, 18}

Innovations to surgical pathology during these years, including microtome cryostats and automated staining stations, allowed for more rapid fresh-frozen-tissue preparations. Patients were the primary beneficiaries of these workflow improvements because treatments were now concluded in a single visit.²

Dr. Mohs continued to publish applications of his technique, lecturing to audiences in various languages. Physicians from around the world came to study with Dr. Mohs. Perry Robins, MD from New York University was one of his original trainees. Dr. Robins wrote that in 1965, after five weeks of training, he "purchased a 'how to' kit, a jar of zinc chloride paste and Dr. Mohs' textbook and began practicing Mohs surgery at NYU."¹⁹ By 1968, Dr. Robins and Alfred W. Kopf, M.D. established the first chemosurgery fellowship.¹⁹ This technique was quickly taken up by dermatologists, as these physicians were already trained in slide preparation and skin pathology.

The first Chemosurgery Society meeting was held in December 1965 in Number 10 Wabash Room of Chicago's Palmer House Hotel.¹⁹ The meeting hosted 20 members. The society, renamed the American College of Mohs Surgery when zinc chloride fixation was phased out, now boasts over 1200 members in countries around the world, each with postresidency training in Mohs surgery, pathology, and plastic reconstructive surgery.²⁰

A brief overview of Dr. Mohs' personal life suitably follows the description of his career because his patients always came first. Dr. Mohs met his wife-to-be, Mary Ellen, in high school and they married in 1943. Together, they had three children: Frederic Jr, Thomas and Jane. During his career, Dr. Mohs left for work at 8:00 am, returned home at 5:45 pm and had dinner at 6:00 pm. After supper, he went off to his study or returned to the hospital. Family-time was brief, not for lack of enjoyment, but because his work truly excited him.

Dr. Mohs never officially retired. His son recalled that he phased out of clinical practice sometime in the late 1980s. Around then, Dr. Mohs spent more time at home with Mary Ellen who enjoyed having him around never rushing off to the hospital. Even after his career, Dr. Mohs remained in command, determined and heroic.¹ Eventually, however, he began to fail mentally. Along with his wife's companionship, however, he continued to live a happy and productive life. When Mary Ellen passed away from a stroke in 1995, Fred Mohs declined rapidly without his support system. On July 1, 2002, Frederic E. Mohs passed away at his home in Madison, WI, at the age of 92.




FIG. 4. Frederic E. Mohs, M.D., examining a specimen at his microscope. Courtesy of Frederic E. Mohs, Jr.

The small grave-side funeral was attended mostly by family. The memory of his judicious devotion to patients lived on as employees attending made apologies for interrupting their work at his clinic. Dr. Mohs had always believed that their attention belonged to their patients. So as not to call attention to himself in the manner of surrounding aristocrats who erected high-reaching obelisks at their gravesites, a bronze plaque with Fred Mohs' name lies at ground level. Before his passing, Dr. Mohs had joked with his family that he liked the idea because he said it would even make mowing the grass more efficient.

Acknowledgments

The authors thank Nadine Goff, Central Historian, and Frederic E. Mohs, Jr., who brought new levels of detail to this work.

REFERENCES

1. Frederic E Mohs Jr. "Frederic E. Mohs". Annual Conference, 2011; American College of Mohs Surgery.
2. Shriner DL, McCoy DK, Goldberg DJ, et al. Mohs micrographic surgery. *J Am Acad Dermatol* 1998;39:79–97.
3. Tierney EP, Hanke CW. Cost effectiveness of Mohs micrographic surgery: review of the literature. *J Drugs Dermatol* 2009;8:914–22.
4. American College of Mohs Surgery. "History of Mohs Micrographic Surgery" Updated 2014. The ACMS. Available at: <http://www.mohscollege.org/about/history.php>. Accessed May 2, 2014.
5. Trost LB, Bailin PL. History of Mohs surgery. *Dermatol Clin* 2011;29:135–9, vii.
6. "Thomas Evans Brittingham, Jr.", UW-Madison: Archives and Records Management Services. 2012. Available at: <http://archives.library.wisc.edu/uw-archives/exhibits/brittingham/14tomjr.html>. Accessed June 19, 2012.
7. Robins P. A tribute to Dr. Frederic E. Mohs. *J Dermatol Surg Oncol* 1978;4:37.
8. Robins P, Henkind P, Menn H. Chemosurgery in treatment of cancer of the periorbital area. *Trans Am Acad Ophthalmol Otolaryngol.* 1971;75:1228–35.
9. Accessible cancer removed by doctor using new methods. *The Daily Northwestern*, Dec 7, 1940. Available at: <http://www.newspapers.com/newspage/18147376/>. Accessed June 12, 2014.
10. Mohs FE. Chemosurgical treatment of cancer of the eyelid; a microscopically controlled method of excision. *Arch Ophthalmol* 1948;39:43–59.
11. Snow SN, Madjar DD Jr. Mohs surgery in the management of cutaneous malignancies. *Clin Dermatol* 2001;19:339–47.
12. Mohs FE. Chemosurgery: a microscopically controlled method of cancer excision. *Arch Surg* 1941;42:279–95.
13. Hanke CW. Frederic Mohs tribute. History of Mohs micrographic surgery. *J Drugs Dermatol JDD* 2002;1:169–74.
14. Wisconsin State Journal. "UW Man Reveals Cancer Killer". Dec. 6, 1940;157(67).
15. Mohs FE. Cancer of eyelids. *Bull Am Coll Chemos* 1970;3:10–1.
16. Mohs FE. Chemosurgery for skin cancer: fixed tissue and fresh tissue techniques. *Arch Dermatol* 1976;112:211–5.
17. Tromovitch TA, Stegman SJ. Microscopic-controlled excision of cutaneous tumors: chemosurgery, fresh tissue technique. *Cancer.* 1978;41:653–58.
18. Tromovitch TA, Stegman SJ. Microscopically controlled excision of skin tumors. *Arch Dermatol* 1974;110:231–2.
19. Robins P, Ebede TL, Hale EK. "The Evolution of Mohs Micrographic Surgery". Available at: <http://www.skincancer.org/skin-cancer-information/mohs-surgery/evolution-of-mohs>. Accessed June 11, 2014.
20. American College of Mohs Surgery. "About the ACMS," American College of Mohs Surgery. Available at: <http://www.mohscollege.org/about-the-acms>. Accessed June 11, 2014.