

2008

## Tumor Epithelial Cell Matrix Metalloproteinase 9 (MMP-9) is a Prognostic Marker in Colorectal Cancer

DS Zuzga

*Thomas Jefferson University*

AV Gibbons

*Thomas Jefferson University*

P Li


*Thomas Jefferson University*

WJ Lubbe

*Thomas Jefferson University*

Follow this and additional works at: <https://jdc.jefferson.edu/petfp>

I Chervoneva

 Part of [Thomas Jefferson University Department of Pharmacology Commons](#), and the [Pharmacy and Pharmaceutical Sciences Commons](#)

**Let us know how access to this document benefits you**

*See next page for additional authors*

---

### Recommended Citation

DS Zuzga; AV Gibbons; P Li; WJ Lubbe; I Chervoneva; and Pitari, Giovanni Mario, "Tumor Epithelial Cell Matrix Metalloproteinase 9 (MMP-9) is a Prognostic Marker in Colorectal Cancer" (2008). *Department of Pharmacology and Experimental Therapeutics Faculty Papers*. Paper 23. <https://jdc.jefferson.edu/petfp/23>

This Article is brought to you for free and open access by the Jefferson Digital Commons. The Jefferson Digital Commons is a service of Thomas Jefferson University's [Center for Teaching and Learning \(CTL\)](#). The Commons is a showcase for Jefferson books and journals, peer-reviewed scholarly publications, unique historical collections from the University archives, and teaching tools. The Jefferson Digital Commons allows researchers and interested readers anywhere in the world to learn about and keep up to date with Jefferson scholarship. This article has been accepted for inclusion in Department of Pharmacology and Experimental Therapeutics Faculty Papers by an authorized administrator of the Jefferson Digital Commons. For more information, please contact: [JeffersonDigitalCommons@jefferson.edu](mailto:JeffersonDigitalCommons@jefferson.edu).

---

**Authors**

DS Zuzga, AV Gibbons, P Li, WJ Lubbe, I Chervoneva, and Giovanni Mario Pitari

# Tumor Epithelial Cell Matrix Metalloproteinase 9 (MMP-9) is a Prognostic Marker in Colorectal Cancer

DS Zuzga, AV Gibbons, P Li, WJ Lubbe, I Chervoneva, and GM Pitari

Department of Pharmacology and Experimental Therapeutics, Thomas Jefferson University, Philadelphia, PA 19107

## Abstract

Colorectal cancer is the second leading cause of cancer-related mortality in developed nations. Mortality from colon cancer largely reflects metastasis, the spread of the disease to distant sites. Early diagnosis of pre-metastatic disease and accurate stratification of patients with metastasis is pivotal to decrease mortality rates from colon cancer by effectively administering surgery alone or with chemotherapy. However, specific pathological markers of colorectal cancer metastasis have not emerged. Matrix metalloproteinase 9 (MMP-9) is a key regulator of metastasis and a therapeutic target in colon cancer. Here, MMP-9 overexpression in pure tumor epithelial, but not stromal, cell populations from patients was associated with metastatic colorectal cancer progression as defined by RT-PCR and confirmed by immunostaining. Thus, tumors with increased MMP-9 expression compared to matched normal adjacent tissues always exhibited metastatic dissemination. In particular, MMP-9 overexpression in tumor epithelial cells, compared to normal epithelial cells, specifically predicted lymph node involvement. Importantly, patients with relative increase of MMP-9 levels in tumor epithelial cells were characterized by more advanced disease stages, with significantly higher proportion of regional lymph nodes harboring metastasis, compared to patients with a relative decrease in MMP-9 expression. Together, these observations suggest tumor epithelial cell MMP-9 is a novel prognostic marker that may be exploited for more efficient disease stage stratification and therapeutic regimen selection in patients with colorectal cancer.

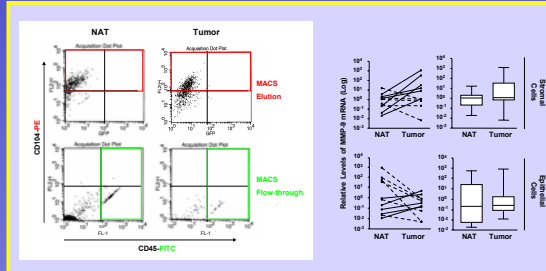
### Table I. Colorectal Cancer Patients

>Age (y)		>Differentiation Grade (%)	
Median (range)	61 (54-85)	Well	1 (9.1)
>Gender (%)		Moderate	7 (63.6)
Male	7 (63.6)	Poor	3 (27.2)
Female	4 (36.3)	>Tumor Depth (%)	
>Tumor Site (%)		T1S (carcinoma in situ)	0 (0)
Colon	10 (90.9)	T1 (limited to submucosa)	0 (0)
Rectum	1 (9.1)	T2 (invading the muscularis propria)	1 (9.1)
>Dukes' Tumor Stage (%)		T3 (invading the serosa)	9 (81.8)
A	1 (9.1)	T4 (invading adjacent organs)	1 (9.1)
B	3 (27.2)	>Lymph Node Metastasis (%)	
C	5 (45.5)	Yes	7 (63.6)
D	2 (18.2)	No	4 (36.3)

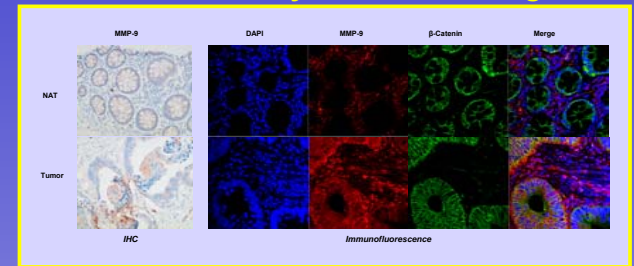
### Table II. TNM-Based Stage Group & Score

Stage Group	TNM	Lymph Nodes Examined (Range)	Patient n. (%)	Score
0	T1s, N0, M0	0	0 (0)	1
I	T1-2, N0, M0	27	1 (9.1)	2
IIA	T3, N0, M0	13-23	3 (27.3)	3
IIB	T4, N0, M0	0	0 (0)	4
IIIA	T1-2, N1, M0	0	0 (0)	5
IIIB	T3-4, N1, M0	9-29	4 (36.3)	6
IIIC	T1-4, N2, M0	13-33	3 (27.3)	7
IV+	T1-4, N0-2, M1	0	0	8

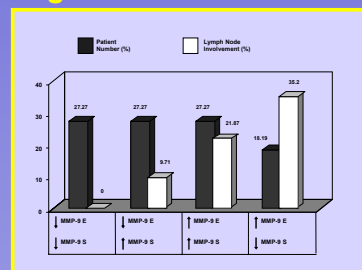
## MMP-9 mRNA Levels in Pure Epithelial and Stromal Cell Populations



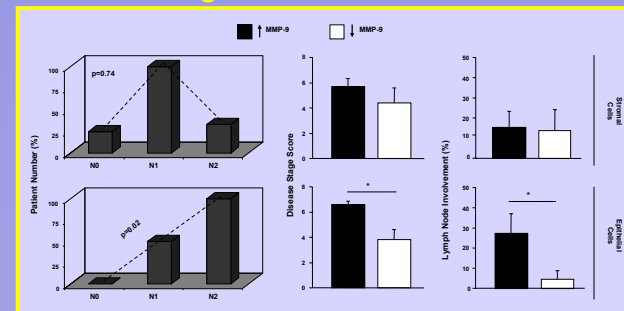
## MMP-9 Overexpression in Tumor Epithelial Cells is Detected by Immunostaining



## MMP-9 Expression Levels Signifies Metastasis

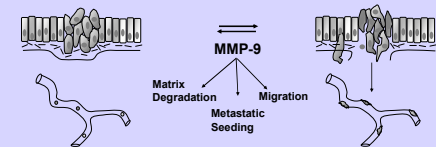


## MMP-9 Overexpression in Tumor Epithelial Cells is a Prognostic Marker in Colon Cancer



## Conclusions

- Increased MMP-9 expression in colorectal tumor cells is associated with locoregional metastatic dissemination
- MMP-9 overexpression in tumor epithelial cells is a prognostic indicator of metastatic colorectal cancer
- MMP-9 overexpression in colorectal tumor cell compartment can be detected by conventional histopathology
- Tumor epithelial cell MMP-9 represents a novel, specific prognostic marker and a potential therapeutic target for patients with colorectal cancer



## Acknowledgements

These studies were supported by funding from the Prevent Cancer Foundation and the Pennsylvania Department (to GMP). The Pennsylvania Department specifically disclaims responsibility for any analyses, interpretations, or conclusions.