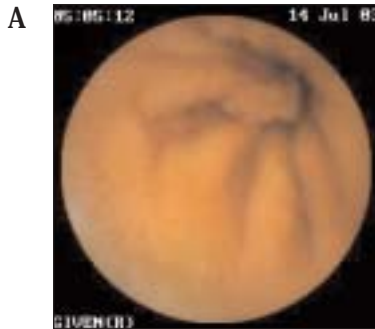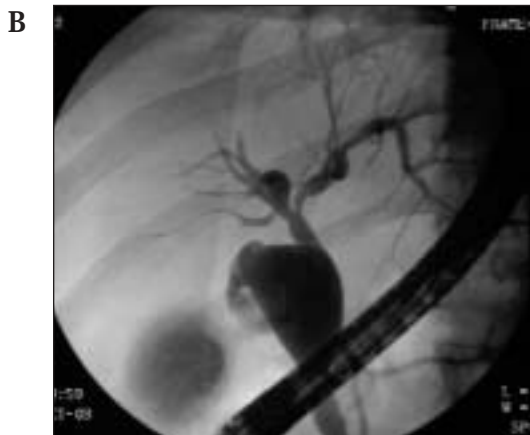


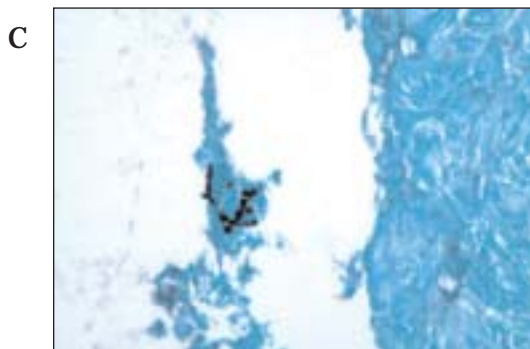Clinical Quiz



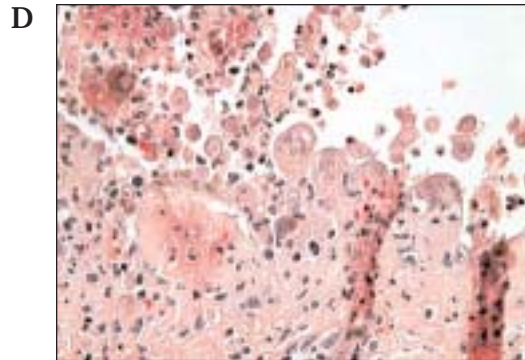
An asymptomatic 14 y/o female with a history of Peutz-Jeugers syndrome and prior small bowel intussusception had the above finding during screening with capsule endoscopy. What is the next step?



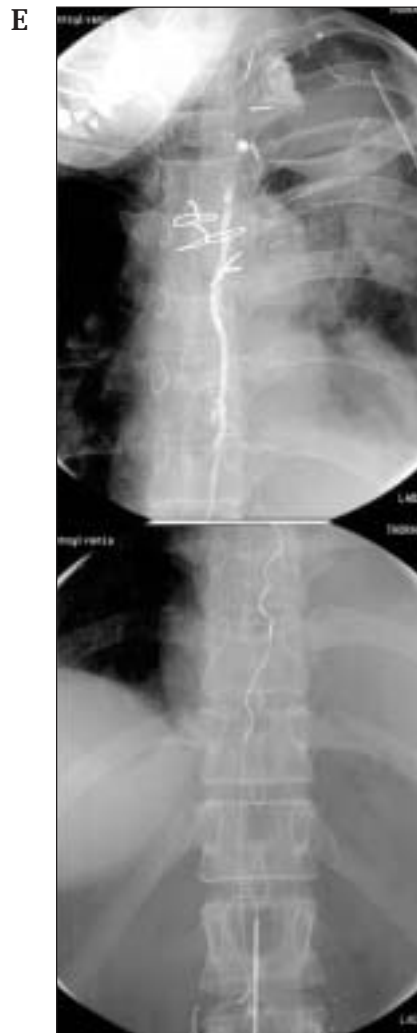
A 33 y/o female with intermittent right upper quadrant pain and an abnormal abdominal ultrasound underwent ERCP evaluation. What abnormality is seen and what would you recommend to this patient?



A 54y/o male with a history of sarcoidosis, in remission from AML after recent chemotherapy and XRT, presents with elevated LFTs and liver nodules on ultrasound. What is shown above?



A 21 y/o healthy male acutely decompensates and presents with a total body punctate rash and fulminant liver and renal failure. What is the diagnosis, based on the histologic slide above?



A 68 y/o woman, status post left upper lobe pneumonectomy for squamous cell cancer of the lung, presents with a 2 week history of heaviness in her chest and dyspnea. Thoracentesis revealed a milky discharge. A therapeutic fluoroscopic procedure is shown above. What is your diagnosis? What is the procedure?

Answers on page 12