

6-20-2012

Anatomical relationships of the anterior blood vessels to the lower lumbar intervertebral discs: analysis based on magnetic resonance imaging of patients in the prone position.

Alexander R Vaccaro

Rothman Institute, Department of Orthopaedic Surgery, Thomas Jefferson University

Christopher K Kepler

Rothman Institute, Department of Orthopaedic Surgery, Thomas Jefferson University

Jeffrey A Rihn

Rothman Institute, Department of Orthopaedic Surgery, Thomas Jefferson University

Hidekazu Suzuki

Rothman Institute, Department of Orthopaedic Surgery, Thomas Jefferson University

Follow this and additional works at: https://jdc.jefferson.edu/rothman_institute

John K Ratliff

 Part of the [Neurosurgery Commons](#), [Orthopedics Commons](#), and the [Radiology Commons](#)

[Let us know how access to this document benefits you](#)

See next page for additional authors

Recommended Citation

Vaccaro, Alexander R; Kepler, Christopher K; Rihn, Jeffrey A; Suzuki, Hidekazu; Ratliff, John K; Harrop, James S; Morrison, William B; Limthongkul, Worawat; and Albert, Todd J, "Anatomical relationships of the anterior blood vessels to the lower lumbar intervertebral discs: analysis based on magnetic resonance imaging of patients in the prone position." (2012). *Rothman Institute Faculty Papers*. Paper 19.
https://jdc.jefferson.edu/rothman_institute/19

This Article is brought to you for free and open access by the Jefferson Digital Commons. The Jefferson Digital Commons is a service of Thomas Jefferson University's [Center for Teaching and Learning \(CTL\)](#). The Commons is a showcase for Jefferson books and journals, peer-reviewed scholarly publications, unique historical collections from the University archives, and teaching tools. The Jefferson Digital Commons allows researchers and interested readers anywhere in the world to learn about and keep up to date with Jefferson scholarship. This article has been accepted for inclusion in Rothman Institute Faculty Papers by an authorized administrator of the Jefferson Digital Commons. For more information, please contact: JeffersonDigitalCommons@jefferson.edu.

Authors

Alexander R Vaccaro, Christopher K Kepler, Jeffrey A Rihn, Hidekazu Suzuki, John K Ratliff, James S Harrop, William B Morrison, Worawat Limthongkul, and Todd J Albert

Anatomical Relationships of the Anterior Blood Vessels to the Lower Lumbar Intervertebral Discs

Analysis Based on Magnetic Resonance Imaging of Patients in the Prone Position

Alexander R. Vaccaro, MD, PhD, Christopher K. Kepler, MD, MBA, Jeffrey A. Rihn, MD, Hidekazu Suzuki, MD, John K. Ratliff, MD, James S. Harrop, MD, William B. Morrison, MD, Worawat Limthongkul, MD, and Todd J. Albert, MD

Investigation performed at the Departments of Orthopaedic Surgery, Neurosurgery, and Radiology, Thomas Jefferson University, Philadelphia, Pennsylvania

Background: Intra-abdominal vascular injuries are rare during posterior lumbar spinal surgery, but they can result in major morbidity or mortality when they do occur. We are aware of no prior studies that have used prone patient positioning during magnetic resonance imaging for the purpose of characterizing the retroperitoneal iliac vasculature with respect to the intervertebral disc. The purpose of this study was to define the vascular anatomy adjacent to the lower lumbar spine with use of supine and prone magnetic resonance imaging.

Methods: A prospective observational study included thirty patients without spinal abnormality who underwent supine and prone magnetic resonance imaging without abdominal compression. The spinal levels of the aortic bifurcation and confluence of the common iliac veins were identified. The proximity of the anterior iliac vessels to the anterior and posterior aspects of the anulus fibrosus in sagittal and coronal planes was measured by two observers, and interobserver reliability was calculated.

Results: The aortic bifurcation and confluence of the common iliac veins were most commonly at the level of the L4 vertebral body and migrated cranially with prone positioning. The common iliac vessels were closer to the anterior aspect of the intervertebral disc and to the midline at L4-L5 as compared with L5-S1, consistent with the bifurcation at the L4 vertebral body. Prone positioning resulted in greater distances between the disc and iliac vessels at L4-L5 and L5-S1 by an average of 3 mm. The position of the anterior aspect of the anulus with respect to each iliac vessel demonstrated substantial variation between subjects. The intraclass correlation coefficient for measurement of vessel position exceeded 0.9, demonstrating excellent interobserver reliability.

Conclusions: This study confirmed the L4 level of the aortic bifurcation and iliac vein coalescence but also demonstrated substantial mobility of the great vessels with positioning. Supine magnetic resonance imaging will underestimate the proximity of the vessels to the intervertebral disc. Large interindividual variation in the location of vasculature was noted, emphasizing the importance of careful study of the location of the retroperitoneal vessels on a case-by-case basis.

Clinical Relevance: Anatomic relationships between vessels and intervertebral discs on supine magnetic resonance imaging may differ from relationships during surgery with the patient in a prone position.

Iatrogenic vascular injury secondary to lumbar disc surgery has an estimated incidence ranging from 0.017% to 0.14%¹⁻³. Additionally, vascular injury during posterior spinal surgery carries a high morbidity and a 10% to 65% mortality rate². Procedures at upper lumbar levels (L2-L4) are associated with

injuries predominantly to the aorta and the inferior vena cava, while procedures in the lower lumbar spine (L4-S1) most commonly injure the paired common iliac arteries and veins²⁻⁸. Other reported vascular injuries have included the superior rectal artery and bridging veins⁹⁻¹¹.

Disclosure: None of the authors received payments or services, either directly or indirectly (i.e., via his or her institution), from a third party in support of any aspect of this work. One or more of the authors, or his or her institution, has had a financial relationship, in the thirty-six months prior to submission of this work, with an entity in the biomedical arena that could be perceived to influence or have the potential to influence what is written in this work. Also, one or more of the authors has had another relationship, or has engaged in another activity, that could be perceived to influence or have the potential to influence what is written in this work. The complete **Disclosures of Potential Conflicts of Interest** submitted by authors are always provided with the online version of the article.

Risk factors for vascular injury include preexisting defects in the anterior longitudinal ligament and anterior aspect of the anulus fibrosus, degenerative disc disease, retroperitoneal inflammatory processes, vascular disease, aggressive discectomy, and repeat discectomy^{2,9,12}. Changes in the location of the vessels due to changes in patient position or intra-abdominal pressure with the patient in the prone position have also been described^{2,13}. Increased intra-abdominal pressure in the prone position may force retroperitoneal vessels closer to the anterior aspect of the lumbar discs where they may be more easily injured. Conceivably, the use of a pressure-free frame prevents this compression and mobilization of the vessels. Simultaneously, the dependent position of the abdomen in the prone position may allow anterior structures to move further away from the spine. To minimize the risk of a vessel injury, careful positioning with a suspended abdomen, meticulous surgical technique, and limited depth of instrument placement are essential.

The anatomical relationship of retroperitoneal vessels to the intervertebral disc has been reported in numerous studies^{8,14-16}. The precise spatial relationship of the vasculature to the disc while a patient is in the prone position, however, has not previously been described, to our knowledge. Therefore, the purpose of this study was to determine the anatomical relationships of the anterior vessels to the lumbar intervertebral discs with use of magnetic resonance imaging (MRI) of the lumbar spine with the patient in the prone position and to characterize the location of vessels on MRI scans taken in both the supine and prone positions for each patient.

Materials and Methods

The institutional review board approved a prospective observational imaging study of thirty patients who required a lumbar MRI for symptoms referable to the lumbar spine. Thirty patients, twenty-one women and nine men, with an average age of forty-one years (range, nineteen to eighty-nine years) were enrolled in the study and underwent MRI in the supine and prone positions. Patients with prior abdominal, pelvic, or lumbar surgery or with an abnormal condition of the lumbar spine were excluded. Lumbar MRI (1.5 Tesla) was performed on all study patients in both the prone and supine positions. To simulate the intraoperative prone position, patients were positioned in the MRI scanner on chest and pelvic rolls, leaving the abdomen free of compression. Axial, coronal, and sagittal T1-weighted and fat-saturated T2-weighted images were obtained. Axial images were obtained at the L2-L3, L3-L4, L4-L5, and L5-S1 disc levels, parallel to the disc space. The levels of the aortic bifurcation and the confluence of the common iliac veins were identified. While the patient was positioned in the supine then the prone position, the proximity of the common iliac arteries and common iliac veins to the anterior and posterior aspects of the anulus fibrosus and the vessel dimensions were measured by an attending radiologist and a fellowship-trained spinal surgeon (Fig. 1) at the L4-L5 and L5-S1 levels using measurement tools embedded in the picture archiving and communication systems (PACS) (Sectra IDS5, version 11.1; Sectra Imtec, Linköping, Sweden).

Average measurements from supine and prone MRIs for the same patient were compared with use of paired Student *t* tests when continuous variables were compared and chi-squared tests when ratios were compared. To provide insight into interindividual variation in measurements, the range of measurement values across the study population was compared with population measurement averages for the distance of the common iliac vessels from the anterior aspect of the anulus, a measurement thought to best convey the likelihood of vessel injury due to accidental intraoperative breach through the anterior aspect of the anulus. Interobserver reliability was assessed by calculating the intraclass correlation coefficient (ICC) for repeated measurements.

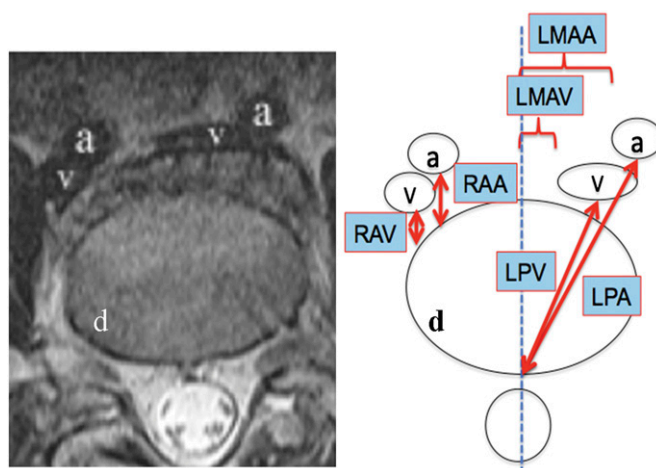


Fig. 1

Schematic showing the measured parameters. RAA = right side, anterior aspect of anulus to common iliac artery, RAV = right side, anterior aspect of anulus to common iliac vein, LAA = left side, distance from midline anteriorly to common iliac artery, LAV = left side, distance from midline anteriorly to common iliac vein, LPA = left side, posterior aspect of anulus to common iliac artery, LPV = left side, posterior aspect of anulus to common iliac vein, d = disc, a = artery, and v = vein.

Source of Funding

This study did not have an external funding source.

Results

Aortic Bifurcation and Iliac Vein Confluence

In the supine position, twenty-two (73%) of thirty aortic bifurcations were at L4 as compared with eighteen (60%) of thirty in the prone position, a statistically nonsignificant difference ($p = 0.3$). In the supine position, five (17%) of thirty aortic bifurcations were above L4 whereas eleven (37%) of thirty were above L4 in the prone position, representing a nonsignificant cranial migration in the prone position ($p = 0.08$). In the supine position, the most common location of the iliac vessel confluence was at L5 (seventeen [57%] of thirty) whereas in the prone position the most common location of the confluence was at L4 (fifteen [50%] of thirty). In the supine position, eighteen (60%) of thirty had the iliac vein confluence at L5 or below as compared with eight (27%) of thirty in the prone position, representing a significant cranial migration in the prone position ($p < 0.01$). At L3-L4, the inferior vena cava was 1 mm (range, 0 to 5) from the anterior aspect of the anulus at its closest point, 10 mm (range, 1 to 22) to the right of the midline of the anterior aspect of the anulus, and 38 mm (range, 29 to 48) from the midline of the posterior aspect of the anulus. A comparison between the prone and supine positions with regard to the level of the aortic bifurcation and the confluence of the common iliac veins is shown in Table I.

Iliac Vasculature Width

All distances are provided as averages and refer to the prone position most reflective of positioning for posterior surgery unless otherwise indicated. The mean width of the right common iliac artery at L4-L5 and L5-S1 was 10.1 mm (range, 5 to 15 mm)

TABLE I Level of Aortic Bifurcation and Confluence of the Common Iliac Veins in Prone and Supine Positions*

Level	Aortic Bifurcation		Confluence of the Common Iliac Veins	
	Prone	Supine	Prone	Supine
L3	5 (17%)	3 (10%)	1 (3%)	0
L3-L4	6 (20%)	2 (7%)	0	1 (3%)
L4	18 (60%)	22 (73%)	15 (50%)	9 (30%)
L4-L5	1 (3%)	2 (7%)	6 (20%)	2 (7%)
L5	0	1 (3%)	8 (27%)	17 (57%)
L5-S1	0	0	0	1 (3%)

*The data are expressed as the number of patients, with the percentage in parentheses.

and 9.2 mm (range, 5 to 21 mm), respectively. The mean width of the right common iliac vein at L4-L5 and L5-S1 was 12 mm (range, 6 to 20 mm) and 11.4 mm (range, 5 to 22 mm), respectively. The mean width of the left common iliac artery at L4-L5 and L5-S1 was 9.5 mm (range, 6 to 15 mm) and 8.6 mm (range, 4 to 24 mm), respectively. The mean width of the left common iliac vein at L4-L5 and L5-S1 was 9.8 mm (range, 5 to 16 mm) and 13.5 mm (range, 6 to 21 mm), respectively. There was no significant difference in artery or vein width with prone or supine positioning (see Appendix).

Distances from the Anterior Aspect of the Anulus

At L4-L5, the right and left common iliac arteries were an average of 5.4 mm (range, 0 to 16 mm) and 2.9 mm (range, 0 to 9 mm) anterior to the anterior aspect of the anulus at their closest point and measured an average of 8.6 mm (range, 0 to 23 mm) and 11.8

mm (range, 2 to 23 mm) from the midline of the anterior aspect of the anulus. The right and left common iliac veins were closer to the disc, at an average of 0.8 mm (range, 0 to 4 mm) and 0.8 mm (range, 0 to 4 mm), respectively, from the anterior aspect of the anulus at its closest point and were 13.9 mm (range, 1 to 28 mm) and 4.8 mm (range, 0 to 17 mm), respectively, from the midline. In comparing supine and prone positioning, there were no significant differences in the positions of the iliac vasculature with reference to the anterior aspect of the anulus (Table II).

At L5-S1, the right and left common iliac arteries were a mean of 8.6 mm (range, 0 to 23 mm) and 12.6 mm (range, 4 to 23 mm) anterior to the anterior aspect of the anulus at their closest point and averaged 18.6 mm (range, 11 to 28 mm) and 19.1 mm (range, 7 to 28 mm), respectively, from the midline. The right and left common iliac veins were an average of 3.1 mm (range, 0 to 9 mm) and 2.5 mm (range, 0 to 9 mm), respectively, from the anterior aspect of the anulus at the closest point and averaged 23 mm (15 to 30 mm) and 21.1 mm (10 to 47 mm) from the midline of the anulus. Both the right iliac artery and vein were significantly more laterally located in the prone position than in the supine position (a mean of 3.4 mm and 3.8 mm, respectively [$p < 0.001$]). The left iliac vein was significantly more anterior (mean, 1.1 mm; $p = 0.01$) and more lateral (mean, 5.1 mm; $p = 0.01$) while the left iliac artery moved significantly more lateral (mean, 2 mm; $p = 0.03$) (Table II).

Distances from the Posterior Aspect of the Anulus

At L4-L5, the right and left common iliac arteries were an average of 43.3 mm (range, 34 to 57 mm) and 40.6 mm (range, 33 to 49 mm) from the midline of the posterior aspect of the anulus. The right and left common iliac veins were an average of 38.1 mm (range, 31 to 49 mm) and 39.9 mm (range, 27 to 50 mm) from the midline of the posterior aspect of the anulus. When supine and prone positioning were compared (Table III), the average

TABLE II Distance from the Anterior Aspect of the Anulus to the Common Iliac Artery and Vein in the Prone and Supine Positions at L4-L5 and L5-S1*

	L4-L5			L5-S1		
	Prone	Supine	P Value	Prone	Supine	P Value
RAA	5.4 (0-16)	5.1 (0-17)	0.54	8.6 (0-23)	8.8 (3-20)	0.78
RAV	0.8 (0-4)	0.6 (0-3)	0.74	3.1 (0-9)	3.3 (0-14)	0.60
LAA	2.9 (0-9)	3.5 (0-10)	0.06	12.6 (4-23)	11.3 (4-20)	0.24
LAV	0.8 (0-4)	0.3 (0-3)	0.39	2.5 (0-9)	1.4 (0-7)	0.01†
RMAA	8.6 (0-23)	8.2 (0-47)	0.08	18.6 (11-28)	15.2 (7-26)	<0.001†
RMAV	13.9 (1-28)	13.1 (0-38)	0.64	23.0 (15-30)	19.2 (9-30)	<0.001†
LMAA	11.8 (2-23)	11.0 (0-19)	0.20	19.1 (7-28)	17.1 (7-24)	0.03†
LMAV	4.8 (0-17)	6.2 (0-32)	0.53	21.1 (10-47)	16.0 (2-29)	0.01†

*The data are presented as average distance between the structures in millimeters, with the range in parentheses. RAA = right side, anterior aspect of anulus to common iliac artery; RAV = right side, anterior aspect of anulus to common iliac vein; LAA = left side, anterior aspect of anulus to common iliac artery; LAV = left side, anterior aspect of anulus to common iliac vein; RMAA = right side, distance from midline anteriorly to common iliac artery; RMAV = right side, distance from midline anteriorly to common iliac vein; LMAA = left side, distance from midline anteriorly to common iliac artery; LMAV = left side, distance from midline anteriorly to common iliac vein. †Difference was significant.

TABLE III Distance from the Posterior Aspect of the Anulus to the Common Iliac Artery and Vein in the Prone and Supine Positions at L4-L5 and L5-S1*

	L4-L5			L5-S1		
	Prone	Supine	P Value	Prone	Supine	P Value
RPA	43.3 (34-57)	39.7 (6-58)	0.03†	45.1 (35-61)	41.4 (13-56)	0.04†
RPV	38.1 (31-49)	35.1 (9-43)	0.01†	39.5 (26-50)	37.1 (27-50)	<0.001†
LPA	40.6 (33-49)	39.3 (32-52)	0.02†	48.1 (35-63)	44.7 (37-58)	0.01†
LPV	39.9 (27-50)	34.3 (3-44)	0.04†	36.3 (7-53)	34.7 (26-43)	0.20

*The data are presented as average distance between the structures in millimeters, with the range in parentheses. RPA = right side, posterior aspect of anulus to common iliac artery; RPV = right side, posterior aspect of anulus to common iliac vein; LPA = left side, posterior aspect of anulus to common iliac artery; LPV = left side, posterior aspect of anulus to common iliac vein. †Significant difference.

distance from the midline of the posterior aspect of the anulus to the closest portion of the common iliac artery increased significantly for both the right and the left common iliac arteries (3.6 mm and 1.3 mm, respectively; $p = 0.03$ and 0.02 , respectively) and both the right and the left common iliac veins (3 mm and 5.6 mm, respectively; $p = 0.01$ and 0.04 , respectively).

At L5-S1, the right and left common iliac arteries were a mean of 45.1 mm (range, 35 to 61 mm) and 48.1 mm (range, 35 to 63 mm) from the midline of the posterior aspect of the anulus. The right and left common iliac veins were a mean of 39.5 mm (range, 26 to 50 mm) and 36.3 mm (range, 7 to 53 mm) from the midline of the posterior aspect of the anulus. When prone and supine positioning were compared, the right and left common iliac arteries were located significantly farther from the midline of the posterior aspect of the anulus in the prone position (mean, 3.7 mm and 3.4 mm, respectively; $p = 0.04$ and 0.01 , respectively), as was also true for the right common iliac vein (mean, 2.4 mm; $p < 0.001$) (Table III).

Sex Differences

There were no differences in level of aortic bifurcation or iliac confluence when the patient cohort was analyzed on the basis of sex ($p > 0.7$ for both). Based on the numbers, there were no significant differences in average distances of the iliac vessels from the anterior aspect of the anulus at L4-L5 or L5-S1 when the patient cohort was analyzed by sex ($p > 0.34$ for all measurements). Mean distances of all four iliac vessels from the midline of the posterior aspect of the anulus at L5-S1 were significantly greater in men than in women by an average of 7 mm ($p < 0.02$ for each measurement), and the mean distance from the midline of the posterior aspect of the anulus to the left common iliac artery at L4-L5 was significantly larger in men ($p < 0.01$) by 6.5 mm. Given the absence of differences in the distance between the anterior aspect of the anulus and the iliac vessels, these differences likely reflect the larger dimensions of the intervertebral disc in men as compared with those in women.

Interindividual Variation in Measurements

Distances between the anterior aspect of the anulus and the right and left common iliac veins demonstrated interindividual ranges

more than 2.8 times the average values at both L4-L5 and L5-S1, suggesting wide variation across subjects in our study in comparison with the average value. The position of the right and left common iliac arteries was similarly variable in their distance from the anterior aspect of the anulus with measurement ranges of greater than 1.5 times the average distance for the left common iliac artery at L5-S1 and greater than 2.7 times the average distance for all other common iliac arteries.

Interobserver Reliability

Interobserver reliability analysis for measurements of retroperitoneal vasculature width and distance from the posterior aspect of the anulus demonstrated intraclass correlation coefficients of 0.93 for vessel diameter and 0.92 for vessel distance from the posterior aspect of the anulus, representing excellent reliability.

Discussion

Information about the effect of positioning on the vascular anatomy during surgery may be helpful in avoiding iatrogenic vessel injury, understanding how anatomy in the prone position differs from supine anatomy seen on MRI, and informing surgeons about the anatomic structures that are at risk. We performed an a priori prospective study in which patients served as their own controls after a change in positioning; in contrast, previous studies that suggested that positioning affects vasculature position did so without direct proof of this phenomenon^{2,13}. While the incidence of injury to major vascular structures during posterior spinal surgery is low, the importance of this topic is reflected by the inordinately high associated morbidity and mortality, which affects 10% to 65% of patients with these vascular injuries^{2,17-19}.

Previous studies have sought to illustrate the relationship of the aortic bifurcation to the lumbar spine. Using lateral-view radiographs and contrast injections of the great vessels, Nilsson and Hakelius²⁰ demonstrated the close proximity of the instruments used in discectomy to the lumbar anterior longitudinal ligament and associated anterior vessels. Pirró et al.²¹ reported in a cadaver study that the aortic bifurcation was most often found at the L4 vertebra (50%) followed by the L5 vertebra (39%), a

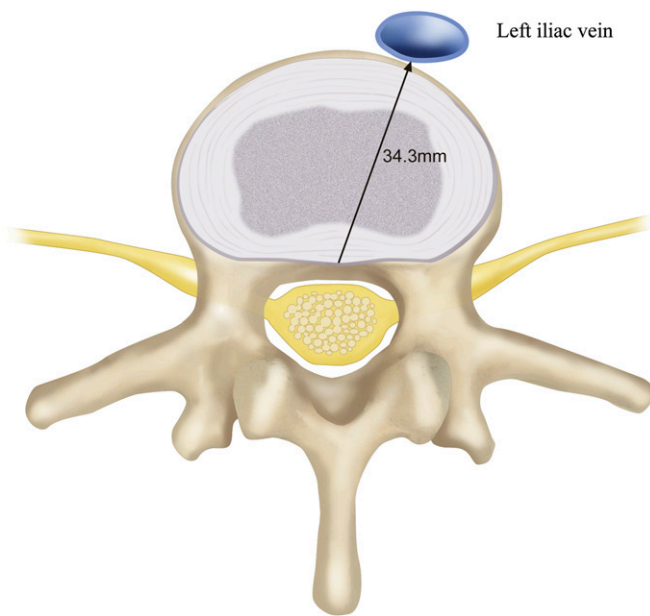


Fig. 2-A

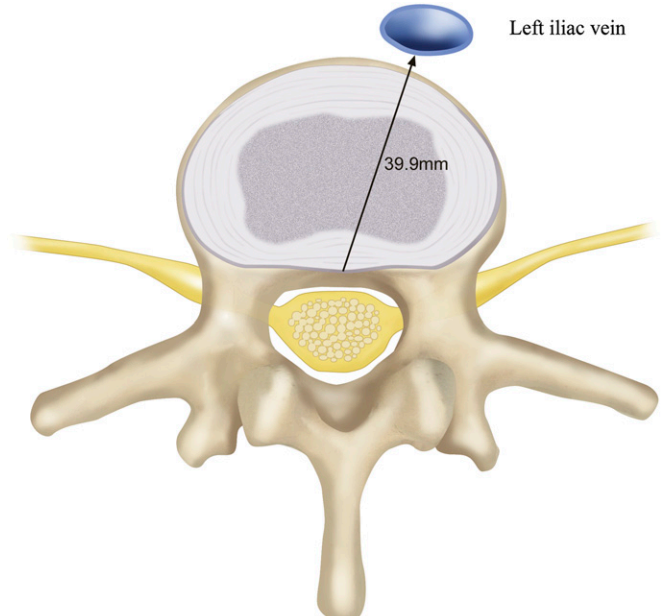


Fig. 2-B

Illustration demonstrating that the distance between the left iliac vein and the posterior aspect of the anulus at L4-L5 varied by >5 mm in the supine (**Fig. 2-A**) versus the prone (**Fig. 2-B**) position, making that vessel less susceptible to injury than a supine MRI would suggest, although it remains the vascular structure at risk compared with other iliac vessels on the basis of its proximity to the posterior aspect of the anulus.

finding that was corroborated by several other studies^{8,22-25}. Khamanarong et al.²⁶ reported bifurcation of the abdominal aorta anterior to the L4 vertebra in 131 (70.1%) of 187 cadavers. All previous studies to date were either cadaveric studies based on the anterior approach to the spine or conventional imaging studies and therefore are descriptions of vascular anatomy with the individual in the supine position. We confirmed that the aortic

bifurcation is most often at the L4 vertebra in the supine position (73%), a percentage that decreased with prone positioning (60%) due to cranial migration of the bifurcation (Table I).

Variability of the ilio caval junction has also been reported. Vraney et al.²³ found that 86% of the patients displayed an iliac vein confluence at L5, and 14% had a confluence overlying L4. Using magnetic resonance angiography, Capellades et al.²⁷ reported that

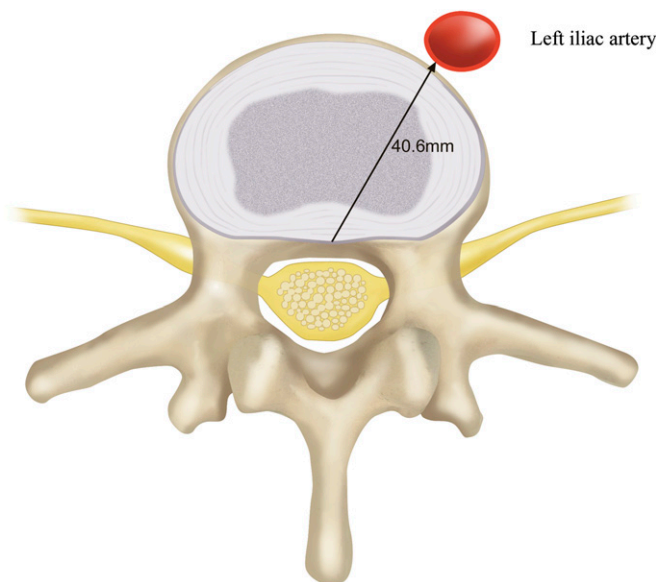


Fig. 3-A

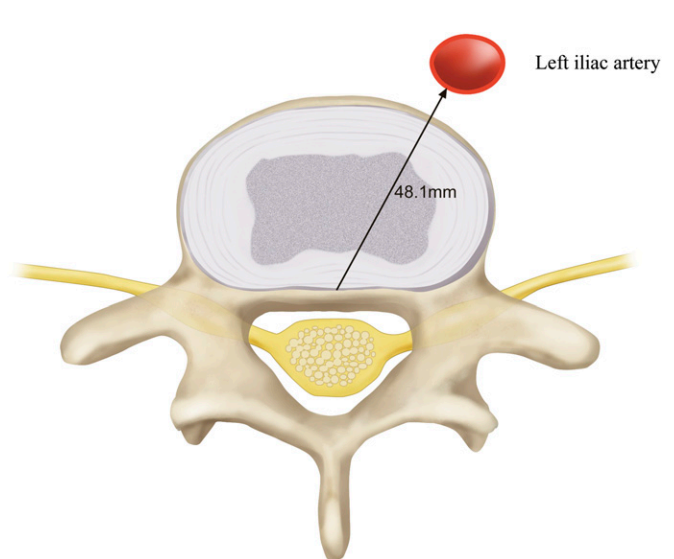


Fig. 3-B

Illustration demonstrating that the left iliac artery was 7.5 mm closer to the posterior aspect of the anulus at L4-L5 (**Fig. 3-A**) than it was at L5-S1 (**Fig. 3-B**). Surgeons must be acutely aware of the level at which they are operating because of major variation in vascular anatomy, even at adjacent spinal levels.

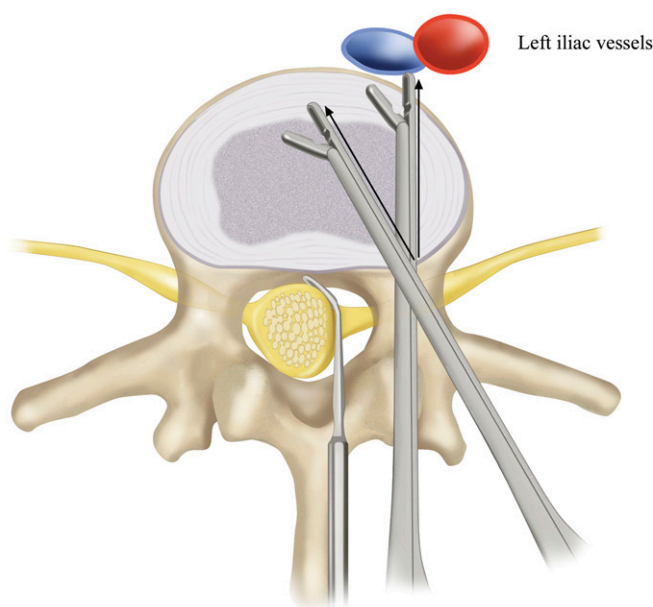


Fig. 4

Illustration depicting the paramount importance of the orientation of an instrument in avoiding injury during intradiscal surgery. Working from the same entry point into the disc and inserted to the same depth, an instrument directed toward the midline is confined safely within the annulus while an instrument directed straight anteriorly breaches the annulus and risks injury to the common iliac artery and common iliac vein.

the ilioacaval junction was most commonly equal at the L4-L5 disc level (59.4%) followed by the L5 vertebra (26.3%). We found movement from the supine into the prone position led to significant ($p < 0.01$) superior migration of the iliac vein confluence.

All four iliac vessels drifted anteriorly in the prone position at L4-L5 in reference to the posterior aspect of the anulus by an average of 3.4 mm, and by 5.6 mm for the left iliac vein. This is an important finding because the left iliac vein is the closest vascular structure to the posterior aspect of the anulus at L4-L5 in the prone position, which may make it more susceptible to injury (Fig. 2). At the L5-S1 level, both iliac arteries and the right iliac vein drifted anteriorly in the prone position while the left iliac vein, again the closest structure to the posterior aspect of the anulus, did not significantly change position, a finding unexplained by any known anatomic constraints. The relative proximity of the left iliac vein to the posterior aspect of the anulus and its lack of mobility are characteristics that may predispose the left iliac vein to iatrogenic injury. At L5-S1, all four iliac vessels shifted away from the midline in the prone position (Table II) to a position less protected by the thickened anterior longitudinal ligament in the case of anular breach. Although the iliac vessels tended to move anteriorly in the prone position, one or both iliac arteries moved posteriorly by greater than 3 mm in five patients (17%) and one or both iliac veins moved posteriorly by greater than 3 mm in three patients (10%). The difference between men and women in distance from the posterior aspect of the anulus to the iliac vessels suggests women may be more prone to iatrogenic vessel injury during disc surgery.

There were substantial differences in the relationship between vascular structures and the disc at L4-L5 compared with that at L5-S1. The average distance in the prone position from the anterior aspect of the anulus is greater by >4 mm for all iliac vessels at L5-S1 than at L4-L5, and the average distance from the posterior aspect of the disc to the left iliac artery is 7.5 mm greater at L5-S1 than it is at L4-L5 (Fig. 3). The iliac vessels also move laterally at L5-S1 by more than 10 mm on the average, potentially moving them outside the protection of the anterior longitudinal ligament. Clinically, iliac vessel injury can occur at both the L4-L5 and L5-S1 spinal levels^{12,28}; it is incumbent on surgeons to be attendant to the risks of surgery that stem from the characteristic vascular anatomy at each level and to take into account any obvious anatomic variation or transitional anatomy that is seen on preoperative magnetic resonance images.

It has been recommended that instruments be marked with distances from the instrument tip so that those distances can be easily appreciated during disc surgery²⁹, and it has also been recommended that instrument penetration into the disc be limited to 25 to 30 mm^{4,30}. Such recommendations must be used with caution to avoid a false sense of security; the orientation of an instrument insertion also impacts the depth of insertion on an anterior to posterior axis (Fig. 4)⁴. Two patients in our study had distances of 15 mm or less between the posterior aspect of the anulus and the right common iliac artery at L4-L5 in the prone position due to far posterolateral iliac artery position, and five patients (17%) had common iliac veins at the L4-L5 level that were <30 mm from the posterior aspect of the anulus in the prone position. The risk of vascular injury during lumbar disc surgery varies from patient to patient and is highly dependent on the orientation of instrument insertion. We caution against reliance on standardized recommendations for guidance on instrument depth.

Our study has limitations. First, although we attempted to enroll subjects without lumbar, abdominal, or retroperitoneal pathology, it is unknown whether our sampling is representative or can be generalized. Secondly, our study is based entirely on MRI measurements; we do not have surgical or postmortem corroboration of findings. The high interobserver reliability, however, suggests that our measurements were highly reproducible.

Appendix

eA A table showing the width of the common iliac artery and vein in the prone and supine positions at the levels of L4-L5 and L5-S1 is available with the online version of this article as a data supplement at jbj.org. ■

Alexander R. Vaccaro, MD, PhD
Christopher K. Kepler, MD, MBA
Jeffrey A. Rihn, MD
Hidekazu Suzuki, MD
John K. Ratliff, MD
James S. Harrop, MD

William B. Morrison, MD
Worawat Limthongkul, MD
Todd J. Albert, MD
Rothman Institute/Department of Orthopaedic Surgery
(A.R.V., C.K.K., J.A.R., H.S., W.L., and T.J.A.),

Department of Neurosurgery (J.K.R. and J.S.H.),
and Department of Radiology (W.B.M.),
Thomas Jefferson University, 1015 Walnut Street,
Room 801, Philadelphia, PA 19107.
E-mail address for C.K. Kepler: chris.kepler@gmail.com

References

- Goodkin R, Laska LL. Vascular and visceral injuries associated with lumbar disc surgery: medicolegal implications. *Surg Neurol*. 1998;49:358-72.
- Papadoulas S, Konstantinou D, Kourea HP, Kritikos N, Haftouras N, Tsolakis JA. Vascular injury complicating lumbar disc surgery. A systematic review. *Eur J Vasc Endovasc Surg*. 2002;24:189-95.
- Bingol H, Cingoz F, Yilmaz AT, Yasar M, Tatar H. Vascular complications related to lumbar disc surgery. *J Neurosurg*. 2004;100(3 Suppl Spine):249-53.
- Birkeland IW, Taylor TK. Major vascular injuries in lumbar disc surgery. *J Bone Joint Surg Br*. 1969;51:4-19.
- Brewster DC, May AR, Darling RC, Abbott WM, Moncure AC. Variable manifestations of vascular injury during lumbar disk surgery. *Arch Surg*. 1979;114:1026-30.
- May AR, Brewster DC, Darling RC, Browne NL. Arteriovenous fistula following lumbar disc surgery. *Br J Surg*. 1981;68:41-3.
- Christensen C, Bank A. Arteriovenous fistula complicating lumbar disc surgery. Case report. *Eur J Surg*. 1991;157:145-6.
- Kang BU, Lee SH, Jeon SH, Park JD, Maeng DH, Choi YG, Tsang YS. An evaluation of vascular anatomy for minimally-invasive anterior L4-5 procedures. *J Neurosurg Spine*. 2006;5:508-13.
- Szolar DH, Preidler KW, Steiner H, Riepl T, Flaschka G, Stiskal M, Moelleken S, Norman D. Vascular complications in lumbar disk surgery: report of four cases. *Neuroradiology*. 1996;38:521-5.
- Tsai YD, Yu PC, Lee TC, Chen HS, Wang SH, Kuo YL. Superior rectal artery injury following lumbar disc surgery. Case report. *J Neurosurg*. 2001;95(1 Suppl):108-10.
- Prabhakar H, Bithal PK, Dash M, Chaturvedi A. Rupture of aorta and inferior vena cava during lumbar disc surgery. *Acta Neurochir (Wien)*. 2005;147:327-9.
- Smith DW, Lawrence BD. Vascular complications of lumbar decompression laminectomy and foraminotomy. A unique case and review of the literature. *Spine (Phila Pa 1976)*. 1991;16:387-90.
- Staar RC, Stoeve WW, Baldwin W, Hickman L. Arteriovenous fistula complicating lumbar disk surgery: report of a case. *J Am Osteopath Assoc*. 1968;67:1379-81.
- Louis R, editor. *Surgery of the spine: surgical anatomy and operative approaches*. Berlin: Springer; 1983.
- Baniel J, Foster RS, Donohue JP. Surgical anatomy of the lumbar vessels: implications for retroperitoneal surgery. *J Urol*. 1995;153:1422-5.
- Tribus CB, Belanger T. The vascular anatomy anterior to the L5-S1 disk space. *Spine (Phila Pa 1976)*. 2001;26:1205-8.
- Desaussure RL. Vascular injury coincident to disc surgery. *J Neurosurg*. 1959;16:222-8.
- Lesoin F, Warembourg H, Asseman P. Fatal congestive heart failure associated with an iatrogenic caval aortic fistula following surgical removal of a herniated intervertebral disk. *Surg Neurol*. 1984;22:532.
- Pirrhó N, Ciampi D, Champsaur P, Di Marino V. The anatomical relationship of the ilio-cava junction to the lumbosacral spine and the aortic bifurcation. *Surg Radiol Anat*. 2005;27:137-41.
- Kawahara N, Tomita K, Baba H, Toribatake Y, Fujita T, Mizuno K, Tanaka S. Cadaveric vascular anatomy for total en bloc spondylectomy in malignant vertebral tumors. *Spine (Phila Pa 1976)*. 1996;21:1401-7.
- Vraney RT, Phillips FM, Wetzel FT, Brustein M. Peridiscal vascular anatomy of the lower lumbar spine. An endoscopic perspective. *Spine (Phila Pa 1976)*. 1999;24:2183-7.
- Chithriri M, Jaibaji M, Steele RD. The anatomical relationship of the aortic bifurcation to the lumbar vertebrae: a MRI study. *Surg Radiol Anat*. 2002;24:308-12.
- Lee CH, Seo BK, Choi YC, Shin HJ, Park JH, Jeon HJ, Kim KA, Park CM, Kim BH. Using MRI to evaluate anatomic significance of aortic bifurcation, right renal artery, and conus medullaris when locating lumbar vertebral segments. *AJR Am J Roentgenol*. 2004;182:1295-300.
- Khamanarong K, Sae-Jung S, Supa-Adirek C, Teerakul S, Prachaney P. Aortic bifurcation: a cadaveric study of its relationship to the spine. *J Med Assoc Thai*. 2009;92:47-9.
- Capellades J, Pellisé F, Rovira A, Grivé E, Pedraza S, Villanueva C. Magnetic resonance anatomic study of ilio-cava junction and left iliac vein positions related to L5-S1 disc. *Spine (Phila Pa 1976)*. 2000;25:1695-700.
- Quigley TM, Stoney RJ. Arteriovenous fistulas following lumbar laminectomy: the anatomy defined. *J Vasc Surg*. 1985;2:828-33.
- Holscher EC. Vascular and visceral injuries during lumbar-disc surgery. *J Bone Joint Surg Am*. 1968;50:383-93.
- Anda S, Aakhus S, Skaanes KO, Sande E, Schrader H. Anterior perforations in lumbar discectomies. A report of four cases of vascular complications and a CT study of the prevertebral lumbar anatomy. *Spine (Phila Pa 1976)*. 1991;16:54-60.