

4-10-2013

Treatment of Intractable Neurogenic Cough with Cricopharyngeal Myotomy

Anne Lee Durstenfeld, BS
Thomas Jefferson University

Joseph Spiegel, MD
Thomas Jefferson University

Mauritis Boon, MD
Thomas Jefferson University

Follow this and additional works at: <https://jdc.jefferson.edu/otograndrounds>

 Part of the [Otolaryngology Commons](#)

[Let us know how access to this document benefits you](#)

Recommended Citation

Lee Durstenfeld, BS, Anne; Spiegel, MD, Joseph; and Boon, MD, Mauritis, "Treatment of Intractable Neurogenic Cough with Cricopharyngeal Myotomy" (2013). *Department of Otolaryngology - Head and Neck Surgery Presentations and Grand Rounds*. Presentation 14. <https://jdc.jefferson.edu/otograndrounds/14>

This Article is brought to you for free and open access by the Jefferson Digital Commons. The Jefferson Digital Commons is a service of Thomas Jefferson University's [Center for Teaching and Learning \(CTL\)](#). The Commons is a showcase for Jefferson books and journals, peer-reviewed scholarly publications, unique historical collections from the University archives, and teaching tools. The Jefferson Digital Commons allows researchers and interested readers anywhere in the world to learn about and keep up to date with Jefferson scholarship. This article has been accepted for inclusion in Department of Otolaryngology - Head and Neck Surgery Presentations and Grand Rounds by an authorized administrator of the Jefferson Digital Commons. For more information, please contact: JeffersonDigitalCommons@jefferson.edu.

Treatment of Intractable Neurogenic Cough with Cricopharyngeal Myotomy

Anne Lee Durstenfeld, BS; Joseph Spiegel, MD¹; Maurits Boon, MD¹
Thomas Jefferson University, Department of Otolaryngology¹

ABSTRACT

Objectives: Neuropathic cough that is incompletely responsive to medical therapy may be due to cricopharyngeal hypertonicity. The objective was to describe the utility of cricopharyngeal myotomy in alleviating symptoms of intractable neuropathic cough.

Study Design: Retrospective review.

Methods: A retrospective chart review was performed for three patients who underwent cricopharyngeal myotomy for intractable cough. Trigger phenomena, previous evaluation and treatment, and outcomes after surgery, namely patient perception of improvement and medication use after surgery, were assessed and documented.

Results: After cricopharyngeal myotomy, all three patients noted symptomatic improvement and were weaned off medication. Continued improvement was noted at follow up, with a mean length of 22 months (range: 7-36 months).

Conclusions: Cricopharyngeal myotomy may be an alternative treatment for chronic cough in patients for whom workup is negative and medical management, dilation, and botulinum toxin have failed to provide long-term relief.

INTRODUCTION

Chronic cough is a challenging diagnostic and therapeutic entity due to its multiple etiologies. For patients whose cough does not improve with appropriate treatment for common causes, a neuropathic etiology can be considered. This characteristic symptom complex is typically longstanding, has trigger phenomena, is preceded by tickle sensations in the throat, and produces paroxysms of unproductive cough.¹ Bastian et al, who proposed these diagnostic criteria, posit that vagal neuropathy manifested as laryngeal hypertonicity or hypersensitivity may be the cause. Some success has been reported regarding management with anticonvulsants and antidepressants as well as botulinum toxin injections.¹⁻⁶ However, some cases may be refractory to such treatments. In this report, we describe 3 patients diagnosed with neuropathic cough who had incomplete response to medical therapy and were identified as having a trigger at the cricopharyngeus. All 3 patients underwent cricopharyngeal myotomy (CPM) with successful resolution of cough.

METHODS

A retrospective chart review was performed for three patients who underwent cricopharyngeal myotomy for intractable cough. Trigger phenomena, previous evaluation and treatment, and outcomes from their surgery were assessed and documented. Outcome measures included use of medication after surgery and patient perception of improvement.

RESULTS

Table 1 shows the characteristics of the three cases. All were women aged 61-62 who had suffered from unpredictable paroxysms of non-productive coughing for 15-22 years. Each had also been found to have an elevated upper esophageal sphincter pressure on manometry (mean: 184 mmHg, range: 125-219mmHg). None had obtained lasting relief from cough after trials of anti-allergy, anti-reflux, and more traditional therapies. Incomplete or temporary relief was experienced from neuropathic medications and esophageal dilation. Two had experienced temporary improvement for 6 months after botulinum toxin injection into the cricopharyngeus.

Subsequent cricopharyngeal myotomy was performed in all patients. All noted symptomatic improvement and were weaned off medication. Continued improvement was noted at follow up, with a mean length of 22 months (range: 7-36 months).

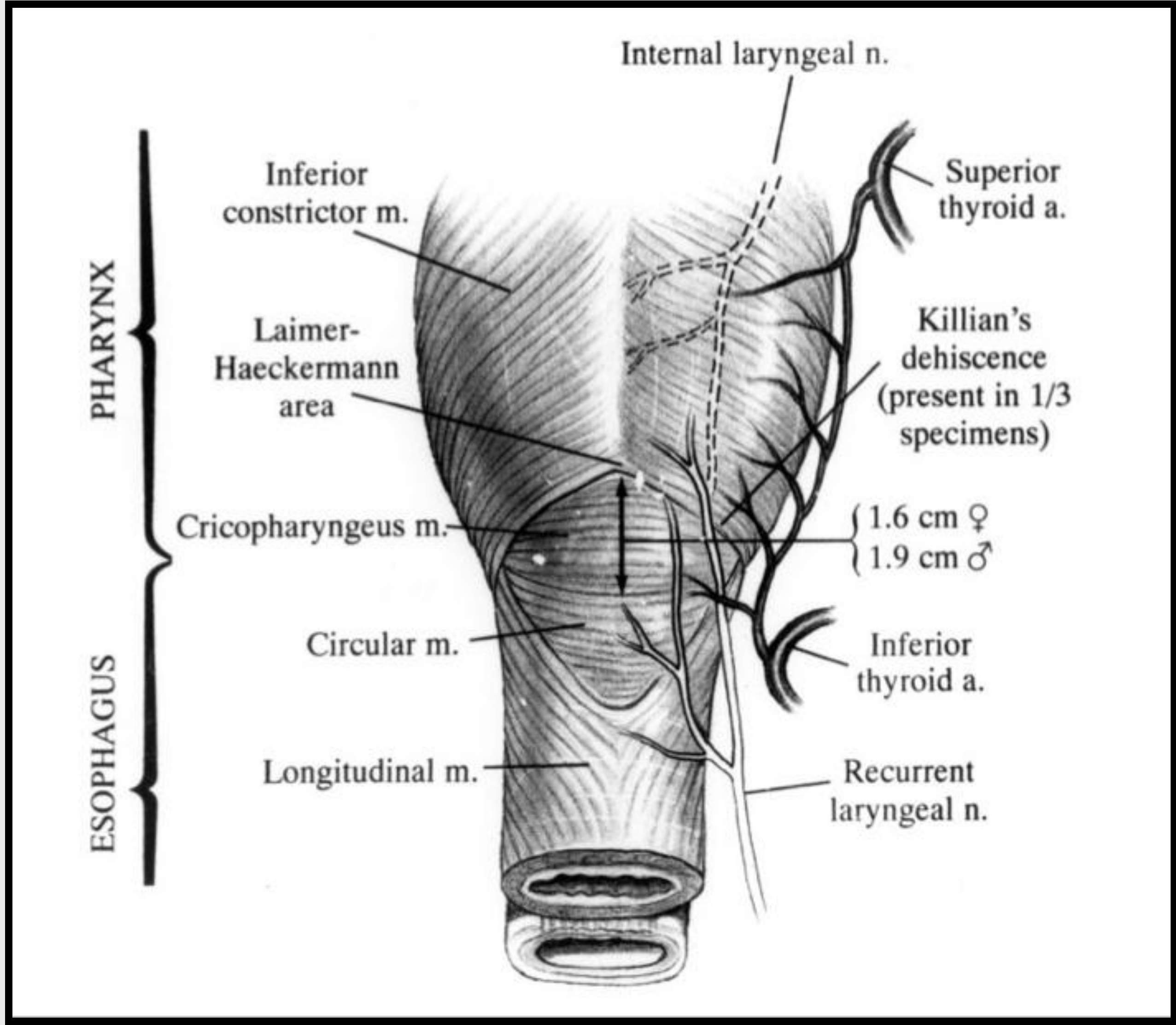


Figure 1. The cricopharyngeus muscle and surrounding structures.
Image from Kelly JH, Management of UES disorders¹⁰

	Case 1	Case 2	Case 3
Duration of cough	15 years	21 years	22 years
PMH	Sinusitis.	Sinusitis, GERD s/p fundoplication, laryngospasm.	Sinusitis s/p sinus surgery, GERD, asthma, allergies, laryngospasm.
Smoking Hx	10 PY	10 PY	Never smoked
Manometry	Increased UES, increased LES resting pressures	Increased UES, decreased LES resting pressures	Increased UES, decreased LES resting pressures
pH measurement	No evidence of GERD	-	No evidence of GERD
Reflux medication	Failed Protonix	Failed Protonix	Failed Prilosec
Allergy medication	Failed Zyrtec	Failed Advair, Singulair, Clarinex	Failed Astelin, Claritin, Tussionex
Neuropathic pain medications	Failed Amitriptyline, nortriptyline, Lyrica	Failed nortriptyline, gabapentin, and Lyrica (ADE)	Failed nortriptyline (ADE), Lyrica, maintained on amitriptyline
Dilation	Once	Once	Once
Botulinum toxin	3 times	Once	-
Surgery	2009	2010	2012
Meds after myotomy	None	None	P.r.n. use of amitriptyline

Table 1. Characteristics of patients.

REFERENCES

1. Bastian RW, Vaidya AM and Delsupehe KG. Sensory Neuropathic Cough: A Common and Treatable Cause of Chronic Cough. Otolaryngology -- Head and Neck Surgery 2006 135: 17
2. Cohen SM, Misono S. Use of specific neuromodulators in the treatment of chronic, idiopathic cough: a systematic review. Otolaryngol Head Neck Surg. 2013 Mar;148(3):374-82.
3. Lee B, Woo P. Chronic cough as a sign of laryngeal sensory neuropathy: diagnosis and treatment. Ann Otol Rhinol Laryngol. 2005 Apr;114(4):253-7.
4. Van de Kerkhove C, Goeminne PC, Van Bleyenbergh P, Dupont LJ. A cohort description and analysis of the effect of gabapentin on idiopathic cough. Cough. 2012 Nov 1;8(1):9.
5. Ryan NM, Birring SS, Gibson PG. Gabapentin for refractory chronic cough: a randomised, double-blind, placebo-controlled trial. Lancet. 2012 Nov 3;380(9853):1583-9.
6. Chu MW, Lieser JD, Sinacori JT. Use of botulinum toxin type A for chronic cough: a neuropathic model. Arch Otolaryngol Head Neck Surg. 2010 May;136(5):447-52.
7. Irwin RS. Unexplained cough in the adult. Otolaryngol Clin North Am. 2010 Feb;43(1):167-80, xi-xii.
8. Chung KF. Chronic 'cough hypersensitivity syndrome': a more precise label for chronic cough. Pulm Pharmacol Ther. 2011 Jun;24(3):267-71.
9. Allen J, White CJ, Leonard R, Belafsky PC. Effect of cricopharyngeus muscle surgery on the pharynx. Laryngoscope. 2010 Aug;120(8):1498-503.
10. Kelly JH. Management of upper esophageal sphincter disorders: indications and complications of myotomy. Am J Med. 2000 Mar 6;108 Suppl 4a:43S-46S.

DISCUSSION

In the majority of patients, systematic evaluation and optimal therapy will lead to successful resolution of chronic cough.⁷ However, in patients for whom thorough work-up and empirical treatment have not produced a solution, several models have been described. These include irritable larynx syndrome, sensory laryngeal neuropathic cough, and post-viral vagal neuropathy, which fall under the newly coined umbrella term of chronic cough hypersensitivity syndrome.⁸ Just as other neuropathies may manifest as paralysis or hypersensitivity to stimuli, vagal neuropathy may present as dysphonia, dysphagia, paresis, pain, laryngospasm, or cough. Neuropathy of motor branches may lead to symptoms of dysphagia and dysphonia while that of sensory branches produces pain and decreased cough threshold.

Bastian et al proposed criteria for a sensory neuropathic model of intractable persistent cough, including irritable cervical and laryngeal sensations, severe attacks of non-productive cough that may be triggered or occur spontaneously, and exclusion criteria based on psychogenic factors such as secondary gain and abrupt onset or resolution. Based on this model, 75% of their patients were treated successfully with amitriptyline.¹ By treating paroxysmal chronic cough as a neuropathic pain disorder, Lee and Woo were able to achieve symptomatic relief in 68% of patients using gabapentin, while Van de Kerkhove et al used gabapentin to decrease cough severity in 20 of 35 patients.^{3,4} A randomized controlled trial by Ryan et al showed clinically and statistically significant improvement with gabapentin in 84% of patients compared to 40% on placebo; however, cough returned after cessation of therapy.⁵ Chu et al attributed the decreased threshold for cough stimulation and increased laryngeal tone to hyperexcitable sensory and motor pathways and aimed to inhibit neurogenic inflammation and hypertonicity using botulinum toxin injection of the thyroarytenoid muscles. They reported complete resolution of cough in a case series of 4 patients.⁶

In this paper, we report on the use of open cricopharyngeal myotomy to treat chronic cough. The rationale behind targeting the cricopharyngeus came from the observation that these patients identified a trigger at the approximate level of the cricopharyngeus and had elevated UES resting pressures on manometry. Additionally, each had previously obtained improvement in cough from dilation and/or botulinum toxin injection of the UES, which can be considered alternatives to cricopharyngeal myotomy. However, relief was self-limited and therefore cricopharyngeal myotomy was offered as a possible permanent solution. Notably, all patients experienced marked improvement. Our experience with cricopharyngeal myotomy suggests that successful treatment of neuropathic cough can be achieved by relieving pharyngeal hypertonicity in select patients. The recent literature on endoscopic cricopharyngeal myotomy suggests that the technique may also be a viable consideration for this population. However, this would require further study.

CONCLUSION

In conclusion, cricopharyngeal myotomy may be an alternative treatment for chronic cough in patients for whom workup is negative and medical management, dilation, and botulinum toxin have failed to provide long-term relief. However, further study is warranted in this patient population to support this assertion.

CONTACT

Anne Lee Durstenfeld, BS
Thomas Jefferson University
Department of Otolaryngology – Head and Neck Surgery
Email: anne.lee@jefferson.edu
Phone: 215.955.5208
Website: <http://www.jefferson.edu/oto>