
On the anatomy of the breast, by Sir Astley
Paston Cooper, 1840

Rare Medical Books

1840

On the anatomy of the breast - Plate III: This plate is intended to show the cutaneous structures of the breast

Sir Astley Paston Cooper , Bart.

Follow this and additional works at: <https://jdc.jefferson.edu/cooper>



Part of the [History of Science, Technology, and Medicine Commons](#)

[Let us know how access to this document benefits you](#)

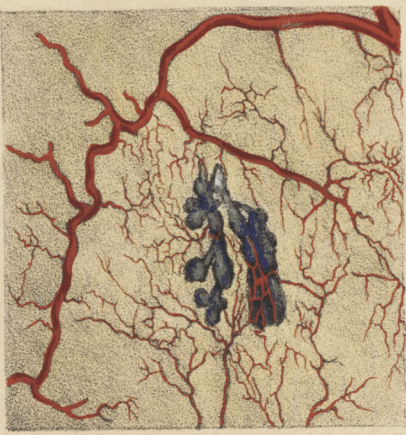Recommended Citation

Cooper, Sir Astley Paston , Bart., "On the anatomy of the breast - Plate III: This plate is intended to show the cutaneous structures of the breast" (1840). *On the anatomy of the breast, by Sir Astley Paston Cooper, 1840*. Paper 13.

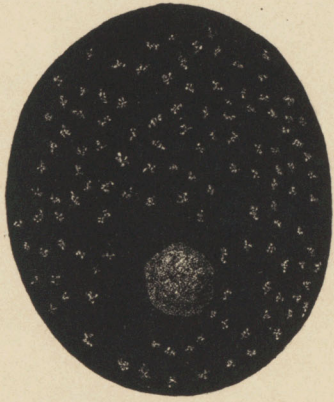<https://jdc.jefferson.edu/cooper/13>

This Article is brought to you for free and open access by the Jefferson Digital Commons. The Jefferson Digital Commons is a service of Thomas Jefferson University's [Center for Teaching and Learning \(CTL\)](#). The Commons is a showcase for Jefferson books and journals, peer-reviewed scholarly publications, unique historical collections from the University archives, and teaching tools. The Jefferson Digital Commons allows researchers and interested readers anywhere in the world to learn about and keep up to date with Jefferson scholarship. This article has been accepted for inclusion in *On the anatomy of the breast, by Sir Astley Paston Cooper, 1840* by an authorized administrator of the Jefferson Digital Commons. For more information, please contact: JeffersonDigitalCommons@jefferson.edu.

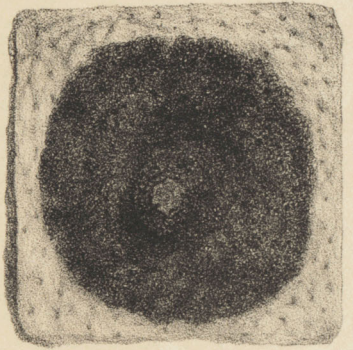
9



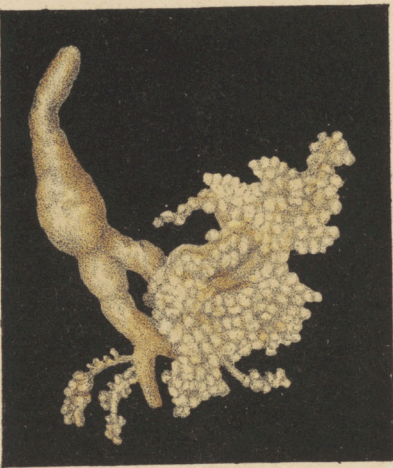5



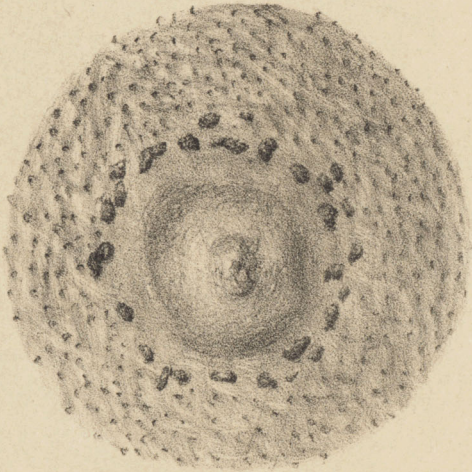
3




11



6



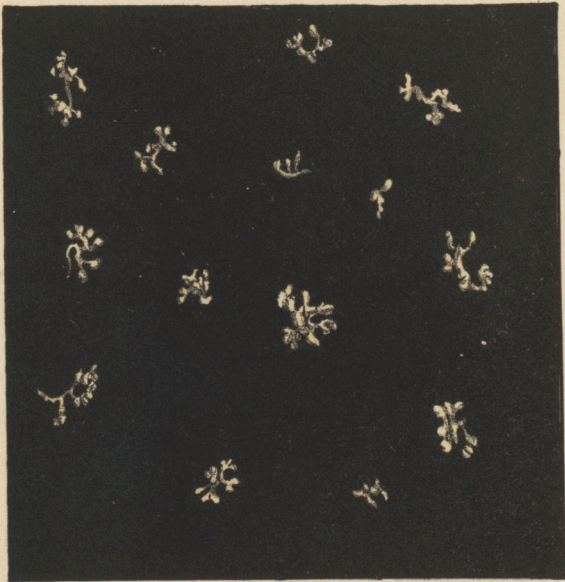1




10



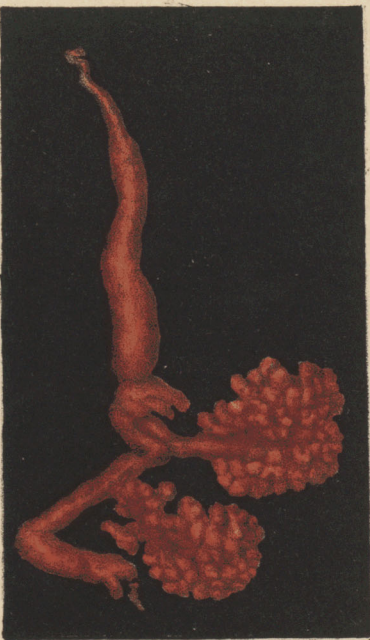7



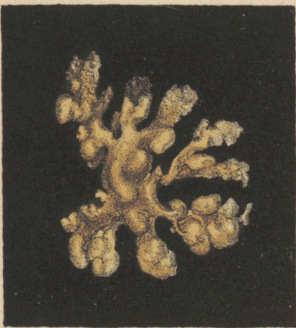2



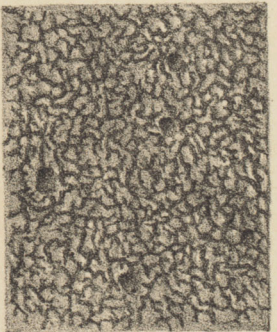
12



8



4



John Holt del et lithog.

J. Gray Printer to the Queen.

PLATE III.

This Plate is intended to show the cutaneous structures of the Breast.

- Fig. 1.—The inner side of the cuticle of the nipple, areola, and surrounding breast, and the folds which it forms to sink into the cutis. In the centre, under the areola, the reticular arrangement of the rete mucosum is seen on the inner side of the cuticle, and forming a circle.
- Fig. 2.—Rete mucosum seen on the inner side of the *cuticle* of an African. (Fifteen times magnified.)
- Fig. 3.—Rete mucosum on the *cutis* of the black (magnified fifteen times.)
- Fig. 4. Rete mucosum on the nipple and areola of the black (natural size). The white cutis seen around it with dark spots where the rete mucosum enters the perspiratory pores.
- Fig. 5. Nipple and areola, with numerous cutaneous glands, filled with yellow injection.
- Fig. 6. Inner side of the nipple, areola, and skin of the breast. Around the nipple, placed in a circle, the glands of the tubercles appear on the inner side of the cutis vera of the areola, and which form openings through the skin upon the surface of the areola.
- Fig. 7. The glands surrounding the nipple filled with yellow injection, and magnified six times.
- Fig. 8. One of the glands magnified twenty times.
- Fig. 9. A gland filled with blue injection, and showing the arteries passing to it.
- Fig. 10. The tubercles surrounding the nipple injected and drawn of their natural size.

Fig. 11. A tubercle filled with yellow injection, and twenty-three times magnified.

Fig. 12. A tubercle filled with red injection, and magnified twenty times.

These are the tubercles which have been supposed by anatomists to produce milk, and to have communication with the lactiferous tubes, from which, however, they are entirely separate and distinct. They secrete a mucous fluid, which has more the appearance of gruel than milk.

