

---

On the anatomy of the breast, by Sir Astley  
Paston Cooper, 1840

Rare Medical Books

---

1840

## On the anatomy of the breast - Plate I: The nipple in its changes

Sir Astley Paston Cooper , Bart.

Follow this and additional works at: <https://jdc.jefferson.edu/cooper>



Part of the [History of Science, Technology, and Medicine Commons](#)

**[Let us know how access to this document benefits you](#)**

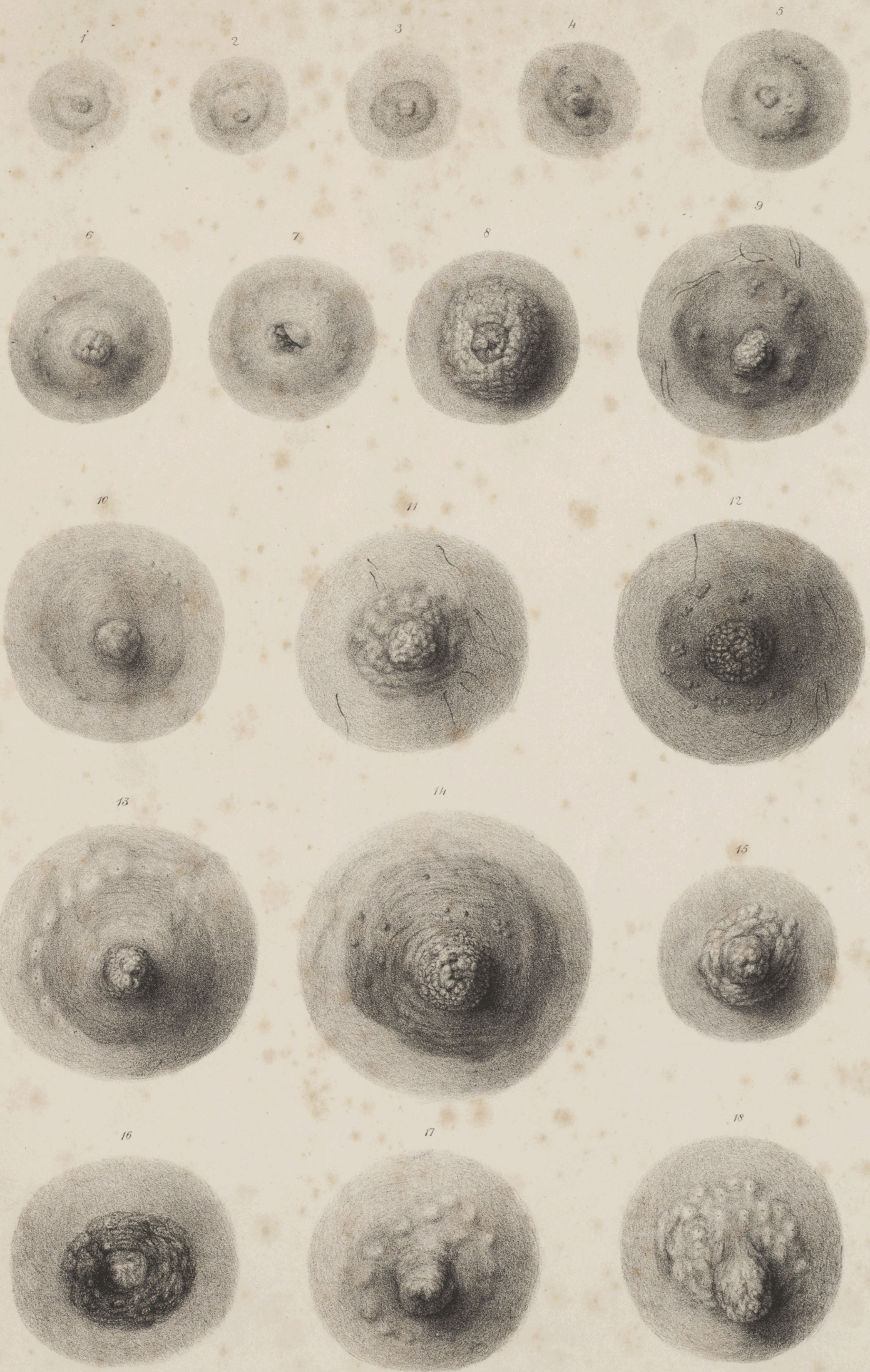
---

### Recommended Citation

Cooper, Sir Astley Paston , Bart., "On the anatomy of the breast - Plate I: The nipple in its changes" (1840).  
*On the anatomy of the breast, by Sir Astley Paston Cooper, 1840*. Paper 11.  
<https://jdc.jefferson.edu/cooper/11>

This Article is brought to you for free and open access by the Jefferson Digital Commons. The Jefferson Digital Commons is a service of Thomas Jefferson University's [Center for Teaching and Learning \(CTL\)](#). The Commons is a showcase for Jefferson books and journals, peer-reviewed scholarly publications, unique historical collections from the University archives, and teaching tools. The Jefferson Digital Commons allows researchers and interested readers anywhere in the world to learn about and keep up to date with Jefferson scholarship. This article has been accepted for inclusion in On the anatomy of the breast, by Sir Astley Paston Cooper, 1840 by an authorized administrator of the Jefferson Digital Commons. For more information, please contact: [JeffersonDigitalCommons@jefferson.edu](mailto:JeffersonDigitalCommons@jefferson.edu).







## PLATE I.

### *The Nipple in its Changes.*

- Fig. 1. Breast of a girl two years of age. Nipple, areola, and point of the nipple just evolving.
- Figs. 2, 3, 4. The nipple larger, being much more evolved, at four, at six, and at nine years of age.
- Fig. 5. At twelve years. Nipple, areola, and tubercles evolving.
- Fig. 6. At fourteen years. Nipple wrinkled and papillous, areola more extended, tubercles enlarged.
- Fig. 7. At fifteen years. Cleft in the nipple, where the orifices of the lactiferous tubes afterwards appear.
- Fig. 8. At sixteen years. Nipple and areola papillous and much wrinkled.
- Fig. 9. At seventeen years. Nipple with considerable papillæ, areola extended, tubercles of large size, hairs growing from the skin around the areola.
- Fig. 10. At twenty years.—Nipple, areola, and tubercles shown.
- Fig. 11. At twenty-four years. Woman who had borne a child. Nipple papillous, tubercles enlarged, areola contracted in its diameter, several hairs appearing.
- Fig. 12. Age twenty-six. Pregnancy. Nipple very papillous, areola enlarged, tubercles increased, hairs appear.
- Fig. 13. Lactation continued for nine months in a woman aged twenty-eight. Papillæ of the nipple smooth, areolar tubercles with their openings seen at the margin of the areola. The tubercles did not emit milk when pressed.

- Fig. 14. At twenty-eight years. Lactation three weeks after delivery, nipple extremely papillous, areola much extended measuring two inches, tubercles appear upon various parts of the areola. Milk could not be pressed from the tubercles when the orifices of the nipple were closed and the breast compressed.
- Fig. 15. At thirty-two years. Sterile woman. Nipple and areola wrinkled, the diameter of the latter small, cleft in the centre of the nipple.
- Fig. 16. At forty years. After lactation. The woman has had nine children. Nipple with a cleft, areola considerably contracted, tubercles prominent, but huddled together.
- Fig. 17. At forty-seven years. Nipple long and truncated, large tubercles at the margin of the areola. Has suckled several children.
- Fig. 18. Old age. After having had children. Nipple elongated, orifices of numerous open tubercles, papillæ of the nipple large, and hanging in a kind of foliage.
- Figs. 8, 15, 18, were drawn from the dead subject, all the others were delineated from the living.
-