

11-18-2021

Native valve endocarditis complicated by abscess formation caused by *Rothia mucilaginosa*


S Haddad
Thomas Jefferson University

Y Saade
American University of Beirut

B Ramlawi
Lankenau Medical Center

B Kreidieh
Lankenau Medical Center

B Gilbert
Lankenau Medical Center
Follow this and additional works at: <https://jdc.jefferson.edu/didem>

 Part of the [Cardiology Commons](#), and the [Infectious Disease Commons](#)
See next page for additional authors

[Let us know how access to this document benefits you](#)

Recommended Citation

Haddad, S; Saade, Y; Ramlawi, B; Kreidieh, B; Gilbert, B; and Rao, S, "Native valve endocarditis complicated by abscess formation caused by *Rothia mucilaginosa*" (2021). *Division of Infectious Diseases and Environmental Medicine Faculty Papers*. Paper 10.
<https://jdc.jefferson.edu/didem/10>

This Article is brought to you for free and open access by the Jefferson Digital Commons. The Jefferson Digital Commons is a service of Thomas Jefferson University's [Center for Teaching and Learning \(CTL\)](#). The Commons is a showcase for Jefferson books and journals, peer-reviewed scholarly publications, unique historical collections from the University archives, and teaching tools. The Jefferson Digital Commons allows researchers and interested readers anywhere in the world to learn about and keep up to date with Jefferson scholarship. This article has been accepted for inclusion in Division of Infectious Diseases and Environmental Medicine Faculty Papers by an authorized administrator of the Jefferson Digital Commons. For more information, please contact: JeffersonDigitalCommons@jefferson.edu.

Authors

S Haddad, Y Saade, B Ramlawi, B Kreidieh, B Gilbert, and S Rao



Case report

Native valve endocarditis complicated by abscess formation caused by *Rothia mucilaginosa*



S. Haddad^{a,*}, Y. Saade^b, B. Ramlawi^c, B. Kreidieh^d, B. Gilbert^e, S. Rao^e

^a Infectious Disease division, Thomas Jefferson University Hospital, Philadelphia, PA, United States

^b Department of Biology, American University of Beirut, Beirut, Lebanon

^c Cardiothoracic Surgery Division, Lankenau Medical Center, Wynnewood, PA, United States

^d Cardiology Division, Lankenau Medical Center, Wynnewood, PA, United States

^e Infectious Disease Division, Lankenau Medical Center, Wynnewood, PA, United States

ARTICLE INFO

Article history:

Received 4 November 2021

Received in revised form 16 November 2021

Accepted 17 November 2021

Available online xxxx

Keywords:

R.mucilaginosa

Endocarditis

Native valve

Aortic root abscess

ABSTRACT

Rothia mucilaginosa is increasingly recognized as an emerging pathogen associated with endocarditis. It has mostly been reported a causative agent for prosthetic valve endocarditis. The previously reported cases of native valve endocarditis caused by this organism only required medical treatment with no surgical intervention. We report a case of *R. mucilaginosa* native valve endocarditis complicated by abscess formation requiring surgical intervention and review the literature of native valve endocarditis caused by this organism.

© 2021 The Authors. Published by Elsevier Ltd.
CC_BY_NC_ND_4.0

Introduction

Rothia spp are gram positive pleomorphic bacteria [1], first reported to infect humans in 1975 [2]. Among the different species of *Rothia*, three have been described to be pathogenic for humans: *R. aeria*, *R. dentocariosa*, *R. mucilaginosa* [3]. The latter three species grow fast under aerobic conditions producing whitish convex colonies while they produce filamentous transparent colonies under anaerobic conditions [3].

Rothia mucilaginosa was formerly known as *Staphylococcus salivarius*, and *Stomatococcus mucilaginosus* [4]. It is a normal inhabitant of the human oral cavity and respiratory tract [5]. Infections with this pathogen usually affect immunocompromised hosts such as patients with cancer, HIV, diabetes mellitus and chronic liver disease [6,7]. It can also affect immunocompetent hosts with certain risk factors such as cardiac valve disease/presence of prosthetic valves, indwelling catheters or IV drug users [4]. It is mostly reported to be involved in respiratory tract infections [8], soft tissue infections [5], meningitis [9], endocarditis [3,4], bone and joint infections [1], central nervous system infections [10] and bacteremia [11].

When infecting cardiac valves, this organism is mostly reported to cause prosthetic valve endocarditis with rare reports of native

valve infections. A case series of infective endocarditis caused by *R.mucilaginosa* shows that most reported native valve infections recovered with antibiotics alone while most patient with prosthetic valve infections required surgical valve replacement [9]. We report a rare case of native valve *Rothia mucilaginosa* endocarditis complicated by aortic root abscess requiring surgical intervention in addition to antibiotic therapy.

Case

An 80-year old man with a past medical history of coronary artery disease, mild intermittent asthma and moderate aortic stenosis presented to the emergency department for evaluation of intermittent fevers of three weeks duration. He reported that the fevers were low grade occurring randomly at no set time of the day. He had associated lethargy, generalized weakness, decreased oral intake and intermittent headache. He denied chest pain, palpitations, shortness of breath, joint pain, or rash. He reported having dental work done 2 months prior to presentation. He denied recent travel or sick contacts, intravenous drug use, recent hospitalization, or antibiotic use.

On arrival, the patient was noted to have low grade fever with a temperature of 100.4°F, tachycardia with a heart rate of 95 beats/minute and was normotensive. On exam, he was noted to have poor dentition and a loud harsh systolic murmur consistent with aortic stenosis. Lung and abdominal exams were unremarkable. No focal

* Corresponding author.

Table 1
Laboratory workup.

	Reference range	Admission day	Day 2	Discharge day
Hemoglobin	11.8–15.7 g/dL	11.6	11.1	9.0
White Blood Cells	3.80–10.50 K/uL	13.4	11.6	13.3
Platelet count	150–369 K/uL	247	251	90
BUN	8–20 mg/dL	11	8	11
Creatinine	0.6–1.1 mg/dL	1.0	0.9	0.9
Sodium	136–144 mEq/L	136	137	138
Potassium	3.6–5.1 mEq/L	3.9	3.6	4.5
Aspartate aminotransferase	15–41 IU/L	72	62	27
Alanine aminotransferase	11–54 IU/L	111	108	41
Alkaline phosphatase	35–126 IU/L	70	68	63
C-reactive protein	< =7.48 mg/L	102.3	69.4	
Erythrocyte sedimentation rate	0–20 mm/h	77	67	
Troponin	< 0.05 ng/mL	0.11	0.06	

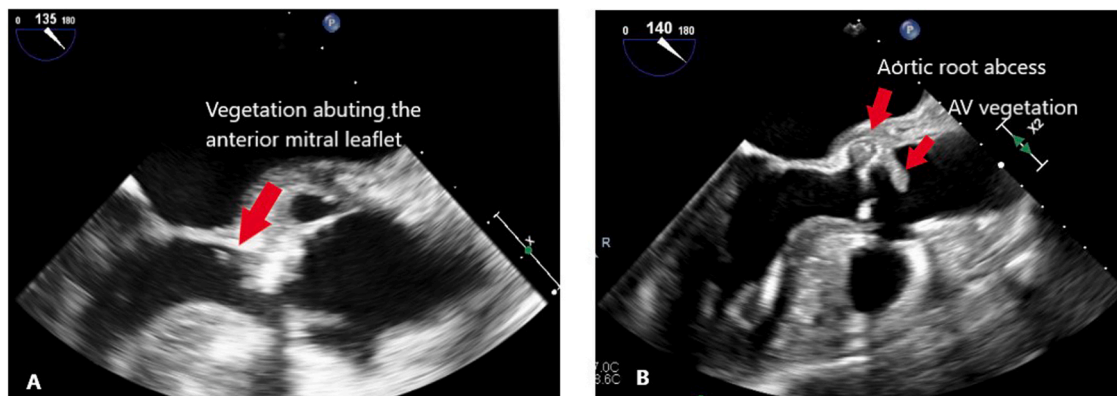


Fig. 1. Transesophageal echocardiogram. A: Aortic valve vegetation extending into the LVOT and abutting the anterior mitral leaflet. B: Aortic valve vegetation with aortic root abscess.

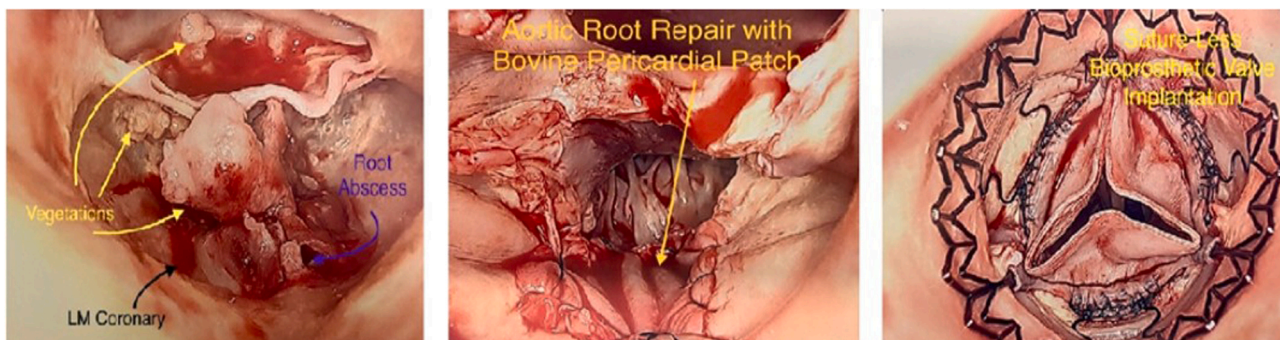


Fig. 2. A: Aortic valve vegetation with aortic root abscess. B: Aortic root repair with insertion of bovine pericardial patch. C: Aortic valve post suture-less bioprosthetic valve implantation (Corcym Perceval prosthesis).

neurologic signs were found. He had no evidence of heart failure or stigmata suggestive of underlying endocarditis. Initial laboratory testing was pertinent for leukocytosis, abnormal liver function tests, elevated troponin and inflammatory markers [Table 1]. A urine analysis, hepatitis and viral panel were done and were negative. A chest X ray was normal. CT abdomen and pelvis with intravenous contrast revealed a 3.3 × 3.5 cm abdominal aortic aneurysm, extensive coronary artery calcification but no definite source of infection. Two sets of blood cultures were obtained, and results came back positive for non-staphylococcus gram positive cocci later

identified as *Rothia mucilaginosa*. The patient was started on ceftriaxone 2 g daily in addition to IV vancomycin. Repeat blood cultures cleared on hospital day 2.

Initial transthoracic echocardiogram showed progressive mitral stenosis, regurgitation with a small mobile echo density attached to the anterior mitral annulus in addition to severe aortic stenosis. A transesophageal echocardiogram was done showing an echo dense highly mobile oscillating structure attached to the left aortic valve cusp between the noncoronary and left coronary cusp measuring 1 × 1.5 cm consistent with an aortic valve vegetation extending into

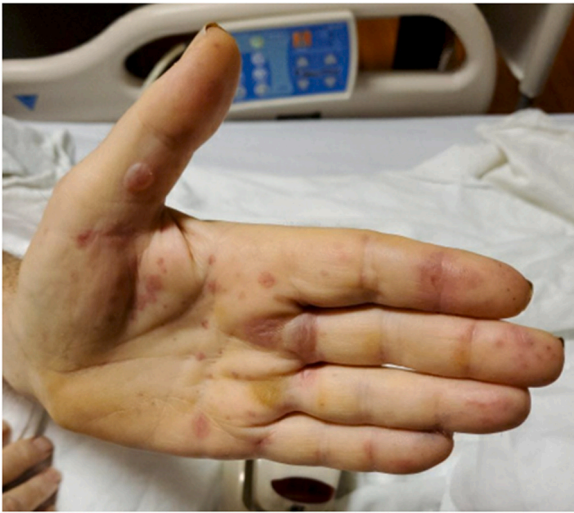

Fig. 3. Bullous eruption of patient's left hand.

the LVOT and abutting the anterior mitral leaflet in addition to an aortic root abscess with loculations and early dehiscence of the base of the aortic valve [Fig. 1]. During his stay, patient complained of recurrent headaches and an MRI brain was done showing at least two foci of septic emboli in the right occipital lobe and right parietal lobe with a focus of subarachnoid hemorrhage in the left parietal sulcus.

On day 10 of hospitalization, patient underwent aortic root debridement and repair with a pericardial patch, mitral valve repair with removal of vegetations noted on the anterior leaflet and aortic valve replacement with a suture-less bovine prosthetic valve [Fig. 2]. The patient had an extensive abscess cavity involving the annulus, superior aspect of the anterior leaflet of the mitral valve and extending toward the left main coronary ostium. After thorough debridement, obliteration of the abscess cavity and reconstruction was performed with bovine pericardial patch [12]. Selection of a self-expanding suture-less prosthesis was intentional to minimize suture material in the setting of infected space. Pathology of the native aortic valve showed acute inflammatory infiltrates and necrosis with tissue cultures negative to date. His course was complicated by atrial fibrillation requiring cardioversion. On post-operative day 4, he developed a blister eruption on the soles of his feet, bilateral hands, arms and abdomen [Fig. 3]. This was attributed to possible vancomycin induced IgA dermatitis and the drug was discontinued with

the patient's skin findings resolving prior to discharge. The patient was discharged on postoperative day 8 without deficits. He was continued on ceftriaxone 2 g daily for a total of 42 days.

Discussion

Rothia mucilaginosa is an organism often difficult to identify secondary to taxonomic confusion and misidentification with other gram-positive organisms such as staphylococcus, streptococcus or micrococcus [13]. *Rothia* infections are classically described as opportunistic diseases and a systematic review published in 2020 looking at *Rothia spp* included 61% of infected patients being immunocompromised with tooth decays reported in 28% of patients with *Rothia* infection [3]. In addition to underlying structural valvular disease, recent dental work was likely a major risk factor for our patient to acquire this particular infection.

Table 2 describes seven patients reported in the literature with native valve infections caused by *Rothia mucilaginosa* [9,14–19] in addition to our case. Most reported cases occurred in patients with underlying valve pathologies [9,14–16,19] or underlying risk factors such as intravenous drug use [17–19]. Six out of seven patients were treated with antibiotics alone [9,14–18] and all but one patient had a favorable outcome [18]. One of the 7 patients required surgical valve replacement [19]. We report here a rare case of native valve endocarditis secondary to *Rothia mucilaginosa* complicated by abscess formation and requiring two valve replacements.

There are no guidelines to assist in antibiotic selection in the treatment of invasive *Rothia* infections [12] and the treatment regimen is not clearly determined. The organism is noted to be generally susceptible to penicillin, ampicillin, cefotaxime, imipenem, rifampin, and vancomycin [4]. In the literature, it has previously been described to be frequently resistant to clindamycin, aminoglycosides, trimethoprim sulfamethoxazole [4,20] and occasionally to penicillin [19]. In our reported case, the organism was susceptible to penicillin (MIC < 0.120), Vancomycin (MIC = 1) and levofloxacin (MIC 0.5). Our isolated strain was intermediately susceptible to clindamycin (MIC 1) and erythromycin (MIC 2) and resistant to trimethoprim sulfamethoxazole (MIC > 4).

Rothia mucilaginosa is increasingly recognized as an emerging pathogen causing infections in both immunocompromised and immunocompetent hosts. It has mostly been described to cause prosthetic valve endocarditis [4] requiring both antibiotic therapy and surgical reconstruction. It, however, can also cause native valve endocarditis with reports of more aggressive disease emerging as is the case with our patient, requiring surgical intervention.

Table 2

Eight cases of *Rothia mucilaginosa* native valve endocarditis reported in the literature and our case.

Reference	Age (years)	Sex	Underlying disease/risk factor	Diagnosis	Treatment
13	63	M	Rheumatic heart disease, Moderate MS and MR	Native MV endocarditis	IV PCN x 5 weeks
14	34	F	IVDU, MV prolapse	Native MV endocarditis	IV PCN x 6 weeks
15	46	M	MV prolapse	Native MV endocarditis	PCN and gentamycin x 4 weeks
9	44	M	MV prolapse and MR	Native MV endocarditis	IV PCN x 6 weeks
16	46	M	IVDU	Native MV endocarditis	IV vancomycin x 6 weeks
17	79	M	none	Native AV,MV endocarditis	Rifampin+vancomycin (expired)
18	35	M	IVDU,endocarditis, AI/MI	Native AV endocarditis	IV vancomycin x 4 weeks + valve replacement
Our case	60	M	AS	Native AV,MV endocarditis	IV CTX x 4 weeks + valve replacement

Ethical approval

No study was performed on volunteers. This is a descriptive case report.

Consent

Informed consent was obtained from the patient for publication of this case report and accompanying images.

Author contribution

Sara Haddad: writing and editing. **Youmna Saade:** Literature review and background search. **Basel Ramlawi:** writing and editing. **Bahij Kreidieh:** writing and editing. **Brett Gilbert:** writing and editing. **Shilpa Rao:** writing and editing.

Acknowledgments and funding

B. Ramlawi is a consultant and advisory board member for Medtronic, Boston Scientific, Corcym and AtriCure. The rest of the authors report no conflict of interest. No source of funding to be declared.

References

- [1] Mahobia N, Chaudhary P, Kamat Y. *Rothia* prosthetic knee joint infection: report and mini-review. *N Microbes N Infect* 2013;1(1):2–5.
- [2] Scharfen J. Untraditional glucose fermenting actinomycetes as human pathogens. Part II: *Rothia dentocariosa* as a cause of abdominal actinomycosis and a pathogen for mice. *Zent Bakteriolog Orig A* 1975;233(1):80–92.
- [3] Franconieri F, Join-Lambert O, Creveuil C, et al. *Rothia* spp. infective endocarditis: a systematic literature review. *Infect Dis Now* 2021;51(3):228–35.
- [4] Bruminhent J, Tokarczyk MJ, Jungkind D, DeSimone Jr. JA. *Rothia mucilaginosa* prosthetic device infections: a case of prosthetic valve endocarditis. *J Clin Microbiol* 2013;51(5):1629–32.
- [5] Tomczak H, Bilska-Stokłosa J, Osmola K, et al. *Rothia mucilaginosa*, rarely isolated pathogen as an etiological factor of infection of soft tissues in young, healthy woman. *Post Hig Med Dosw* 2013;67.
- [6] McWhinney PH, Kibbler CC, Gillespie SH, et al. *Stomatococcus mucilaginosa*: an emerging pathogen in neutropenic patients. *Clin Infect Dis* 1992;14(3):641–6.
- [7] Gruson D, Hilbert G, Pigneux A, et al. Severe infection caused by *Stomatococcus mucilaginosa* in a neutropenic patient: case report and review of the literature. *Hematol Cell Ther* 1998;40(4):167–9.
- [8] Maraki S, Papadakis IS. *Rothia mucilaginosa* pneumonia: a literature review. *Infect Dis J* 2015;47(3):125–9. Mar 4.
- [9] Pérez-Vega C, Narváez J, Calvo G, Castro-Bohorquez FJ, Falgueras MT, Vilaseca-Momplet J. Cerebral mycotic aneurysm complicating *Stomatococcus mucilaginosa* infective endocarditis. *Scand J Infect Dis* 2002;34(11):863–6.
- [10] Goldman M, Chaudhary UB, Greist A, Fausel CA. Central nervous system infections due to *Stomatococcus mucilaginosa* in immunocompromised hosts. *Clin Infect Dis* 1998;27(5):1241–6.
- [11] Mitchell PS, Huston BJ, Jones RN, Holcomb L, Koontz FP. *Stomatococcus mucilaginosa* bacteremias: typical case presentations, simplified diagnostic criteria, and a literature review. *Diagn Microbiol Infect Dis* 1990;13(6):521–5.
- [12] Bedeir K, Reardon M, Ramlawi B. Infective endocarditis: perioperative management and surgical principles. *J Thorac Cardiovasc Surg* 2014;147(4):1133–41.
- [13] Faiad G, Singh M, Narasimhan A, Mendez M, Sharma S, Nassar N. *Rothia mucilaginosa* life threatening infections in non-neutropenic hosts. *Open J Intern Med* 2011;1:68–71.
- [14] Rubin SJ, Lyons RW, Murcia AJ. Endocarditis associated with cardiac catheterization due to a Gram-positive coccus designated *Micrococcus mucilaginosa incertae sedis*. *J Clin Microbiol* 1978;7(6):546–9.
- [15] Relman DA, Ruoff K, Ferraro MJ. *Stomatococcus mucilaginosa* endocarditis in an intravenous drug abuser. *J Infect Dis* 1987;155(5):1080–1.
- [16] Prag J, Kjølner E, Espersen F. *Stomatococcus mucilaginosa* endocarditis. *Eur J Clin Microbiol* 1985;4(4):422–4.
- [17] Abdelmaseih R, Abdelmasih R, Faluk M, Hasan M. Uncommon pathogen in an unexpected host: a rare case of *rothia mucilaginosa* infective endocarditis in an immunocompetent patient without an underlying valvular disease. *Cureus* 2021;13(6).
- [18] Castaño MA, Gascón F, Sánchez E, et al. Bacteriemia por *Stomatococcus mucilaginosa* en un paciente de riesgo. *Rev Diag. Biol.* 2001;50(3):147–8.
- [19] Pinsky RL, Piscitelli V, Patterson JE. Endocarditis caused by relatively penicillin-resistant *Stomatococcus mucilaginosa*. *J Clin Microbiol* 1989;27(1):215–6.
- [20] Kaasch AJ, Saxler G., Seifert H. Septic arthritis due to *Rothia mucilaginosa*; 2011 Feb;39(1):81–82.