

4-1-2012

Balloon-occluded retrograde transvenous obliteration for the treatment of gastric varices.

Alia S Dadabhai
Thomas Jefferson University

Jonathan M Fenkel
Thomas Jefferson University

Daniel B Brown
Thomas Jefferson University

Loren Laine
Yale University School of Medicine and V.A. Connecticut Healthcare System

Follow this and additional works at: https://jdc.jefferson.edu/gastro_hepfp



Part of the [Gastroenterology Commons](#), and the [Hepatology Commons](#)

[Let us know how access to this document benefits you](#)

Recommended Citation

Dadabhai, Alia S; Fenkel, Jonathan M; Brown, Daniel B; and Laine, Loren, "Balloon-occluded retrograde transvenous obliteration for the treatment of gastric varices." (2012). *Division of Gastroenterology and Hepatology Faculty Papers*. Paper 8.

https://jdc.jefferson.edu/gastro_hepfp/8

This Article is brought to you for free and open access by the Jefferson Digital Commons. The Jefferson Digital Commons is a service of Thomas Jefferson University's [Center for Teaching and Learning \(CTL\)](#). The Commons is a showcase for Jefferson books and journals, peer-reviewed scholarly publications, unique historical collections from the University archives, and teaching tools. The Jefferson Digital Commons allows researchers and interested readers anywhere in the world to learn about and keep up to date with Jefferson scholarship. This article has been accepted for inclusion in Division of Gastroenterology and Hepatology Faculty Papers by an authorized administrator of the Jefferson Digital Commons. For more information, please contact: JeffersonDigitalCommons@jefferson.edu.

As submitted to:

Hepatology

And later published as:

**Balloon-occluded retrograde transvenous obliteration
for the treatment of gastric varices**

Volume 55, Issue 4, pages 1301–1304, April 2012

DOI: 10.1002/hep.25635

**Alia S. Dadabha, Jonathan M. Fenkel, Daniel B.
Brown, Loren Laine**

Editors' Note

Clinical Perspectives in Hepatology aims to engage two experts with opinions supporting differing perspectives on the management of a case. Typically, the case represents an area of debate or evolving practice in clinical hepatology.

The patient presented below gives us the opportunity to discuss balloon-occluded retrograde transvenous obliteration (BRTO) for treatment of gastric varices. Although described since the mid-1990s and accepted as effective therapy, particularly in Japan, BRTO is used sporadically in the United States and Europe. In fact, it is not mentioned in the U.S. (AASLD) or European (EASL/Baveno V) guidelines. Hopefully, increased awareness of and expertise in this modality will generate the evidence-based data needed to establish the role and safety of BRTO in patients with gastric varices.

Drs. Alia Dadabhai, Jonathan Fenkel, and Daniel Brown: Case Presentation

A 50-year-old male with hepatitis C and alcohol related cirrhosis was hospitalized with his first upper gastrointestinal bleed secondary to isolated large gastric fundal varices, as confirmed by endoscopy. The patient was stabilized with conservative treatment. Magnetic resonance imaging (MRI) revealed thrombosis of the main, left, and right portal veins, with patency of the splenic vein and a spontaneous splenorenal shunt (Panels A and B). As endoscopic N-butyl-2-cyanoacrylate injection was not available, and given the presence of portal vein thrombosis and a

spontaneous splenorenal shunt, an elective balloon-occluded retrograde transvenous obliteration (BRTO) procedure was selected over a transjugular intrahepatic portosystemic shunt (TIPS).

Using a right groin approach, the splenorenal shunt was catheterized and an 11-mm occlusion balloon (Python, Applied Medical, Rancho Santa Margarita, CA) inflated in the venous outflow. The varix was selectively catheterized back to the point of communication with the portal venous system. Foam sclerosant consisting of 3 parts air, 2 parts 3% Sotradecol (Angiodynamics, Queensbury, NY) and 1 part Ethiodol (Guerbet, Roissy, France) was mixed and approximately 13 mL injected during catheter withdrawal, filling the varix and outflow vein back to the level of the balloon (panel C). Balloon inflation was maintained for 3 hours at which point the patient was restudied and satisfactory occlusion was confirmed. The patient was discharged without further bleeding and 3-month follow-up computed tomography (CT) confirmed collapse of the varices (panel D).

Dr. Laine: The Endoscopist's Perspective

The Endoscopist's Conventional Approach

Endoscopic therapy with tissue adhesive (e.g., Nbutyl-cyanoacrylate [BCA]) is recommended for acute treatment of bleeding from isolated gastric varices in the fundus (IGV1), present in the patient described, and antrum (IGV2), and from type 2 gastroesophageal varices (GOV2), which extend from the esophagus into the fundus and tend to be long and tortuous.^{1,2} Following the acute episode, either BCA or TIPS is recommended for prevention of recurrent bleeding from IGV or GOV2.

The Evidence to Support the Endoscopist's Perspective

Observational Studies of Endoscopic Therapy with BCA. Data assessing tissue adhesives come primarily from observational studies, with a limited number of randomized trials available. BCA is the most widely used tissue adhesive. In the U.S., BCA is approved for cerebral arteriovenous malformations but not for gastric varices. 2-Octyl-cyanoacrylate, approved for cutaneous wound closure in the U.S., has also been used. Case series indicate initial hemostasis of actively bleeding gastric varices with BCA from 82%- 100%, with rebleeding in large series generally 15%.^{3,4} Complications range from 0%-8% in most series and include bleeding due to early glue cast extrusion, distant embolism (e.g., brain, lung, spleen, heart), and sepsis.^{3,5} A majority of patients in most series have GOV rather than IGV but multivariate analysis in a recent large series found no significant association of gastric variceal type and rebleeding⁴ after BCA therapy.

Clinical Trials of BCA Versus Other Therapies for Bleeding Gastric Varices

Ligation. BCA had significantly better control of actively bleeding gastric varices in one randomized trial (87% versus 45%),⁶ but not another (93% versus 93%).⁷ Both studies showed

significantly lower rates of long-term rebleeding with BCA (31% versus 54% and 22% versus 44%).^{6,7} The greatest benefit of BCA appeared to be in patients with IGV1.⁷ Ligation had more complications (primarily treatment-induced ulcer bleeding) and a strong trend to decreased survival (29% versus 48%; $P = 0.05$) in one study.⁶ A third randomized trial, restricted to GOV1, found significantly lower rates of persistent or recurrent bleeding (16% versus 35%) with BCA.⁸

b-Blockers. BCA had significantly lower rates of gastric variceal rebleeding (15% versus 55%) and mortality (3% versus 25%) over a median of 26 months in a randomized trial.⁹

TIPS. BCA had significantly more gastric variceal rebleeding (38% versus 11%) in a randomized trial.¹⁰ No significant difference was seen in survival or complications, although encephalopathy was more common with TIPS (26% versus 3%). Observational studies from the U.S. and U.K. raise the possibility that healthcare resource utilization may be higher with TIPS in the first 6-12 months, with more days in hospital due to TIPS complications.^{11,12}

Conclusions

Endoscopic BCA is first-line therapy for acute treatment of bleeding gastric varices. If BCA is unsuccessful or unavailable, TIPS is recommended. TIPS is more effective than BCA in preventing recurrent bleeding, but has a higher rate of encephalopathy. In patients in whom TIPS is technically difficult or impossible, BRTO, as in the case presented, appears to be a very reasonable option.

Dr. Brown: The Interventional Radiologist's Perspective

The Interventional Radiologist's Conventional Approach

TIPS is the standard approach for variceal bleeding that fails endoscopic management. BRTO can be performed when TIPS has a higher risk, such as portal vein thrombosis, high Model for Endstage Liver Disease (MELD) score, or encephalopathy. Our sclerosant preference is a mixture, as used in this case, which damages vascular endothelium within 2 minutes of contact and results in complete vascular thrombosis within 30 minutes. The minimum balloon inflation time is unknown—some authors use only 30 minutes,¹³ but we leave the balloon in place for 3 hours, similar to others using Sotradecol.¹⁴ Patient selection is important to achieve procedural success, as BRTO is not feasible in all patients. A patent shunt connecting the varices/ portal system to the renal vein must be present. Once the varix is catheterized, outflow veins with systemic communication must be embolized to prevent unintentional infusion of the sclerosant into the systemic circulation. Embolization of these systemic communicators is necessary in approximately 50% of cases and is relatively straightforward.¹⁴

The Evidence to Support the Interventional Radiologist's Perspective

Observational Studies of BRTO. When evaluating outcomes over multiple studies, Sabri et al.¹⁴ described rebleeding rates following BRTO ranging from 0%- 9%. Varices were completely obliterated in 87%-100% of patients at follow-up endoscopy. Long term, freedom from recurrent gastric variceal hemorrhage of 90% at 8 years follow-up has been described.¹³ In this long-term follow-up study, the gastric varices were completely eradicated at endoscopy in 61 of 63 patients. Technical failure due to anatomic unsuitability ranges from 7%-12%.^{13,15} Potential adverse effects of BRTO include development of esophageal varices and/or ascites resulting from elevation in portal pressure due to occlusion of a large gastroduodenal shunt. In one series of 78 patients,¹⁶ worsening of esophageal varices was observed in 29 patients, with incidences at 1, 3, and 5 years of 27%, 58%, and 66%, respectively. On the other hand, encephalopathy and synthetic function have been shown not to worsen following BRTO as portal perfusion increases.^{17,18} Surveillance endoscopy after BRTO and appropriate use of nonselective beta-blockade and/or banding are required to prevent the possibility of esophageal variceal bleeding.

Conclusions

BRTO data, although largely uncontrolled, demonstrates excellent control of bleeding with durable obliteration of treated varices. The presence of a splenorenal shunt in the setting of factors increasing the risk for TIPS, such as portal vein thrombosis in the case presented, represents the ideal clinical application for BRTO. Expansion of use of this technique in the U.S. is likely over the next several years.

References

1. de Franchis R. Revising consensus in portal hypertension: report of the Baveno V consensus workshop on methodology of diagnosis and therapy in portal hypertension. *J Hepatol* 2010;53:762-768
2. Garcia-Tsao G, Sanyal AJ, Grace ND, Carey WD. Prevention and management of gastroesophageal varices and variceal hemorrhage in cirrhosis. *HEPATOLOGY* 2007;46:922-938
3. Irani S, Kowdley K, Kozarek R. Gastric varices: an updated review of management. *J Clin Gastroenterol* 2011;45:133-148
4. Choudhuri G, Chetri K, Bhat G, Alexander D, Das K, Ghoshal UC, et al. Long-term efficacy and safety of N-butylcyanoacrylate in endoscopic treatment of gastric varices *Trop Gastroenterol* 2010;31: 155-164.
5. Cheng LF, Wang ZQ, Li CZ, Lin W, Yeo AET, Jin B. Low incidence of complications from endoscopic gastric variceal obturation with butyl cyanoacrylate. *Clin Gastroenterol Hepatol* 2010;8:760-766.

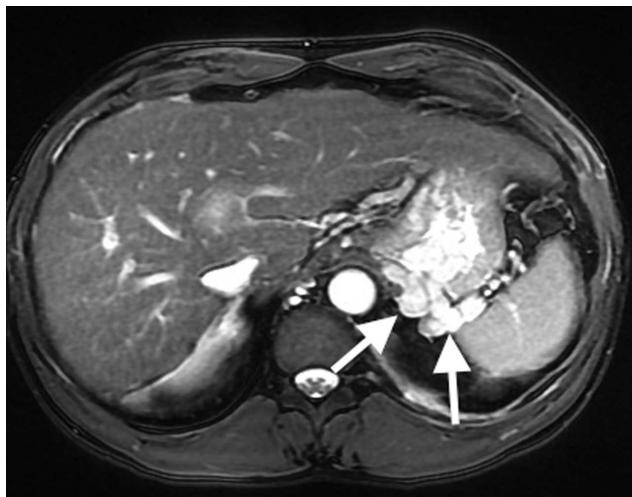6. Lo GH, Lai KH, Cheng JS, Chen MH, Chiang HT. A prospective, randomized trial of butyl cyanoacrylate injection versus band ligation in the management of bleeding gastric varices. *HEPATOLOGY* 2001;33: 1060-1064.
7. Tan PC, Hou MC, Lin HC, Liu TT, Lee FY, Chang FY, et al. A randomized trial of endoscopic treatment of acute gastric variceal hemorrhage: N-butyl-2-cyanoacrylate injection versus band ligation. *HEPATOLOGY* 2006;43:690-7.
8. El Amin H, Abdel Baky L, Sayed Z, Abdel Mohsen E, Eid K, Fouad Y, et al. A randomized trial of endoscopic variceal ligation versus cyanoacrylate injection for treatment of bleeding junctional varices. *Trop Gastroenterol* 2010;31:279-284.
9. Mishra SR, Sharma BC, Kumar A, Sarin SK. Endoscopic cyanoacrylate injection versus b-blocker for secondary prophylaxis of gastric variceal bleed: a randomised controlled trial. *Gut* 2010;59:729-735.
10. Lo GH, Liang HL, Chen WC, Chen MH, Lai KH, Hsu PI, et al. A prospective, randomized controlled trial of transjugular intrahepatic portosystemic shunt versus cyanoacrylate injection in the prevention of gastric variceal rebleeding. *Endoscopy* 2007;39:679-685.
11. Procaccini N, Al-Osaimi AMS, Northup P, Argo C, Caldwell SH. Endoscopic cyanoacrylate versus transjugular intrahepatic portosystemic shunt for gastric variceal bleeding: a single-center U.S. analysis. *Gastrointest Endosc* 2009;70:881-887.
12. Mahadeva S, Bellamy MC, Kessel D, Davies MH, Millson CE. Costeffectiveness of N-butyl-2-cyanoacrylate (histoacryl) glue injections versus transjugular intrahepatic portosystemic shunt in the management of acute gastric variceal bleeding. *Am J Gastroenterol*. 2003;98: 2688-2693.
13. Akahoshi T, Hashizume M, Tomikawa M, Kawanaka H, Yamaguchi S, Konishi K, et al. Long-term results of balloon-occluded retrograde transvenous obliteration for gastric variceal bleeding and risky gastric varices: a 10-year experience. *J Gastroenterol Hepatol* 2008;23:1702-1709.
14. Sabri SS, Swee W, Turba UC, Saad WE, Park AW, Al Osaimi AM, et al. Bleeding gastric varices obliteration with balloon-occluded retrograde transvenous obliteration using sodium tetradecyl sulfate foam. *J Vasc Interv Radiol* 2011;22:309-316.
15. Cho SK, Shin SW, Lee IH, Do YS, Choo SW, Park KB, et al. Balloonoccluded retrograde transvenous obliteration of gastric varices: outcomes and complications in 49 patients. *AJR Am J Roentgenol* 2007; 189:W365-W372.

16. Ninoi T, Nishida N, Kaminou T, Sakai Y, Kitayama T, Hamuro M, et al. Balloon-occluded retrograde transvenous obliteration of gastric varices with gastrosplenic shunt: long-term follow-up in 78 patients. *AJR Am J Roentgenol* 2005;184:1340-1346.

17. Kasuga A, Mizumoto H, Matsutani S, Kobayashi A, Endo T, Ando T, et al. Portal hemodynamics and clinical outcomes of patients with gastric varices after balloon-occluded retrograde transvenous obliteration. *J Hepatobiliary Pancreat Sci* 2010;17:898-903.

18. Uehara H, Akahoshi T, Tomikawa M, Kinjo M, Hashimoto N, Nagao Y, et al. Prediction of improved liver function after balloon-occluded retrograde transvenous obliteration: relation to hepatic vein pressure gradient. *J Gastroenterol Hepatol* 2012;27:137-141.

Figure 1: Baseline axial MRI demonstrates multiple prominent gastric fundal varices (White Arrows).



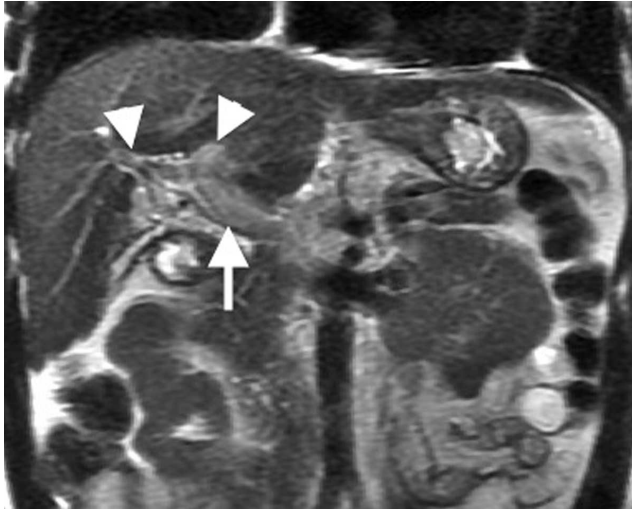
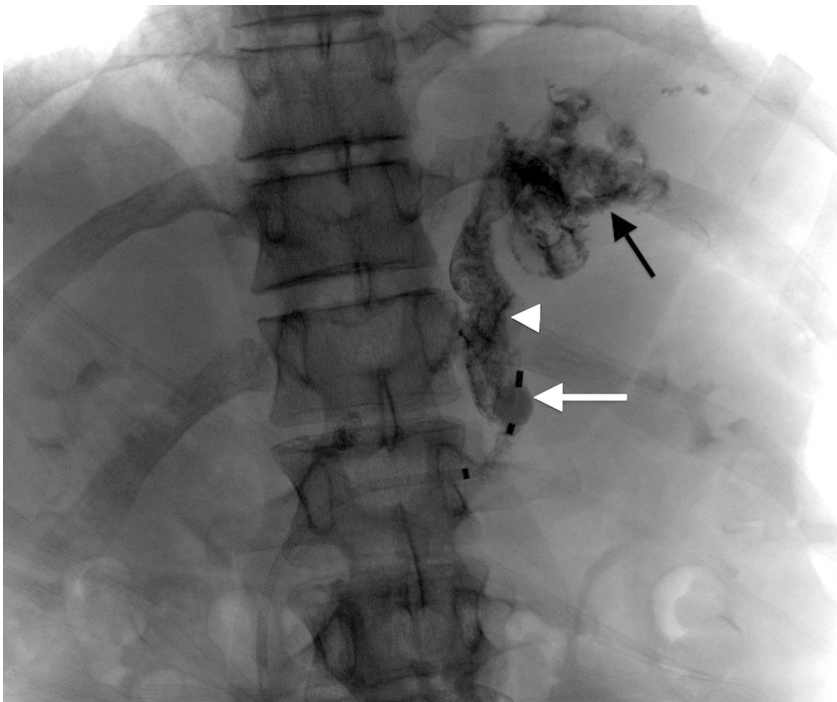


Figure 2: Coronal images from the same study demonstrate occlusive thrombus in the main (White Arrow), and left and right (Arrowheads) portal vein branches.

Figure 3: With the balloon inflated (White Arrow), the sclerosing agent fills the gastroduodenal shunt (White Arrowhead) and the gastric varices (Black Arrow).



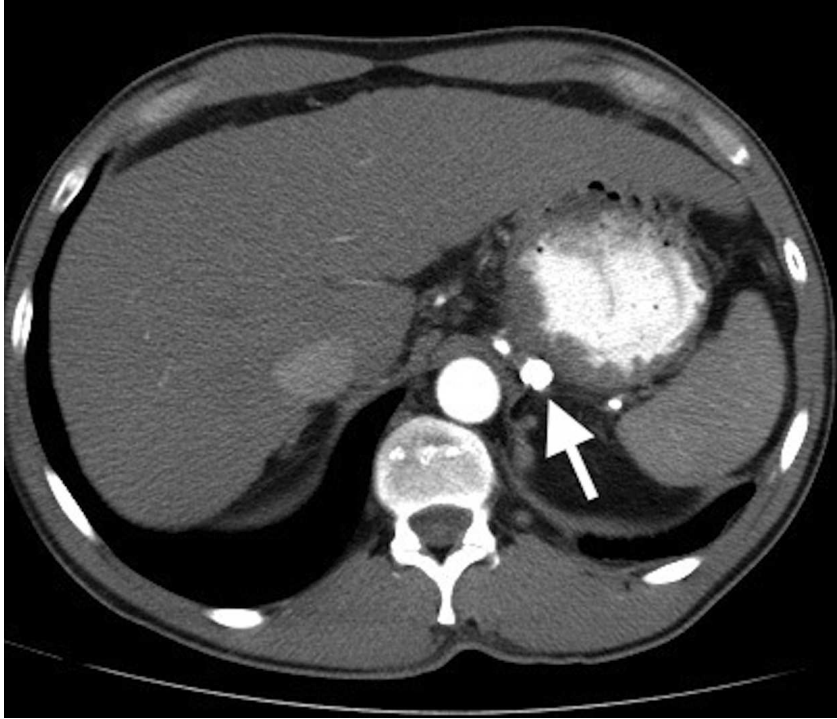


Figure 4: CT scan obtained 3 months after the procedure demonstrates resolution of the varices with residual sclerosant in the veins (White Arrow).