

4-13-2023

Intraocular Lens Tilt Due to Optic-Haptic Junction Distortion Following Intrasccleral Haptic Fixation With the Yamane Technique

Jordan P. Safran

Thomas Jefferson University, jordan.safran@students.jefferson.edu

Steven G. Safran

Follow this and additional works at: <https://jdc.jefferson.edu/skmcstudentworks>



Part of the [Ophthalmology Commons](#)


[Let us know how access to this document benefits you](#)

Recommended Citation

Safran, Jordan P. and Safran, Steven G., "Intraocular Lens Tilt Due to Optic-Haptic Junction Distortion Following Intrasccleral Haptic Fixation With the Yamane Technique" (2023). *SKMC Student Presentations and Publications*. Paper 1.

<https://jdc.jefferson.edu/skmcstudentworks/1>

This Article is brought to you for free and open access by the Jefferson Digital Commons. The Jefferson Digital Commons is a service of Thomas Jefferson University's [Center for Teaching and Learning \(CTL\)](#). The Commons is a showcase for Jefferson books and journals, peer-reviewed scholarly publications, unique historical collections from the University archives, and teaching tools. The Jefferson Digital Commons allows researchers and interested readers anywhere in the world to learn about and keep up to date with Jefferson scholarship. This article has been accepted for inclusion in SKMC Student Presentations and Publications by an authorized administrator of the Jefferson Digital Commons. For more information, please contact: JeffersonDigitalCommons@jefferson.edu.



Intraocular lens tilt due to optic-haptic junction distortion following intrascleral haptic fixation with the Yamane technique

Jordan P. Safran^{a,*}, Steven G. Safran^b

^a Sidney Kimmel Medical College of Thomas Jefferson University, Philadelphia, PA, USA

^b Lawrenceville, NJ, USA

ARTICLE INFO

Keywords:

Yamane technique
Intrascleral haptic fixation
Intraocular lens exchange
Zeiss lens
Tilted intraocular lens
Cataract surgery complication

ABSTRACT

Purpose: To report two patients with a complication of Yamane intrascleral haptic fixation surgery (ISHF) with the Zeiss CT Lucia 602 lens: severely tilted intraocular lens (IOL) leading to significantly decreased vision in the early post-operative period.

Observations: We report two patients presenting with severely tilted IOL implants one day and one month following Yamane ISHF. The first patient is a monocular 81-year-old woman referred for treatment of cornea edema. Initial surgery involved replacement of an anterior chamber lens with a CT Lucia 602 posterior chamber lens using Yamane technique and Descemet's stripping endothelial keratoplasty. The patient returned at one month follow-up with poor vision and IOL tilt observable at the slit lamp through a peripheral iridectomy site. Explanation of the Zeiss lens revealed haptic distortion at the optic-haptic insertion point such that each haptic was about 45° off axis to the plane of the optic in approximately equal and opposite directions. The second patient, a 75-year-old woman, was referred with a completely dislocated lens-bag complex in the right eye. The initial operative treatment for this patient included pars plana vitrectomy, retrieval and removal of the dislocated lens-bag complex, and placement of a Zeiss 602 lens via Yamane ISHF technique. On the first postoperative day, the patient was counting fingers in the right eye with an intraocular pressure of 5 mm Hg and obvious IOL tilt on slit lamp examination. Explanation of the lens revealed severely distorted haptics relative to the optic by more than a 60-degree angle on both sides. In both cases, initial surgery was performed with an IOL inspected prior to implantation and found to have normal appearing haptics. At the end of each case, there was adequate centration and no tilt of the IOL. Management in both patients included removal of the defective lens and placement of a new, same power CT Lucia 602 lens via the Yamane technique. Visual acuity improved from CF to 20/30 best corrected after reoperation in both cases.

Conclusions and importance: In summary, we describe a complication of Yamane ISHF with the CT Lucia 602 lens in which there is lens tilting associated with distortion at the optic-haptic fastening zone in the early post-operative period. In the event of a tilted lens following Yamane ISHF, awareness of this complication may help surgeons consider lens replacement, as the haptics may be permanently distorted or damaged.

1. Introduction

Yamane intrascleral haptic fixation (ISHF) is a surgical technique for patients with poor or absent capsular support. Since its introduction in 2014¹ this elegant, sutureless, minimally invasive technique has been further refined and represents a significant advance in IOL fixation techniques. An intraocular lens (IOL) commonly utilized in this approach is the Zeiss CT Lucia 602 because of the biomechanical intrascleral stability,² shape recovery capability,^{3,4} and resistance to kinking^{5,6} of its polyvinylidene fluoride (PVDF) material haptics.

Herein we describe two patients with a severely tilted IOL leading to significantly decreased vision following Yamane intrascleral haptic fixation surgery with the Zeiss CT Lucia 602 lens. In both cases, lens tilting occurred within one month of surgery, with the explanted lens showing significant distortion of the angle between the haptic and optic. In both cases, vision improved from CF after initial surgery to 20/30 within a month after replacement with a new Zeiss CT Lucia 602 lens via repeat Yamane ISHF.

* Corresponding author.

E-mail address: Jordan.safran@students.jefferson.edu (J.P. Safran).

<https://doi.org/10.1016/j.ajoc.2023.101845>

Received 20 December 2022; Received in revised form 6 March 2023; Accepted 8 April 2023

Available online 13 April 2023

2451-9936/© 2023 The Authors. Published by Elsevier Inc. This is an open access article under the CC BY-NC-ND license (<http://creativecommons.org/licenses/by-nc-nd/4.0/>).

2. Case report

2.1. Case 1

A monocular 81-year-old woman was referred for treatment of cornea edema in her left eye. The eye had a history of placement of a Kelman tripod PCIOL 30 years prior, POAG treated with topical medication, and vision-limiting cornea edema with CF visual acuity.

At the time of referral, visual acuity was CF and intraocular pressure (IOP) was 13 mm Hg. Examination revealed cornea edema with stromal folds and microcysts obscuring the view of the anterior chamber lens and iris, and pachymetry measurement was 673 μm . A Kelman tripod anterior chamber lens was present in the anterior chamber of the left eye with the superior haptic prolapsed through the peripheral iridectomy. Dilation in the eye was poor; however, B-scan, funduscopy exam, and ocular coherence tomography (OCT) of the optic nerve and macula were unremarkable.

The operative treatment plan for this patient included pars plana vitrectomy (PPV), removal of the anterior chamber lens, off-label placement of a Zeiss CT Lucia 602 lens via Yamane ISHF, and Descemet's stripping endothelial keratoplasty (DSAEK). During surgery, pars plana trocars were placed, vitrectomy was carried out, and a temporal peritomy was performed with a self-sealing scleral tunnel incision 6 mm wide. The tripod anterior chamber lens was removed in one piece through the scleral tunnel incision. The new lens, a 22.0 diopter, Zeiss CT Lucia 602 was inspected to make sure that the haptics were properly oriented, and then placed in the anterior chamber. The distal haptic was captured with a 30-gauge needle placed 2 mm posterior to the limbus and tunneled into the eye. The proximal haptic was captured with the 30-gauge needle 180° away in a similar fashion. Both haptics were

externalized and the lens was centered well. The tips were melted into scleral flanges, and the flanges pushed into the tip of the scleral groove on each side with good centration of the lens. At this point in the operation, there was good visibility and no observed tilt of the IOL. The anterior chamber was then filled with cohesive viscoelastic and Descemet's stripping was carried out. After removal of the diseased endothelium and the viscoelastic, the DSAEK graft was pulled into the anterior chamber with a microforceps, centered, and pinned to the back of the cornea in the proper orientation with a full air fill maintained for 10 min.

On post-operative day 1, the graft was completely adherent to the back of the cornea, which had mild to moderate stromal and epithelial edema. The scleral tunnel was covered by conjunctiva and the eye was Seidel negative. The visual acuity remained at CF uncorrected. The IOP was 13 mm Hg (measured first by rebound tonometry and confirmed by Goldman tonometry) and a B-scan was unremarkable. It was difficult to see if the lens was tilted at that point because the cornea was not completely clear, and the patient's pupil did not dilate well. At one month follow-up, the patient reported continued poor vision and was referred back to us with a diagnosis of IOL tilt, with visual acuity remaining CF in the left eye. On examination in our clinic through the poorly dilating pupil, it was difficult on first inspection to determine that the lens was tilted; however, use of a gonioscopy lens revealed the haptic of the IOL through the peripheral iridectomy (PI) site at an acute angle relative to the IOL (Fig. 1A) and the lens was determined to be tilted relative to the plane of the iris. A decision was made to take the patient back to the operating room for surgical repair.

Six weeks after the initial procedure the patient was brought back to the O. R and after placing iris retractors to expand the pupil, severe tilt of the IOL (Fig. 1B) was easily seen. This IOL was exchanged with a new

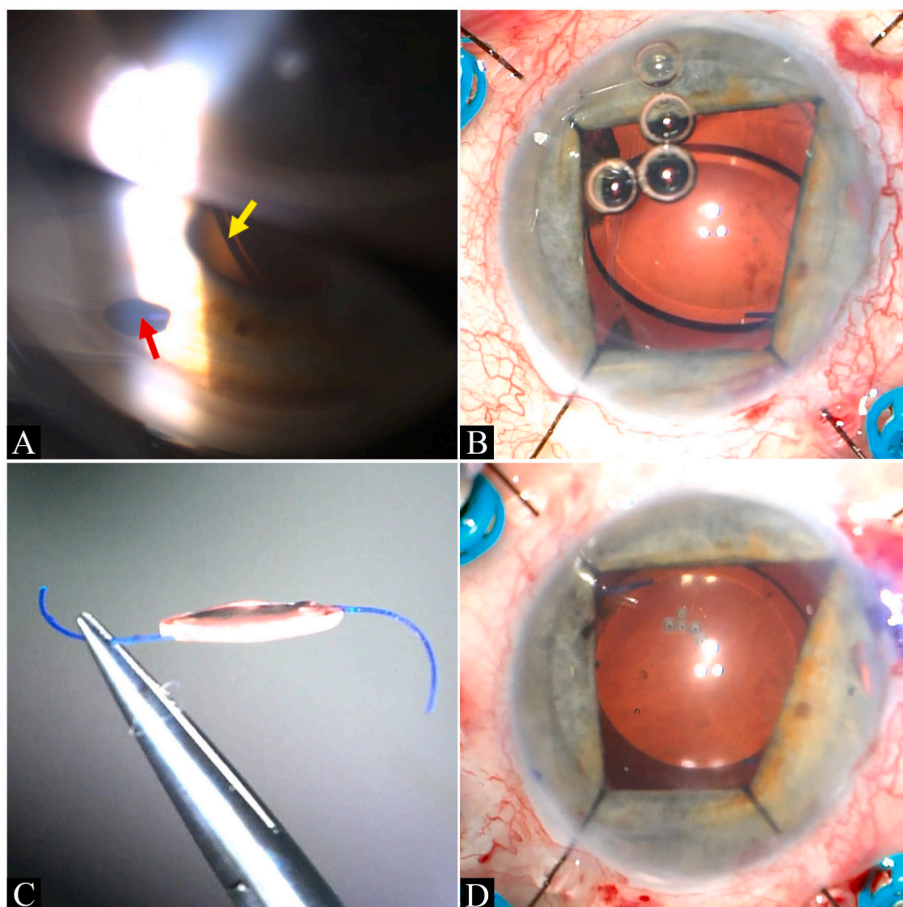


Fig. 1. Clinical images of post-operative IOL tilt in Patient 1.

Gonioscopic view on slit lamp exam reveals the haptic through the peripheral iridectomy (red arrow) which appears to be at a 30–40° angle relative to the IOL optic (yellow arrow). The optic can be seen to be tilted relative to the plane of the iris in this image as well (A). After placing iris retractors the intra scleral haptic fixated IOL can be seen to be severely tilted (B). The tilted Zeiss CT Lucia 602 lens removed from this patient's eye in one piece can be seen to have both haptics distorted in roughly equal and opposite directions relative to the optic (C). The replacement Zeiss 602 lens after Yamane ISHF prior to removing the iris retractors and trocars can be seen to be planar with no evidence of tilt or decentration. The lens remained in this configuration through the post-operative course (D).

Zeiss lens using Yamane ISHF. During this surgery, four iris retractors were placed 1 mm posterior to the limbus to mechanically dilate the pupil and provide better visibility. Three 25-gauge pars plana trocars were placed for infusion and instrumentation required to remove and replace the tilted lens. The tips of the haptics of the tilted lens were dissected out of their respective scleral tunnels, cut, and the lens was pulled back into the anterior chamber. The previously made scleral tunnel incision was reopened using blunt dissection and the lens was taken out through the main incision. Observation of the explanted Zeiss lens outside of the eye revealed haptic distortion at the optic-haptic insertion point such that each haptic was about 45° off axis to the plane of the optic in equal and opposite directions (Fig. 1C). A 22.0 D, Zeiss CT Lucia 602 was placed in the anterior chamber. Intrasceral haptic fixation with Yamane technique with 30-gauge needles was repeated with satisfactory centration (Fig. 1D). Further PPV was then performed to remove blood from the vitreous cavity and the surface of the retina that occurred from bleeding during removal and replacement of the IOL.

Post-operatively, the vision improved to 20/50 in the left eye at one week. At 4 weeks, the vision was 20/25 uncorrected for near and 20/30 at distance with a manifest refraction of $-1.5-2.0 \times 106$. The IOP was 11 mm Hg on no topical glaucoma medications and the new intrasceral fixated Zeiss lens remained in excellent position without tilt at all of these timepoints.

2.2. Case 2

A 75-year-old woman was referred with a completely dislocated lens-bag complex in the right eye. Past ocular history is significant for bilateral placement of IOLs with yttrium-aluminum-garnet (YAG) capsulotomy approximately 10 years previously and posterior vitreous detachment (PVD) in both eyes. This patient also had a history of dry age-related macular degeneration (ARMD) OD. The left eye had neovascular ARMD with active choroidal neovascularization (CNV) treated previously since January 2020 q8 weeks with Eylea injections with resolved endophthalmitis occurring after one of her Eylea injections.

At the time of referral, visual acuity was CF uncorrected in the right eye and 20/50 best corrected in the left eye. IOP was 14 mm Hg in the right eye and 12 mm Hg in the left eye. The corneas were clear bilaterally. The iris of the right eye did not dilate well, and she had pseudoexfoliation material on the iris border. The OD had vitreous presenting through the pupil with the lens-bag complex dislocated posteriorly and seen to be sitting on the inferior retina with indirect ophthalmoscopy. The OS had a well-positioned intraocular lens in the capsular bag. While the optic nerve appeared healthy bilaterally on fundoscopic exam, drusen and mild retina pigment epithelial mottling were present in the macula of both eyes with greater atrophic changes OS.

The operative treatment for this patient included PPV, retrieval and removal of the dislocated lens-bag complex, and off-label placement of a Zeiss CT Lucia 602 lens via Yamane ISHF. Peripheral iridectomy was also performed to prevent reverse pupillary block. Four pars plana

trocars were placed and iris retractors used to mechanically dilate the pupil. Vitrectomy was carried out, and the lens-bag complex could be visualized on the retina using indirect posterior visualization and chandelier light. After completion of PPV the lens-bag complex was brought up into the anterior chamber, cut in half, and removed through 2.75 mm clear cornea incision. A Zeiss CT Lucia 602, 18.0 D lens was injected into the anterior chamber and each haptic was captured within the lumen of a 30-gauge needle tunneled 2 mm posterior the limbus into the posterior chamber, 180° apart as per the Yamane technique. The needles were externalized with the haptics brought out with them, the haptic tips melted into flanges with hot tip cautery and placed into the tip of the scleral groove on each side. At this point, the lens centered well without evidence of any tilt (Fig. 2A). Miochol was used to constrict the pupil and a peripheral iridectomy was created at 9 o' clock.

On postoperative day one, the patient saw only CF uncorrected, and no improvement was obtained with refraction. On slit lamp exam the lens was obviously markedly tilted at more than a 45-degree angle to the iris plane. The IOP was measured at 5 mm Hg but the chamber was formed and the cornea relatively clear. Retinal exam showed no evidence of hypotony maculopathy. A decision was made to surgically reposition or replace the IOL as soon as possible.

The patient was brought back to the operating room 2 weeks later. Intraoperatively, the lens was found to be tilted severely and both haptics appeared to be embedded in the sclera properly (Fig. 2B). A decision was made to remove the lens and replace it. Pars plana trocars were placed, the flanges dissected out of their sclera tunnels on each side, and the tip of each haptic cut proximal to the flange so the haptics could be pulled into the eye. The lens was brought up into the anterior chamber, cut in half, and removed through the original cornea incision. The lens was inspected, and the haptics were found to be severely distorted relative to the optic by more than a 60-degree angle on both sides (Fig. 2C). At this point, a new Zeiss CT Lucia 602 18.0 D lens was inspected and injected into the anterior chamber. Intrasceral haptic fixation was carried out in the same fashion with good centration. Lastly, 10-0 nylon sutures were placed in the main incision and trocar sclerotomy sites with the knots buried.

Postoperatively, at day one the patient's vision had improved in the right eye to 20/80 with some residual blurriness. By one week post-op, the patient's vision had improved to 20/40 in the right eye and at 3 months post-op the IOL remained in good position with vision of 20/30 uncorrected, a manifest refraction of plano, and an IOP of 10 mm Hg. Her fundus exam in this eye demonstrated similar mild ARMD changes as previous to surgery.

3. Discussion

The Yamane intrasceral haptic fixation technique was introduced in 2014¹ as a surgical approach for patients with capsular bag insufficiency.⁷ The technique involves extensive haptic manipulation during surgery as well as careful creation of intrasceral tunnels placed to prevent tilt and decentration of the IOL. Given the extensive haptic manipulation during surgery required for this technique, many surgeons

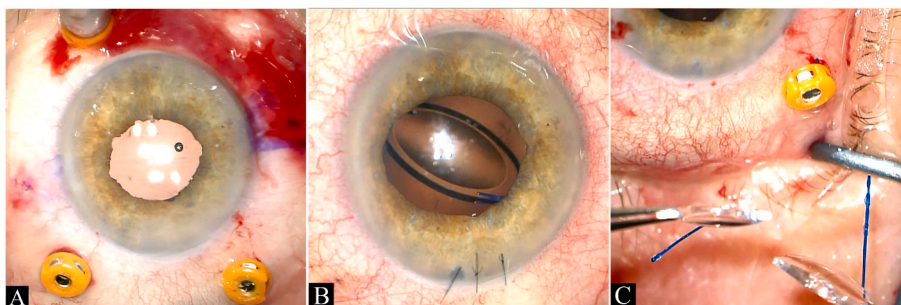


Fig. 2. Clinical images of post-operative IOL tilt in Patient 2.

At the end of the patient's first surgical procedure, the Zeiss CT Lucia 602 lens can be seen in planar configuration with excellent centration. This is just prior to removing trocars and conclusion of surgery (A). The view under the surgical microscope of this same IOL at the beginning of her second surgery. The lens is now severely tilted (B). Upon removal of the severely tilted IOL (which was cut in half during extraction) the haptics can be seen to be distorted 60–80° in opposite directions relative to the optic (C).

prefer to use lenses with PVDF instead of polymethylmethacrylate (PMMA) haptics because the PVDF haptics have demonstrated better memory of shape^{3,4} with resistance to deformation and kinking^{5,6} that can occur with manipulation. Another reason PVDF haptics are preferred over PMMA haptics is due to the way they melt reliably to create a “mushroom” shaped flange when exposed to heat which provides more secure fastening of the haptic tip in the scleral bed.⁸ The only IOL currently available in the U.S. with PVDF haptics is the Zeiss CT Lucia 602. This is a foldable, hydrophobic acrylic 3-piece lens with a 6 mm optic, and due to its resilient haptics^{2,6} and hydrophobic acrylic optic material it has become very popular for off-label use for ISHF in cases of capsular bag insufficiency.⁹

There are several steps required in the Yamane technique that must be executed with care to prevent tilt and decentration of the IOL. If the needle tunnels are not of similar length, at a similar distance and angle relative to the limbus, and exactly 180° apart, the lens is unlikely to center well or may end up tilted relative to the iris plane.^{10–12} Improper haptic flange creation can also lead to displacement and tilt of the lens optic.⁸ Lens tilt can lead to significant refractive error, astigmatism, and coma, which will degrade the quality of vision, while decentration can lead to astigmatism,^{13–15} higher order aberrations, decreased contrast and glare.¹⁶ Tilt and decentration can best be avoided with proper instrumentation and meticulous surgical technique. In these two cases of severe tilt following Yamane ISHF, it is important to consider the possibility of improper surgical technique.

Capturing and externalizing haptics are surgical manipulations that can put strain on the optic-haptic junction during Yamane ISHF. This potentially can cause damage to the haptic or disinsert the haptic itself. In a case of severe tilt due to improper surgical technique or extensive haptic manipulation, the dislocation of the lens would likely be evident during the surgical procedure, with poor centration or tilt evident by the end of surgery. Haptic distortion would likely be greater on the side to which surgical manipulation induced damage occurred. In both cases presented in this series, video review of the surgery reveals minimal haptic manipulation and the lens position was assessed and confirmed to be centered without any evidence of tilt or decentration at the conclusion of ISHF (Video 1). Severe tilt was easily seen, however, upon return to O.R. for revision. In both cases, the haptics of the explanted implants were distorted relative to the optic in roughly equal and opposite directions on either side (rather than affected on only one side), with no kinking of the haptics (Video 2).

Supplementary video related to this article can be found at <https://doi.org/10.1016/j.ajoc.2023.101845>

Taken together, these findings suggest that some force acted on the lens to distort the optic relative to the haptics after placement in the eye, and that this permanently changed the lens haptic configuration. In the first case presented, after the new IOL was placed with Yamane technique, there was a DSAEK procedure done. Careful review of the video of this surgery demonstrates buckling of the scleral wall inward as the donor graft was pulled into the eye with forceps (Fig. 3). It is possible that the moment of the buckling of the sclera while the haptics were embedded within the scleral wall represents the point during surgery at which forces may have been placed on the IOL that distorted the optic-haptic relationship and caused tilt of the IOL. This motion on the IOL was not visible to the surgeon because of the loss of clarity of the cornea after placement of the DSAEK graft, in addition to the miotic pupil already present.

In the second case presented, the implant was in good position without tilt or decentration at the end of the surgery (Video 1). On return to the clinic the following day, the patient’s patch was removed and the IOP was 5 mm Hg. It is possible that there was some leakage through one of the four trocar sclerotomies in the early post-operative period. The pressure may have been much lower than this at some point post-operatively leading to hypotony and scleral collapse in this vitrectomized eye, which may have placed a torquing force on the IOL already embedded within the scleral wall via ISHF. It is also possible that there

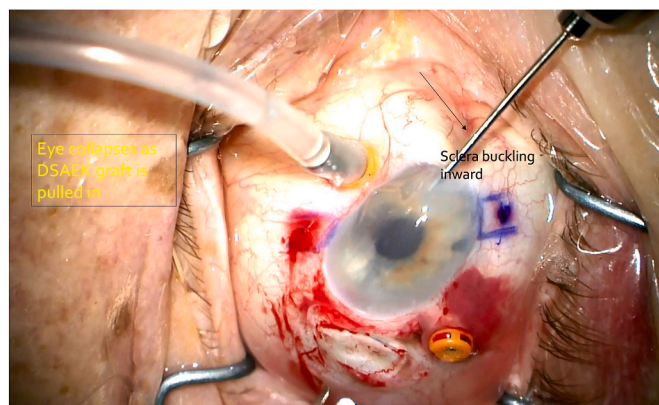


Fig. 3. Scleral buckling during DSAEK in Patient 1.

Still from Patient 1 surgical video which demonstrates scleral collapse of the eye as DSAEK graft is being pulled into the eye from Busin glide. At this moment there are likely significant torquing forces placed on the haptics of the intrascleral haptic fixated lens which could lead to rotation at the optic-haptic junction and subsequent tilt of the lens.

were forces placed on the sclera transmitted to the lens at the conclusion of the procedure with removal of the speculum.

We present two cases of severe lens tilt following Yamane ISHF with optic-haptic junction distortion in the early post-operative period. Given these findings, we recommend careful inspection of lenses used for Yamane ISHF before and after surgery. If a distorted or damaged haptic is discovered after surgery, we recommend lens replacement in favor of repositioning to avoid tilt or decentration, as there may be permanent compromise to the optic-haptic relationship. Mechanical forces during and after surgery, including those that induce scleral deformation or collapse (e.g., scleral depression) may predispose the lens and haptic to deforming forces, and this should be considered when planning and performing surgery. Further, a soft, vitrectomized eye may be more prone to scleral collapse which could place torquing forces on the lens-haptic junction. We recommend carefully closing all incisions and sclerotomies with sutures if necessary, pressurizing the eye to physiologic IOP, and carefully removing the speculum at the end of the case to prevent leakage and hypotony in the post-operative period.

Our case series is limited by a retrospective design and small sample size. Further studies of lens complications related to the optic-haptic insertion point will need to be carried out to better characterize this finding.

4. Conclusions

In summary, we describe a complication of Yamane scleral haptic fixation with the CT Lucia 602 lens in which there is lens tilting associated with distortion at the optic-haptic fastening zone in the early postoperative period. In the event of a tilted lens following Yamane intrascleral haptic fixation, awareness of this complication may help surgeons consider lens inspection and replacement if necessary, as the haptics may be permanently distorted or damaged.

Patient consent

Consent to publish the case series was obtained from all patients.

Authorship

All authors attest that they meet the current ICMJE criteria for authorship.

Funding

This study was not funded.

Declaration of competing interests

The authors declare the following financial interests/personal relationships which may be considered as potential competing interests: Dr. Steven Safran was a consultant for Johnson & Johnson Surgical Vision, Inc and Cynosure, LLC in 2019-2020, a speaker for Allergan Inc. in 2019, a speaker for Bausch & Lomb, a division of Bausch Health US, LLC in 2020, and a speaker and consultant for Haag-Streit Group in 2020-2021. Jordan Safran has no financial disclosures related to this work.

References

1. Yamane S, Inoue M, Arakawa A, Kadonosono K. Sutureless 27-gauge needle-guided intrascleral intraocular lens implantation with lamellar scleral dissection. *Ophthalmology*. 2014;121(1):61–66. <https://doi.org/10.1016/j.ophtha.2013.08.043>.
2. Ma KK, Yuan A, Sharifi S, Pineda R. A biomechanical study of flanged intrascleral haptic fixation of three-piece intraocular lenses. *Am J Ophthalmol*. 2021;227:45–52. <https://doi.org/10.1016/j.ajo.2021.02.021>.
3. Kimura W, Kimura T, Sawada T, et al. Comparison of shape recovery ratios in various intraocular lens haptics. *J Cataract Refract Surg*. 1992;18(6):547–553. [https://doi.org/10.1016/S0886-3350\(13\)80440-3](https://doi.org/10.1016/S0886-3350(13)80440-3).
4. Kimura W, Kimura T, Sawada T, Kikuchi T, Nagai H, Yamada Y. Comparison of shape recovery ratios of single-piece poly(methyl methacrylate) intraocular lens haptics. *J Cataract Refract Surg*. 1993;19(5):635–639. [https://doi.org/10.1016/S0886-3350\(13\)80015-6](https://doi.org/10.1016/S0886-3350(13)80015-6).
5. McKee Y, Price FW, Feng MT, Price MO. Implementation of the posterior chamber intraocular lens intrascleral haptic fixation technique (glued intraocular lens) in a United States practice: outcomes and insights. *J Cataract Refract Surg*. 2014;40(12):2099–2105. <https://doi.org/10.1016/j.jcrs.2014.04.027>.
6. Shen JF, Deng S, Hammersmith KM, et al. Intraocular lens implantation in the absence of zonular support: an outcomes and safety update. *Ophthalmology*. 2020;127(9):1234–1258. <https://doi.org/10.1016/j.ophtha.2020.03.005>.
7. Darian-Smith E, Safran SG, Coroneo MT. Zonular and capsular bag disorders: a hypothetical perspective based on recent pathophysiological insights. *J Cataract Refract Surg*. 2023;49(2):207–212. <https://doi.org/10.1097/j.jcrs.0000000000001098>.
8. Kronschlager M, Blouin S, Roschger P, Varsits R, Findl O. Attaining the optimal flange for intrascleral intraocular lens fixation. *J Cataract Refract Surg*. 2018;44(11):1303–1305. <https://doi.org/10.1016/j.jcrs.2018.07.042>.
9. Fan KC, Patel NA, Al-Khersan H, Townsend JH. Outcomes of flanged intrascleral haptic fixation with CT Lucia three-piece intraocular lens. *Ophthalmic Surg Lasers Imaging Retina*. 2021;52(12):658–662. <https://doi.org/10.3928/23258160-20211127-01>.
10. Kurimori HY, Inoue M, Hirakata A. Adjustments of haptics length for tilted intraocular lens after intrascleral fixation. *Am J Ophthalmol Case Rep*. 2018;10:180–184. <https://doi.org/10.1016/j.ajoc.2018.02.025>.
11. Ucar F, Cetinkaya S. Flattened flanged intrascleral intraocular lens fixation technique. *Int Ophthalmol*. 2020;40(6):1455–1460. <https://doi.org/10.1007/s10792-020-01312-9>.
12. Ganne P, Baskaran P, Krishnappa NC. Re: Yamane et al.: flanged intrascleral intraocular lens fixation with double-needle technique (*Ophthalmology* . 2017;124:1136-1142). *Ophthalmology*. 2017;124(12):e90–e91. <https://doi.org/10.1016/j.ophtha.2017.07.007>.
13. Bonaque-González S, Bernal-Molina P, López-Gil N. Amount of aspheric intraocular lens decentration that maintains the intraocular lens' optical advantages. *J Cataract Refract Surg*. 2015;41(5):1110–1111. <https://doi.org/10.1016/j.jcrs.2014.12.048>.
14. Ashena Z, Maqsood S, Ahmed SN, Nanavaty MA. Effect of intraocular lens tilt and decentration on visual acuity, dysphotopsia and wavefront aberrations. *Vision*. 2020;4(3):41. <https://doi.org/10.3390/vision4030041>.
15. McKelvie J, McArdle B, McGhee C. The influence of tilt, decentration, and pupil size on the higher-order aberration profile of aspheric intraocular lenses. *Ophthalmology*. 2011;118(9):1724–1731. <https://doi.org/10.1016/j.ophtha.2011.02.025>.
16. Durr GM, Ahmed IIK. Intraocular lens complications. *Ophthalmology*. 2021;128(11):e186–e194. <https://doi.org/10.1016/j.ophtha.2020.07.004>.