

7-1-2013

An old problem with a new therapy: gastrointestinal bleeding in ventricular assist device patients and deep overtube-assisted enteroscopy.

Konrad Sarosiek

Thomas Jefferson University, Konrad.Sarosiek@jefferson.edu

Linda J Bogar

Division of Cardiothoracic Surgery, Department of Surgery, Thomas Jefferson University, Linda.Bogar@jefferson.edu

Mitchell I Conn

Thomas Jefferson University, mitchell.conn@jefferson.edu

Brendan O'Hare

Thomas Jefferson University, Brendan.O'Hare@jefferson.edu

Hitoshi Hirose, MD, PhD

*Thomas Jefferson University, Hitoshi.Hirose@Jefferson.edu**See next page for additional authors*

[Let us know how access to this document benefits you](#)

Follow this and additional works at: <http://jdc.jefferson.edu/surgeryfp> Part of the [Surgery Commons](#)

Recommended Citation

Cobb R, Cavarocchi NC, Hirose H. Percutaneous endoscopic gastrostomy (PEG) tube placement in patients with continuous-flow left ventricular assist devices (LVAD). *World J Cardiovasc Surg*, 2013, 3, 97-99.

This Article is brought to you for free and open access by the Jefferson Digital Commons. The Jefferson Digital Commons is a service of Thomas Jefferson University's [Center for Teaching and Learning \(CTL\)](#). The Commons is a showcase for Jefferson books and journals, peer-reviewed scholarly publications, unique historical collections from the University archives, and teaching tools. The Jefferson Digital Commons allows researchers and interested readers anywhere in the world to learn about and keep up to date with Jefferson scholarship. This article has been accepted for inclusion in Department of Surgery Faculty Papers by an authorized administrator of the Jefferson Digital Commons. For more information, please contact: JeffersonDigitalCommons@jefferson.edu.

Authors

Konrad Sarosiek; Linda J Bogar; Mitchell I Conn; Brendan O'Hare; Hitoshi Hirose, MD, PhD; and Nicholas C. Cavarocchi, MD

An Old Problem with a New Therapy: Gastrointestinal Bleeding in Ventricular Assist Device Patients and Deep Overtube-Assisted Enteroscopy

KONRAD SAROSIEK,* LINDA BOGAR,* MITCHELL I. CONN,† BRENDAN O'HARE,† HITOSHI HIROSE,* AND NICHOLAS C. CAVAROCCHI*

Conventional algorithms for diagnosis and treatment of gastrointestinal bleeding (GIB) in patients with nonpulsatile ventricular assist devices (VADs) may take days to perform while patients require transfusions. We developed a new algorithm based on deep overtube-assisted enteroscopy (DOAE) to facilitate a rapid diagnosis and treatment. From 2004 to 2012, 84 patients who underwent VAD placement in our institution, were evaluated for episodes of GIB. Our new algorithm for the management of GIB using DOAE was evaluated by dividing the episodes into three groups: group A (traditional management without enteroscopy), group B (traditional management with enteroscopy performed >24 hours after presentation), and group C (new management algorithm with enteroscopy performed <24 hours after presentation). Gastrointestinal bleeding was observed in 14 (17%) of our study patients for a total of 45 individual episodes of which 28 met our criteria for subanalysis. Forty-one (84%) lesions were confined to the upper gastrointestinal tract with more than 91% of these lesions being arteriovenous malformations. Average number of transfusions in groups A, B, and C were 4.1, 6.3, and 1.3, respectively ($p = 0.001$). The number of days to treatment was significantly shorter in group C than group B (0.4 vs. 5.3 days, $p = 0.0002$). Our new algorithm for the management of GIB using DOAE targets the most common locations of bleeding found in this patient population. When performed early, DOAE has the potential to decrease the need for transfusions and allow for an early diagnosis of GIB in VAD recipients. *ASAIO Journal* 2013; 59:384–389.

Key Words: gastrointestinal bleeding, ventricular assist device, mechanical circulatory support, enteroscopy

From the *Cardiothoracic Surgery, Thomas Jefferson University, Philadelphia, Pennsylvania; and †Gastroenterology, Thomas Jefferson University, Philadelphia, Pennsylvania.

Submitted for consideration November 2012; accepted for publication in revised form April 2013.

Disclosure: The authors have no conflicts of interest to report.

Presented at ASAIO 58th Annual Conference, San Francisco, CA, June 13–16, 2012.

Reprint Requests: Nicholas C. Cavarocchi, MD, Thomas Jefferson University Hospital, 1025 Walnut St., Ste. 605, Philadelphia, PA 19107. Email: Nicholas.cavarocchi@jefferson.edu.

Copyright © 2013 by the American Society for Artificial Internal Organs

DOI: 10.1097/MAT.0b013e318299fcd3

Ventricular assist devices (VADs) are used to treat advanced heart failure either as a bridge to transplant or as destination therapy.¹ The majority of VADs currently implanted are continuous flow VADs (CFVADs) which create nonpulsatile blood flow. These CFVADs are smaller and have increased longevity than the previous pulsatile VAD.² Gastrointestinal bleeding (GIB) has a reported incidence of 18%–40% in patients with a VAD and is known to be much more common in patients with the CFVAD.^{2,3} Treatment of each episode of GIB requires the discontinuation of anticoagulation, which carries a risk for developing a thrombus in the pump and possible subsequent embolization.⁴ While a diagnosis is pursued, patients receive blood transfusions which have been known to increase the risk of infection and development of additional antibodies.^{5,6} The traditional GIB algorithms for diagnosis and treatment can vary widely from center to center and can take days to complete. The current management of GIB in these VAD patients follows the same algorithms used for the general population and does not take into consideration the specialized needs of patients who are on mechanical circulatory support. Patients with a VAD who develop GIB need a faster diagnosis and treatment so that anticoagulation can be resumed and transfusions can be minimized. Thus, we reviewed our VAD patients who developed postoperative GIB to identify bleeding characteristics and the management performed. We propose a new algorithm that acts to shorten the time to diagnosis and treatment.

Methods

Patients

After obtaining approval from the hospital internal review board, a retrospective chart review was performed on all patients receiving a VAD at our institution from 2004 to 2012. Demographic data were generated from The Society of Thoracic Surgeons (STS) national database. Each chart was reviewed looking for episodes of GIB from the date of VAD implant through the duration of follow-up. A total of 84 patients were identified of which 25 had a pulsatile VAD and 59 had a CFVAD. Patient demographics were described in **Table 1**.

Left Ventricular Assist Device Placement and Management

Two types of VADs were implanted; pulsatile VAD (Novacor and Abiomed AB5000) and CFVAD (HeartMate II and Jarvik) during the study period. The Novacor (Novacor Corp., Oakland, CA), HeartMate II (Thoratec, Pleasanton, CA), and

Table 1. Demographics

Variable	Without Gastrointestinal Bleeding n = 70	With Gastrointestinal Bleeding n = 14	p Value
Age, mean \pm SD	53 \pm 13	58 \pm 10	0.164
Male	51 (73%)	11 (79%)	0.368
Device			
Pulsatile device	25 (36%)	0 (0%)	0.0079
Nonpulsatile device	45 (64%)	14 (100%)	0.0076
Race			
Caucasian	44 (63%)	7 (50%)	0.037
African American	16 (23%)	7 (50%)	0.131
Other	10 (14%)	0 (0%)	0.702
Preoperative risk factors			
Smoker	12 (17%)	3 (21%)	0.702
Diabetes	27 (39%)	6 (43%)	0.764
Hyperlipidemia	40 (57%)	9 (64%)	0.621
Hypertension	52 (74%)	9 (64%)	0.444
Cardiogenic shock	26 (37%)	3 (21%)	0.259
Postoperative discharge medications for (for CFVAD only)	n = 45	n = 14	
Anticoagulation	45 (100%)	14 (100%)	1.000
Antiplatelet	45 (100%)	14 (100%)	1.000

CFVAD, continuous flow ventricular assist device.

Abiomed AB5000 (Abiomed, Danvers, MA) were placed *via* standard sternotomy between the left ventricular apex and the ascending aorta, and the Jarvik 2000 (Jarvik Heart Inc., New York, NY) was placed *via* left thoracotomy between the left ventricular apex and the mid-descending aorta. The VAD pocket was created anterior to the diaphragm, and no VAD was placed in the abdominal cavity. Device selection was individualized to each patient and the indications were as a bridge to transplant for 54 (64%) patients and as destination therapy for 30 (36%). Postoperatively, all patients, regardless if on pulsatile (Novacor and Abiomed) or CFVAD (HeartMate II and Jarvik), were started on an antiplatelet drug on postoperative day 1 begun on a heparin bridge to Coumadin with a goal international normalized ratio (INR) of 1.8–2.0 on postoperative day 2. If patients had a history of atrial fibrillation, the target INR was increased to 2.5. No patients in this study had a history of documented GIB before VAD placement. All patients received a proton-pump inhibitor after VAD insertion that was continued unless a contraindication existed.

Definition of Gastrointestinal Bleeding

An episode of GIB was defined as heme-positive stool or hematemesis and a decrease in hemoglobin >1 g/dl. The resolution of GIB was defined as the stabilization of hemoglobin for a minimum of 24 hours. Transfusion triggers were continued bleeding, hemoglobin level below 7 g/dl, or hemodynamic instability. Gastrointestinal bleeding data acquisition was completed by January 2012.

Definition of Upper and Lower Gastrointestinal Tract

For the purpose of diagnosing GIB, traditionally the gastrointestinal tract is divided into upper (esophagus, stomach, and duodenum) and lower (jejunum, ileum, colon, and rectum) regions. With the development of new technology which allows the passage of an endoscope from the mouth through

the duodenum into the distal small bowel, the upper gastrointestinal tract was redefined as esophagus, stomach, duodenum, jejunum, and ileum; or all areas accessible by the endoscope.⁷ The lower gastrointestinal tract was defined as distal ileum, colon, rectum, and anus.

Traditional Gastrointestinal Bleeding Work-up

Patients presenting with GIB had all anticoagulation stopped and gastroenterology was consulted for the appropriate workup. A traditional diagnostic algorithm is displayed in **Figure 1**. Variations of this algorithm exist and the performed tests dictated by the gastroenterology service.

New Technology and Algorithm

Deep overtube-assisted enteroscopy (DOAE) is a new and emerging technology that uses a standard endoscope with an overtube to view the esophagus and stomach first, then the bowel of the duodenum, jejunum, and ileum. There are three different instruments used to perform this intervention: single-balloon (Olympus Optical, Tokyo, Japan), double-balloon (Fujinon Inc., Saitama, Japan), and spirus enteroscopy (Spirus Medical Inc., Stoughton, MA). The new technologies allow the gastroenterologist to pleat the small bowel over the endoscope and overtube allowing them to visualize the small bowel distal to the ligament of Treitz. Although three different instruments exist to perform DOAE, preference for which instruments are used lies with the individual gastroenterologist. Using this new technology of enteroscopy, a new algorithm was created for diagnosis and treatment of GIB (**Figure 2**).

Subgroup Analysis

In the 14 patients who experienced GIB, 45 individual episodes were identified. To evaluate the efficacy of early use of the DOAE in the work-up of GIB in VAD patients, a subgroup

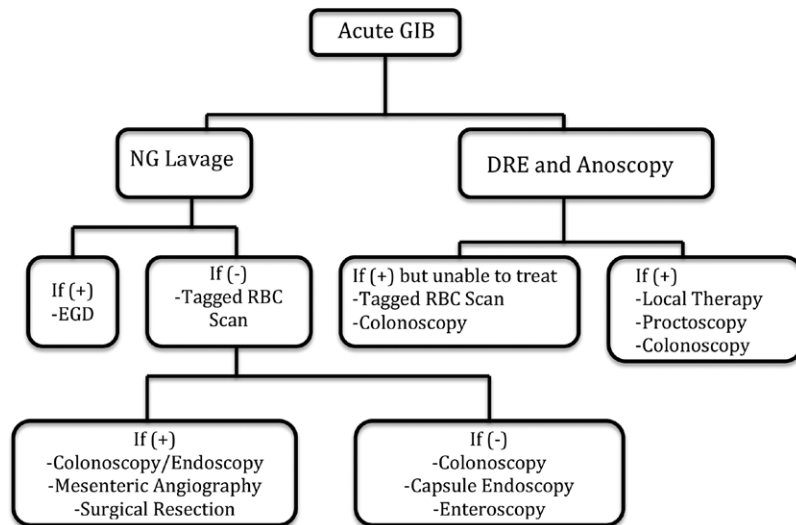


Figure 1. Traditional gastrointestinal bleeding management algorithm. DRE, digital rectal examination; EGD, esophagogastroduodenoscopy; GIB, gastrointestinal bleeding; NG, nasogastric lavage; RBC, red blood cell scan.

analyses was performed. Ten episodes of obvious colonic bleeding, which were not eligible for DOAE, were treated with colonoscopy and were not included in this subgroup analysis. Five episodes of gastric bleeding were not included because a standard DOAE includes an upper endoscopy; thus these lesions would have been found and treated with DOAE on initial pass. Two episodes were excluded because of hemodynamic instability that prohibited the patient from undergoing endoscopy. A total of 28 episodes in 12 patients were eligible for our subgroup analysis, which were divided into three groups based on the GIB work-up performed. Group A (traditional management without DOAE) consisted of patients with GIB who did not undergo DOAE at any point during their hospital stay despite multiple other imaging modalities (bleeding scans, upper endoscopy, colonoscopy, etc.) being performed. The bleeding episode, in this subgroup, resolved without a clear source being identified. Group B (traditional

management with DOAE performed >24 hours) consisted of patients who underwent multiple imaging modalities that ultimately resulted in enteroscopy being performed 24 hours or more after presentation to the hospital. Group C (new management algorithm with enteroscopy <24 hours) consists of individuals who received a DOAE within 24 hours of presentation to the hospital as the initial test performed. Outcome measures were the number of packed red blood cells transfused, the number of days from presentation to treatment, and the number of diagnostic/treatment procedures performed.

Statistics

Data were expressed as a mean with standard deviation or number and corresponding percentage as appropriate. Continuous variables were compared using a two-tailed Student's t-test, and categorical variables were compared using

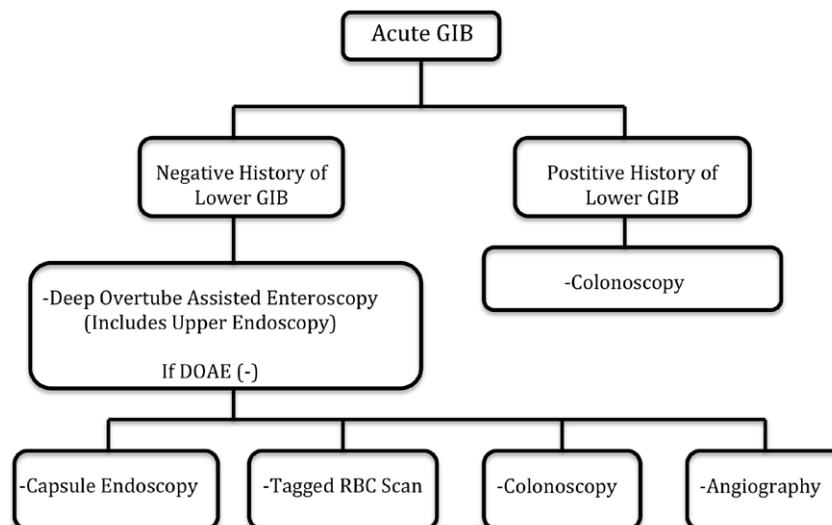


Figure 2. New algorithm for diagnosis and treatment of gastrointestinal bleeding in patients with a ventricular assist device. DOAE, deep overtube-assisted enteroscopy; GIB, gastrointestinal bleeding; RBC, red blood cell scan.

chi-square test or Fisher's exact test. Comparisons of the aforementioned subgroups were performed using one-way ANOVA. $p < 0.05$ was considered significant.

Results

Among the 84 patients who received a VAD during the study period, 14 (17%) developed at least one episode of GIB during mean follow-up period of 33.6 ± 19.8 months. Of these patients with GIB, all 14 (100%) had a CFVAD; none were pulsatile. Five (35%) patients developed the sentinel bleed within 30 days from date of VAD implant, whereas eight (57%) developed the first episode of GIB from 31 days to 1 year. There was one outlier at 612 days who had one isolated incident. The average time from implant to the first episode of GIB was 65 ± 62 days excluding the outlier mentioned earlier. Of the 14 patients, 10 patients (72%) developed a second bleed, seven (50%) developed a third bleed, five (36%) a fourth, and three (21%) a fifth. All 13 patients who developed a sentinel bleed within 1 year of VAD implant had each subsequent bleeding episode within 1 year of the initial event.

During the study period, a total 45 individual episodes of GIB occurred in 14 patients. The mean INR on presentation of a VAD patient with an episode of GIB was 1.85 ± 1.32 , whereas 64% of the episodes had an INR < 1.5 . A variety of tests were used to identify the location of the GIB. In the 45 episodes that met the criteria for the definition of GIB, 49 individual sites were identified for analysis with four episodes having multiple locations of bleeding. Among the 49 lesions of GIB, 45 (92%) were from arteriovenous malformations (AVM), one (2%) was from a bleeding Dieulafoy's lesion, one (2%) was a bleeding polyp in the duodenum, and two (4%) were diverticular bleeds. Forty-one (84%) were from upper gastrointestinal tract and eight (18%) from lower gastrointestinal tract as defined previously. The detail of the GIB location and type is shown in **Table 2**. Most of the bleeding sites, 41 (84%), were within the reach of DOAE for diagnosis and treatment during the same procedure.

Details of the subgroup analyses can be seen in **Table 3**. Enteroscopy was performed in 13 (46%) of the 28 episodes and was able to detect 13 individual GIB sites. Treatment was performed using either argon plasma coagulation or through injection of a sclerosing agent. Patients with GIB who underwent enteroscopy as the initial test and therapy during the first 24 hours of presentation to the hospital (group C) achieved significantly faster resolution of GIB than patients who had delayed enteroscopy after other imaging modalities had been performed (group B). In comparing the number of transfusions, patients in group C received significantly fewer units of blood when compared with groups A and B, 1.3 vs. 4.1 and 6.3 ($p = 0.001$), respectively. The number of diagnostic tests performed on patients in group C averaged 1.1 per episode, which was significantly fewer than 2.4 and 3.5 for groups A and B ($p = 0.005$).

Discussion

The Interagency Registry for Mechanically Assisted Circulatory Support (INTERMACS) reports have shown a steady increase in the number of VAD implants as a bridge to transplant or as destination therapy during the last 5 years. This is, in part, because of the VAD's smaller size, ease of implant, and decrease in complication rates.³

Table 2. Location and Description of the Lesions Identified in the 45 Episodes (49 Lesions)*

Location	Number of Lesions	Type of Lesion
Stomach	7 (14%)	7 AVM
Duodenum	20 (41%)	18 AVM, 1 Dieulafoy's lesion, 1 polyp
Jejunum	13 (26%)	13 AVM
Ileum	1 (2%)	1 AVM
Colon	8 (16%)	6 AVM, 2 diverticulosis

*Some individuals had more than one bleeding lesion. AVM, arteriovenous malformation.

Recent studies of GIB in VAD patients showed that 18%–40% develop GIB while receiving VAD therapy and have also shown a difference between the pulsatile VAD and CFVAD.^{8–10} Crow *et al.*¹⁰ found that patients with CFVAD had GIB rates 10 times as much as patients with pulsatile VADs. The shift from the early VADs, which used a pulsatile system to mimic normal cardiac output, to the modern CFVAD being used today has come with an increased propensity for patients to develop GIB.¹⁰ With the increasing number of implanted CFVADs, many have postulated the reasons for the increased propensity to develop GIB in this population. In as early as 1958, Heyde¹¹ found increased rates of GIB in patients with aortic stenosis. Modern day CFVADs produce a continuous flow, which is similar to what is seen in patients with severe aortic stenosis. The severely stenotic valve creates high shear stress across the aortic leaflets leading to denaturing of von Willebrand factor (vWF) multimers, which promotes their destruction.^{10,12} With the proteolytic cleavage of this factor, patients develop acquired vWF disease that increases their propensity to bleed.¹³ In addition, CFVADs are known to alter the visceral circulation leading to an increased intraluminal pressure which leads to dilation of mucosal veins and AVM development.¹⁴ CFVADs also decrease gastrointestinal mucosal perfusion, which may lead to mucosal ischemia and an increased propensity to develop bleeding at those sites.¹⁵ The cause of GIB is likely a combination of all of these factors. Interestingly, after removal of the VAD with either cardiac recovery or a transplant, the episodes of GIB abate.⁹

Each individual, when presenting with an episode of GIB, may require readmission, reversal or cessation of anticoagulation, multiple imaging modalities to attempt to identify and treat the source of bleeding, and last, multiple transfusions. Each discontinuation of anticoagulation places the patient at risk for device thrombosis and potential embolization; thus a speedy diagnosis and therapy are important.⁵ Episodes of GIB may not be simply controlled with lowering INR or stopping the antiplatelet agent. Our study found that 64% of our patients had an INR < 1.5 on presentation suggesting that the INR alone was not responsible for the bleeding. Each diagnostic test requires time to complete and most require a bowel preparation that can affect the patient's hemodynamics caused by dehydration. During the work-up phase, patients receive multiple transfusions that increase the risk of antibody development and can affect the ability of the patient to receive a future heart transplant.¹⁶ Most importantly, despite recent improvements in technology, the traditional algorithms we use to treat GIB were primarily designed for the general population and are not specific for VAD patients.

Table 3. Subgroup Analysis of Gastrointestinal Bleeding

	Group A: Traditional Without Enteroscopy	Group B: Traditional With Enteroscopy	Group C: New Management Algorithm	<i>p</i> Value
Episodes	15	6	7	
Enteroscopy	Never	Late	Early	
Average transfused packed red cells	4.1	6.3	1.3	0.001
Days to treatment	n/a	5.3	0.4	0.0002
Average number of tests performed	2.4	3.5	1.1	0.005

Group A: episodes where no diagnosis was ever made and patients did not undergo an enteroscopy. Group B: episodes that underwent multiple diagnostic/therapeutic modalities with enteroscopy being performed >24 hours after the admission for treatment. Group C: episodes where enteroscopy was performed within 24 hours of presentation.

Technology has seen many improvements during the last decade, especially when examining the small bowel. Our results showed that the majority of lesions were seen in the small intestine with the duodenum, jejunum, and ileum accounting for 69% of all lesions encountered. Aggarwal *et al.*³ showed that 57% of the patients they identified had the upper gastrointestinal tract including the proximal small bowel as the source of bleeding with 44% of them experiencing recurrent bleeding. In their cohort of patients, Elmunzer *et al.*¹⁷ discovered that almost all subjects sustained hemorrhage from an upper gastrointestinal source which confirms our belief that the initial focus for a source needs to be the proximal gastrointestinal tract.

Bleeding from the small intestine used to be difficult to diagnose because of the lack of adequate instruments to visualize the lumen with surgery being the only option.¹⁴ In 2001, the emergence of capsule endoscopy allowed us to visualize the lumen of the small intestine.¹⁸ The capsule, once swallowed, takes multiple images of the small bowel to identify the source of bleeding as it traverses through the intestine.¹⁹ Because capsule endoscopy is purely diagnostic, once a lesion is identified, patients require another procedure for treatment.²⁰

In early 2001, a new technology called DOAE was created and was being used to treat GIB. Yamamoto *et al.*²¹ reported on the first use of a double-balloon enteroscope which allowed access to the duodenum, jejunum, and ileum not only for visualization but also for concurrent treatment. The technology uses an enteroscope backloaded with an overtube to visualize the small intestine.¹⁹ The overtube and endoscope each have a balloon on the end; once the scope enters the small bowel, the balloons are sequentially inflated and deflated while the overtube is retracted and the enteroscope is advanced.¹⁹ This congruent sequence "pleats" the small bowel over the enteroscope allowing it to advance further in the small bowel. Since 2001, single-balloon enteroscopy and spirus enteroscopy have also emerged. Single-balloon enteroscopy uses an overtube like in double-balloon enteroscopy, whereas spirus enteroscopy uses a helical overtube which is also backloaded over the enteroscope. The overtube has raised ridges wrapped circumferentially, similar to a cork-screw, and when rotated, will pleat the bowel in a circular manner over the overtube allowing for the visualization of the small bowel.²² Diagnostic yields, when compared between single-balloon enteroscopy and spiral enteroscopy, are not statistically significant,²³ and the rate of complications remains low. Complications of these technologies, when used exclusively for diagnosis, are less than 1% but may approach 4% when used for treatment.²⁴ Elmunzer *et al.*¹⁷ point out that enteroscopy is safe and essential to evaluate

the gastrointestinal tract and paramount to treatment of GIB in patients with a VAD.¹⁷ Each of these new technologies has been developed during the last decade and offer VAD patients with GIB a quick diagnosis and therapy of the most commonly found lesions in the small bowel, thus eliminating additional tests and reducing the time to treatment.

Looking at the characteristics of the patients in our study, patients with a pulsatile VAD did not experience a single episode thus, all of our GIB was observed in CFVAD. The majority of patients (92%) presented with a sentinel bleed within the first year of implant. The most common location of GIB was in the duodenum and jejunum (67%), whereas the colon only accounted for 16%. With most of our lesions being confined to the proximal small bowel (stomach, duodenum, and jejunum), enteroscopy was successful in treating these lesions on the first pass. Approximately one third of the GIB lesions were confined to the jejunum and ileum and would not be diagnosed without capsule endoscopy or DOAE and be missed. Patients who received enteroscopy on initial presentation, received fewer units of packed red blood cells, fewer diagnostic tests, and had a decreased time to diagnosis and treatment when compared with patients who received DOAE after other tests had been done which failed to localize bleeding or in patients who did not have DOAE done at all. The episodes where the new technology of DOAE was used did not experience any complications or adverse events. This discovery led us to create a new GIB work-up algorithm (**Figure 2**) designed specifically for the VAD patient focusing on performing DOAE early in a patient's hospital course.

The focus of our new algorithm is prompt assessment of the most common location of bleeding in the gastrointestinal tract. Lower GIB can be screened at presentation by digital rectal examination and a careful medical history to identify conditions which can make the patient more prone to bleed from the colon. If lower GIB is suspected, colonoscopy should be scheduled. Otherwise, all patients without a history of lower GIB should be scheduled for a DOAE based on the frequency and most common locations of the offending lesions. Our data suggest a potential advantage of incorporating our new algorithm for the management of GIB in VAD patients.

Although our results proved to have statistical significance, our study has limitations. Our study was performed at a single center where the number of the patients is relatively small and a multicenter study would be ideal. A standardization of the management of GIB is essential; however, it is difficult because most centers are using an individually constructed management plan. In addition, the definition of GIB needs to be standardized; studies presented in the literature use multiple

definitions and make comparison of significant events very difficult between centers. Randomized comparison between the traditional GIB algorithm and our new algorithm will be difficult at our institution because we are no longer following the traditional algorithm.

Conclusion

With the population of VAD patients growing each year, physicians will be increasingly forced to deal with complications of this therapy. We identified that most GIB lesions in patients with CFVAD are AVMs and are located either in the stomach, duodenum, jejunum, or ileum. Noting the location of these lesions, only DOAE allows for the visualization and treatment of these lesions to occur during the same procedure without having to take the patient to surgery. The prompt initiation of enteroscopy, either double-balloon, single-balloon, or spirus, can allow for rapid identification and treatment of these lesions, thereby limiting the number of tests performed and decreasing the number of transfusions that the patients receive.

Acknowledgment

The authors thank Barbra Ebert, CRNP, and Margaret M. Lusardi, BA, for data acquisition.

References

- Oz MC, Rose EA, Levin HR: Selection criteria for placement of left ventricular assist devices. *Am Heart J* 129: 173–177, 1995.
- Kirklin JK, Naftel DC, Pagani FD, et al: Long-term mechanical circulatory support (destination therapy): On track to compete with heart transplantation? *J Thorac Cardiovasc Surg* 144: 584–603; discussion 597, 2012.
- Aggarwal A, Pant R, Kumar S, et al: Incidence and management of gastrointestinal bleeding with continuous flow assist devices. *Ann Thorac Surg* 93: 1534–1540, 2012.
- John R, Kamdar F, Eckman P, et al: Lessons learned from experience with over 100 consecutive HeartMate II left ventricular assist devices. *Ann Thorac Surg* 92: 1593–9; discussion 1599, 2011.
- Reisner EG, Kostyu DD, Phillips G, Walker C, Dawson DV: Alloantibody responses in multiply transfused sickle cell patients. *Tissue Antigens* 30: 161–166, 1987.
- Lannan KL, Sahler J, Spinelli SL, Phipps RP, Blumberg N: Transfusion immunomodulation—The case for leukoreduced and (perhaps) washed transfusions. *Blood Cells Mol Dis* 50: 61–68, 2013.
- Sarosiek K, Hirose H, Pitcher HT, Cavarocchi NC: Adult extracorporeal membrane oxygenation and gastrointestinal bleeding from small bowel arteriovenous malformations: A novel treatment using spiral enteroscopy. *J Thorac Cardiovasc Surg* 143: 1221–1222, 2012.
- John R, Kamdar F, Liao K, Colvin-Adams M, Boyle A, Joyce L: Improved survival and decreasing incidence of adverse events with the HeartMate II left ventricular assist device as bridge-to-transplant therapy. *Ann Thorac Surg* 86: 1227–34; discussion 1234, 2008.
- Stern DR, Kazam J, Edwards P, et al: Increased incidence of gastrointestinal bleeding following implantation of the HeartMate II LVAD. *J Card Surg* 25: 352–356, 2010.
- Crow S, John R, Boyle A, et al: Gastrointestinal bleeding rates in recipients of nonpulsatile and pulsatile left ventricular assist devices. *J Thorac Cardiovasc Surg* 137: 208–215, 2009.
- Heyde E: Gastrointestinal bleeding in aortic stenosis. *N Engl J Med* 259: 196, 1958.
- Suarez J, Patel CB, Felker GM, Becker R, Hernandez AF, Rogers JG: Mechanisms of bleeding and approach to patients with axial-flow left ventricular assist devices. *Circ Heart Fail* 4: 779–784, 2011.
- Crow S, Chen D, Milano C, et al: Acquired von Willebrand syndrome in continuous-flow ventricular assist device recipients. *Ann Thorac Surg* 90: 1263–1269, 2010.
- Kochhar GS, Sanaka MR, Vargo JJ: Therapeutic management options for patients with obscure gastrointestinal bleeding. *Therap Adv Gastroenterol* 5: 71–81, 2012.
- Demirozu ZT, Radovancevic R, Hochman LF, et al: Arteriovenous malformation and gastrointestinal bleeding in patients with the HeartMate II left ventricular assist device. *J Heart Lung Transplant* 30: 849–853, 2011.
- Coppage M, Baker M, Fialkow L, et al: Lack of significant de novo HLA allosensitization in ventricular assist device recipients transfused with leukoreduced, ABO identical blood products. *Hum Immunol* 70: 413–416, 2009.
- Elmunzer BJ, Elmunzer BJ, Padhya KT, et al: Endoscopic findings and clinical outcomes in ventricular assist device recipients with gastrointestinal bleeding. *Dig Dis Sci* 56: 3241–3246, 2011.
- Iddan G, Meron G, Glukhovskiy A, Swain P: Wireless capsule endoscopy. *Nature* 405: 417, 2000.
- Semrad CE: Small bowel enteroscopy: Territory conquered, future horizons. *Curr Opin Gastroenterol* 25: 110–115, 2009.
- Teshima CW: Small bowel endoscopy for obscure GI bleeding. *Best Pract Res Clin Gastroenterol* 26: 247–261, 2012.
- Yamamoto H, Sekine Y, Sato Y, et al: Total enteroscopy with a non-surgical steerable double-balloon method. *Gastrointest Endosc* 53: 216–220, 2001.
- Voelkel JP, Di Palma JA: Deep enteroscopy. *South Med J* 103: 1045–1048, 2010.
- Khashab MA, Lennon AM, Dunbar KB, et al: A comparative evaluation of single-balloon enteroscopy and spiral enteroscopy for patients with mid-gut disorders. *Gastrointest Endosc* 72: 766–772, 2010.
- Buscaglia JM, Okolo PI 3rd: Deep enteroscopy: Training, indications, and the endoscopic technique. *Gastrointest Endosc* 73: 1023–1028, 2011.