Thomas Jefferson University
Jefferson Digital Commons

Department of Surgery Faculty Papers | Department of Surgery

November 2012

Fate of the lower extremity in patients with VA-ECMO via femoral cannulation

Hitoshi Hirose
Thomas Jefferson University, Hitoshi.Hirose@Jefferson.edu

Kathleen Lamb
Thomas Jefferson University, Kathleen.Lamb@jefferson.edu

Neil Moudgill
Thomas Jefferson University

Paul Dimuzio
Thomas Jefferson University, Paul.Dimuzio@jefferson.edu

Megan McCullough
Thomas Jefferson University, Megan.McCullough@jefferson.edu

See next page for additional authors

Let us know how access to this document benefits you

Follow this and additional works at: http://jdc.jefferson.edu/surgeryfp

Part of the Surgery Commons

Recommended Citation

Lamb KM, Moudgill N, McCullough M, Karbowski P, Rao A, DiMuzio P, Hirose H, Cavarocchi NC, Eisenberg J. Fate of the lower extremity in patients with VA-ECMO via femoral cannulation. Presented at 50th Annual Meeting of the Eastern Cardiothoracic Surgical Society, Naples, FL, October 4-6, 2012.

This Article is brought to you for free and open access by the Jefferson Digital Commons. The Jefferson Digital Commons is a service of Thomas Jefferson University's Center for Teaching and Learning (CTL). The Commons is a showcase for Jefferson books and journals, peer-reviewed scholarly publications, unique historical collections from the University archives, and teaching tools. The Jefferson Digital Commons allows researchers and interested readers anywhere in the world to learn about and keep up to date with Jefferson scholarship. This article has been accepted for inclusion in Department of Surgery Faculty Papers by an authorized administrator of the Jefferson Digital Commons. For more information, please contact: JeffersonDigitalCommons@jefferson.edu.

Authors
Hitoshi Hirose, Kathleen Lamb, Neil Moudgill, Paul Dimuzio, Megan McCullough, Pawel Karbowski, Atul Rao, Nicholas Cavarocchi, and Joshua Eisenberg

This poster is available at Jefferson Digital Commons: http://jdc.jefferson.edu/surgeryfp/68

Fate of the lower extremity in patients with VA-ECMO via femoral cannulation

Kathleen Lamb MD, Neil Moudgill MD, Paul DiMuzio MD, Megan McCullough NP, Pawel Karbowski PA, Atul Rao MD, Hitoshi Hirose MD, Nicholas C. Cavarocchi MD, Joshua Eisenberg MD.
Thomas Jefferson University Hospital, Philadelphia PA

Introduction

Femoral cannulation for Veno-Arterial (VA)-ECMO is associated with limb complications, including ischemia, limb loss, arterial infections and wound infections. Ischemia is reported in 10-70% [1-6] of cases , with decreased rates of ischemia when distal perfusion catheters (DPC) are used.[3,5-6] Near infared spectroscopy (NIRS) can be used for early detection of ischemia.[7-8] No protocol has been established to address these limb complications.

Hypothesis

A protocol including placement of distal arterial cannulas, continuous limb oximetry with NIRS, open repair of arteriotomy at decannulation and attentive wound management, will decrease rates of limb complications, particularly ischemia, related to ECMO cannulation.

Methods

A retrospective review was conducted in 17 patients requiring VA- ECMO via femoral cannulation for cardiopulmonary failure from 1/2010–4/2012.

DPC were placed during cannulation if feasible, otherwise limbs were monitored for ischemia and reattempted if necessary. All patients had continuous limb oximetry (NIRS) leads placed on bilateral lower extremities while on ECMO.

Study endpoints included: ischemia, limb loss, arterial infections, wound infections.

Arterial cannula sizes were 16-20 Fr; DPC 4-5 Fr.

Low Oximetry Tracing Protocol was followed if abnormal tracings were detected on limb oximetry (NIRS).

Low Oximetry Tracing Protocol

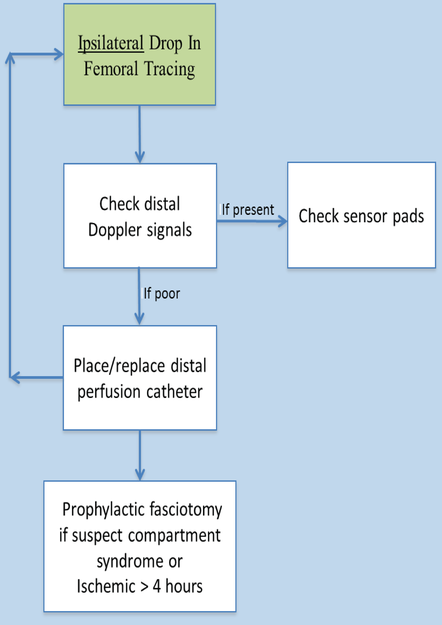

Results

17 patients supported with VA-ECMO during the study period

ISCHEMIC COMPLICATIONS

- 13/17 had successful DPC placement:
  - 9 placed at cannulation with no ischemia
  - 4 were placed after signs of ischemia developed, with resolution of symptoms
  - In 4 without DPC: only 2 developed ischemia: 1 was decannulated, 1 resolved spontaneously
  - 2/18 fasciotomies for ischemia: both without DPC initially
- At decannulation, open repair was performed of common femoral artery and vein, with bovine patch angioplasty in 4/15. Three patients had withdraw of care on ECMO, so no open decannulation.
- **No ischemia requiring amputations**

INFECTIOUS COMPLICATIONS

- **No arterial infections**
- 3/17 wound infections treated: vessels covered with autologous tissue, Vacuum assisted closure (VAC) therapy and antibiotics

SURVIVAL

- 11/17 survived to discharge

Conclusions

Ischemia is decreased when detected early with NIRS and when DPC are used. Open repair of the arteriotomy can prevent stenosis. Wound management using VAC therapy heals femoral wounds and prevents arterial infections.

Femoral Cannulation Protocol

Cannulation Continuous limb oximetry Distal perfusion catheter placement if able or signs of ischemia
Decannulation Open repair of arteriotomies +/- patch angioplasty
Wound management Early drainage , antibiotics, wound VAC

References

[1] Bisdas T, et al. Vascular complications in patients undergoing femoral cannulation for extracorporeal membrean oxygenation support. *Ann Thorac Surg.* 2011;92:626-31. [2]Zimpfer D, et al. Late vascular complications after extracorporeal membrane oxygenation support. *Ann Thorac Surg.* 2006;81:892-5. [3]Huang SC, et al. Pressure criterion for placement of distal perfusion catheter to prevent limb ischemia during adult extracorporeal life support *J Thorac Cardiovasc Surg.* 2004;128:776-7. [4]D'Alessandro C, et al. Extracorporeal membrane oxygenation temporary support for early graft failure after cardiac transplantation. *Eur J Cardiothorac* Surg. 2010;37:343-9. [5]Foley PJ, et al. Limb ischemia during femoral cannulation for cardiopulmonary support.. *J Vasc Surg.* 2010; 52: 850–853. [6]Madershahian N, et al. A simple technique of distal limb perfusion during prolonged femoro-femoral cnanulation. *J Card Surg.* 2006;21:168-9. [7]Wong JK, et al. Cerebral and lower limb near-infrared spectroscopy in adults on ECMO. Artif Organs. 2012 Aug;36(8):659-67. [8]Schachner T, et al. Near infared spectroscopy for controlling the quality of distal leg perfusion in remote access cardiopulmonary bypass. *E J Thorac Surg.* 2008;34:1253-4.

Contact Information

Nicholas Cavarocchi, MD, Nicholas.cavarocchi@jefferson.edu

Fate of the lower extremity in patients with VA-ECMO via femoral cannulation

Kathleen Lamb MD, Neil Moudgill MD, Paul DiMuzio MD, Megan McCullough NP, Pawel Karbowski PA, Atul Rao MD, Hitoshi Hirose MD, Nicholas C. Cavarocchi MD, Joshua Eisenberg MD.
Thomas Jefferson University Hospital, Philadelphia PA

Introduction

Femoral cannulation for Veno-Arterial (VA)-ECMO is associated with limb complications, including ischemia, limb loss, arterial infections and wound infections. Ischemia is reported in 10-70% [1-6] of cases , with decreased rates of ischemia when distal perfusion catheters (DPC) are used.[3,5-6] Near infared spectroscopy (NIRS) can be used for early detection of ischemia.[7-8] No protocol has been established to address these limb complications.

Hypothesis

A protocol including placement of distal arterial cannulas, continuous limb oximetry with NIRS, open repair of arteriotomy at decannulation and attentive wound management, will decrease rates of limb complications, particularly ischemia, related to ECMO cannulation.

Methods

A retrospective review was conducted in 17 patients requiring VA- ECMO via femoral cannulation for cardiopulmonary failure from 1/2010–4/2012.

DPC were placed during cannulation if feasible, otherwise limbs were monitored for ischemia and reattempted if necessary. All patients had continuous limb oximetry (NIRS) leads placed on bilateral lower extremities while on ECMO.

Study endpoints included: ischemia, limb loss, arterial infections, wound infections.

Arterial cannula sizes were 16-20 Fr; DPC 4-5 Fr.

Low Oximetry Tracing Protocol was followed if abnormal tracings were detected on limb oximetry (NIRS).

Low Oximetry Tracing Protocol

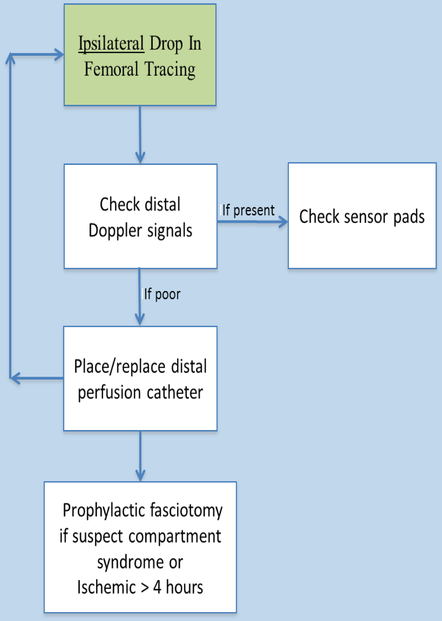

Results

17 patients supported with VA-ECMO during the study period

ISCHEMIC COMPLICATIONS

- 13/17 had successful DPC placement:
  - 9 placed at cannulation with no ischemia
  - 4 were placed after signs of ischemia developed, with resolution of symptoms
  - In 4 without DPC: only 2 developed ischemia: 1 was decannulated, 1 resolved spontaneously
  - 2/18 fasciotomies for ischemia: both without DPC initially
- At decannulation, open repair was performed of common femoral artery and vein, with bovine patch angioplasty in 4/15. Three patients had withdraw of care on ECMO, so no open decannulation.
- **No ischemia requiring amputations**

INFECTIOUS COMPLICATIONS

- **No arterial infections**
- 3/17 wound infections treated: vessels covered with autologous tissue, Vacuum assisted closure (VAC) therapy and antibiotics

SURVIVAL

- 11/17 survived to discharge

Conclusions

Ischemia is decreased when detected early with NIRS and when DPC are used. Open repair of the arteriotomy can prevent stenosis. Wound management using VAC therapy heals femoral wounds and prevents arterial infections.

Femoral Cannulation Protocol

Cannulation Continuous limb oximetry Distal perfusion catheter placement if able or signs of ischemia
Decannulation Open repair of arteriotomies +/- patch angioplasty
Wound management Early drainage , antibiotics, wound VAC

References

[1] Bisdas T, et al. Vascular complications in patients undergoing femoral cannulation for extracorporeal membrean oxygenation support. *Ann Thorac Surg.* 2011;92:626-31. [2]Zimpfer D, et al. Late vascular complications after extracorporeal membrane oxygenation support. *Ann Thorac Surg*. 2006;81:892-5. [3]Huang SC, et al. Pressure criterion for placement of distal perfusion catheter to prevent limb ischemia during adult extracorporeal life support *J Thorac Cardiovasc Surg.* 2004;128:776-7. [4]D'Alessandro C, et al. Extracorporeal membrane oxygenation temporary support for early graft failure after cardiac transplantation. *Eur J Cardiothorac* Surg. 2010;37:343-9. [5]Foley PJ, et al. Limb ischemia during femoral cannulation for cardiopulmonary support.. *J Vasc Surg*. 2010; 52: 850–853. [6]Madershahian N, et al. A simple technique of distal limb perfusion during prolonged femoro-femoral cnanulation. *J Card Surg*. 2006;21:168-9. [7]Wong JK, et al. Cerebral and lower limb near-infrared spectroscopy in adults on ECMO. Artif Organs. 2012 Aug;36(8):659-67. [8]Schachner T, et al. Near infared spectroscopy for controlling the quality of distal leg perfusion in remote access cardiopulmonary bypass. *E J Thorac Surg.* 2008;34:1253-4.

Contact Information

Nicholas Cavarocchi, MD, Nicholas.cavarocchi@jefferson.edu