

November 2012

# Novel approach to monitoring renal perfusion with the use of continuous renal oximetry in the setting of aortic dissection

Hitoshi Hirose

*Thomas Jefferson University, Hitoshi.Hirose@jefferson.edu*

Philip Batista

*Thomas Jefferson University, Philip.Batista@jefferson.edu*

Nicholas C. Cavarocchi

*Thomas Jefferson University, nicholas.cavarocchi@jefferson.edu*

## Let us know how access to this document benefits you

Follow this and additional works at: <http://jdc.jefferson.edu/surgeryfp>

 Part of the [Surgery Commons](#)

### Recommended Citation

Batista P, Cavarocchi N, Hirose H. Novel approach to monitoring renal perfusion with the use of continuous renal oximetry in the setting of aortic dissection. Presented at Chest 2012, Atlanta GA, October 20-25.

This Article is brought to you for free and open access by the Jefferson Digital Commons. The Jefferson Digital Commons is a service of Thomas Jefferson University's [Center for Teaching and Learning \(CTL\)](#). The Commons is a showcase for Jefferson books and journals, peer-reviewed scholarly publications, unique historical collections from the University archives, and teaching tools. The Jefferson Digital Commons allows researchers and interested readers anywhere in the world to learn about and keep up to date with Jefferson scholarship. This article has been accepted for inclusion in Department of Surgery Faculty Papers by an authorized administrator of the Jefferson Digital Commons. For more information, please contact: [JeffersonDigitalCommons@jefferson.edu](mailto:JeffersonDigitalCommons@jefferson.edu).

# Novel Approach to Monitoring Renal Perfusion with the use of Continuous Renal Oximetry in the Setting of Aortic Dissection

Philip M. Batista, MD, Nicholas C. Cavarocchi, MD, Hitoshi Hirose, MD

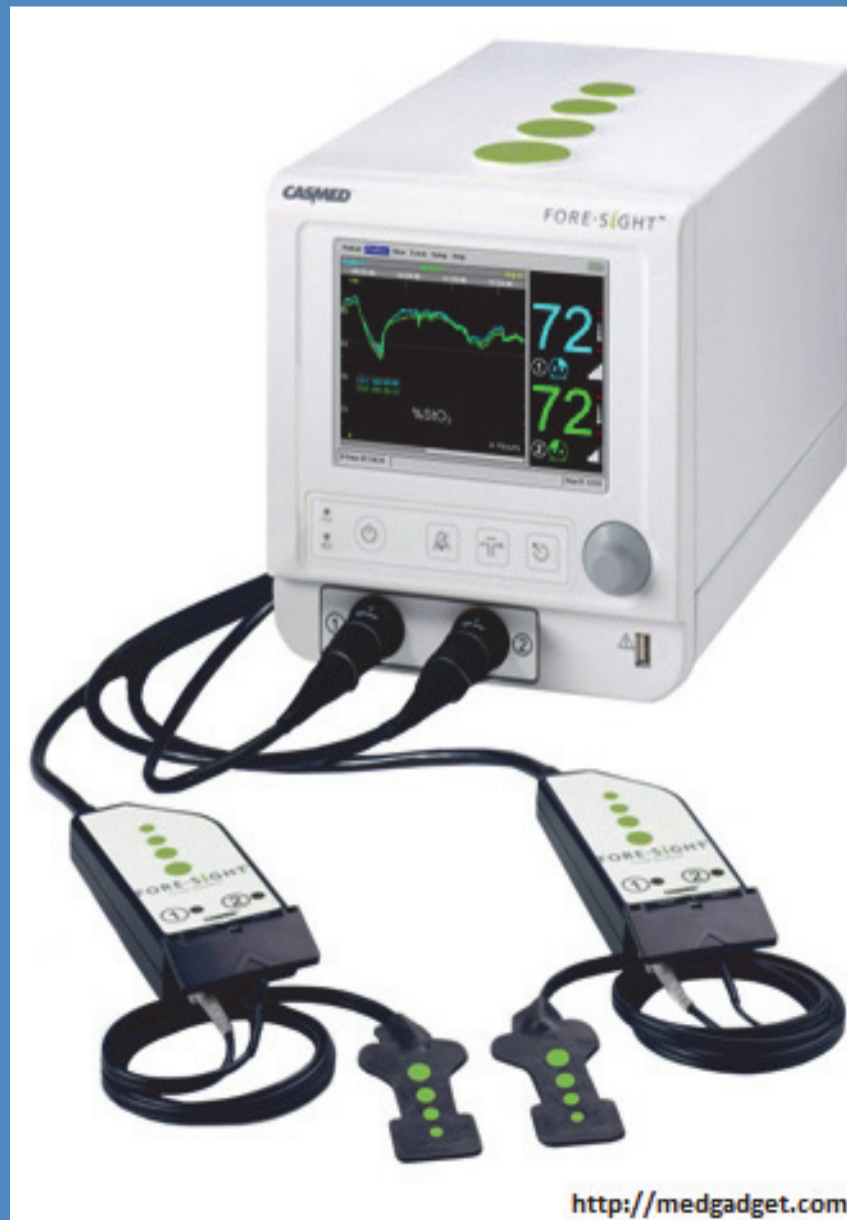Department of Surgery, Division of Cardiothoracic Surgery, Thomas Jefferson University Hospital, Philadelphia, PA, United States

## Introduction

Aortic dissections commonly extend beyond the renal arteries with varying effects ranging from asymptomatic to renal failure. We report a case of aortic dissection with initial renal compromise, which was continuously monitored utilizing direct renal oximetry for evaluation of real-time renal perfusion and function.

## FORE-SIGHT Oximeter

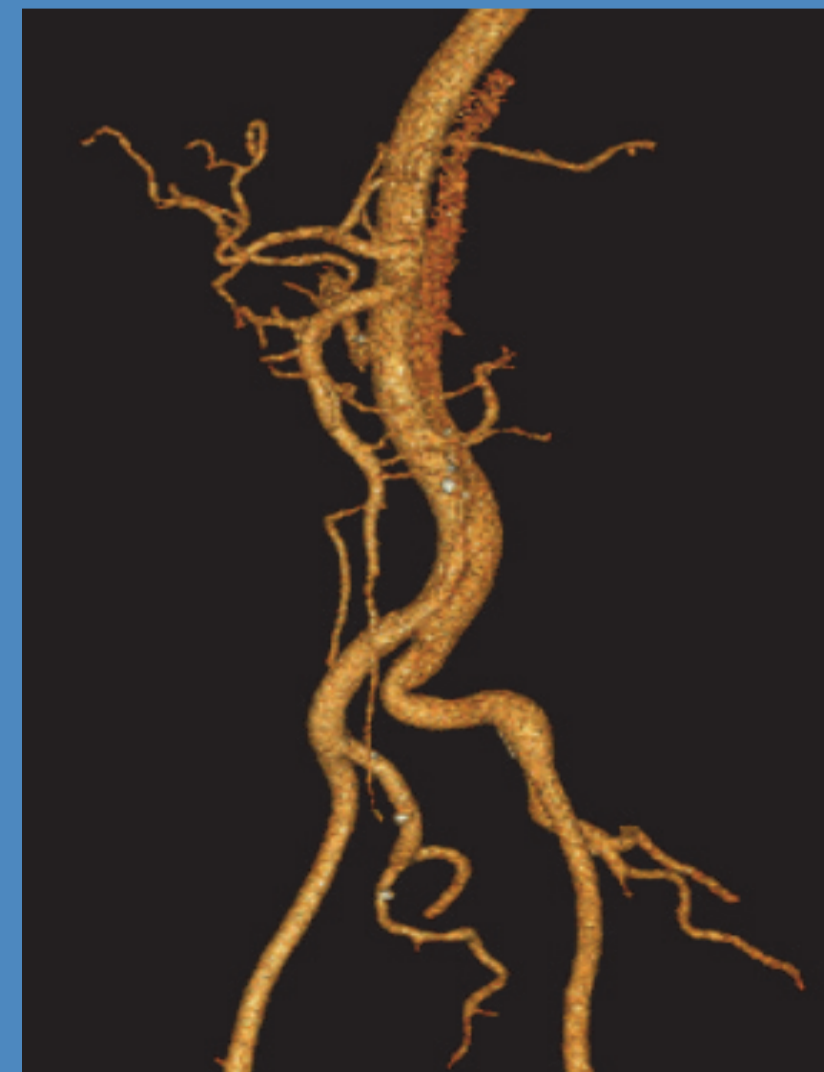
- Safe, Non-invasive
- Laser diode narrows spectral bandwidth compared to standard LED
- Multiple light detectors for varying depths and noise cancellation
- Bases tissue perfusion on both arterial and venous saturations without need for pulsatile flow
- Direct absolute measurements that correlated to blood co-oximetry



## Case Presentation

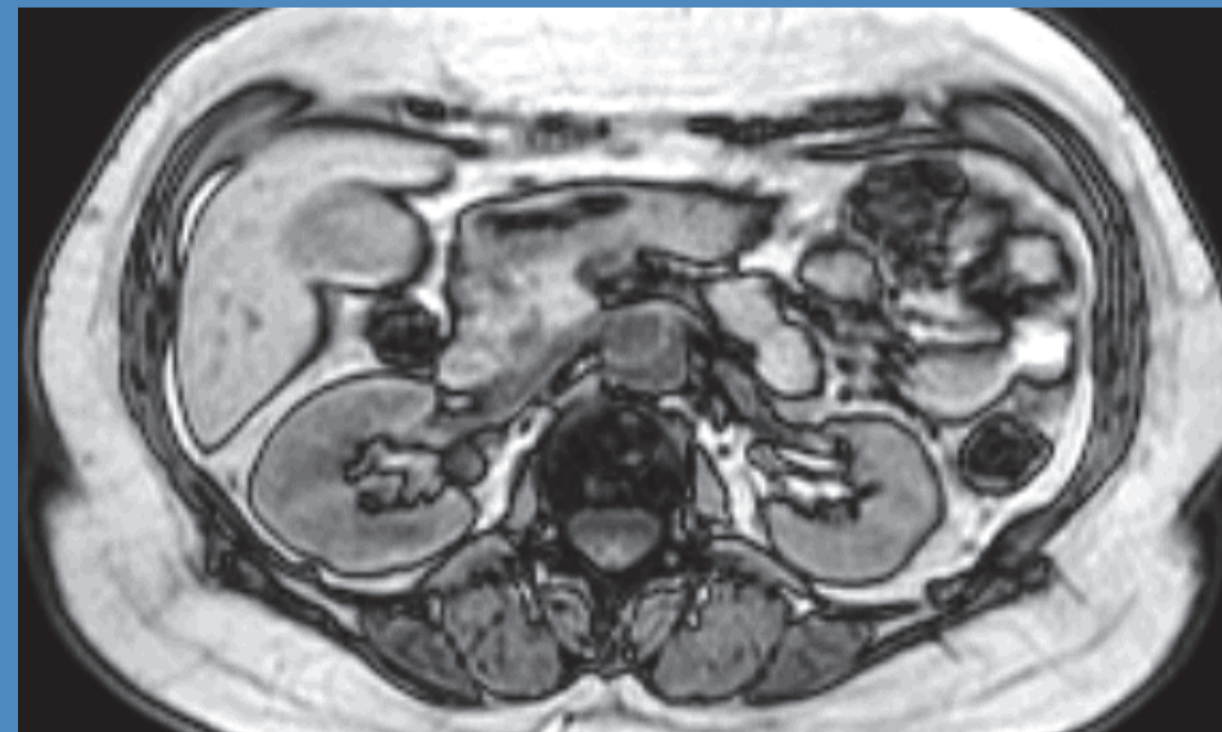65 year-old female with a long history of hypertension presented with acute retrosternal chest pain radiating to the back for 12 hours.

- MRA demonstrated a type A dissection
- Left renal artery perfused via the false lumen
- Initial serum creatinine of 1.6mg/dl.
- Operative management: aortic root repair with graft.



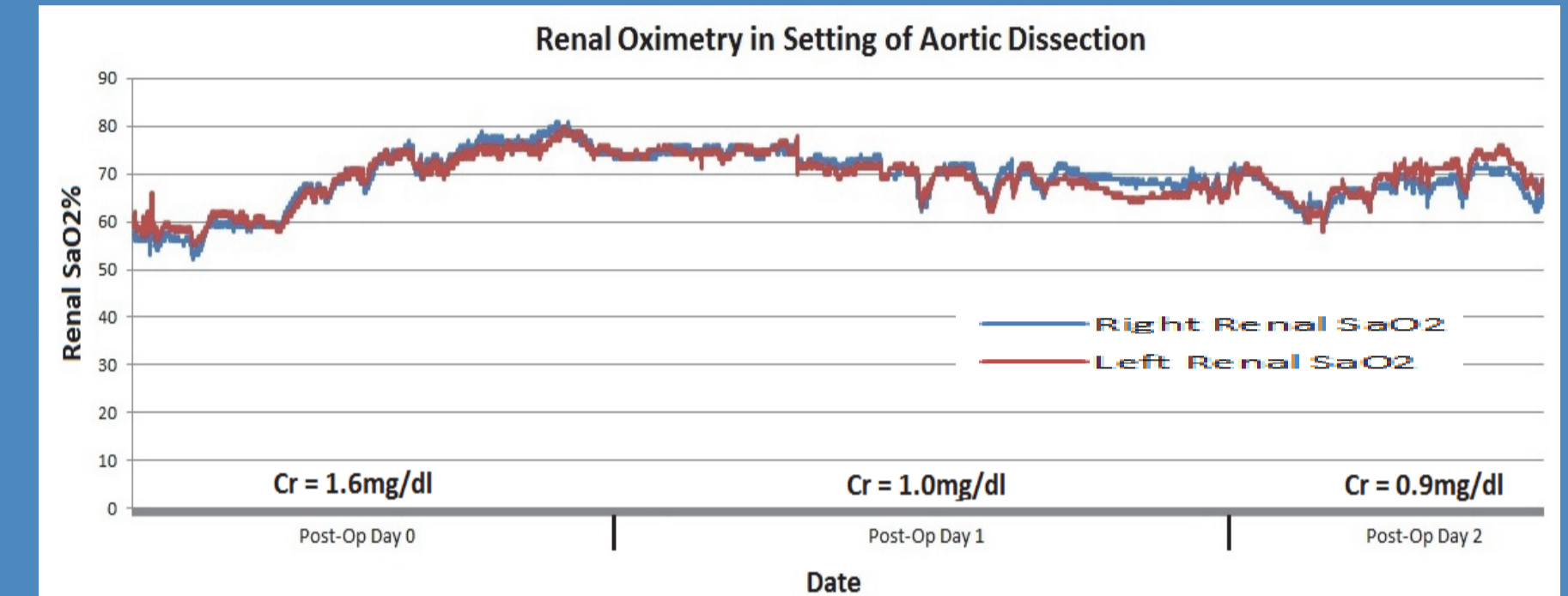
FORE-SIGHT oximetry monitoring was placed on each kidney utilizing pre-operative imaging.

- Absolute renal tissue oxygen saturation was recorded for 3 consecutive days post-operatively.
- Right kidney = 31 hours at >60% saturation (89%)
- Left kidney = 32 hours at >60% saturation (92%)
- Neither kidney recorded saturations below 52%
- Serum creatinine cleared to baseline
- CT angiography confirmed perfusion in both kidneys.



## Contact

Hitoshi Hirose MD  
Associate Professor Of Surgery  
Cardiac Critical Care Attending  
[Hitoshi.Hirose@jefferson.edu](mailto:Hitoshi.Hirose@jefferson.edu)



## Discussion

Distal organ perfusion can be a difficult assessment to make in the setting of aortic dissection. The laser technology utilized by FORE-SIGHT implements precise and narrow wavelengths proven to provide more accurate and absolute oxygen saturation values. By utilizing FORE-SIGHT oximetry in conjunction with imaging for precise placement, our group was able to accurately monitor renal perfusion in real time as opposed to waiting for contrast CT scan or traditional secondary markers such as serum creatinine and urine output. Saturations were maintained at expected levels throughout the post-operative course and renal function improved. This novel approach may serve a role in adjusting for renal oxygenation and subsequent perfusion in order to prevent renal failure in variety of settings from aortic injury to open cardiac procedures

## Conclusion

Renal oximetry may serve as an additional tool in evaluating, and potentially preventing, renal injury in the setting of aortic dissection as well as other poor perfusing states such as ECMO and cardiovascular surgery,