

9-1-2012

# Massive haemoptysis on veno-arterial extracorporeal membrane oxygenation.

Meredith Harrison

*Thomas Jefferson University, meredith.harrison@jefferson.edu*

Scott W. Cowan

*Thomas Jefferson University, Scott.Cowan@jefferson.edu*

Nicholas C. Cavarocchi

*Thomas Jefferson University, nicholas.cavarocchi@jefferson.edu*

Hitoshi Hirose

*Thomas Jefferson University, Hitoshi.Hirose@jefferson.edu*

## [Let us know how access to this document benefits you](#)

Follow this and additional works at: <http://jdc.jefferson.edu/surgeryfp>Part of the [Surgery Commons](#)

### Recommended Citation

Harrison, Meredith; Cowan, Scott W.; Cavarocchi, Nicholas C.; and Hirose, Hitoshi, "Massive haemoptysis on veno-arterial extracorporeal membrane oxygenation." (2012). *Department of Surgery Faculty Papers*. Paper 77.

<http://jdc.jefferson.edu/surgeryfp/77>

**As submitted to:**

***European Journal of Cardio-Thoracic Surgery***

**And later published as:**

**Massive Hemoptysis on Veno-Arterial Extracorporeal  
Membrane Oxygenation (VA-ECMO)**

**Volume 42, Issue 3, March 30, 2012, Pages: 587-589.**

**doi: 10.1093/ejcts/ezs156**

Meredith Harrison, MD, Scott Cowan, MD, Linda Bogar, MD, Nathaniel Evans, MD, Harrison Pitcher, MD, Nicholas Cavarocchi, MD, Hirose Hitoshi, MD.

From Department of Surgery, Thomas Jefferson University  
605 College Building, 1025 Walnut Street, Philadelphia, PA 19107

Running Head: Massive hemoptysis on VA-ECMO  
**Word count 747 (main text only Max allowance 750)**

The abstract was presented at the 49<sup>th</sup> Annual Meeting of the Eastern Cardiothoracic Surgical Society, National Harbor, Maryland.

Corresponding Author: Hitoshi Hirose, MD, FCCP.  
Department of Surgery, Thomas Jefferson University  
605 College Building, 1025 Walnut Street, Philadelphia, PA 19107  
Phone: 215-518-4418, Email: [genex@nifty.com](mailto:genex@nifty.com)

Meredith Harrison, MD.  
Department of Surgery, Thomas Jefferson University  
[meredith.harrison@jeffersonhospital.org](mailto:meredith.harrison@jeffersonhospital.org)

Scott Cowan MD.  
Department of Surgery, Thomas Jefferson University  
[Scott.cowan@jefferson.edu](mailto:Scott.cowan@jefferson.edu)

Nathaniel Evans MD, FCCP.  
Department of Surgery, Thomas Jefferson University  
[Nathaniel.evans@jefferson.edu](mailto:Nathaniel.evans@jefferson.edu)

Linda Bogar, MD.  
Department of Surgery, Thomas Jefferson University  
[Linda.Bogar@jefferson.edu](mailto:Linda.Bogar@jefferson.edu)

Harrison Pitcher, MD.  
Department of Surgery, Thomas Jefferson University  
[Harrison.pitcher@jefferson.edu](mailto:Harrison.pitcher@jefferson.edu)

Nicholas Cavarocchi, MD.  
Department of Surgery, Thomas Jefferson University  
[Nicholas.Cavarocchi@jefferson.edu](mailto:Nicholas.Cavarocchi@jefferson.edu)

Hitoshi Hirose MD, FCCP.  
Department of Surgery, Thomas Jefferson University  
[genex@nifty.com](mailto:genex@nifty.com)

None of the authors have any financial or personal support to report and have no conflicts of interest.

### **Abstract**

A 49-year-old female presented with severe heart failure with end-organ dysfunction and was placed on veno-arterial ECMO for bridge to a decision for end organ recovery. While on ECMO, the patient developed massive hemoptysis after Swan-Ganz catheter manipulation. The hemoptysis was not controllable by conventional methods including bronchoscopy with cold saline and epinephrine application, balloon hemostasis or angiography. The endotracheal tube was clamped to provide tamponade and the patient relied on full ECMO support for 36 hours. After the hemoptysis resolved, the endotracheal tube was unclamped and the patient developed ARDS and was ventilated using the ARDSnet protocol with continued support from ECMO. On post-ECMO day 20, the patient underwent successful ECMO wean and a Heart Mate II left ventricular assist device placement. (**Abstract word count 123, Max 150**)

## Introduction

ECMO is an extracorporeal technique of providing both cardiac and/or respiratory support to patients whose heart and lungs are so severely diseased or damaged that they can no longer serve their function. Potential complications of ECMO are often associated with the anticoagulation, including subarachnoid hemorrhage, retroperitoneal hematoma, hemorrhage at the surgical site, and hemoptysis. We present a patient who developed massive hemoptysis while on ECMO related to manipulation of a Swan-Ganz catheter.

## Case Report

A 49 year old female with a history of non-ischemic cardiomyopathy secondary to adriamycin chemotherapy for breast cancer presented with decompensated biventricular congestive heart failure. Despite multiple inotrope support, there was no hemodynamic or clinical improvements; end-organ function worsened. At this time, VA-ECMO, via femoral vessels, was instituted as a bridge to decision for end organ recovery.

Forty eight hours after initiation of VA-ECMO, the patient developed massive hemoptysis following Swan-Ganz manipulation (Figure 1). Emergent bedside flexible bronchoscopy demonstrated massive hemorrhage from the right upper and lower airways. The heparin infusion was immediately stopped while blood products were given. Epinephrine and cold saline lavage through the endotracheal tube was unsuccessful. A right-sided bronchial blocker was placed, however the bleeding continued and overwhelmed the ventilator tubing. Finally, a clamp was placed on the endotracheal tube, the endotracheal tube balloon was maximally inflated, and the patient was disconnected from the ventilator while ECMO support continued (Figure 2). An urgent pulmonary arteriogram demonstrated no extravasation. A total of 8 units of fresh frozen plasma, 10 units of platelets, 4 units of packed red blood cells, and a dose of proflinone were used to optimize the hemostasis while the endotracheal tube was clamped. While clamped, the oxygen saturation was maintained above 95% and the cerebral tissue saturation was maintained above 50%. The endotracheal tube was unclamped 36 hours after the onset of hemoptysis; repeat bronchoscopy was performed demonstrating no further evidence of bleeding. Chest x-ray, arterial blood gas, and ventilator parameters were consistent with ARDS (ECMO  $\text{FiO}_2$  100%, ventilator  $\text{FiO}_2$  50%,  $\text{PaO}_2$  93, Peak airway pressure 35). The patient was placed on an ARDSnet ventilation protocol and maintained on full ECMO support. Heparin was restarted 60 hours after hemoptysis. Seven days after the event, the patient's chest x-ray, arterial blood gas, compliance and oxygen requirements improved (ECMO  $\text{FiO}_2$  50%, ventilator  $\text{FiO}_2$  50%,  $\text{PaO}_2$  147, Peak airway pressure 22). On post ECMO day 20, the patient underwent ECMO wean and decannulation; a Heart Mate II left ventricular assist device was successfully placed.

## Discussion

Massive hemoptysis is a devastating complication, especially in an anticoagulated patient on ECMO. There are established algorithms to follow in the event of massive hemoptysis presented by Sakr et al (1). Our patient underwent flexible bronchoscopy first, while concomitantly, received products for volume resuscitation and correction of coagulopathy. The next step was cold saline and epinephrine lavage, followed by balloon tamponade by a bronchial blocker, all of which were unsuccessful. At this time, the ventilator tubing continued to be overwhelmed with blood and stopped functioning. Because options were limited, we modified the algorithm to create a novel approach and we clamped the endotracheal tube to allow the entire airway to tamponade and increased the ECMO flows to optimize circulation and oxygenation. After hemoptysis, she developed ARDS; however, it was smoothly managed with

an ARDSnet protocol and ECMO support. This approach, to our knowledge, has never been described before

This case report forces a closer look at the use of Swan-Ganz catheters. Swan-Ganz catheterization is an invasive monitoring tool and its manipulation is associated with pulmonary artery rupture at an incidence of 0.03%-0.2%. Once the pulmonary artery ruptures, the risk of mortality is significantly as high as 70% (2, 3). Proposed risk factors for pulmonary artery rupture include elderly patients, pulmonary hypertension, improper balloon inflation, anticoagulation, cardiopulmonary bypass and improper catheter positioning, which our patient was affected by two of the these factors. In addition, in a patient on ECMO, the heart is decompressed and the Swan-Ganz catheter frequently migrates forward into distal pulmonary vasculature, which is likely what happened in our patient.

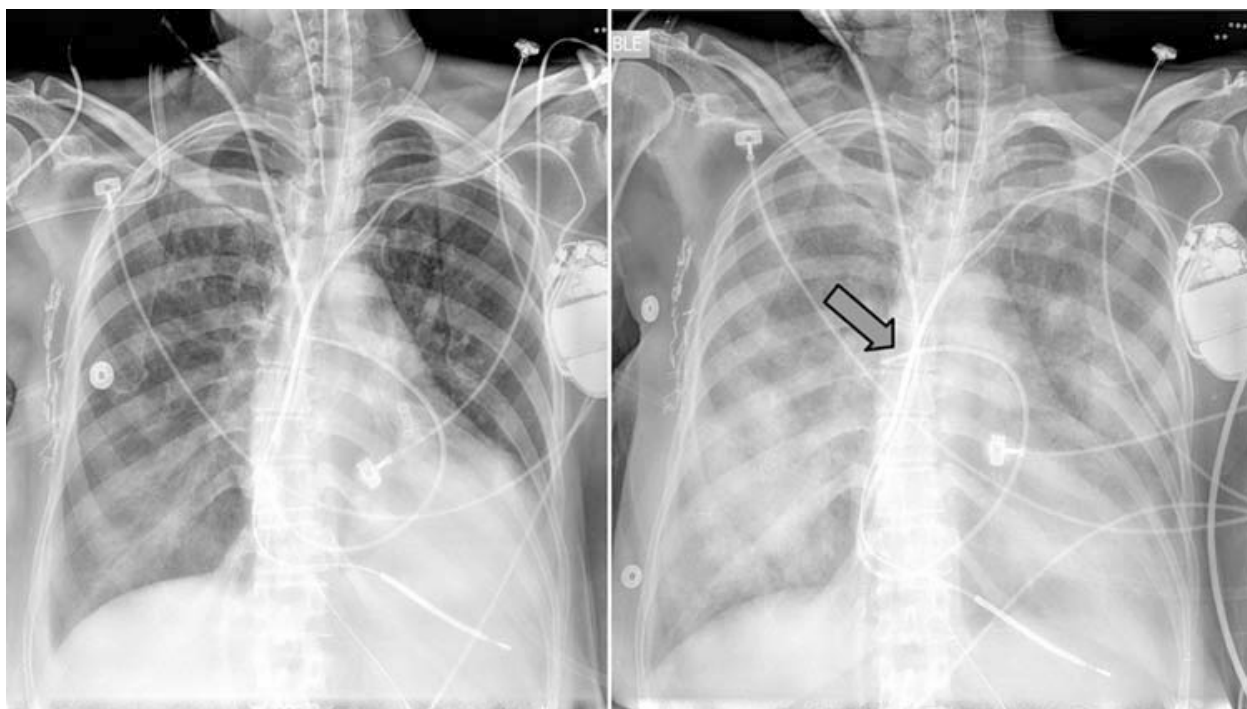
Successful management of massive hemoptysis on VA-ECMO has not been described in the literature. Our patient received full cardiorespiratory support provided by V-A ECMO without heparinization with concomitant clamping of the endotracheal tube and cessation of mechanical ventilation, which resulted in control of hemoptysis. Resultant ARDS from hemorrhagic aspiration resolved with full ECMO support and lung rest. Endotracheal tube clamping during VA-ECMO support is a novel therapeutic approach that proved to be successful in the resolution of massive hemoptysis and subsequent ARDS.

**References:**

1. L. Sakr, H. Dutau. Massive hemoptysis: an update on the role of bronchoscopy in diagnosis and management. *Respiration* 2010;80:38-58.
2. Evans DC, Doraiswamy VA, Prosciak MP, et al. Complications associated with pulmonary artery catheters: a comprehensive clinical review. *Scand J Surg* 2009;98:199–208.
3. Abreu AR, Campos MA, Krieger BP. Pulmonary artery rupture induced by a pulmonary artery catheter: a case report and review of the literature. *J Intensive Care Med.* 2004;19:291-296.

### Legends of figures

**Figure 1:** Chest x-ray of the patient before the hemoptysis on the right and after event on the left. An arrow shows that Swan-Ganz catheter is migrated into the secondary pulmonary artery.





**Figure 2:** Chest x-ray on the left shows bilateral pulmonary opacification suggesting massive hemoptysis. Please note the endotracheal tube was clamped. Chest x-ray on the right shows improved opacification.

