Clinical and Diagnostic Features of Patients with Compound Heterozygous A467T/W748S POLG1 Mutations: A Case Report and Review of Previous Cases

David Roshal, D.O., Andro Zangaladze, M.D. Ph.D.

Department of Neurology, Thomas Jefferson University Hospital, Philadelphia, PA

Introduction

Mutations in the POLG1 gene are considered to be the most common gene defect identified in autosomal recessive mitochondrial DNA depletion disorders [1]. POLG1 is a gene encoding the 195kDa catalytic (alpha) subunit of the mitochondrial (gamma) DNA polymerase, located on chromosome 15q25 and is responsible for mtDNA replication [1]. Mutations in POLG1 are associated with highly variable phenotypes. The vast majority of pathogenic mutations in POLG1 have been associated with chronic progressive external ophthalmoplegia (CPEO) [2]. Other genes that have been implicated in causing syndromic and non-syndromic mitochondrial disorders have been found on both mtDNA (3243A>G, 8344A>G, 8993T>G, and 11778A>G) and nDNA (SURF1, POLG1, TWINKLE, and ANT1) [3].

We report a patient with a rare type of POLG1 gene (A467T/W748S) mutation with a wide range of neurological manifestations, including, focal parieto-occipital lobe seizures, sensory axonal neuropathy, intestinal mal-absorption, and impairment of visual perception and other cognitive domains. Mitochondrial disorders can have a very insidious clinical course, which can make the diagnosis difficult especially if genetic workup for routinely tested mitochondrial disorders is negative. Treatment of the epilepsy in patients with POLG1 gene mutations, specifically the compound heterozygous A467T/W748S, can be very challenging. While some conventionally used anti-seizure medications can turn out to be ineffective, others such as valproic acid can have deleterious effects on neurological function and make the seizures worse.

Case Report

•A 16-year-old woman, who was an ex-preemie (GA 36 weeks) born by C-section after spontaneous rupture of membranes to non-consanguineous parents, developed over a one year period progressively worsening focal seizures refractory to oxcarbazepine, levetiracetam, and zonisamide. Topiramate was started but the patient developed cognitive side effects and was therefore stopped. Valproic acid was initiated which made the patient's cognitive symptoms and seizures worse, at which time the patient presented to our epilepsy monitoring unit with focal status epilepticus. Before the seizures started, the patient had done well in school with no learning disabilities. The patient had denied any known seizure risk factors and had no past medical history except for migraine headaches, depression, and anxiety. As an infant she had episodes of back arching and crying spells of long duration. As a toddler she had fear episodes with a sensation that the ceiling was falling down on her. In kindergarten she had episodes of starring spells. The patient had normal emergence of speech and ambulation.

•She described three seizure types: Focal twitching of the right face, arm, and leg followed sometimes by loss of awareness and a secondary generalized tonic-clonic convulsion with right head version lasting less than five minutes, which was followed by residual weakness on the right side and post-ictal confusion. The first seizure type would occur at a frequency of up to six times in a day. The second seizure type presented with either a right homonymous hemianopsia or colored balls in the right visual field that occurred several times daily and lasted for minutes to hours. The third seizure type was described as a feeling of numbness and tingling on the right side of the body that also occurred several times daily and lasted minutes to hours. Besides seizures the patient also complained of memory and word finding difficulties; nausea, abdominal discomfort, constipation, migraine headaches, brief episodes of diaphoresis and palpitations, and blurry vision, which have worsened of over the last six months.

•General physical exam revealed normal vital signs, obesity and abdominal striae. Neurological examination revealed abnormalities on mental status including: disorientation to date, fluent speech with word-finding difficulties, severe anomia with decreased categorical fluency, dyscalculia, alexia with agraphia, ideomotor and constructional apraxia, poor attention and concentration. Cranial nerve exam was noteworthy for downbeat and horizontal nystagmus, ocular dysmetria, right homonymous hemianopsia, bilateral tilted and atrophic optic nerves, and mild right central facial nerve palsy with the rest of the cranial nerves being grossly intact. On manual motor testing there was a right upper extremity drift with power of 4/5, right lower extremity was 4/5 with right foot drop, and the left upper and lower extremities were 5/5. Sensation was diminished to pain, temperature, vibration, and proprioception in all four extremities. On coordination testing the patient was unable to perform finger-to-nose or heel-to-shin and there was a positive Romberg sign. Gait was unsteady, wide-based, and ataxic with the patient leaning more to the right. Reflexes were hypoactive at +1/4 in the upper and lower extremities. Plantar cutaneous responses were flexor bilaterally with no clonus or pathologic spread.

•Based on the patient's clinical history of worsening seizures on valproate and multi-systemic symptoms, we initiated a work-up for a mitochondrial cytopathy and started the patient on 10% dextrose IV with L-carnitine and coenzyme Q-10. Her valproate was stopped and her seizures were improved with phenytoin. After measuring high serum lactate and pyruvate levels **(Figure 1)**, the patient was subjected to further testing including: echocardiogram, muscle biopsy, and routine genetic testing for mitochondrial disorders through Athena labs, which all came back negative.

Case Report

•MRI of the brain **(Figure 3)** revealed T2 hyperintensities in the left thalamus, left parietal and left occipital cortical regions,and right cerebellar white matter with corresponding restricted diffusion on DWI, as well as associated atrophy of the left parieto-occipital lobe. A continuous 24-hour scalp EEG **(Figure 2)** with video revealed frequent interictal parieto-occipital sharp waves in wakefulness and sleep, as well as frequent seizures with onset in the left parieto-occipital region with patient reporting seeing colored balls in the right visual field and tingling sensation on the right side of the body. There were also a few seizures detected in the left posterior temporal region, which were sub- clinical. The differential diagnosis at this point was extended to include: Rassmusen's encephalitis, cerebral autosomal dominant arteriopathy with subcortical infarcts and leukoencephalopathy (CADASIL), familial hemiplegic migraine (FHM), autosomal dominant ataxias, leukodystrophy, paraneoplastic disorder, as well as infectious, autoimmune, and neurodegenerative etiologies. Extensive laboratory and diagnostic testing **(Figure 1)** were performed over a period of several months in the outpatient setting and excluded the above conditions.

•The patient also had an EMG/NC study which detected the presence of a sensory axonal neuropathy. Routine neuropathy work-up revealed a vitamin B12 deficiency. The patient was also found to have a vitamin D deficiency and osteoporosis on a DEXA scan. Endocrine work-up as well as testing of pancreatic enzymes and celiac disease antibodies was negative. The presence of a wide range of neurological manifestations and intestinal malabsorption, with elevated levels of serum lactate and pyruvate, prompted further investigation into a mitochondrial disorder with additional genetic testing that was beyond what was available through the conventional Athena panel. This genetic test was sent out to a different lab, which identified a compound heterozygous A467T/W748S mutation in the POLG1 gene. The patient was restarted back on coenzyme Q-10 and continued on phenytoin for her seizures, with lamotrigine added later on. Since her discharge in 2007, her seizures have become less severe, with only infrequent simple somatosensory and visual focal seizures. She has also experienced some improvement in her neurological deficits, especially with correction of her vitamin B12 levels. Follow up MRI of the brain has shown resolution of the high T2 signal abnormalities in various cortical and subcortical regions, however, prominent left parieto-occipital atrophy remains.

Figure 1: Laboratory and Diagnostic Tests

Test	Result
CBC, CMP, TSH, HgA1C	Normal
Serum lactate	33.1 (4.5-19.8)
Serum pyruvate	0.154 (0.030-0.107)
CSF Cell count with diff	WBC 8 (0-5) with 65%L, RBC 9 (0-5), G 56, P 85(15-45)
CSF Protein Electrophoresis and SPEP	Normal with no oligoclonal bands
CSF Myelin Basic Protein	5.6 (0.07-4.10)
CSF HTLV-1, Lyme Ab, Herpes PCR	Normal
CSF Pyruvate	0.03 (0.06-0.19)
CSF LD	46 (11-22)
CSF Lactate	Normal
CADASIL, FHM, autosomal dominant ataxia panel	Negative
Mitochondrial disorders Athena panel	Normal
Vitamin B12	163 (180-900)
Methylmalonic acid	Normal
Vitamin D, 25-Hydroxy	8.4 (32-100)
Vitamin A, K, E	Normal
Celiac antibody panel	Normal
Pancreatic enzymes	Normal
Homocysteine	Normal
CPK and Aldolase	Normal
Muscle biopsy	Normal without ragged red fibers
Anti-GAD,VGKC,Hu,Ri,Yo,NMDA Ab	Normal
Urine Sulfatides	Normal
ANA, ESR, ENA, cANCA, and pANCA	Normal
Echocardiogram	Normal
DEXA scan	Osteoporosis
EMG/NC	Sensory axonal neuropathy
CA-125 tumor marker	Normal
EEG	Figure 2
MRI Brain	Figure 3
POLG1 genetic testing (Patient)	Compound heterozygous A467T/W748S mutation
POLG1 genetic testing (Parents)	Father: Heterozygous A467T mutation Mother: Heterozygous W748S mutation

Case Report

Figure 2: EEG

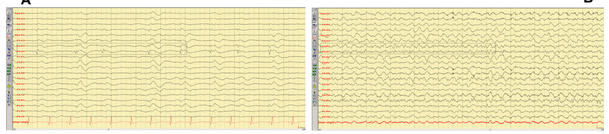

A: 24 hour scalp EEG with interictal left parieto-occipital sharp waves. **B:** 24 hour scalp EEG with left parieto-occipital seizure

Figure 3: MRI Brain

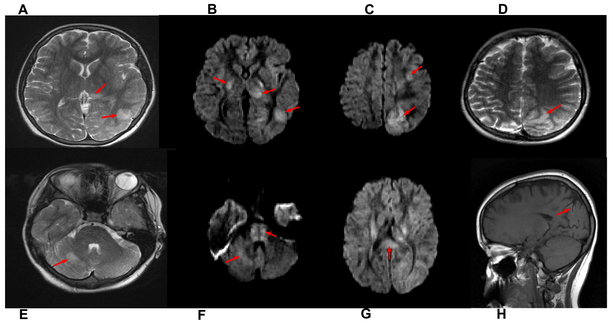

•Axial T2 MRI brain **(A,D,E)** with hyperintensities in the left parietal lobe, left thalamus, left occipital lobe, and right cerebellar hemisphere with corresponding restricted diffusion as seen on the axial DWI MRI brain **(B, C, F)**. Additional areas of restricted diffusion are seen in the right basal ganglia, left frontal lobe, brain stem, and splenium of the corpus collosum **(B,C,F,G)**. Prominent parieto-occipital lobe atrophy with high signal abnormality is seen on sagittal T1brain w/o gad **(H)**.

Discussion

•The POLG1 gene encodes for the human mitochondrial DNA polymerase [4]. Mutations in the POLG1 gene can cause autosomal dominant and recessive chronic progressive external ophthalmoplegia (CPEO), Alpers' syndrome, sensory ataxic neuropathy, dysarthria, and ophthalmoparesis (SANDO), parkinsonism, and a mitochondrial recessive ataxic syndrome [4]. The majority of mutations in the POLG1 gene cause CPEO, however, two mutations, the 1399G/A and 2243G/C giving the amino acid substitutions A467T and W748S, respectively, cause a recessive mitochondrial ataxic syndrome, which is what we suspect our patient had [4].

•The age of onset of neurological symptoms in patients with POLG1 mutations ranges from 2-36, with most starting in their teens [4]. Irrespective of genotype, patients exhibit a progressive neurological disorder characterized by epilepsy, headache, ataxia, neuropathy, myoclonus, and late onset ophthalmoplegia. The epilepsy often occurs in combination with headaches that have features of migraine [4]. Patients with POLG1 gene mutations are at high risk of death from status epilepticus and from liver failure, especially if exposed to sodium valproate [4]. Kaplan-Meier survival analysis from small case series shows that compound heterozygous patients do significantly worse than those who are homozygous either for the A467T/A467T or W748S/W748S [4]. Median survival for patients with A467T/A467T, A467T/W748S, and W748S/W748S mutations is 50, 6, and 26 months respectively [4]. Despite this dire statistic, our patient, who is currently more than two years from her diagnosis, is clinically doing well.

Discussion

•Based on previous case reports, patients with an A467T/W748S POLG1 mitochondrial disorder may have cortical and cerebellar atrophy as well as abnormal T2 hyperintensities with restricted diffusion on MRI in various cortical and subcortical structures including: occipital cortex, deep cerebellar structures, thalamus (most common), basal ganglia, and inferior olives [4]. Laboratory testing usually reveals increased serum and CSF lactate, pyruvate as well as positive oligoclonal bands, elevated CSF protein and CSF pleocytosis [3]. Muscle biopsy may or may not be helpful diagnostically, however, the presence of ragged red fibers should elevate a mitochondrial cytopathy on the differential.

•The prevalence of epilepsy by POLG1 genotype is –A467T: 100%, W748S: 70%, A467T/W748S: 75% [5]. VEEG monitoring may show simple partial motor seizures, most often involving an arm, shoulder, neck and or head, as in our patient [5]. Patients with an occipital lobe predilection usually complain of perception of colored light in one visual hemifield or either a scotoma or a hemianopsia which can persist for hours, days, weeks, months, or even years [5]. Formed visual hallucinations as well as nystagmus and eye-lid myoclonus have also been reported [5]. Complex partial seizures (CPS) with motor symptoms have also been documented in these patients. Patients have been observed to have as part of their CPS (focal jerks, head turning, motor automatisms as well as visual symptoms). Interestingly, our patient had prominent sensory symptoms as part of her seizures, referable to a parieto-occipital focus. Previous case reports of A467T/W748S mutations describe the seizures as having an occipital lobe onset with prominent visual and motor symptoms.. The MRI brain of our patient demonstrates that POLG1-related cerebral cortical lesions are not only confined to the occipital areas, as previously described, but also can involve the parietal cortex as well. Our case report further corroborates that the posterior regions (parieto-occipital lobe) of the brain serve as the epileptic origin in POLG1-related epilepsy. The reason for why there is a parieto-occipital lobe predilection is still unknown and remains to be established.

•Combination anti-epileptic therapy, which has been showed to be beneficial for seizure frequency reduction include: sodium channel blockers (e.g. carbamazepine (CBZ), phenytoin (PHT), oxcarbazepine (OXC) or lamotrigine [5]. Often these drugs are combined with benzodiazepines. Epilepsy in patients with a POLG1 mutation should be treated very aggressively to prevent a vicious cycle of epileptogenesis, which leads to seizure refractoriness and ultimately epileptic status, which is the main cause of morbidity and mortality in these patients [5].

Conclusion

•This is a rare case of a POLG1 gene mutation with a wide range of neurological manifestations. The gradual onset of symptoms as well as multi-organ involvement made the diagnosis difficult. The focal seizures were the initial manifestation of the disease and the patient was thought to have cryptogenic focal epilepsy. Multi-organ involvement and worsening of the symptoms on valproate raised the concern for mitochondrial disease. However, conventional work up for mitochondrial disease using the genetic panel run through Athena was negative, making the diagnosis more challenging and resulting in more extensive testing for metabolic, degenerative, paraneoplastic, and infectious disorders. Our case report helps to illustrate the key clinical features associated with POLG1 mutations, specifically the A467T/W748S, which if recognized by neurologists can help focus the investigation on POLG1 and make it unnecessary to investigate mtDNA genes. In addition to advocating for aggressive epilepsy treatment for these patients, we also recommend good nutrition; particularly close follow-up, and supplements such as L-carnitine and coenzyme-Q10.

References

1. Ashley N, O'Rourke A, Smith C, et. Al., Depletion of Mitochondrial DNA in Fibroblast Cultures from Patients with POLG1 Mutations is a Consequence of Catalytic Mutations. Human Molecular Genetics, 2008, Vol. 17, No.16, 2496-2506.
2. Longley M, Graziewics M, Bienstock R, et. Al., Consequences of Mutations in Human DNA Polymerase Gamma. Gene 354 (2005) 125-131.
3. Finsterer J, Mitochondrial Disorders, Cognitive Impairment, and Dementia. Journal of the Neurological Sciences 283 (2009) 143-148.
4. Tzoulis C, Engelsen B, et. Al., The Spectrum of Clinical Disease Caused by the A467T and W748S POLG Mutations: A Study of 26 Cases. Brain (2006), 129, 1685-1692.
5. Engelsen B, Tzoulis C, et. Al., POLG1 Mutations Cause a Syndromic Epilepsy with Occipital Lobe Predilection. Brain (2008), 131, 818-828.

Disclosures: Dr. Roshal and Dr. Zangaladze have nothing to disclose.