Thomas Jefferson University
Jefferson Digital Commons

Department of Radiology Faculty Papers | Department of Radiology

1-1-2012

Determining Efficacy of Breast Cancer Therapy by Pet Imaging of HER2 MRNA

Bishnuhari Paudyal
Thomas Jefferson University, Bishnuhari.Paudyal@jefferson.edu

Kaijun Zhang
Thomas Jefferson University, Kaijun.Zhang@jefferson.edu

Changpo Chen
Thomas Jefferson University, Changpo.Chen@jefferson.edu

Neil Mehta
Thomas Jefferson University, Neil.Mehta@jefferson.edu

Eric Wickstrom
Thomas Jefferson University, Eric.Wickstrom@jefferson.edu

See next page for additional authors

Follow this and additional works at: http://jdc.jefferson.edu/radiologyfp

Part of the Medical Molecular Biology Commons, and the Radiology Commons

Recommended Citation
Paudyal, Bishnuhari; Zhang, Kaijun; Chen, Changpo; Mehta, Neil; Wickstrom, Eric; Gray, Brian; Mattis, Jeffrey; Pak, Koon; and Thakur, Mathew L, "Determining Efficacy of Breast Cancer Therapy by Pet Imaging of HER2 MRNA" (2012). *Department of Radiology Faculty Papers.* Paper 20.
http://jdc.jefferson.edu/radiologyfp/20

This Article is brought to you for free and open access by the Jefferson Digital Commons. The Jefferson Digital Commons is a service of Thomas Jefferson University's Academic & Instructional Support & Resources Department (AISR). The Commons is a showcase for Jefferson books and journals, peer-reviewed scholarly publications, unique historical collections from the University archives, and teaching tools. The Jefferson Digital Commons allows researchers and interested readers anywhere in the world to learn about and keep up to date with Jefferson scholarship. This article has been accepted for inclusion in Department of Radiology Faculty Papers by an authorized administrator of the Jefferson Digital Commons. For more information, please contact: JeffersonDigitalCommons@jefferson.edu.

Authors
Bishnuhari Paudyal, Kaijun Zhang, Changpo Chen, Neil Mehta, Eric Wickstrom, Brian Gray, Jeffrey Mattis, Koon Pak, and Mathew L Thakur

This poster is available at Jefferson Digital Commons: http://jdc.jefferson.edu/radiologyfp/20

DETERMINING EFFICACY OF BREAST CANCER THERAPY BY PET IMAGING OF HER2 MRNA

B. Paudyal[1], K. Zhang[1], C. Chen[2], N. Mehta[1], E. Wickstrom[2, 3], B. Gray[4], J. Mattis[4], C. Pak[4], M. Thakur[1, 3]
Departments of Radiology[1], Biochem. & Mol. Biol.[2], Kimmel Cancer Center[3], Thomas Jefferson University, Philadelphia, PA and Molecular Targeted Therapy, Inc.[4], West Chester, PA, USA

Objective: Monitoring the effectiveness of therapy early and accurately continues to be challenging.

We hypothesize that determination of HER2 mRNA in malignant Breast Cancer cells by PET imaging, before and after treatment, would reflect therapeutic efficacy.

Materials and Method: Peptide Nucleic Acid (PNA) that would hybridize with HER2 mRNA was synthesized together with D (CSKC), a cyclic peptide, that facilitated internalization of the PNA via IGFR expressed on breast (BC) cancer cells and DOTA that chelated Cu-64. Mice (n=8) with BT474 ER+/HER2+ human BC received doxorubicin (DOX), 1.5 mg/kg) intraperitoneally, three times a week. Mice (n=3) without DOX treatment served as controls. All mice were PET imaged with F-18-FDG and 24-48 hrs later with Cu-64-PNA. PET imaging was performed before and 72 hrs after each treatment. Standard Uptake Values (SUV) for tumors were determined and % change calculated. Animal body weight (BW) and tumor volume (TV) were measured.

Results: Following each of the three DOX treatments, tumor SUV for Cu-64-PNA declined to 54±17%, 41±15%, 29±7% of pretreatment SUV (P<0.05), as compared to 42±22%,31±18%, 13±9% (P<0.05), SUVs respectively for F-18-FDG. In control mice the corresponding % SUVs for Cu-64-PNA were 145±82% , 165 ±39 and 212±105%, and for F-18-FDG 108±28%, 151±8 and 152±35%. In treated mice, at the end of three DOX treatments, BW was 101.7±12.7% while TV declined to 35.1±35%. In control mice, BW remained 107.8±9.3% and TV averaged 181.3±51.5%.

Tumor SUV as % of Pretreatment SUV for Cu-64-PNA in DOX Treated Mice

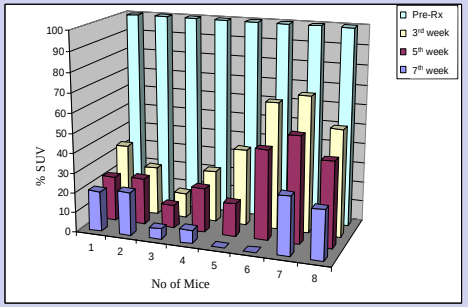

Tumor SUV as the % of Pretreatment SUV for F-18-FDG in DOX Treated Mice

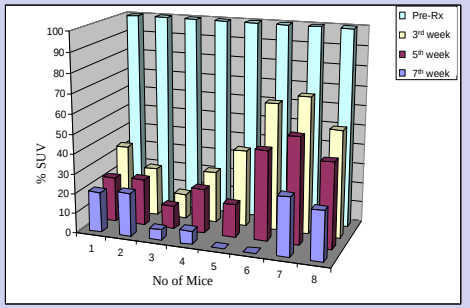

Cross Sectional PET Images of a BT474 Tumor Bearing Mouse, Before and After DOX Treatment

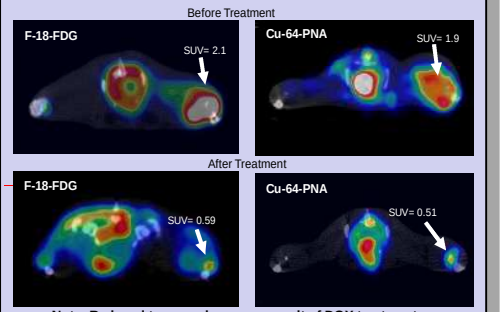

Note: Reduced tumor volume as a result of DOX treatment. These results can be better appreciated in figure below.

Tumor SUV for F-18-FDG and Cu-64-PNA in DOX Pre-Treated and Treated Mice Bearing BT474 Tumors

Study (n=8)	Pre-Treatments	Post-Treatments						
	1st Week	3rd Week	% Change	5th Week	% Change	7th Week	% Change
Cu-64-PNA	0.95 0.32	0.56 0.18	54 17 (P<0.05)	0.43 0.23 (P<0.05)	41 15 (P<0.05)	0.32 0.14	29 7 (P<0.05)
F-18-FDG	2.34 0.99	1 0.85	42 22	0.77 0.6	31 18	0.34 0.25	13 9
Control (n=3)	Initial	No Treatment (Control)					
Cu-64-PNA	0.49 0.21	2.03 1.6	145 82 (P<0.05)	0.81 0.7	165 39 (P<0.05)	1.04 0.12	212 105 (P<0.05)
F-18-FDG	1.9 1.12	0.56 0.18	108 28 (P<0.05)	2.8 2.2	151 8 (P<0.05)	4.1 3.7	152 35 (P<0.05)

Ratios of PET Pixel Counts in Each 1x1x1 mm Voxel Across a Central 1 mm Slice of BT474 Tumor Before and After Three Treatments of DOX (F-18-FDG (1 hr) and Cu-64-PNA (4 hr)

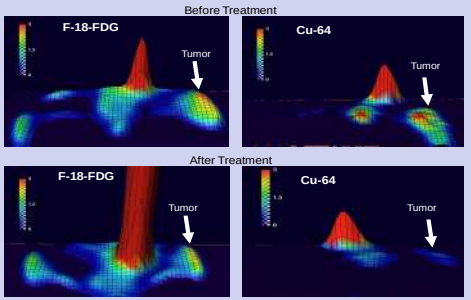

Note: Significantly reduced tumor pixel count ratios with Cu-64-PNA than with F-18-FDG.

Arbitrary Values of a BT474 Tumor (right) and Contralateral Normal Tissue (left), Derived from a Surface Rendered PET/CT Image of a Mouse (4 hr After Administration of Cu-64-PNA)

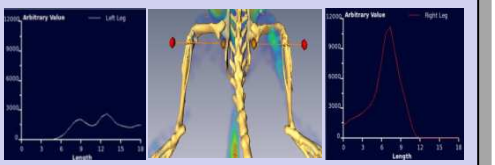

Conclusion: Effectiveness of therapy can be better determined by PET-imaging measurements of genomic biomarkers targeted specifically, than by PET imaging of metabolic activity of a tumor. Cu-64-PNA PET-imaging provides a genetic tool for evaluation of therapeutic efficacy.

Support: NIH 1R44CA136306. IP Licensed from E. Wickstrom/M. L. Thakur.