

12-1-1990

Malignant external otitis and mastoiditis associated with an IgG4 subclass deficiency in a child.

Ricardo Castro, MD
Medical Center of Delaware

Norman Robinson, MD
Medical Center of Delaware

Joel Klein, MD
Thomas Jefferson University

William Geimeier, MD
Medical Center of Delaware

Let us know how access to this document benefits you

Follow this and additional works at: <http://jdc.jefferson.edu/pedsfp>

 Part of the [Bioethics and Medical Ethics Commons](#), and the [Pediatrics Commons](#)

Recommended Citation

Castro, MD, Ricardo; Robinson, MD, Norman; Klein, MD, Joel; and Geimeier, MD, William, "Malignant external otitis and mastoiditis associated with an IgG4 subclass deficiency in a child." (1990). *Department of Pediatrics Faculty Papers*. Paper 14.
<http://jdc.jefferson.edu/pedsfp/14>

This Article is brought to you for free and open access by the Jefferson Digital Commons. The Jefferson Digital Commons is a service of Thomas Jefferson University's [Center for Teaching and Learning \(CTL\)](#). The Commons is a showcase for Jefferson books and journals, peer-reviewed scholarly publications, unique historical collections from the University archives, and teaching tools. The Jefferson Digital Commons allows researchers and interested readers anywhere in the world to learn about and keep up to date with Jefferson scholarship. This article has been accepted for inclusion in Department of Pediatrics Faculty Papers by an authorized administrator of the Jefferson Digital Commons. For more information, please contact: JeffersonDigitalCommons@jefferson.edu.

SCIENTIFIC ARTICLE

Malignant External Otitis and Mastoiditis Associated with an IgG4 Subclass Deficiency in a Child

Ricardo Castro, M.D.
Norman Robinson, M.D.
Joel Klein, M.D.
William Geimeier, M.D.

Malignant external otitis, also called necrotizing otitis externa, was first described in 1959.¹ It is a severe infection of the external ear canal and deep periauricular tissues caused usually by *Pseudomonas aeruginosa*, which does not respond to most oral or topical antibiotics. Since the first case, there have been 164 cases described in adults, and 18 cases in children. Ninety-four of the adult cases were in patients with diabetes mellitus; however, of the 18 reported cases in children, only three (16 percent) of them had diabetes mellitus, including the latest reported cases in children by Rubin² in 1988 and Wolff³ in 1989.

Dr. Castro is a practicing pediatrician in the Newark area and is Senior Attending Physician, Department of Pediatrics, Medical Center of Delaware.

Dr. Robinson is a practicing otolaryngologist and Senior Attending Physician, Department of Surgery, Section of Otolaryngology, Medical Center of Delaware.

Dr. Klein is Associate Attending Physician, Department of Pediatrics, Medical Center of Delaware, and Chief, Division of Infectious Diseases, A. I. du Pont Institute.

Dr. Geimeier is Associate Attending Physician, Department of Pediatrics, Medical Center of Delaware, and Chief, Section of Pediatric Allergy, Medical Center of Delaware.

Pseudomonas aeruginosa is a gram negative bacterium that generally infects patients with a compromised immune status. It is the most frequent bacterium isolated in this illness, found in 99 percent of adult cases and 93 percent of childhood cases. In adults this illness often results in cranial nerve paralysis, osteomyelitis and chondritis and may even result in a high mortality rate. In children the most frequent complications are facial nerve paralysis, mastoiditis and decreased hearing. In children it may be associated with diabetes mellitus, anemia, leukemia, malnutrition, solid tumors and Stevens-Johnson syndrome.^{2,7}

Following is a report of the first case of malignant external otitis in a child in Delaware, and the first case associated with a deficiency of the IgG4 subclass of IgG4.

Case Report

A five-and-a-half-year-old white female was admitted to the hospital with a four-month history of bilateral ear pain and purulent drainage, not

responsive to oral and topical antibiotics. Previous medical history revealed that approximately one year previously she had undergone tonsillectomy, adenoidectomy and bilateral myringotomies with placement of tubes. This was done because of chronic mouth-breathing, snoring, recurrent tonsillitis and otitis media. A few months later both tubes fell out, but the perforations in the tympanic membranes persisted. Subsequently, she developed a heavy green-yellow bilateral ear discharge and pain that did not improve with the usual treatment. Past medical and family history revealed no serious illnesses or hospitalizations. The remainder of her family, including an older brother and a younger sister, were in good health.

The physical examination showed the following: T:36° C, R:20/min, P:80/min, BP:85/50, Wt:13 kg (25%), Lt:109 cm (25%) (her mother was

also short [25%]). The only positive pertinent findings were tenderness of both ears and a bilateral thick yellow-green discharge. After evacuating the liquid discharge and cleaning the granulation tissue, no tympanic membranes were seen; there were only necrotic remnants at the periphery. There was moderate tenderness to touch and pressure in the tissues surrounding the ears, as well as the area of the left mastoid. The remainder of the physical examination was normal.

Computed axial tomography (CT scan) of the ears and mastoids demonstrated a left mastoiditis and destruction of the bony cells of the left middle ear (Figures 1 and 2). A hearing evaluation showed a marked hearing loss in both ears, especially the left. Bacterial cultures of the ear drainage produced a heavy growth of *Pseudomonas aeruginosa* sensitive to tobramycin and nafcillin.

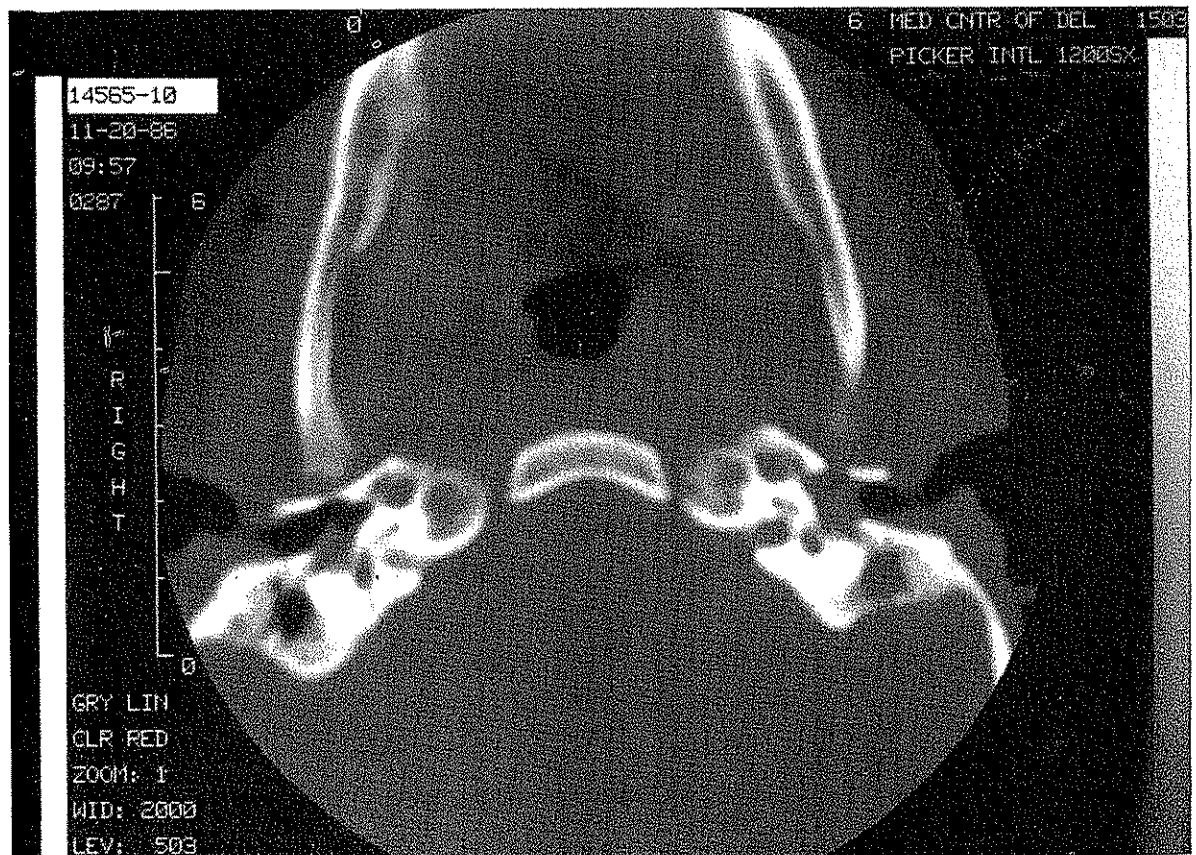


FIGURE 1

After two weeks of intravenous antibiotics, a repeat CT scan showed a marked improvement of the left mastoid. The ears stopped draining, the ear pain disappeared, and a repeat hearing test showed marked improvement. She was discharged home.

Five months later, the patient was rehospitalized because of a two-and-a-half week history of pain and drainage from the left ear. Physical examination revealed the same findings, only this time localized to the left ear. Again, cultures of the drainage showed heavy growth of *Pseudomonas aeruginosa*. Both CT and Gallium scans revealed a larger area of involvement of the left mastoid. She was again started on intravenous tobramycin and seven days later underwent a left mastoidectomy. Cultures taken during the operation also grew *Pseudomonas aeruginosa*. Tissue

removed during operation showed chronic inflammation and mastoiditis. She was continued on tobramycin for another week, after which there was no more drainage and the ear pain subsided. A repeat hearing test showed marked improvement. She was discharged.

Six months later she was admitted again because of a three-week history of bilateral ear pain and drainage with the same characteristics as previously. Cultures again grew *Pseudomonas aeruginosa*, and she was put on a three-week course of intravenous tobramycin and clindamycin. The left mastoidectomy was repeated and the surgical specimen and cultures gave the same findings as previously. She again showed marked clinical improvement and was discharged.

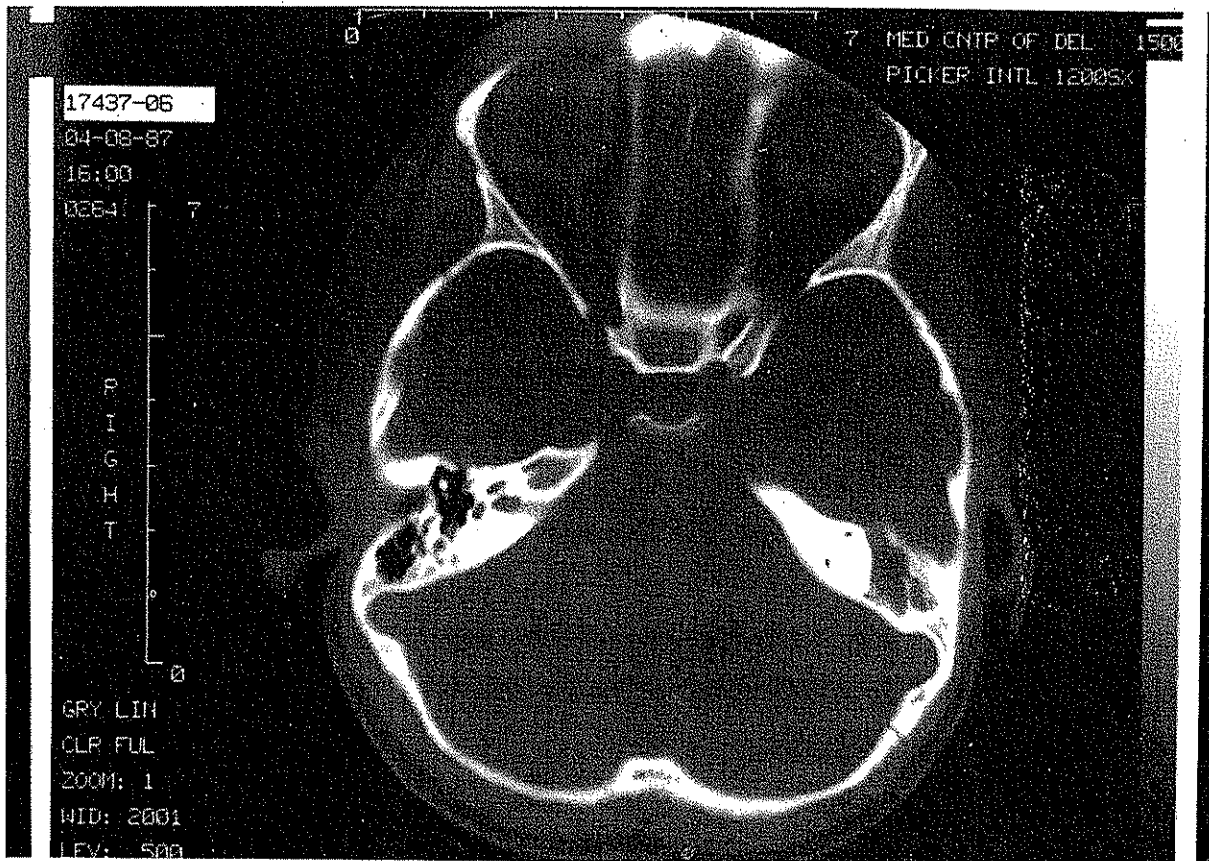


FIGURE 2

During the hospitalizations, multiple laboratory tests and evaluations were done, including CBC, urinalysis, SMA-12, SMA-6, fasting blood sugar, nitro blue tetrazolin test, lymphocyte enumeration, tetanus and H. influenzae B antibody titers, C3 and C4 titers and serum immunoglobulins IgE, IgG, IgA and IgM. Cultures were done for other bacteria, fungi and mycobacteria. Skin tests for candida, mumps, tetanus were normally reactive and a PPD was negative. All findings were negative or normal except two:

- o Sedimentation rate was moderately elevated, 22 and 26 mm/hour, and
- o IgG4 subclass was low.

Immune globulins were tested twice, at the Nichols Laboratory, California, and gave substantially the same result each time:

| | Patient | Expected Value |
|-------|-----------|------------------|
| IgG1 | 648 mg/dl | 305 - 1480 mg/dl |
| IgG2 | 132 mg/dl | 35 - 477 mg/dl |
| IgG3 | 19 mg/dl | 10 - 105 mg/dl |
| IgG4 | 2 mg/dl | 4 - 158 mg/dl |
| Total | 801 mg/dl | 400 - 1660 mg/dl |

The IgG4 subclass normally represents 5 percent of the total,⁸ but in our patient was only 0.25 percent.

It was then decided to perform a tympanoplasty to provide her with new "tympanic membranes." Grafts of fascia from the large temporalis muscle were used, first on the left and later on the right. Now, two years after the tympanoplasties, she has not had any more problems or ear infections. She is in good health, though still has decreased hearing.

DESIGNING YOUR RETIREMENT PROGRAM

H. Thomas Hollinger, Vice President
NATIONAL RETIREMENT PLAN SERVICES

As a professional or business executive, you assume the mantle of responsibility for a satisfying retirement program—for yourself and your employees. The past decade has brought an enormous amount of change in this area, from tax laws to participation requirements to vesting schedules. Making sure the right people are covered in the right way requires the services of professionals skilled in handling the complexities of designing—and administering—retirement plans. That's our specialty, and leaving this vital program in our hands frees you to concentrate on yours.

Creative retirement planning provides a brighter future.



Wilmington Financial Group

201 Topkis Building • 100 Chapman Road • P.O. Box 8118 • Newark, Delaware 19714 • (302) 731-1326



Discussion

Our patient, as other patients with malignant otitis externa, had pain, soft tissue involvement, copious ear discharge, and cultures which showed heavy growth of *Pseudomonas aeruginosa*. In children this disorder usually has an acute onset as opposed to adults, where the onset is very slow and gradual. This patient's onset was, as in adults, slow and gradual, but her recurrences were acute.

Of all previously reported cases of malignant external otitis in children, only one received multiple courses of intravenous antibiotics and surgical care, including mastoidectomy.⁹ All others required only one course of intravenous antibiotics. In contrast, in adults, recurrence of this problem is common. In children the tympanic membranes are necrotic in more than half the cases, but in adults, the tympanic membranes are usually spared. Facial nerve palsy is more frequent in children. Mortality in adults is high, usually about 20 percent; but in children, no deaths from this condition have yet been reported. Increased sedimentation rate is not unexpected.¹⁰⁻¹¹

In adults, antibiotics are recommended for five to six weeks, but in children, a two- to three-week course is usually sufficient as long as a clinical response is obtained. In our patient, multiple cultures from middle ear, mastoid and drainage always grew out *Pseudomonas aeruginosa*, sensitive to tobramycin. This aminoglycoside is the drug of choice for this condition, though some authors recommend a concurrent anti-*Pseudomonas* penicillin compound.² Surgery is usually indicated when there is a focus of infection, as in our patient; however, surgery does not decrease morbidity. In previously reported cases in children, male and female are equally represented. Mastoidectomies were performed in six of 18, and five of 18 had decreased hearing.

This is the first documented case of malignant otitis/mastoiditis with an associated IgG4 deficiency. Such IgG4 deficiencies have been described in children with recurrent infections and, in particular, sinopulmonary infections.¹²⁻¹³ Currently there is no consensus as to how best to manage such patients. Some authors advocate intravenous gammaglobulin replacement therapy,¹⁴⁻¹⁵ while others question its value and recommend that such

therapy only be used as part of experimental protocols.¹⁶

In our patient we decided first to implant new tympanic membranes to give the ears the natural protective barrier they need to prevent the entry of outside infections. In doing so we did not have to use intravenous gammaglobulin. This course of action has worked well over the past two years.

Summary

We have presented the first child in Delaware with malignant external otitis associated with IgG4 deficiency. Our patient needed three courses of intravenous antibiotics and twice required mastoidectomy, but has recovered completely following the restoration of the natural barrier between the internal and external ear, using a fascial graft from the large temporalis muscle. Some hearing deficit remains.

References

1. Meltzer PE, Kelmen G. Pyocutaneous osteomyelitis of the temporal bone, mandible, and zygoma. *Laryngoscope*. 1959;69:1300-1316.
2. Rubin J, Yu VL, Stool SE. Malignant external otitis in children. *J Pediatr*. 1988;113:965-970.
3. Wolff LJ. Necrotizing otitis external during therapy for acute lymphoblastic leukemia. *Pediatrics*. 1989;84:882-885.
4. Merritt WT, Bass JW, Bruhn FW. Malignant external otitis in adolescent with diabetes. *J Pediatr*. 1980;96:872-873.
5. Sobie S, Brodsky L, Stanievich JF. Necrotizing external otitis in children, report of two cases and review of the literature. *Laryngoscope*. 1987;97:598-601.
6. Sherman P, Black S, Grossman M. Malignant external otitis due to *Pseudomonas aeruginosa* in childhood. *Pediatrics*. 1980;66:782-783.
7. Rubenstein E, Ostfeld E, Ben-Zaray S, Schiby G. Necrotizing external otitis. *Pediatrics*. 1980;618-620.
8. Duncan JM, Herrod HG, Crawford LV. IgG subclass deficiency and recurrent respiratory tract disease in childhood. *Pediatric Asthma, Allergy & Immunology*. 1988;2:269-278.
9. Giguere P, Rouillard G. Otitis externe maligne bilaterale chez un fillette de 10 ans. *J Otolaryngol (Can)*. 1976;5:159-166.
10. Coser PL, Staman AEC, Lobo RC, Pinto JA. Malignant external otitis in infants. *Laryngoscope*. 1980;90:312-315.
11. Horn KL, Gherini S. Malignant external otitis in childhood. *Am J Otol*. 1981;2:402-404.
12. Beck CS, Heiner DC. Selective IgG4 deficiency and recurrent infections of the respiratory tract. *Amer Rev Resp Dis*. 1981;124:94-96.
13. Shackelford PG, Polmar SH, Mayus JL, Johnson WL, Corny JM, Nahm MH. Spectrum of IgG2 subclass deficiency in children with recurrent infections: prospective study. *J Pediatr*. 1986;108:647-653.
14. Heiner DC. Recognition and management of IgG subclass deficiencies. *Pediatr Inf Dis J*. 1987;6:235-238.
15. Schur PH. IgG subclasses - a review. *Ann Allergy*. 1987;58:89-96.
16. Choi SY. Immunoglobulin G subclass deficiencies: should we treat? *J Pediatr*. 1988;113:789.