Thomas Jefferson University
Jefferson Digital Commons

Department of Urology Faculty Papers | Department of Urology

4-1-2009

Transperitoneal robotic-assisted laparoscopic prostatectomy after prosthetic mesh herniorrhaphy.

Costas D. Lallas
Thomas Jefferson University, costas.lallas@jefferson.edu

Mark L. Pe
Thomas Jefferson University

Jitesh V. Patel
Thomas Jefferson University

Pranav Sharma
Thomas Jefferson University

Leonard G. Gomella
Thomas Jefferson University

See next page for additional authors

Let us know how access to this document benefits you

Follow this and additional works at: http://jdc.jefferson.edu/urologyfp

Part of the Urology Commons

Recommended Citation

Lallas, Costas D.; Pe, Mark L.; Patel, Jitesh V.; Sharma, Pranav; Gomella, Leonard G.; and Trabulsi, Edouard J., "Transperitoneal robotic-assisted laparoscopic prostatectomy after prosthetic mesh herniorrhaphy." (2009). *Department of Urology Faculty Papers.* Paper 5.
http://jdc.jefferson.edu/urologyfp/5

This Article is brought to you for free and open access by the Jefferson Digital Commons. The Jefferson Digital Commons is a service of Thomas Jefferson University's Center for Teaching and Learning (CTL). The Commons is a showcase for Jefferson books and journals, peer-reviewed scholarly publications, unique historical collections from the University archives, and teaching tools. The Jefferson Digital Commons allows researchers and interested readers anywhere in the world to learn about and keep up to date with Jefferson scholarship. This article has been accepted for inclusion in Department of Urology Faculty Papers by an authorized administrator of the Jefferson Digital Commons. For more information, please contact: JeffersonDigitalCommons@jefferson.edu.

Authors
Costas D. Lallas, Mark L. Pe, Jitesh V. Patel, Pranav Sharma, Leonard G. Gomella, and Edouard J. Trabulsi

This article is available at Jefferson Digital Commons: http://jdc.jefferson.edu/urologyfp/5

SCIENTIFIC PAPER

Transperitoneal Robotic-Assisted Laparoscopic Prostatectomy After Prosthetic Mesh Herniorrhaphy

Costas D. Lallas, MD, Mark L. Pe, MD, Jitesh V. Patel, MD, Pranav Sharma, Leonard G. Gomella, MD, Edouard J. Trabulsi, MD

ABSTRACT

Background and Objectives: We report our institutional experience performing transperitoneal robotic-assisted laparoscopic prostatectomy (RALP) in patients with prior prosthetic mesh herniorrhaphy to assess the feasibility of this procedure in this patient population.

Methods: From October 2005 to January 2008, transperitoneal robotic-assisted laparoscopic prostatectomies were performed and prospectively recorded. We retrospectively reviewed 309 patients.

Results: Twenty-seven patients (8.7%) were found to have a history of prior hernia repair with prosthetic mesh placement. The mean age was 55.7, estimated blood loss (EBL) was 228 mL, operative (console) time was 197 minutes, and length of hospital stay (LOS) was 1.62 days. In contrast, patients undergoing RALP with no history of mesh herniorrhaphy had a mean age of 59.3, EBL of 302 mL, console time of 193 minutes, and LOS of 2.2 days. These differences were not statistically significant. The mesh herniorrhaphy cohort had a lower percentage of organ-confined disease, but no difference was seen in margin status, continence, or potency rates after one year.

Conclusions: Transperitoneal RALP is a feasible option for previously operated on patients with prosthetic mesh herniorrhaphy. Two areas that we identified as critical were the initial step of gaining access for pneumoperitoneum and port placement, and meticulous dissection to expose the mesh, which can be subsequently avoided and left intact. As RALP continues to gain popularity, urologists will continue to exploit the advantages of robotic surgery to perform increasingly challenging cases.

Key Words: Prostatectomy, Hernia repair, Mesh, Laparoscopy, Robotics.

Department of Urology, Kimmel Cancer Center, Thomas Jefferson University, Philadelphia, Pennsylvania, USA (all authors).

Address correspondence to: Costas D. Lallas, MD, Department of Urology, Kimmel Cancer Center, Thomas Jefferson University, 1025 Walnut St, Ste 1112 College Building, Philadelphia, PA 19107, USA. Telephone: (215) 955-6961, Fax: (215) 923-1884, E-mail: costas.lallas@jefferson.edu

© 2009 by *JSLS, Journal of the Society of Laparoendoscopic Surgeons.* Published by the Society of Laparoendoscopic Surgeons, Inc.

INTRODUCTION

Robotic-assisted laparoscopic prostatectomy (RALP) has gained increasing popularity and acceptance in urologic practice. Compared with laparoscopic prostatectomy (LRP), the advantages of improved visualization, ergonomics, and instrumental range of motion have dramatically decreased the learning curve to achieve proficiency.[1–3] In addition, emerging studies demonstrate similar clinical and pathological outcomes compared with traditional radical retropubic prostatectomy (RRP).[4,5]

Inguinal hernia repair with the incorporation of prosthetic mesh has been reported to create a dense, fibrotic reaction, complicating future pelvic procedures.[6] There have been several reports of surgeons encountering severe fibrosis and scarring during RRP in patients who have undergone prior mesh hernia repairs, leading to early termination of the procedure.[7–9] In addition, prosthetic mesh used in umbilical hernia repairs can similarly cause intraperitoneal adhesions and scarring, making port placement and dissection technically challenging in patients who undergo intraperitoneal laparoscopic or robotic procedures. This dense inflammation and fibrosis can destroy natural planes of dissection and compromise oncological surgery.[6] Due to these issues, prior laparoscopic herniorrhaphy with mesh has been considered a relative contraindication to RRP and LRP.

Recent studies have reported that LRP after prior laparoscopic inguinal herniorrhaphy is feasible and does not adversely affect operative and functional results.[10,11] We retrospectively reviewed our institutional experience with RALP concerning patients who had undergone prior herniorrhaphy with prosthetic mesh to assess the feasibility of robotic prostatectomy in this patient population.

METHODS

From the initiation of RALP at Thomas Jefferson University Hospital in October 2005 until January 2008, 309 procedures were performed by 2 surgeons (CDL and EJT) and were recorded in our robotic database. After obtaining approval from our institutional IRB, demographic and perioperative data were collected prospectively. In addition, data regarding final pathology, extracapsular exten-

sion, and margin status were documented. The 4-armed da Vinci robot (Intuitive Surgical, Inc., Sunnyvale, CA) was used for all cases, and all were performed intraperitoneally, using a 6-port setup. Statistical analysis was performed on all data by using the chi-square test to compare patients with and without a history of mesh herniorrhaphy.

RESULTS

The records of these 309 patients were reviewed. Patient characteristics and perioperative data are shown in **Table 1**. A total of 27 patients (8.7%) were identified as having prior herniorrhaphy with prosthetic mesh placement. For the series, the mean age was 55.7. The mean estimated blood loss was 227.7 mL, console time was 197 minutes, and length of stay was 1.62 days. Postoperative anemia requiring transfusion in one patient was the only complication seen in the group. By contrast, our patients with no history of hernia repair who underwent RALP had a mean age of 59.3, mean EBL of 301.8 mL, console time of 187 minutes, and length of stay of 2.16 days; however, these differences were not statistically significant **(Table 1)**.

Perioperative pathologic parameters are demonstrated in **Table 2**. Of note, a significant difference was seen in the final pathologic stage, with a much larger number of those patients without mesh herniorrhaphy being pT2 ($P<0.001$). Regardless, positive margin rates for both pT2 and pT3/4 disease were similar for both cohorts. PSA data need to mature.

Quality of life outcomes for both cohorts of patients are demonstrated in **Table 3**. In accordance with the lower amount of organ-confined disease, fewer nerve-sparing procedures were performed in the mesh herniorrhaphy patients. This did not translate into a significant difference in either postoperative continence or potency, when stratified for nerve-sparing results. This table shows follow-up at 1 year and includes both mean International Index of Erectile Function (IIEF) and International Prostate Symptom Score (IPSS) results for both groups of patients. Continence was defined as ≤1 pad per day for protection, and potency as successful vaginal penetration with or without the use of pharmacotherapy.

DISCUSSION

Laparoscopic prostatectomy was first reported in 1997.[12] The advantages of increased visual acuity and decreased patient morbidity and convalescence were evident; however, the procedure was technically demanding and was associated with a steep learning curve. The introduction of the da Vinci robot to assist in laparoscopic prostatectomy has significantly reduced the learning curve, making the procedure technically feasible.[2] As RALP has gained increasing acceptance, recent data are emerging that show outcomes comparable to those of RRP.[4,5]

Laparoscopic umbilical and inguinal hernia repair have become increasingly popular.[13] Although the number of laparoscopic hernia repairs is rising, the incorporation of prosthetic mesh may interfere with future surgical procedures. Laparoscopic inguinal hernia repair, in particular, has been associated with extensive intraabdominal and pelvic fibrosis and inflammation, making radical retropubic prostatectomy so difficult that early termination of the procedure has been reported.[6–8] Katz et al[9] reported on 2 patients with prior laparoscopic bilateral inguinal hernia repairs who underwent RRP. In each case, considerable inflammation and scarring was encountered. In one case, the mesh completely obliterated the space of Retzius, and further dissection could not be safely performed. The procedure was subsequently aborted and the patient underwent external beam radiotherapy. The second case was completed, albeit with great difficulty. The authors concluded that RRP after laparoscopic inguinal hernia

Table 1.
Mean Age, Estimated Blood Loss, Console Time, and Length of Stay of Robotic-Assisted Laparoscopic Prostatectomy (RALP) Patients, With and Without Prior Mesh Herniorraphy

	RALP With History of Mesh Herniorrhaphy	RALP Without Mesh Herniorrhaphy	P Value
Number of Patients	27 (8.7%)	282 (91.3%)	
Age (years), mean	55.7	59.3	P = 0.67
Estimated Blood Loss (mL), mean	227.7	301.8	P = 0.61
Console Time (min), mean	197	187	P = 0.45
Length of Stay (days), mean	1.62	2.16	P = 0.51

Table 2.
Preoperative and Postoperative Pathologic Comparison of Patients With and Without Mesh Herniorrhaphy

	*RALP With History of Mesh Herniorrhaphy	RALP Without Mesh Herniorrhaphy	P Value
Number of patients	27 (8.7%)	282 (91.3%)	
Preoperative PSA	6.4	6.2	0.52
Preoperative clinical stage T1c	74.1%	77.0%	0.74
Pathologic T2	51.9%	82.1%	0.001
Total positive margin	18.5%	15.6%	0.17
Positive margin pT2	7.1%	11.1%	0.57
Positive margin pT3/4	30.8%	34.2%	0.79

*RALP=robotic-assisted laparoscopic prostatectomy.

Table 3.
Functional Outcomes of Patients With and Without Mesh Herniorrhaphy. One-year Follow-up Demonstrated

	RALP With History of Mesh Herniorrhaphy	RALP Without Mesh Herniorrhaphy	P Value
Number of Patients	27 (8.7%)	282 (91.3%)	
Continent (Mean Baseline/Followup IPSS*)	89% (9.4/8.4)	91% (8.6/5.7)	0.75
Bilateral Nerve Spare	44%	60%	0.13
Potent (Mean baseline/followup IIEF*)	83% (59/34)	81% (55/39)	0.84
Unilateral nerve spare	7.4%	14.1%	0.86
Potent (Mean baseline/followup IIEF*)	50% (31/26)	26.7% (44/16)	0.27
Non nerve spare	48.1%	26.3%	0.14
Potent (Mean baseline/followup IIEF*)	7.7% (42/8)	9.0% (37/3)	0.72

*IPSS=International Prostate Symptom score. IIEF=International Index of Erectile Function.

repair is difficult, if not nearly impossible to perform, and that patients should be counseled with appropriate alternative treatment options.

Since the publication of that case report, other authors[7,8] have described similar experiences. There is general consensus amongst these reports that the inflammatory reaction surrounding the anterior bladder may compromise an already tenuous vesicourethral anastomosis and that careful and meticulous nerve-sparing is not assured.[8,9] One group reported that the oncological outcomes of future pelvic surgery may be compromised as well.[6] They described a patient with muscle-invasive bladder cancer who had undergone prior bilateral laparoscopic hernia repair and was scheduled for a radical cystoprostatectomy. Intraoperative difficulties with dissection due to the mesh concerned the authors that such conditions could lead to bladder perforation and tumor spillage, adversely affecting the clinical outcome and overall patient prognosis.

With regard to minimally invasive prostatectomy, Erdogru et al[11] reported their experience with LRP after prior open or laparoscopic inguinal hernia repair. In their series of over 1000 patients who underwent LRP, 20 were identified with a history of prior laparoscopic inguinal hernia repair. This cohort was matched and compared with a group of LRP patients with a history of open hernia repair and a group of LRP patients with no history of herniorrhaphy. They found no differences in mean operative time, EBL, positive margin rate and continence. The authors found that prior open and laparoscopic herniorrhaphy did not present any noteworthy disadvantage during the procedure and concluded that LRP can be performed safely in these patients.

Recently, other studies have demonstrated successful LRP in patients with prior laparoscopic herniorrhaphy. Brown and Dahl[10] reported the first cases of performing LRP to completion in patients with previous laparoscopic inguinal hernia repair. They acknowledged that dense scarring may be present, but with the aid of laparoscopy, optimal planes of dissection can be better visualized, and the anterior bladder may be freed from mesh under direct visualization. In addition, there would be no compromise to the hernia repair, and the exposure of the mesh could be avoided. In the current series, 2/27 (7.4%) of our patients with a history of prior mesh hernia repair had undergone a bilateral laparoscopic inguinal hernia repair. Only 4 patients in all had undergone a laparoscopic herniorrhaphy; in addition to these, one patient underwent a unilateral inguinal hernia repair and one an umbilical hernia repair with mesh. In all of these patients, the RALP was completed without complication.

Although not reported, laparoscopic umbilical hernia repair can pose a similar surgical dilemma regarding a fibrotic inflammatory response associated with the mesh and the surrounding adhesions that form. This can be particularly problematic for pelvic laparoscopic procedures that are initiated intraperitoneally, such as the transperitoneal RALP. Accordingly, this may be obviated through extraperitoneal RALP. Extraperitoneal RALP has been reported to have no significant difference in operative time, EBL, length of stay, or complication rate compared with the transperitoneal approach.[14–16] In addition, patients with prior lower abdominal or pelvic surgery undergoing extraperitoneal RALP have similar operative characteristics and complication rates compared with patients with no prior surgery.[17] In particular, concerning patients with a prior history of prosthetic mesh inguinal herniorrhaphy, Stolzenburg et al[18] reported that simple modifications in port placement and surgical technique have made laparoscopic extraperitoneal prostatectomy a possibility. However, although the extraperitoneal approach may be a promising alternative for this patient population, creating the extraperitoneal space in a patient with mesh can be equally daunting as we have seen in the RRP literature.[7–9]

To our knowledge, there is one other series in the literature describing transperitoneal robotic-assisted laparoscopic prostatectomy in patients with prior intraabdominal mesh.[19] These investigators determined that RALP is feasible in patients with a history of hernia repair both with and without mesh, but only a minority (3%) of their patients had a history of mesh herniorrhaphy. In our institutional experience of 309 transperitoneal robotic prostatectomies, almost 9% of the patients had undergone prior mesh hernia repair. Interestingly, in our retrospective comparison, patients with a history of mesh herniorrhaphy had a slightly longer operative time but a lower EBL and shorter LOS. Although these differences did not attain statistical significance, we attributed these results to patient selection. We attempted more challenging cases later in our experience, and thus were able to demonstrate outcomes that were at least equivalent, and actually trending toward improvement. Although fewer of our mesh herniorrhaphy patients had organ-confined disease, neither pathologic nor quality of life outcomes appeared to suffer despite the more difficult dissection, again more likely a result of being higher on the learning curve when those cases were undertaken **(Tables 2 and 3)**. This was even the case in patients who had a laparoscopic inguinal hernia repair, who theoretically could have a tenuous anastomosis from scarring at the anterior bladder; these patients were not affected with regard to their continence.

Pelvic lymph node dissection (PLND) was performed in patients stratified preoperatively to intermediate and high-risk disease. Early in our series, patients defined as low-risk using the D'Amico classification did not undergo pelvic lymphadenectomy.[20] Later in our series, PLND was not performed in patients whose predicted risk of nodal involvement was 1% or less based on the Kattan preoperative nomogram.[21] However, over the last 15 months, we have performed PLND in all patients undergoing RALP, regardless of risk, because of the diagnostic value and low risk of the procedure. According to these criteria, the majority of our patients (19/23) with inguinal mesh underwent pelvic lymph node dissection. There was no increase in difficulty noted during the dissection in these patients; no significant difference in intraoperative characteristics was seen compared with that in patients who did not undergo pelvic lymph node dissection.

In a patient with a prior history of herniorrhaphy with prosthetic mesh placement, it is essential to proceed with caution, given the variable number of adhesions and fibrosis that may be encountered. Of paramount importance is gaining optimal access with precise port placement. Access into the abdomen must be carefully planned and executed. If patients have a prior history of umbilical hernia repair, we recommend gaining access remote from the area of the mesh, such as in the right upper quadrant, where the likelihood of encountering adhesions is less likely. In addition, although we did not in our experience, one could consider the Hassan technique of laparoscopic access. Once optimal port placement is obtained, the exceptional visualization supplied by the robotic system

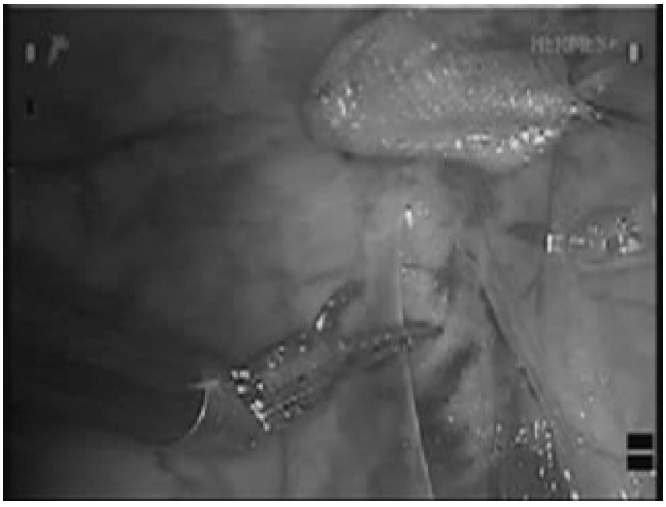

Figure 1. Prosthetic mesh from prior right inguinal hernia repair encountered during RALP. Mesh plug identified at entrance to internal inguinal ring.

and a laparoscopic template can facilitate meticulous dissection through a scar created by previously placed mesh. The intercalated mesh can be visualized and avoided, leaving the hernia repair intact **(Figure 1)**.

CONCLUSIONS

Hernia repair with intraabdominal mesh has been reported to complicate and potentially compromise oncological procedures, particularly RRP. We have shown through our institutional experience that RALP, in patients with a prior history of herniorrhaphy with mesh placement, is a reasonable alternative to LRP or RRP. We believe that with the growing popularity of RALP, urologists will continue to expand their indications for the procedure, exploiting the known advantages of robotic surgery to undertake more challenging cases, including patients with mesh herniorrhaphy.

References:

1. Menon M, Shrivastava A, Tewari A, et al. Laparoscopic and robot assisted radical prostatectomy: establishment of a structured program and preliminary analysis of outcomes. *J Urol.* 2002;168:945–949.

2. Ahlering TE, Skarecky D, Lee D, et al. Successful transfer of open surgical skills to a laparoscopic environment using a robotic interface: initial experience with laparoscopic radical prostatectomy. *J Urol.* 2003;170:1738–1741.

3. Binder J, Kramer W. Robotically assisted laparoscopic radical prostatectomy. *BJU Int.* 2001;87:408–410.

4. Menon M, Tewari A, Members of the Vattikuti Institute Prostatectomy Team. Robotic radical prostatectomy and the Vattikuti urology institute technique: an interim analysis of results and technical points. *Urology.* 2003;61(suppl 4A):15–20.

5. Ahlering TE, Woo D, Eichel L, et al. Robot-assisted versus open radical prostatectomy: a comparison of one surgeon's outcomes. *Urology.* 2004;63:819–822.

6. Hsia M, Ponsky LE, Rosenblatt S, et al. Laparoscopic inguinal hernia repair complicates future pelvic oncologic surgery. *Ann Surg.* 2004;240:922–923.

7. Cook H, Afzal N, Cornaby AJ. Laparoscopic hernia repairs may make subsequent radical retropubic prostatectomy more hazardous. *BJU Int.* 2003;91:729.

8. Cooperberg MR, Downs TM, Carroll PR. Radical retropubic prostatectomy frustrated by prior laparoscopic mesh herniorrhaphy. *Surgery.* 2004;135:452–453.

9. Katz EE, Patel RV, Sokoloff MH, et al. Bilateral laparoscopic inguinal hernia repair can complicate subsequent radical retropubic prostatectomy. *J Urol.* 2002;167:637–638.

10. Brown JA, Dahl DM. Transperitoneal laparoscopic radical prostatectomy in patients after laparoscopic prosthetic mesh inguinal herniorrhaphy. *Urology.* 2004;63:380vii-380ix.

11. Erdogru T, Teber D, Frede T, et al. The effect of previous transperitoneal laparoscopic inguinal herniorrhaphy on transperitoneal laparoscopic radical prostatectomy. *J Urol.* 2006;173:769–772.

12. Schuessler WW, Schulam PG, Clayman RV, et al. Laparoscopic radical prostatectomy: initial short-term experience. *Urology.* 1997;50:854–857.

13. Rutkow IM. Epidemiologic, economic, and sociologic aspects of hernia surgery in the United States in the 1990s. *Surg Clin North Am.* 1998;78:941–951.

14. Joseph JV, Rosenbaum R, Madeb R, et al. Robotic extraperitoneal prostatectomy: an alternative approach. *J Urol.* 2006;175:945–951.

15. Gettman MT, Hoznek A, Salamon L, et al. Laparoscopic radical prostatectomy: description of the extraperitoneal approach using the da Vinci robotic system. *J Urol.* 2003;170:416–419.

16. Atug F, Castle EP, Woods M, et al. Transperitoneal versus extraperitoneal robotic-assisted radical prostatectomy: is one better than the other? *Urology.* 2006;68:1077–1081.

17. Stolzenburg JU, Ho KMT, Do M, et al. Impact of previous surgery on endoscopic extraperitoneal radical prostatectomy. *Urology.* 2005;65:325–331.

18. Stolzenburg JU, Anderson C, Rabenalt T, et al. Endoscopic extraperitoneal radical prostatectomy in patients with prostate

cancer and previous laparoscopic inguinal mesh placement for hernia repair. *World J Urol*. 2005;23:295–299.

19. Laungani RG, Kaul S, Muhlataler F, et al. Impact of previous inguinal hernia repair on transperitoneal robotic prostatectomy. *Can J Urol*. 2007;14:3635–3639.

20. D'Amico AV, Whittington R, Malkowicz SB, et al. Biochemical outcome after radical prostatectomy, external beam radiation therapy, or interstitial radiation therapy for clinically localized prostate cancer. *JAMA*. 1998;280:969–974.

21. Kattan MW, Stapleton AM, Wheeler TM, et al. Evaluation of a nomogram used to predict the pathologic stage of clinically localized prostate carcinoma. *Cancer*. 1997;79:528–537.